

Nodular Fasciitis With Malignant Morphology and a *COL6A2–USP6* Fusion: A Case Report (of a 10-Year-old Boy)

International Journal of Surgical Pathology
2021, Vol. 29(6) 642–647
© The Author(s) 2021



Article reuse guidelines:
sagepub.com/journals-permissions
DOI: 10.1177/1066896921996045
journals.sagepub.com/home/ijsp



Tess Tomassen¹, Cees van de Ven, MD, PhD²,
Jakob Anninga, MD, PhD², Christian Koelsche, MD, PhD³,
Laura S. Hiemcke-Jiwa, MD, PhD^{2,4}, Simone ter Horst, MD, PhD^{2,4} ,
Wendy W. de Leng, PhD⁴, Franck Tirode, PhD⁵,
Marie Karanian, MD⁵, and Uta Flucke, MD, PhD^{1,2} 

Abstract

Nodular fasciitis is usually a benign lesion genetically characterized by ubiquitin-specific protease 6 (*USP6*) rearrangements. We present a case of a 10-year-old boy with a 1.5-week history of a painless mass on the right chest wall, which was excised. A histomorphologically malignant tumor with pronounced pleomorphism, atypical mitotic figures, and a myoid immunophenotype was observed. The methylation profile was consistent with nodular fasciitis and fluorescence in situ hybridization confirmed *USP6* rearrangement. Using Archer Fusion Plex (Sarcoma Panel) and RNA sequencing, a collagen, type VI, alpha 2 (*COL6A2*)–*USP6* gene fusion was subsequently identified. Furthermore, DNA clustering analysis also showed a match with nodular fasciitis. During the follow-up of 22 months, no recurrence or metastasis occurred. In conclusion, we describe a clinically benign, histomorphologically malignant mesenchymal neoplasm with a myoid immunophenotype, and a genetic and epigenetic profile consistent with nodular fasciitis. In such cases, molecular analysis is a useful adjunct to avoid unnecessary overtreatment.

Keywords

pleomorphic sarcoma, nodular fasciitis, *COL6A2–USP6*, fusion gene, clustering, DNA-cluster analysis, methylation profiling

Introduction

Nodular fasciitis (NF) is a benign rapidly growing myofibroblastic lesion, usually arising in the superficial soft tissue of young adult patients. Involvement of the upper limbs and trunk is most common but localization at any other site is possible.^{1–5} The identification of ubiquitin-specific protease 6 (*USP6*) rearrangement in over 90% of NF cases has not only supported its clonal neoplastic nature^{1,6–8} but also serves as a reliable diagnostic confirmation in respective lesions, especially when small biopsies are taken, to avoid overtreatment. Malignant behavior of NF has been reported exceptionally in cases with classical morphology.^{9,10} However, according to our knowledge, NF cases with pleomorphic sarcoma-like morphology are hitherto not described.

In this report, we present an unusual case of a clinically benign but morphologically malignant lesion in a 10-year-old boy, which is genetically and epigenetically consistent with NF.

Clinical Summary

A 10-year-old, otherwise healthy, boy presented with a 1.5-week history of a painless swelling on the right dorsal chest wall. Clinically, it was a firm, slightly mobile

mass, not adherent to the overlying skin but fixed to the muscle. On magnetic resonance imaging an intramuscular lobulated lesion in the serratus anterior muscle was seen, measuring 24 × 12 × 22 mm. The lesion showed slightly high signal intensity compared to the surrounding muscles on T1-weighted images and moderately high signal intensity on T2-weighted images. Hypointensity of the tumor border was observed in both T1-weighted and T2-weighted images. The mass extended along the superficial fascia of the muscle (fascial tail sign). Positron emission tomography scan localized the metabolic activity. After a core needle biopsy was

¹Department of Pathology, Radboud University Medical Center, Nijmegen, The Netherlands

²Princess Máxima Center for Pediatric Oncology, Utrecht, The Netherlands

³Department of General Pathology, University Hospital Heidelberg, Heidelberg, Germany

⁴Department of Pathology, University Medical Center Utrecht, Utrecht, The Netherlands

⁵Cancer Research Center of Lyon, INSERM & Department of Pathology, Centre Léon Bérard, Lyon, France

Corresponding Author:

Uta Flucke, Radboud University Medical Center, Department of Pathology, P.O. Box 9101, 6500 HB Nijmegen, The Netherlands.
Email: uta.flucke@radboudumc.nl

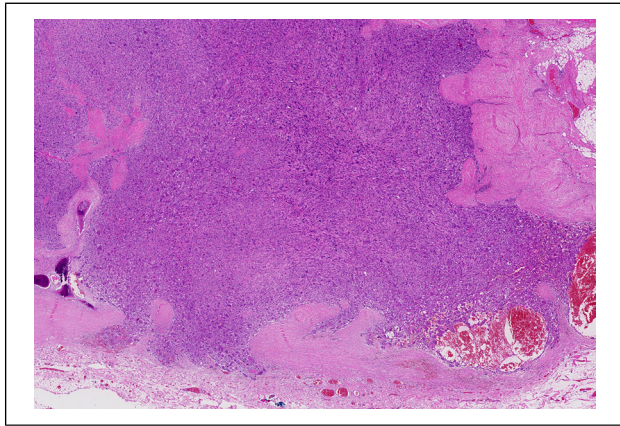


Figure 1. Low magnification shows a high cellular, infiltrative, and well-circumscribed soft tissue lesion.

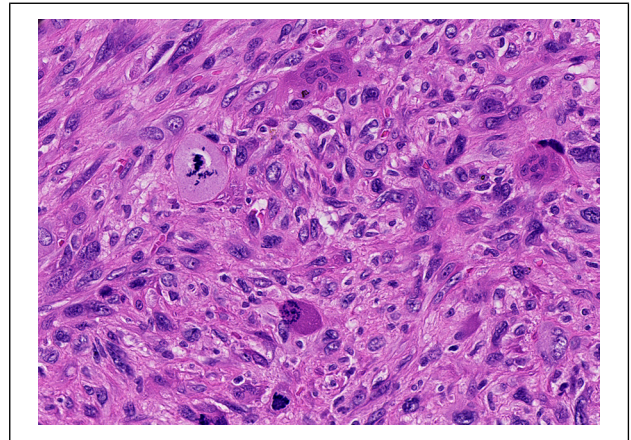


Figure 3. Atypical mitoses are frequent.

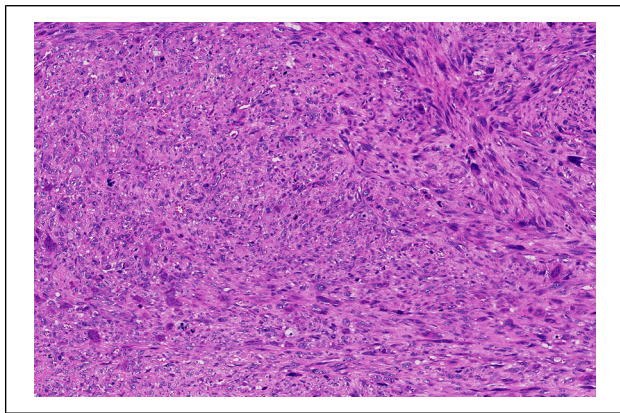


Figure 2. High magnification illustrates fascicular growth and pronounced pleomorphism.

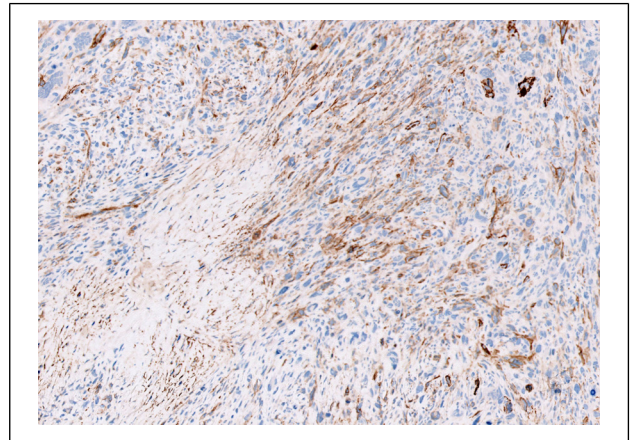


Figure 4. Smooth muscle actin (SMA) expression is inconsistent.

taken, yielding a diagnosis of pleomorphic sarcoma possibly leiomyogenic in type, wide resection including the deep fascia of the serratus anterior muscle and part of the latissimus dorsi muscle was performed. The tumor was completely removed with oncological margins. No adjuvant therapy was administered. Follow-up was performed every 3 months and the patient underwent annual computed tomography scanning and chest X-ray on the right chest wall. In the most recent follow-up, 22 months after surgery, the child had no subjective symptoms including pain and there was no sign of recurrence or metastasis.

Material and Methods

The tissue was fixed in 4% buffered formalin, routinely processed, and embedded in paraffin; 2 to 4 μ m thick sections were stained with hematoxylin and eosin and immunohistochemistry was performed using standard protocols and commercially available antibodies.

Fluorescence in situ hybridization (FISH) was previously reported by Bekers et al,¹¹ whereas Archer Fusion

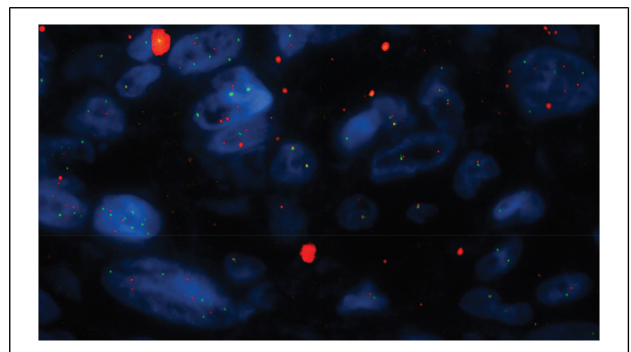


Figure 5. By *USP6*-FISH, a break-apart signal indicating rearrangement was shown.

Abbreviations: *USP6*, ubiquitin-specific protease 6; FISH, fluorescence in situ hybridization.

Plex (Sarcoma Panel) was used analogously to Lam et al.¹² RNA sequencing and DNA clustering analysis were described by Karanian et al.¹³ DNA methylation profiling was performed as published by Koelsche et al.¹⁴

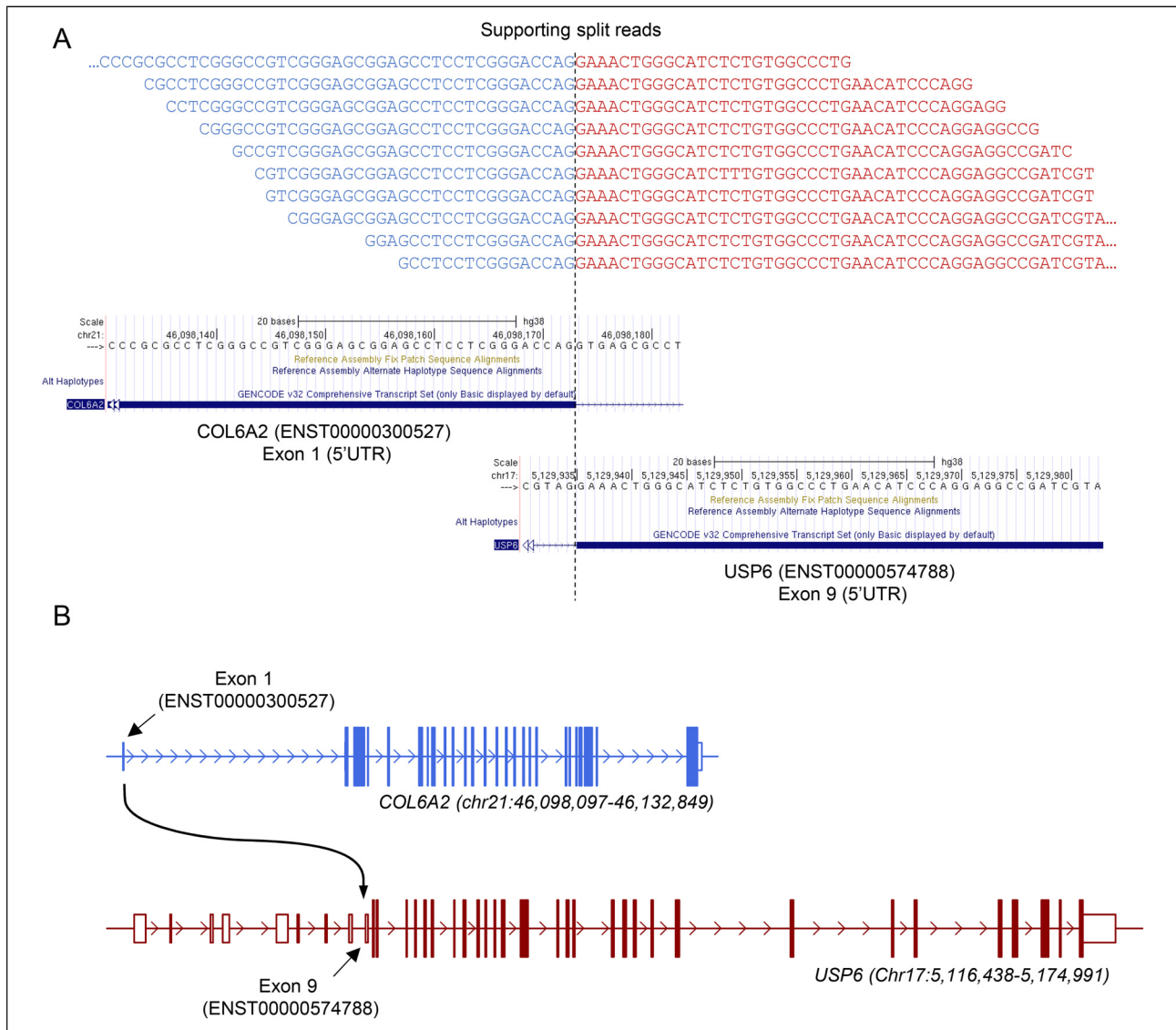


Figure 6. *COL6A2*–*USP6* fusion gene as detected by RNAseq. (A) Ten unique reads supporting the *COL6A2*–*USP6* fusion were detected to align both at the *COL6A2* (ENST00000300527) exon 1 boundary and the exon 9 boundary of *USP6* (ENST00000574788). Positions on UCSC Genome Browser are shown for both genes. (B) Schema of the genomic region of *COL6A2* (blue) and *USP6* (red) genes. Genomic regions and positions indicated are related to the GRCh38 genome assembly. Abbreviations: *COL6A2*, collagen, type VI, alpha 2; *USP6*, ubiquitin-specific protease 6.

A next-generation sequencing (NGS) cancer hotspot panel as described by de Leng et al¹⁵ was additionally used.

Pathological Findings

The core needle biopsy revealed a pleomorphic tumor with a fascicular growth pattern. The atypical cells had enlarged, irregular, and vesicular nuclei with prominent nucleoli. Mitotic figures were numerous including atypical forms. Osteoclast-like giant cells were seen, scattered throughout. The resection specimen showed a relatively circumscribed lesion incompletely surrounded by a collagenous pseudocapsule. Histology was similar to the biopsy. In addition,

there was focally peripheral ossification and hemosiderin deposition throughout the lesion. Vascular invasion was observed focally (Figures 1 to 3).

Immunohistochemically, the spindle cells were positive for smooth muscle actin (SMA) and caldesmon and negative for desmin, S100, cytokeratin MNF116, epithelial membrane antigen, and CD34 (Figure 4).

Molecular Findings

The methylation profile matched with NF (calibration score: 0.94). Therefore, FISH, Archer Fusion Plex (Sarcoma Panel) and RNA sequencing were performed identifying *USP6*

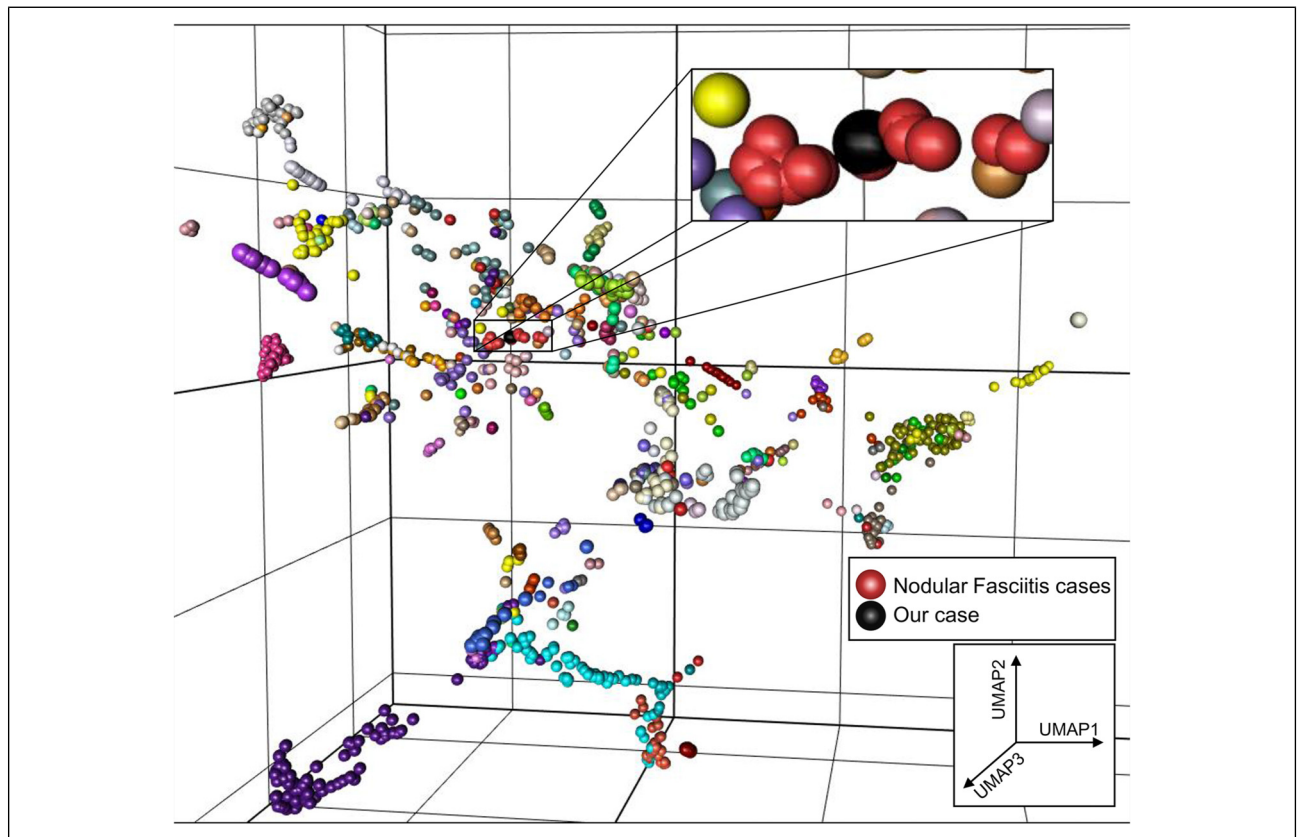


Figure 7. Uniform manifold approximation and projection (UMAP) analysis represented nodular fasciitis cases in red and our case in black.

rearrangement (break apart signal in 49 of 100 cells) with a collagen, type VI, alpha 2 (*COL6A2*)–*USP6* (ex1–ex9) fusion (Figures 5 and 6). DNA clustering analysis (uniform manifold approximation and projection [UMAP] three-dimensional plot) of 1434 sarcoma samples in 124 molecular subgroups allocated the lesion within the NF cluster (Figure 7). An NGS cancer hotspot panel with complete coding regions of the genes F-box and WD repeat containing 7 (*FBXW7*), SWI/SNF related, matrix associated, actin dependent regulator of chromatin, subfamily a, member 4 (*SMARCA4*), SWI/SNF related, matrix associated, actin dependent regulator of chromatin, subfamily b, member 1 (*SMARCB1*), Tumor protein P53 (*TP53*), von Hippel-Lindau tumor suppressor (*VHL*), and WT1 transcription factor (*WT1*) revealed no aberrations.

Diagnosis

Based on morphological and immunohistochemical findings, the initial diagnosis on the biopsy specimen was high-grade sarcoma possibly leiomyogenic in type, which was confirmed on the resection specimen showing a similar histological and immunohistochemical profile (Figures 1 to 4). *USP6* rearrangement with a *COL6A2*–*USP6* fusion, DNA clustering analysis, and methylation profiling, however, led to the diagnosis of NF (Figures 5 to 7).

Discussion

NF usually is a benign superficially located soft tissue lesion molecularly defined by the presence of a *USP6* rearrangement.^{1,6} Currently, several *USP6* fusion partners including ribosome binding protein 1 (*RRBP1*), myosin heavy chain 9 (*MYH9*), calumenin (*CALU*), catenin beta 1 (*CTNBN1*), MIR22 host gene (*MIR22HG*), secreted protein acidic and cystein rich (*SPARC*), thrombospondin 2 (*THBS2*), and *COL6A2* are known⁸ and their number is still growing due to improved molecular techniques.

USP6 fusions also occur in other nonmalignant soft tissue and bone abnormalities such as myositis ossificans, fibro-osseous pseudotumor of the digits, a subset of fibromas of the tendon sheath, possibly better classified as NF, primary aneurysmal bone cyst, and giant-cell tumors of the small bones.^{11,16–20} All these lesions probably form a spectrum of one entity called *USP6*-associated neoplasms.²⁰ As our lesion was intramuscularly situated and showed focally ossification one could argue whether this case better could be classified as myositis ossificans. However, this is clinically not of relevance.

The current available comprehensive molecular analysis allowed us to make the diagnosis of NF in a histomorphological pleomorphic sarcoma-like lesion in a child. We identified for NF known *COL6A2*–*USP6* fusion.⁸

Also, methylation profiling and DNA-clustering analysis were consistent with NF. Furthermore, we did not find secondary genetic changes using a NGS oncology panel. To our knowledge, this is the first NF case showing pleomorphism with bizarre nuclei and atypical mitotic figures, not in concordance with the classical morphology of NF. However, the lesion behaved benignly like ordinary NF cases.

In the literature, we encountered two cases with malignant clinical course.^{9,10} In contrast to our case, both showed classical histologic features of NF and a *PPP6R3-USP6* fusion with additional amplification suggesting that this specific amplified fusion gene is causative for the aggressive clinical course of the disease. One of these cases was characterized by multiple recurrences and metastatic behavior whereas the other case showed aggressive growth with local invasion.^{9,10}

In summary, we present a soft tissue tumor in a child with morphological features of a high-grade sarcoma but with molecular characteristics of NF representing the first case of a morphologically malignant NF, albeit with benign clinical features.

This case illustrates that the morphology of soft tissue tumors does not predict per se clinical behavior and genetic analysis is of added value to get a better insight into the morphological spectrum of an entity. The latter can help to avoid over- or undertreatment.

Declaration of Conflicting Interests

The authors declared no potential conflicts of interest with respect to the research, authorship, and/or publication of this article.

Funding

The authors received no financial support for the research, authorship, and/or publication of this article.

Ethical Approval

Confirm that all the research meets the ethical guidelines, including adherence to the legal requirements of the study country.

Informed Consent

Informed consent was obtained.

Trial Registration

Not applicable, because this article does not contain any clinical trials.

ORCID iDs

Simone ter Horst  <https://orcid.org/0000-0003-4849-5826>

Uta Flucke  <https://orcid.org/0000-0003-0315-4307>

References

1. WHO Classification of Tumours Editorial Board. *Soft Tissue and Bone Tumours*. International Agency for Research on Cancer; 2020.
2. Luna A, Molinari L, Bollea Garlatti LA, et al. Nodular fasciitis, a forgotten entity. *Int J Dermatol*. 2019;58:190-193.
3. Gibson TC, Bishop JA, Thompson LD. Parotid gland nodular fasciitis: a clinicopathologic series of 12 cases with a review of 18 cases from the literature. *Head Neck Pathol*. 2015;9:334-344.
4. Chemmanam JJ. Nodular fasciitis in the tongue—a mimicker of malignancy: case report and review of literature. *Indian J Surg Oncol*. 2017;8:214-216.
5. Malik F, Wang L, Yu Z, et al. Benign infiltrative myofibroblastic neoplasia of childhood with *USP6* gene rearrangement. *Histopathology*. 2020;77:760-768.
6. Erickson-Johnson MR, Chou MM, Evers BR, et al. Nodular fasciitis: a novel model of transient neoplasia induced by *MYH9-USP6* gene fusion. *Lab Invest*. 2011;91:1427-1433.
7. Paulson VA, Stojanov IA, Wasman JK, et al. Recurrent and novel *USP6* fusions in cranial fasciitis identified by targeted RNA sequencing. *Mod Pathol*. 2020;33:775-780.
8. Patel NR, Chrisinger JS, Demicco EG, et al. *USP6* activation in nodular fasciitis by promotor-swapping gene fusions. *Mod Pathol*. 2017;30:1577-1588.
9. Guo R, Wang X, Chou MM, et al. *PPP6R3-USP6* amplification: novel oncogenic mechanism in malignant nodular fasciitis. *Genes Chromosomes Cancer*. 2016;55:640-649.
10. Teramura Y, Yamazaki Y, Tanaka M, et al. Case of mesenchymal tumor with the *PPP6R3-USP6* fusion, possible nodular fasciitis with malignant transformation. *Pathol Int*. 2019;69:706-709.
11. Bekers EM, Eijkelenboom A, Grünberg K, et al. Myositis ossificans—another condition with *USP6* rearrangement, providing evidence of a relationship with nodular fasciitis and aneurysmal bone cyst. *Ann Diagn Pathol*. 2018;34:56-59.
12. Lam SW, Cleton-Jansen AM, Cleven AH, et al. Molecular analysis of gene fusions in bone and soft tissue tumors by anchored multiplex PCR-based targeted next-generation sequencing. *J Mol Diagn*. 2018;20:653-663.
13. Karanian M, Kelsey A, Painsavoine S, et al. *SRF* fusion other than with *RELA* expand the molecular definition of *SRF*-fused perivascular tumors. *Am J Surg Pathol*. 2020;44:1725-1735.
14. Koelsche C, Schrimpf D, Stichel D, et al. Sarcoma classification by DNA methylation profiling. *Nat Commun*. 2021;12:498
15. de Leng WW, Gadellaa-van Hooijdonk CG, Barendregt-Smouter FA, et al. Targeted next generation sequencing as a reliable diagnostic assay for the detection of somatic mutations in tumours using minimal DNA amounts from formalin fixed paraffin embedded material. *PLoS One*. 2016;11:e0149405.
16. Agaram NP, LeLoarer FV, Zhang L, et al. *USP6* gene rearrangements occur preferentially in giant cell reparative granulomas of the hands and feet but not in gnathic location. *Hum Pathol*. 2014;45:1147-1152.
17. Blackburn PR, Davila JI, Jackson RA, et al. RNA sequencing identifies a novel *USP9X-UPS6* promoter swap gene fusion in a primary aneurysmal bone cyst. *Genes Chromosomes Cancer*. 2019;58:589-594.

18. Carter JM, Wang X, Dong J, Westendorf J, Chou MM, Oliveira AM. USP6 genetic rearrangements in cellular fibroma of tendon sheath. *Mod Pathol.* 2016; 29: 865-869.
19. Flucke U, Shepard SJ, Bekers EM, et al. Fibro-osseous pseudotumor of digits—expanding the spectrum of clonal transient neoplasms harboring USP6 rearrangement. *Ann Diagn Pathol.* 2018;35:53-55.
20. Hiemcke-Jiwa LS, van Gorp JM, Fisher C, Creytens D, van Diest PJ, Flucke U. USP6-associated neoplasms: a rapidly expanding family of lesions. *Int J Surg Pathol.* 2020;28:816-825.