

CASE REPORT

Type 3 of progressive familial intrahepatic cholestasis (PFIC-3): Case report

Mohammad Badr Almoshantaf¹  | Suja Alasaad² | Mhd Amin Alzabibi² | Mosa Shibani² | Weaam Ezzdean³

¹Department of Neurosurgery, Ibn Al-Nafees Hospital, Damascus, Syria

²Faculty of Medicine, Syrian Private University, Damascus, Syria

³Department of Urology, Ibn Al-Nafees Hospital, Damascus, Syria

Correspondence

Mohammad Badr Almoshantaf,
Department of Neurosurgery, Ibn Al-Nafees Hospital, Damascus, Syria.
Email: baderalmoshantaf1995@gmail.com

Abstract

Genetic testing should always be advised in both parents and children of families with progressive familial intrahepatic cholestasis as early detection will provide more options to a better qualitative life.

KEYWORDS

ABCB4 gene, case report, progressive familial intrahepatic cholestasis, type 3, vitamin K deficiency

1 | INTRODUCTION

Progressive familial intrahepatic cholestasis (PFIC) is an abnormality in the formation and secretion of bile components and bile acids, which is present in infancy and early childhood as signs of growth failure and vitamin K deficiency. We present a case of a 6-year-old female who complained of yellow discoloration of the sclera and skin and abdominal distension. Her history revealed tiredness, mild abdominal pain, itching, frequent bleeding, and epistaxis. At first, hepatic cirrhosis was the diagnosis, but the abdominal ultrasound revealed hypoechoic lesions with the normal bile duct. The diagnosis of PFIC-3 was confirmed via detecting pathogenic variants in the ABCB4 gene. PFIC-3 is an extremely rare case in the literature, which we can add to the other reported cases previously.

Progressive familial intrahepatic cholestasis (PFIC) is a heterogeneous group of genetic autosomal recessive disorders which cause defects in the formation and secretion of bile components and bile acids.¹ PFIC consists of five different variant forms numbered 1 through 5 based on the

gene involved.² Most of these disorders present in infancy and early childhood as signs of growth failure vitamin K deficiency (i.e., easy bruising, epistaxis, coagulopathies) due to impaired vitamin K absorption and progressive liver disease leading to cirrhosis before adulthood.^{1,2}

PFIC-3 is an autosomal recessive disorder arising from mutations in the ATP-binding cassette subfamily B member 4 (ABCB4) gene located on chromosome 7.³ This gene encodes multidrug resistance protein-3 (MDR3). This 12-domain transmembrane plasmalemmal translocator actively transports phosphatidylcholine from the inner to the outer canalicular membrane to neutralize bile salts and prevent injury to biliary epithelial and bile canaliculi.⁴

The PFIC-3 patients are homozygous or compound heterozygous for ABCB4 pathogenic variants; however, monoallelic ABCB4 variants may also result in cholestatic liver disease.⁵ Genetic testing confirms the diagnosis of PFIC syndromes for all types, and immunostaining can confirm the diagnosis of PFIC types 2 and 3.^{6,7}

There were no approved pharmacological treatment options to treat PFIC that may lead to symptom relief or

even limit the disease progression. Ultimately, liver failure would be the definitive result and may indicate a need for liver transplantation.⁶

2 | CASE REPORT

A 6-year-old girl presented to the internal medicine clinic in King Saud medical city due to yellow discoloration of the sclera and skin and abdominal distension. The parents reported that their child has recently complained of tiredness, mild abdominal pain, itching, frequent bleeding, and epistaxis. Her parents have noticed the abdominal distension earlier. However, they did not seek any medical consultation until they noticed the yellow discoloration of the skin and mucous membranes at 4 years old. She was diagnosed with hepatic cirrhosis of unknown etiology at the time. Her family history was unremarkable, but the parents have mentioned that they were second-degree relatives.

The physical examination revealed a yellow discoloration of the skin sclera and the mucous membranes,

failure to thrive, hepatosplenomegaly, moderate ascites, and ecchymosis in both legs.

Her vital signs were normal, and the physical examination was otherwise normal.

The abdominal ultrasonography examination reported that the liver was of average size measuring 11.5 cm coarse parenchymal echo pattern, with multiple small variable sizes ill-defined hypoechoic lesions (Figure 1), the gallbladder had a thick wall yet no stones or biliary sludge were seen inside (Figure 2), and splenomegaly was also reported. The examination was otherwise normal. The complete blood count test revealed mild normocytic normochromic anemia, mild leukopenia, and neutropenia, thrombocytopenia, as hemoglobin levels were 11.2 g/dL (normal g/dL), hematocrit of 32.0 percent (normal percent), mean corpuscular volume of white blood cell count $4.47 \times 10^3/\mu\text{L}$ (normal $10^3/\mu\text{L}$), platelet count of $92 \times 10^3/\mu\text{L}$. Other laboratory tests revealed elevated serum AST of 223 U/L (normal <40 U/L), ALT of 115 U/L (normal <50 U/L), and total bilirubin levels of 4.14 mg/dL (normal 0.2–1.3 mg/dL), alkaline phosphatase levels of 647 U/L (normal 38–126 U/L) whereas serum GGT was

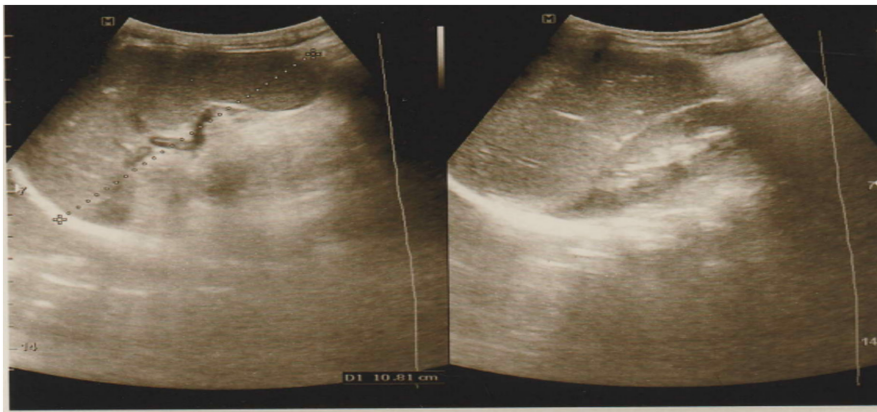


FIGURE 1 Abdominal ultrasound revealed multiple small variable sizes ill-defined hypoechoic lesions.

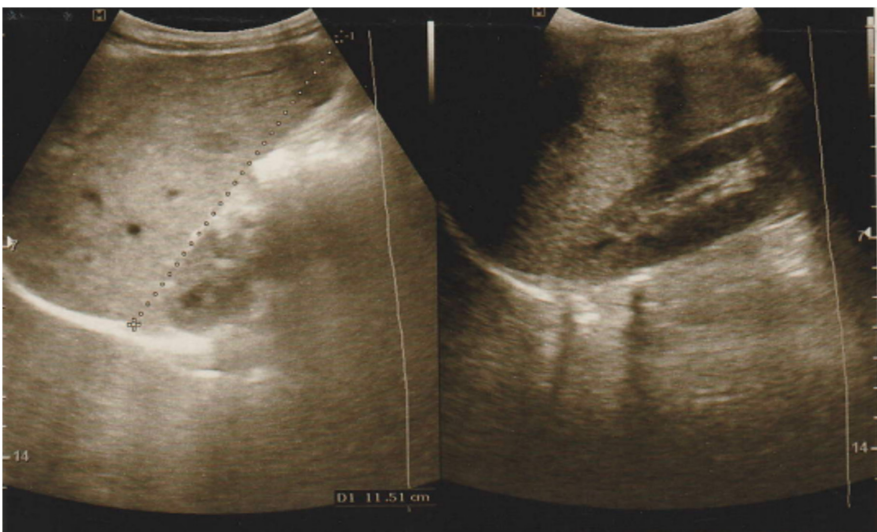


FIGURE 2 Abdominal ultrasound revealed no stones or biliary sludge in gallbladder.

not measured. Thyroid-stimulating hormone was also measured and revealed a serum level of 6.54 mIU/L (normal 0.465–4.68 mIU/L), the measurement of endomysial autoantibodies was positive. Other laboratory tests were in the normal range. The diagnosis of PFIC-3 was confirmed via detecting pathogenic variants in the ABCB4 gene. The patient has been listed as a candidate for liver transplantation, as the patient showed signs of portal hypertension in ultrasonography examination after a 1-year follow-up.

3 | DISCUSSION

PFIC-3 is an autosomal recessive disease. This is a rare case of PFIC-3, which results from consanguineous parents. The parents are second-degree relatives with no clinical signs of PFIC-3. Neither the mother nor the patient had reported jaundice in the post gestation period. The patient's siblings are unaffected but were recommended for carrier testing.

PFIC-3 usually manifests in later childhood or young adulthood. Unlike type 1 and type 2, PFIC-3 has a later onset and slower prognosis.⁸ In our case, signs of splenomegaly appeared in the infancy period at the first months after birth, but jaundice was delayed until 4 years of age. Occasional ascites and leg pigmentations have been noted after. Coagulation profile abnormalities are coherent with obstructive chronic liver disease. Infections with *Salmonella typhi* or *Brucella* were excluded. Serology testing for hepatitis B and C were also negative. We have concluded a diagnosis of PFIC-3 based on both clinical picture and genetic testing.

Using cytogenetic testing, biochemical testing, and molecular testing, a variant of uncertain significance has been detected in the PC gene, which is associated with pyruvate carboxylate deficiency. Although the clinical picture is not adequately consistent with severe types of pyruvate carboxylate deficiency, episodic types cannot be excluded. Thus, further genetic counseling may be required.

Symptomatic treatment involving ursodeoxycholic acid was ordered. The patient is beginning to show signs of portal hypertension. She is on the list for liver transplantation, and it is expected to be fully curable.

A similar case has been described by Zhang et al.⁹ in which PFIC-3 is combined with biliary atresia. A 4-month-old female presented with severe jaundice, pruritus, and pale stool for 20 days. Abnormally strong echoes near the portal area, an abnormally small gallbladder with an irregularly stiff wall, and splenomegaly were identified on abdominal ultrasound. Blood tests showed elevated liver enzymes as well. Kasai

portoenterostomy was enough to relieve clinical symptoms and improve blood tests. To compare with our case, this patient presented at a younger age, with more complicated symptoms due to biliary atresia, and eventually required the Kasai procedure. Similar ultrasound features and elevated liver blood tests were observed. The diagnosis was confirmed by genetic testing of the ABCB4 gene as well.

Additionally, Lipiński et al. have reported four cases of PFIC-3.¹⁰ The mean age was 7. Only two of them presented with pruritus, and all of them had splenomegaly. All of them established chronic cholestatic liver disease of unknown etiology, which was the key to order genetic counseling. Several novel variants have been identified. They concluded that the clinical phenotype of PFIC-3 could be variable, and the diagnosis of PFIC-3 is difficult because some PFIC-3 patients initially presented with no jaundice. Fortunately, in our case, our patient's main complaint was jaundice, which helped faster diagnosis.

4 | CONCLUSION

Children with jaundice, and elevated liver enzymes, with unknown etiology, should always be considered for genetic testing. Although PFIC-3 is not widely common, we recommend that consanguineous parents should undergo genetic counseling before conceiving.

AUTHOR CONTRIBUTIONS

Mohammad Badr Almoshantaf: Conceptualization; writing – original draft; writing – review and editing. **Suja Alasaad:** Writing – original draft; writing – review and editing. **Mhd Amin Alzabibi:** Writing – original draft; writing – review and editing. **Mosa Shibani:** Writing – original draft; writing – review and editing. **Weaam Ezzdean:** Writing – original draft; writing – review and editing.

CONFLICT OF INTEREST STATEMENT

The authors have no conflict of interest to declare.

DATA AVAILABILITY STATEMENT

Any further data may be accessed upon request.

CONSENT

Written informed consent was obtained from the patient to publish this report in accordance with the journal's patient consent policy.

ORCID

Mohammad Badr Almoshantaf  <https://orcid.org/0000-0002-7369-8978>

REFERENCES

1. Goubran M, Aderibigbe A, Jacquemin E, et al. Case report: progressive familial intrahepatic cholestasis type 3 with compound heterozygous ABCB4 variants diagnosed 15 years after liver transplantation. *BMC Med Genet.* 2020;21:238. doi:10.1186/s12881-020-01173-0
2. Davit-Spraul A, Gonzales E, Baussan C, Jacquemin E. Progressive familial intrahepatic cholestasis. *Orphanet J Rare Dis.* 2009;4:1. doi:10.1186/1750-1172-4-1
3. de Vree J, Jacquemin E, Sturm E, et al. Mutations in the MDR3 gene cause progressive familial intrahepatic cholestasis. *Proc Natl Acad Sci USA.* 1998;95(1):282-287. doi:10.1073/pnas.95.1.282
4. De Masi R, Orlando S, De Donno A, et al. Progressive familial intrahepatic cholestasis type-3 and multiple sclerosis: lessons from comorbidity. *Ann Clin Transl Neurol.* 2019;6:2347-2350. doi:10.1002/acn3.50883
5. Lipiński P, Ciara E, Jurkiewicz D, Płoski R, Wawrzynowicz-Syczewska M, Pawłowska J, Irena Jankowska: progressive familial intrahepatic cholestasis type 3: report of four clinical cases, novel ABCB4 variants and long-term follow-up. *Ann Hepatol.* 2021;25:1665-2681. doi:10.1016/j.aohep.2021.100342
6. Baker A, Kerkar N, Todorova L, Kamath BM, Roderick HJ. Houwen: systematic review of progressive familial intrahepatic cholestasis. *Clin Res Hepatol Gastroenterol.* 2019;43(1):20-36. doi:10.1016/j.clinre.2018.07.010
7. Beuers U, Trauner M, Jansen P, Poupon R. New paradigms in the treatment of hepatic cholestasis: from UDCA to FXR, PXR and beyond. *J Hepatol.* 2015;62(1):S25-S37. doi:10.1016/j.jhep.2015.02.023
8. Gunaydin M, Cil ATB. Progressive familial intrahepatic cholestasis: diagnosis, management, and treatment. *Hepat Med.* 2018;10:95-104. doi:10.2147/HMER.S137209
9. Zhang BP, Huang ZH, Dong C. Biliary atresia combined with progressive familial intrahepatic cholestasis type 3: a case report and review of the literature. *Medicine.* 2019;98(19):e15593. doi:10.1097/MD.00000000000015593
10. Lipiński P, Ciara E, Jurkiewicz D, et al. Progressive familial intrahepatic cholestasis type 3: report of four clinical cases, novel ABCB4 variants and long-term follow-up. *Ann Hepatol.* 2021;25:100342. doi:10.1016/J.AOHEP.2021.100342

How to cite this article: Almoshantaf MB, Alasaad S, Alzabibi MA, Shibani M, Ezzdean W. Type 3 of progressive familial intrahepatic cholestasis (PFIC-3): Case report. *Clin Case Rep.* 2023;11:e7197. doi:10.1002/ccr3.7197