

# Hemothorax Following Traumatic Dobhoff Tube Insertion

Lindsey M. Shain<sup>1</sup>, Leslie McHale<sup>1</sup>, Taha Ahmed<sup>1</sup>

1. Internal Medicine, University of Kentucky, Lexington, USA

**Corresponding author:** Taha Ahmed, tah227@uky.edu

---

---

## Abstract

Dobhoff tube is a specialized small-bore and flexible nasogastric tube that makes it more comfortable for placement than a usual nasogastric tube. Dobhoff tube insertion is commonly considered a relatively safe bedside procedure, but it is not without its associated risks. Inadvertent tracheobronchial placement of Dobhoff tube has been associated with severe complications, most notably pneumothorax. We present a rare cause of right-sided hemothorax following tracheobronchial insertion of a Dobhoff tube with a prolonged and arduous clinical course.

---

**Categories:** Emergency Medicine, Internal Medicine, Gastroenterology

**Keywords:** hemothorax, dobhoff tube

## Introduction

Dobhoff and other flexible, small-bore nasogastric tubes are frequently placed for maintenance of enteral nutrition and delivery of medications in the inpatient setting. Dobhoff tube placement is typically considered a benign procedure and is most often performed using only visual and tactile clues to guide insertion during swallowing. Proper intra-gastric positioning is confirmed afterward via radiography [1,2]. A large majority of these cases are met with no complications. However, there have been several reported instances of inadvertent bronchopulmonary placement that have resulted in significant pulmonary trauma, particularly pneumothorax [3-8]. Hemothorax (a collection of blood within the pleural cavity) has been mentioned as a potential complication of a misplaced enteral feeding tube, but very few cases have been documented previously [9,10]. The aim of this report is to present a unique case of traumatic hemothorax caused by Dobhoff tube misplacement.

## Case Presentation

An 86-year-old Caucasian male with a history of hypertension, peripheral vascular disease, coronary artery disease, and rheumatoid arthritis presented to our facility as a direct transfer from an outside hospital (OSH) due to hemothorax. Per OSH documentation, the patient initially presented for acute encephalopathy. Due to his altered mental status, reported difficulties with swallowing, and concern for malnutrition, he was evaluated with a modified barium swallow study on hospital day (HD) 8. It demonstrated a high risk for aspiration, and a Dobhoff tube was subsequently placed at the bedside for delivery of enteral nutrition. A chest X-ray performed shortly after the tube placement demonstrated that the tip of the Dobhoff tube was within the right lung base, following the course of the right mainstem bronchus (Figure 1).

Review began 01/29/2021

Review ended 02/01/2021

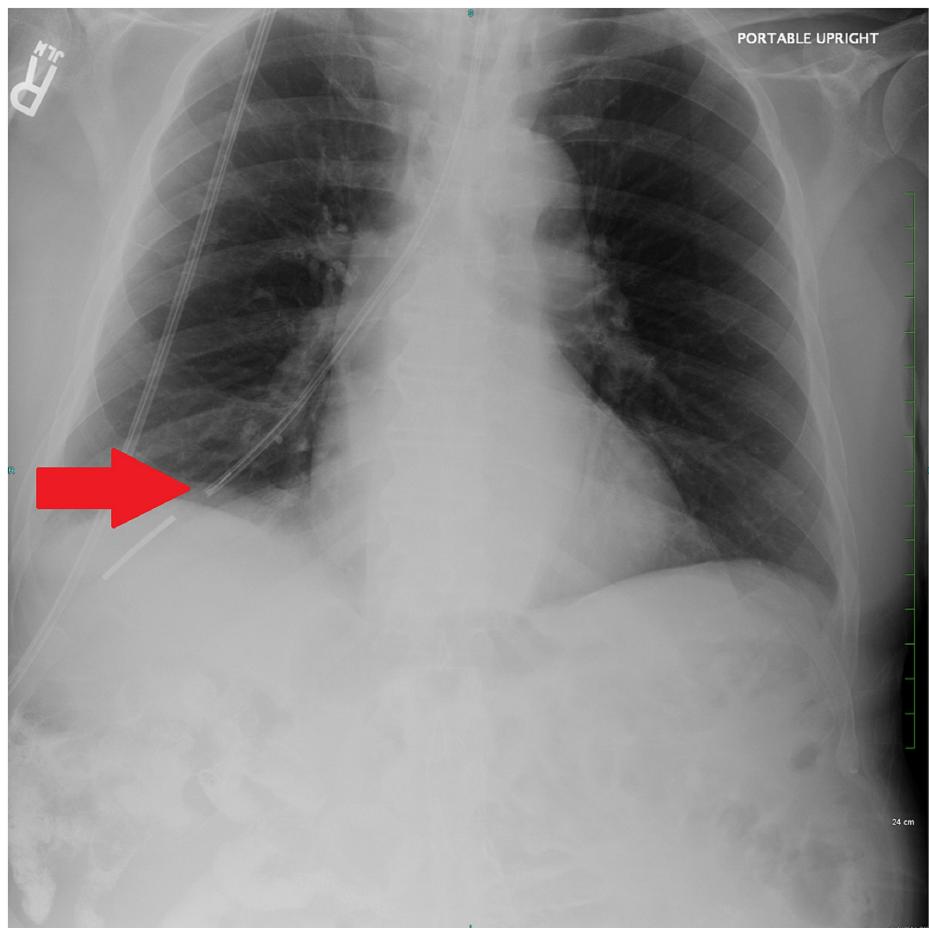
Published 02/03/2021

© Copyright 2021

Shain et al. This is an open access article distributed under the terms of the Creative Commons Attribution License CC-BY 4.0., which permits unrestricted use, distribution, and reproduction in any medium, provided the original author and source are credited.

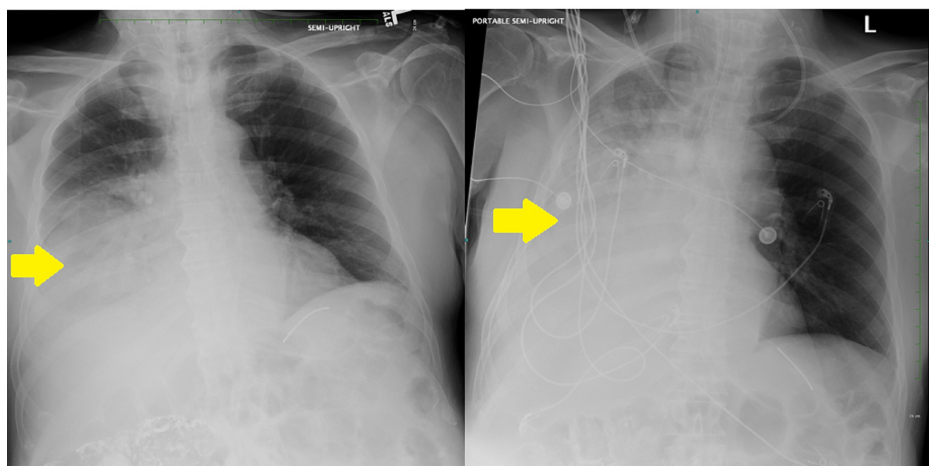
### How to cite this article

Shain L M, McHale L, Ahmed T (February 03, 2021) Hemothorax Following Traumatic Dobhoff Tube Insertion. Cureus 13(2): e13097. DOI 10.7759/cureus.13097



**FIGURE 1: Chest X-ray demonstrating the Dobhoff tube penetrating the right lung base via the right mainstem bronchus (red arrow).**

The Dobhoff tube was immediately removed and replaced on HD 9 under fluoroscopic guidance. Sequential chest X-rays on HD 10 demonstrated progressively increasing right-sided pleural effusion without evidence of pneumothorax (Figure 2).



**FIGURE 2: Sequential chest X-rays demonstrating progressive accumulation of right-sided pleural effusion (yellow arrows).**

The patient became hypoxic and was intubated for acute hypoxic respiratory failure. Hemoptysis was later observed on endotracheal tube suctioning. Chest computed tomography (CT) the following day revealed a

large right-sided pleural effusion with areas of attenuation concerning for hemothorax, a right consolidating pneumonia, and a cavitating infiltrate in the right upper lobe concerning aspiration pneumonia. Broad-spectrum antibiotics were initiated, and a chest tube was placed for drainage of hemothorax.

On HD 17, the patient was transferred to our facility for continued intensive care unit (ICU) management. He arrived on mechanical ventilation, with a right-sided chest tube in place. Broad-spectrum antibiotic treatment was continued due to persistent right consolidation and right upper lobe cavitating infiltrate. During the ICU admission, the patient's chest tube was replaced and intrapleural combination tissue plasminogen activator (TPA) and dornase were administered with complete resolution of the hemothorax. The patient was extubated on HD 33. Subsequently, the patient failed multiple modified barium swallow studies. Multiple Dobhoff tubes were replaced due to concern for aspiration, the necessity of maintaining enteral nutrition, and repeated removal by the patient. These were met with no further complications. The patient was ultimately given a percutaneous endoscopic gastrostomy tube with plans for discharge to a subacute rehabilitation center.

## Discussion

Small-bore nasogastric feeding tubes continue to be used widely to provide adequate enteral nutrition to patients with barriers to normal oral intake. Due to a typical blind placement procedure, abnormal positioning is often only appreciated after significant trauma is already dealt with in the lungs or other organs. Over the past few decades, the incidence of feeding tube misplacement into the bronchopulmonary system has remained around 1-3% of all tube placements, with pneumothorax being the most frequent complication [11,12]. Our case exemplifies another potentially life-threatening consequence of Dobhoff tube misplacement, hemothorax. Hemothorax from any cause is associated with a number of serious consequences such as atelectasis, anemia, respiratory failure, hemorrhagic shock, and infection of pleural fluid (i.e., empyema), among others [10]. In our patient, such dire outcomes were fortunately averted. Full resolution of the hemothorax was achieved with chest tube placement and treatment with TPA/dornase alpha.

Prior reports of traumatic Dobhoff placement have described situations in which attempts at insertion were met with some resistance [7]. Others described uneventful placements with no resistance or other hints that misplacement had occurred [4,10]. Because the inciting event in the current case occurred at a hospital outside of the authors' institution, the full context surrounding the feeding tube misplacement is unclear. Regardless, clinical signs during blind placement are often unreliable indicators of proper positioning. Post-insertion X-ray remains the gold standard for placement confirmation but does not necessarily prevent adverse outcomes [12]. Newer techniques such as electromagnetic guidance allow for real-time tracking as a feeding tube is being advanced at a lower cost than traditional fluoroscopy and without exposure to ionizing radiation. This method has demonstrated a high success rate with reduced complications from pulmonary placement [13,14].

In general, we aim to highlight a severe complication that may arise from a routine procedure and to hopefully increase awareness of potentially fatal consequences. A growing body of evidence supports the safety, efficacy, and feasibility of new techniques for bedside guidance of Dobhoff tube insertion. Currently, fluoroscopy-guided placement in every patient is not a feasible solution due to cost and increased exposure to ionizing radiation. Additionally, it may take a few years for electromagnetic guidance to become more standard. Importantly, healthcare providers should be mindful of the potential risks when inserting Dobhoff tubes, and placement should at the very least be confirmed radiographically before use.

## Conclusions

Dobhoff feeding tubes are frequently placed by various healthcare providers to maintain enteral nutrition. Despite being perceived as a common and harmless procedure, feeding tube insertion is not without risk. Due to blind placement, Dobhoff tubes may be inadvertently positioned within the lung via the tracheobronchial tree, resulting in pneumothorax or hemothorax. This case report contributes to the literature by describing another rare instance of hemothorax from traumatic Dobhoff misplacement. Dobhoff placement should be confirmed radiographically in all cases. Additionally, the risk of misplacement may be mitigated by increased awareness of possible complications as well as the use of techniques for more accurate bedside guidance.

## Additional Information

### Disclosures

**Human subjects:** Consent was obtained by all participants in this study. **Conflicts of interest:** In compliance with the ICMJE uniform disclosure form, all authors declare the following: **Payment/services info:** All authors have declared that no financial support was received from any organization for the submitted work. **Financial relationships:** All authors have declared that they have no financial relationships at present or within the previous three years with any organizations that might have an interest in the submitted work. **Other relationships:** All authors have declared that there are no other relationships or activities that could appear to have influenced the submitted work.

## References

1. Metheny NA: Initial and ongoing verification of feeding tube placement in adults (applies to blind insertions and placements with an electromagnetic device). *Crit Care Nurse*. 2016, 36:8-13. [10.4037/ccn2016141](https://doi.org/10.4037/ccn2016141)
2. Metheny NA: Preventing respiratory complications of tube feedings: evidence based practice . *Am J Crit Care*. 2006, 15:360-369. [10.4037/ajcc2006.15.4.360](https://doi.org/10.4037/ajcc2006.15.4.360)
3. Krenitsky J: Blind bedside placement of feeding tubes: treatment or threat? . *Pract Gastroenterol*. 2011, 93:32-42.
4. Paul V, Shenoy A, Kupfer Y, Tessler S: Pneumothorax occurring after nasogastric tube removal . *BMJ Case Rep*. 2013, 2013:2013010419. [10.1136/bcr-2013-010419](https://doi.org/10.1136/bcr-2013-010419)
5. Amirlak B, Amirlak I, Awad Z, Zahmatkesh M, Pipinos I, Forse A: Pneumothorax following feeding tube placement: precaution and treatment. *Acta Med Iran*. 2012, 50:355-358.
6. Sparks DA, Chase DM, Coughlin LM, Perry E: Pulmonary complications of 9931 narrow-bore nasoenteric tubes during blind placement: a critical review. *JPEN J Parenter Enteral Nutr*. 2011, 35:625-629. [10.1177/0148607111413898](https://doi.org/10.1177/0148607111413898)
7. Abidali A, Mangram A, Shirah GR, Wilson W, Abidali A, Moeser P, Dzandu JK: Bilateral pneumothoraces in a trauma patient after Dobhoff tube placement. *Am J Case Rep*. 2018, 19:244-248. [10.12659/AJCR.906846](https://doi.org/10.12659/AJCR.906846)
8. Lim JY, Yong E, Aneez DBA, Tham CH: A simple procedure gone wrong: pneumothorax after inadvertent transbronchial nasogastric tube insertion necessitating operative management. *J Surg Case Rep*. 2019, 6:186. [10.1093/jscr/rjz186](https://doi.org/10.1093/jscr/rjz186)
9. Lee SW, Kim DH, Chang YR, Yun J, Choi S, Chang SW, Yun JH: A penetrating lung injury by a feeding tube . *Trauma Image Proced*. 2018, 5:50-52. [10.24184/tip.2018.3.2.50](https://doi.org/10.24184/tip.2018.3.2.50)
10. Attar MN, Al-Najjar Y, Tewari S, et al.: Haemopneumothorax - a rare complication of a common procedure . *Case Rep Clin Pract Rev*. 2006, 7:111-113.
11. Rassias AJ, Ball PA, Corwin HL: A prospective study of tracheopulmonary complications associated with the placement of narrow-bore enteral feeding tubes. *Crit Care*. 1998, 2:25-28. [10.1186/cc120](https://doi.org/10.1186/cc120)
12. Sorokin R, Gottlieb JE: Enhancing patient safety during feeding-tube insertion: a review of more than 2000 insertions. *JPEN J Parenter Enteral Nutr*. 2006, 30:440-445. [10.1177/0148607106030005440](https://doi.org/10.1177/0148607106030005440)
13. Metheny NA, Meert KL: Effectiveness of an electromagnetic feeding tube placement device in detecting inadvertent respiratory placement. *Am J Crit Care*. 2014, 23:240-247. [10.4037/ajcc2014954](https://doi.org/10.4037/ajcc2014954)
14. Bear DE, Champion A, Lei K, Camporota L, Barrett NA: Electromagnetically guided bedside placement of post-pyloric feeding tubes in critical care. *Br J Nurs*. 2017, 26:1008-1015. [10.12968/bjon.2017.26.18.1008](https://doi.org/10.12968/bjon.2017.26.18.1008)