



Contents lists available at ScienceDirect

Indian Pacing and Electrophysiology Journal

journal homepage: www.elsevier.com/locate/IPEJ

Unipolar and bipolar electrogram characteristics of recurrent cases of idiopathic ventricular arrhythmias undergoing repeat catheter ablation

Anupam Jena^a, Mohammad Iqbal^b, Yong-Soo Baek^b, Kwang- No Lee^b,
Seung- Young Rho^b, Jae Min Shim^b, Joing Il Choi^b, Young-Hoon Kim^{b,*}

^a Kalinga Institute of Medical Sciences, Republic of Korea

^b Korea University Medical Center, Seoul, Republic of Korea

ARTICLE INFO

Article history:

Received 12 September 2021

Received in revised form

2 November 2021

Accepted 18 November 2021

Available online 22 November 2021

Keywords:

Catheter ablation

Ventricular arrhythmia

Premature ventricular contractions

Radiofrequency ablation

Unipolar electrogram

Bipolar electrograms

ABSTRACT

Introduction: Activation mapping guided catheter ablation (CA) of ventricular arrhythmias (VAs) is limited in some cases when it is only relied on bipolar electrogram (EGM). We hypothesized that activation mapping with use of combined bipolar and unipolar EGM facilitates to identify the focal origin of VAs and results in reduction of recurrence rate of CA of VAs.

Methods: We analyzed the data of patients undergoing repeat ablations for idiopathic out-flow tract VAs. The EGM of the 1st and 2nd ablations were compared for earliest local activation time (LAT), presence of discrete potentials, and polarity reversal, unipolar potential morphology (QS or non-QS), potential amplitude and activation slope.

Results: Thirty-seven patients were included. The Local activation time was significantly earlier in the 2nd ablation as compared to the 1st procedure (36.90 msec vs 31.85 msec, $P < 0.01$). The incidence of discrete potentials and polarity reversal were similar in both procedures (51% vs 57%, $P = 0.8$ and 62% in both the occasions, respectively). The unipolar voltage was similar in both occasions (6.94 mV vs 7.22 mV in repeat ablations, $P = 0.7$). The recurrence rate (5.7%) was significantly lower with routine use of combined unipolar and bipolar EGMs, as compared to the use of bipolar EGM alone (16.7%).

Conclusions: Use of both bipolar and unipolar electrograms helps in better delineation of the sites of earliest activation for effective ablation of VAs. Use of unipolar electrograms in addition to bipolar electrograms is associated with lower long term recurrence rate.

© 2022 Indian Heart Rhythm Society. Published by Elsevier B.V. This is an open access article under the CC BY-NC-ND license (<http://creativecommons.org/licenses/by-nc-nd/4.0/>).

1. Introduction

Ventricular arrhythmias (VAs) in the absence of structural heart disease are a common entity. Patients presenting with idiopathic VA account for 10% of those referred for evaluation and treatment of VA, and greater than 70%–80% of idiopathic VA originate from the ventricular outflow tracts [1]. Although idiopathic outflow tract VAs (OTVA) are generally considered benign, they can cause severe

symptoms and may be associated with VA-induced cardiomyopathy [1]. Radiofrequency catheter ablation (RFCA) is highly effective with procedural success rates greater than 80% [1–4]. Recurrence after RFCA is seen in 5–30% of cases of idiopathic OTVAs [5,6].

The objective of the study was to assess whether the bipolar and unipolar electrogram (EGM) characteristics reveal the reasons for failure of the first attempted RFCA in patients with idiopathic OTVAs. We hypothesized that activation mapping with combined use of bipolar and unipolar EGM may facilitate to identify successful ablation sites in redo cases of idiopathic OTVAs.

2. Methods

This was a single center retrospective study done at Korea University Anam Hospital. The inclusion criteria were as follows: Patients presenting with symptoms suggestive of cardiac

* Corresponding author. Division of Cardiology, Department of Internal Medicine, Korea University College of Medicine, School of Medicine, Korea University Medical Center, Anam hospital, 73, Incheon-ro, Seongbuk-gu, Seoul, 136-705, Republic of Korea.

E-mail addresses: yhkmd@korea.ac.kr, yhkmd@unitel.co.kr (Y.-H. Kim).

URL: <http://www.korea-heartrhythm.com>

Peer review under responsibility of Indian Heart Rhythm Society.

arrhythmias such as palpitation, dizziness, presyncope etc. and Idiopathic outflow tract VAs, premature ventricular contraction (PVC) or ventricular tachycardia (VT), patients undergoing redo ablations due to recurrent VAs, and structurally normal heart. The presence of structural heart disease was evaluated by 12 lead ECG and echocardiogram in all cases. Exercise stress testing, cardiac catheterization, and/or cardiac magnetic resonance imaging (MRI) were done when indicated. Exclusion criteria were any evidence of structural heart disease, initial ablation done at other centers, and non – OTVAs. We analyzed data of a total of 500 patients who underwent RFCA for VAs, out of which 393 patients were cases of idiopathic OT PVC/VT. Redo ablations were done in 56 patients, out of which 37 cases satisfied the inclusion criteria and were included in final analysis.

3. Electrophysiological testing and catheter ablation

Catheters were placed through a right femoral vein approach. A quadripolar electrode catheter was inserted in the right ventricle and used for electrical programmed stimulation. Two SL1 sheaths were placed in the RVOT for mapping and ablation. If no spontaneous VA occurred, electrical programmed stimulation was performed before and after intravenous isoproterenol (2–10 µg/min) infusion, if necessary. The electrical programmed stimulation protocol consisted of three drive cycle lengths (600, 500, and 400 ms) with up to three ventricular extra stimuli.

Conventional 4 mm ablation catheters were used in majority of the cases and irrigated-tip catheters were used in 11 patients. Bipolar EGMs recorded from the distal (1–2) and proximal (3–4) electrode pair of the mapping catheter (filtered at 30–500 Hz), the unipolar EGM recorded from the distal electrode (filtered at 0.05–500 Hz), and the 12-lead surface ECG were displayed simultaneously and stored on an electrophysiologic recording system.

Target sites for RFCA were selected based on (1) Local activation time (LAT), (2) presence of a unipolar QS configuration, (3) presence of reversed polarity and (4) presence of discrete potentials preceding ventricular EGM during VA. LAT was measured from the bipolar EGM recorded from the distal electrode pair of the mapping catheter and was defined as the interval between the initial sharp peak of the EGM and the onset of the QRS of VA. The presence of reversed polarity was evaluated from the bipolar EGMs recorded from the distal (1 & 2) and proximal (3 & 4) electrode pairs of the mapping catheter and was defined as a rapid simultaneous deflection in the opposite direction of the initial part of the bipolar EGMs occurring before the onset of the QRS of VA. To record reversed polarity, the mapping catheter was positioned parallel or in a shallow angle to the endocardial surface. RF energy was applied at 50 W with a maximum temperature of 60 °C. If the VA was abolished within 20 seconds, the energy application was continued for 60 seconds. If the VA was not abolished within 20 seconds, the energy application was terminated, and further mapping was continued. The procedural endpoint was reached when the targeted VA did not occur spontaneously after a waiting period of 30 minutes after the last application and could not be induced by electrical programmed stimulation before and after isoproterenol infusion.

4. EGM analysis

The EGM characteristics at successful ablation sites were analyzed. Unipolar EGMs at the ablation attempted sites were assessed for EGM morphology, potential amplitude, activation slope, and the interval between rapid negative deflection and onset of QRS. Unipolar activation slope was defined as the ratio of voltage and time interval from onset of QS to the nadir of S wave. These

EGM characteristics were compared for ablation target sites during first and repeat ablation procedures. Unipolar QS morphology was further evaluated for QS morphology with a rapid negative deflection and QS morphology with an initial slow negative deflection followed by rapid negative deflection (Fig. 1).

5. Statistical analysis

Statistical analysis was performed using SPSS (version 22.0, SPSS Inc., Chicago, IL, USA). $P < 0.05$ was considered significant. Continuous variables are expressed as mean \pm SD and were compared using the paired Student's t-test. Categorical variables are expressed as number (%) and were analyzed using the Chi-square test.

6. Results

This study included 37 patients (43% females, mean age 38.7 ± 12.5 years). Mean left ventricular ejection fraction (LVEF) was $58 \pm 6\%$. Fifty-four percent ($n = 20$) presented with sustained or nonsustained VT and 46% ($n = 17$) presented with frequent PVCs. During the first ablation procedure, the successful ablation sites were in RVOT ($n = 24$, 65%) and in LVOT ($n = 13$, 35%). In redo ablation procedures the sites of successful ablation were in RVOT in 57% ($n = 21$) and LVOT in 43% ($n = 16$). 3D electroanatomical mapping (EAM) was used in 21 cases (15 cases in Ensite NavX™ and 6 cases with CARTO™). Successful ablation sites in RVOT: 15 septal, 4 free wall and 2 from pulmonary artery. Successful ablation sites in LVOT: 8 septal, 4 LCC, 1 RCC, 2 LCC-RCC junction, 1 AMC.

The EGM characteristics of 1st and 2nd ablations are shown in Table 1. The LAT on bipolar EGM was significantly earlier in 2nd ablation procedure compared to the first ablation ($p = 0.01$). The unipolar EGM was more frequently used in 2nd (16/37, 43.2%) than in 1st ablation (9/37, 24.3%, $p < 0.05$). Successful ablation sites showed QS morphology with rapid negative deflection on unipolar EGM in first and 2nd ablations (Fig. 2). No comparison was done for fluoroscopic guided mapping vs 3D EAM. In 3 redo cases, successful ablation was achieved at sites showing a slow-rapid QS pattern on unipolar EGM (initial slow negative deflection followed by rapid negative deflection (Fig. 1), and rapid negative deflection was earlier than onset of QRS as shown in Figs. 1–3. As shown in Fig. 2, the LAT on bipolar EGM was similar between unsuccessful and successful site, but in unipolar EGM, tiny r wave and rapid negative deflection was noted after onset of QRS, which was one of the characteristic EGMs in unsuccessful site. Fig. 3 showed one representative example showing the importance of unipolar EGM, not only QS morphology, but also the timing of rapid negative deflection prior to onset of QRS, especially in whom a discrete potential was noted preceding QRS on bipolar EGM. Acute procedural success was achieved in all patients and there were no procedure related complications. In the cohort of idiopathic OTVAs, the redo ablation rate (16 out of 205 patients, 7.8%) was significantly lower with routine use of combined unipolar and bipolar EGMs, as compared to the use of bipolar EGM alone (40 out of 188 patients, 21.2%) ($P < 0.05$). The number of 3rd ablations was also lower with the use of both unipolar and bipolar EGMs as compared to bipolar EGM alone (6.2% vs 23.8%, $P = 0.15$).

7. Discussion

7.1. Main findings

In patients undergoing redo catheter ablations for idiopathic OTVAs, QS morphology and rapid negative deflection prior to onset of QRS on unipolar EGM facilitate identification of early activation

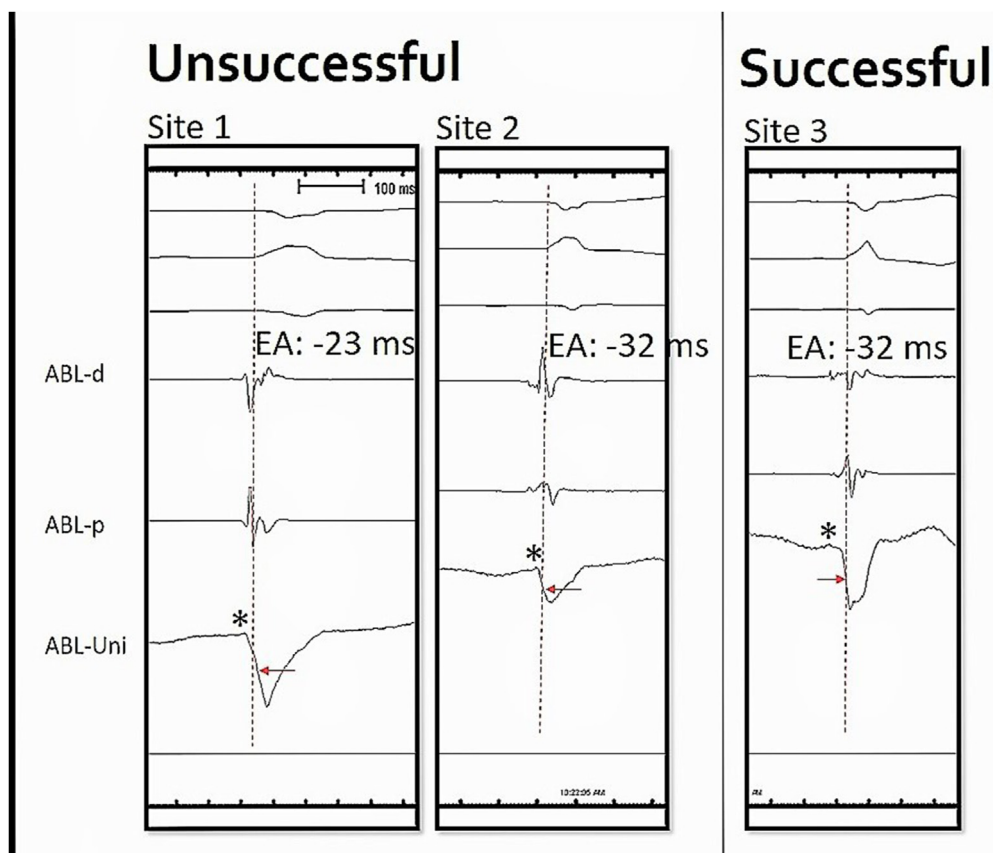


Fig. 1. Electrogram (EGM) characteristics at unsuccessful and successful sites. In site 1, the earliest activation (EA) of bipolar electrograms (ABLd and ABLp) was 23 msec before QRS onset and there was polarity reversal. Unipolar EGM contained a small r wave before QS and rapid negative deflection was noted after onset of QRS. Ablation was unsuccessful. Site 2, EA = 32 msec and a discrete potential was noted at bipolar EGM, but unipolar EGM contained a small r and rapid negative deflection was almost the same time of QRS onset. Ablation was unsuccessful. Site 3, successful ablation site, EA = 32 msec and a discrete potential and polarity reversal were noted at bipolar EGMs, and unipolar EGM showing initial slow QS complex and rapid negative deflection was slightly earlier than onset of QRS. (Dotted line indicates beginning of QRS complex, asterisk indicates beginning of unipolar EGM, red arrow indicates rapid negative deflection).

Table 1
The Electrogram Characteristics of 1st and 2nd Ablations.

| Measurement | 1st Ablation | 2nd Ablation | P value |
|-------------------------------------|--------------|--------------|---------|
| LAT* | 31.8 msec | 36.5 msec | 0.01 |
| Presence of discrete potentials | 51% | 57% | 0.8 |
| Presence of polarity reversal | 62% | 62% | 1 |
| Unipolar voltage (mV) | 6.94 | 7.22 | 0.7 |
| Unipolar activation slope (mV/msec) | 0.156 | 0.171 | 0.2 |

(*LAT – Local activation time).

sites and improves success of CA. Bipolar EGM characteristics like polarity reversal and presence of discrete potentials have no additive efficacy in redo CA cases. A slow-rapid initial QS morphology with its earlier timing to QRS onset may improve the success of CA in idiopathic OTVAs.

Catheter ablation remains the most important therapeutic option to eliminate OT-VAs [6]. Previous studies of CA in idiopathic outflow tract VA have reported acute success rates of 84%–100% [1]. [[2,5] Long term recurrence rates have been reported to be ≤ 30% [5,6]. The reasons underlying ablation failure are multifactorial and include lack of accurate localization because of minimal ectopy available to map [7], safety concerns with ablation at the target site(s) [8,9], recurrence of different VAs [5], and inability to access critical sites for mapping or ablation [8,10–12]. Wen et al. found

endocardial activation time at the successful ablation site as the only independent predictor of tachycardia recurrences after RFCA of idiopathic VA [13]. A delta wave-like onset of the QRS complex during VA has also been reported to be associated with unsuccessful catheter ablation, suggesting that a slow onset of the QRS complex may indicate an intramural or epicardial origin of the ventricular tachycardia [14]. Our study specifically analyzed the EGM characteristics in 1st and 2nd CAs and we tried to find any significant differences in EGM features. We found a significantly earlier LAT during 2nd ablation as compared to 1st ablation. This difference was due to higher use of unipolar EGM in 2nd (43.2%) than in 1st ablations (24.3%). The unipolar QS morphology aided in finding an earlier LAT.

The presence of reversed polarity has been shown to have a high predictive value for successful ablation sites in focal idiopathic RVOT arrhythmias [15]. In our study we did not find significant difference in the incidence of polarity reversal between 1st and 2nd ablations.

Discrete potentials are not uncommon in idiopathic OTVAs. Discrete potential- and substrate-guided ablation strategy has been proposed to reduce the recurrence of idiopathic OTVAs [16]. However, 70% of cases still had a discrete potentials even after elimination of VAs [16]. In our study, there was no significant difference in the incidence of discrete potentials in 1st and 2nd ablations.

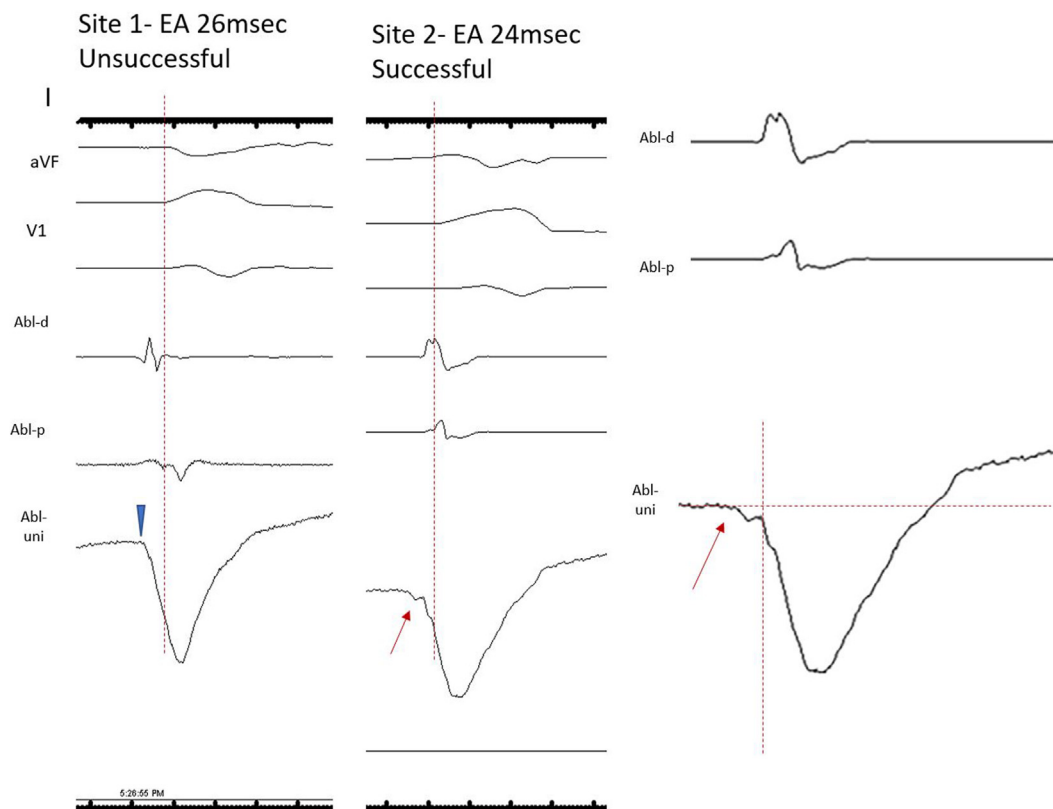


Fig. 2. Site (left panel) of unsuccessful ablation at right ventricular outflow tract (RVOT) shows the earliest activation (EA) 26 msec before QRS onset on bipolar electrogram (ABL-d and ABL-p) and in unipolar electrogram (ABL-Uni), tiny r wave (arrow head) and rapid negative deflection (activation slope 0.161 mV/ms) was noted after onset of QRS. Site of successful ablation at RVOT shows the EA 24 ms before QRS onset on bipolar electrogram, however, unipolar QS morphology (ABL-Uni) with initial slow negative deflection (red arrow) followed by rapid negative deflection (slope of initial deflection = 0.036 mV/ms, slope of rapid deflection = 0.158), which was prior to onset of QRS (indicated by a red arrow). A right panel is 1.5 times of zoom in figure of successful RVOT.

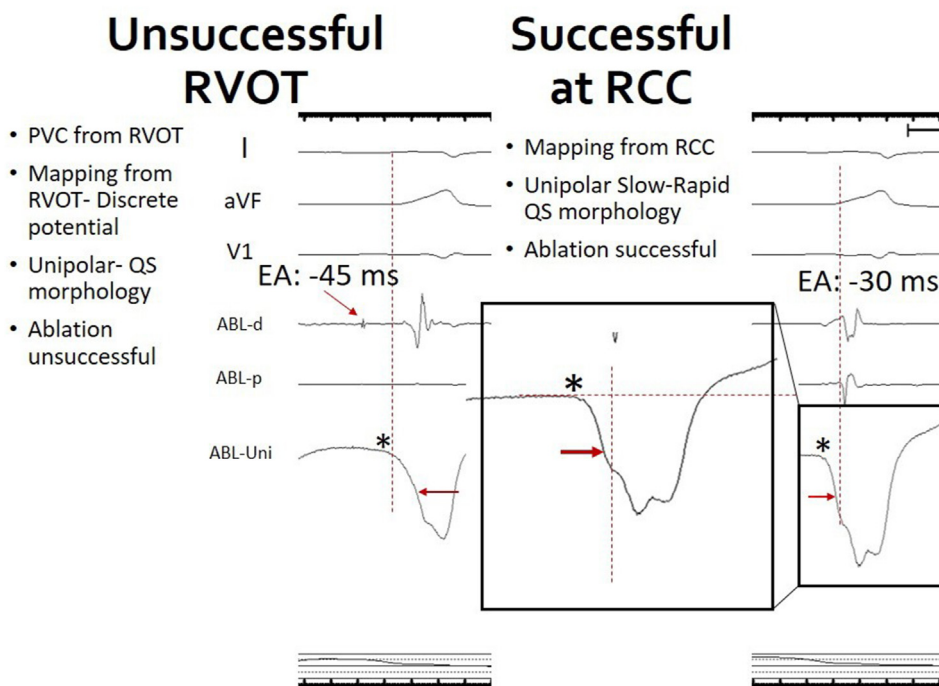


Fig. 3. Site (left panel) of unsuccessful ablation at right ventricular outflow tract (RVOT) shows the earliest activation (EA) 45 ms of a discrete potential before QRS onset on bipolar electrogram (ABL-d and ABL-p) and in unipolar electrogram (ABL-Uni), QS morphology (an asterisk) and rapid negative deflection was noted much later than onset of QRS (indicated by a red arrow). Site of successful ablation at RCC (right coronary cusp) shows the EA 30 ms before QRS onset on bipolar electrogram and initial slow negative deflection (an asterisk) followed by rapid negative deflection prior to onset of QRS (indicated by a red arrow) on unipolar electrogram. A middle is 1.5 times of zoom in figure of electrogram at successful RCC (right panel).

7.2. Unipolar QS morphology

The morphology of the unipolar recording indicates the direction of wave front propagation. The usefulness of unipolar QS morphology has been reported by Soejima et al. An optimum QS complex in unipolar EGM has been defined as: a QS-pattern unipolar electrogram as one that ought to accompany sufficient amplitudes of local bipolar and unipolar electrograms and ST elevation, and the initial deflection of the unipolar electrogram must be very steep (high dV/dt). A false positive QS-pattern is commonly observed when catheter contact is insufficient, or far-field recording occurs. In the former, ST elevation is always non-discernible or insufficient, and in the latter, initial dV/dt is quite low. In the series of 27 patients, the sensitivity and specificity of unipolar QS-pattern to determine the optimum ablation target sites were 1.0 and 0.89 in RVOT VT and 0.86 and 0.83 in LVOT VT, respectively [17]. Our findings are also in agreement with the above study and searching of earlier bipolar EGM can be guided by characteristic unipolar EGMs. However, the size of the area showing a QS complex was larger than the focus, exceeding a centimeter or more in diameter which compromises its specificity. In epicardial and mid myocardial PVCs getting an optimal unipolar EGM with QS is nearly impossible. In such cases the slow-rapid QS helps in identifying ablation target areas. The successful site of ablation in the region of mid myocardial and epicardial often needs to be mapped by GCV/AIV catheters. Sometimes sites adjacent to best activation timing despite being not correlating unipolar and bipolar signals may be successful [19].

In 3 redo cases, the successful ablation sites showed an initial slow followed by a rapid deflection and earlier timing of rapid negative deflection to QRS onset in unipolar EGM (Fig. 3). This slow-rapid QS, along with its timing relationship of QRS onset in unipolar EGMs hasn't been reported previously. We hypothesize that this characteristic unipolar EGM may be due to (1) presence of deeper subendocardial foci of VA, (2) anisotropic conduction or (3) preferential conduction of deeply seated focus. Smaller QS slope on unipolar EGMs predict deeper foci and thereby difficult ablation, as shown by Okumura et al. [18] Therefore a careful search for a slow-rapid QS morphology on unipolar EGM can identify subendocardial sites or sites with conduction disturbances and difficult ablation sites which may be related to recurrence after catheter ablation, for example, a muscular extension from pulmonary artery or nearby coronary cusps through preferential conducting pathway.

8. Conclusion

The combined use of unipolar and bipolar EGM characteristics predicts a high acute procedural success and reduces the number of recurrences and repeated ablation procedures. Unipolar initial morphology and timing of rapid negative deflection to QRS onset are key to identify the successful ablation site in cases of idiopathic OTVA.

Financial Support

None.

Declaration of competing interest

None.

References

- [1] Aliot EM, Stevenson WG, Almendral-Garrote JM, et al. EHRA/HRS expert consensus on catheter ablation of ventricular arrhythmias: developed in a partnership with the European Heart Rhythm Association (EHRA), a registered branch of the European Society of Cardiology (ESC), and the Heart Rhythm Society (HRS); in collaboration with the American College of Cardiology (ACC) and the American Heart Association (AHA). *Heart Rhythm* 2009;6:886–933.
- [2] Borger van der Burg AE, de Groot NM, van Erven L, Bootsma M, van der Wall EE, Schalij MJ. Long-term follow-up after radiofrequency catheter ablation of ventricular tachycardia: a successful approach? *J Cardiovasc Electro-physiol* 2002;13:417–23.
- [3] Calkins H, Kalbfleisch SJ, el-Atassi R, Langberg JJ, Morady F. Relation between efficacy of radiofrequency catheter ablation and site of origin of idiopathic ventricular tachycardia. *Am J Cardiol* 1993;71:827–33.
- [4] Chinushi M, Aizawa Y, Takahashi K, Kitazawa H, Shibata A. Radiofrequency catheter ablation for idiopathic right ventricular tachycardia with special reference to morphological variation and long-term outcome. *Heart* 1997;78: 255–61.
- [5] Latchamsetty R, Yokokawa M, Morady F, et al. Multicenter outcomes for catheter ablation of idiopathic premature ventricular complexes. *J Am Coll Cardiol EP* 2015;1:116–23.
- [6] Ling Z, Liu Z, Su L, et al. Radiofrequency ablation versus antiarrhythmic medication for treatment of ventricular premature beats from the right ventricular outflow tract: prospective randomized study. *Circ Arrhythm Electrophysiol* 2014;7:237–43.
- [7] Choi EK, Kumar S, Nagashima K, et al. Better outcome of ablation for sustained outflow-tract ventricular tachycardia when tachycardia is inducible. *Europace* 2015;17:1571–9.
- [8] Santangeli P, Marchlinski FE, Zado ES, et al. Percutaneous epicardial ablation of ventricular arrhythmias arising from the left ventricular summit: outcomes and electrocardiogram correlates of success. *Circ Arrhythm Electrophysiol* 2015;12:1145–53.
- [9] Mountantonakis SE, Frankel DS, Tschabrunn CM, et al. Ventricular arrhythmias from the coronary venous system: prevalence, mapping, and ablation. *Heart Rhythm* 2015;12:1145–53.
- [10] Yamada T, Doppalapudi H, Maddox WR, McElderry HT, Plumb VJ, Kay GN. Prevalence and electrocardiographic and electrophysiological characteristics of idiopathic ventricular arrhythmias originating from intramural foci in the left ventricular outflow tract. *Circ Arrhythm Electrophysiol* 2016;9:e004079.
- [11] Yokokawa M, Good E, Chugh A, et al. Intramural idiopathic ventricular arrhythmias originating in the intraventricular septum: mapping and ablation. *Circ Arrhythm Electrophysiol* 2012;5:258–63.
- [12] Yokokawa M, Morady F, Bogun F. Injection of cold saline for diagnosis of intramural ventricular arrhythmias. *Heart Rhythm* 2016;13:78–82.
- [13] Wen MS, Taniguchi Y, Yeh SJ, Wang CC, Lin FC, Wu D. Determinants of tachycardia recurrences after radiofrequency ablation of idiopathic ventricular tachycardia. *Am J Cardiol* 1998;81:500–3.
- [14] Rodriguez LM, Smeets JL, Timmermans C, Wellens HJ. Predictors for successful ablation of right- and left-sided idiopathic ventricular tachycardia. *Am J Cardiol* 1997;79:309–14.
- [15] van Huls van Taxis CF, Wijnmaalen AP, den Uijl DW, et al. Reversed polarity of bipolar EGMs for predicting a successful ablation site in focal idiopathic right ventricular outflow tract arrhythmias. *Heart Rhythm* 2011;8:665–71.
- [16] Liu E, Xu G, Liu T, et al. Discrete potentials guided radiofrequency ablation for idiopathic outflow tract ventricular arrhythmias. *Europace* 2015;17:453–60.
- [17] Soejima Y, Aonuma K, Iesaka Y, Isobe M. Ventricular unipolar potential in radiofrequency catheter ablation of idiopathic non-reentrant ventricular outflow tachycardia. *Jpn Heart J* 2004;45:749–60.
- [18] Okumura Y, Watanabe I, Nakai T, et al. A quantitative and qualitative analysis of the virtual unipolar EGMs from non-contact mapping of right or left-sided outflow tract premature ventricular contractions/ventricular tachycardia origins. *J Intervent Card Electrophysiol* 2011;30:17–25.
- [19] Cronin Edmond M, Bogun Frank M, Peichl Petr, et al. HRS/EHRA/APHS/LAHS expert consensus statement on catheter ablation of ventricular arrhythmias. *Heart Rhythm* 2019;17:e2–154. 2019.