



Case report

Suprachoroidal hemorrhage during femtosecond laser assisted cataract surgery



Tahir Kansu Bozkurt, Kevin M. Miller*

Department of Ophthalmology, David Geffen School of Medicine at UCLA and the Stein Eye Institute, Los Angeles, CA, USA

ARTICLE INFO

Article history:

Received 16 April 2016

Received in revised form

21 August 2016

Accepted 29 August 2016

Available online 31 August 2016

Keywords:

Femtosecond laser assisted cataract surgery

FLACS

Suprachoroidal hemorrhage

Docking

Patient interface

ABSTRACT

Purpose: To describe a case of suprachoroidal hemorrhage that occurred during femtosecond laser assisted cataract surgery (FLACS).

Observations: A 67-year-old woman with high myopia underwent FLACS. Following two unsuccessful attempts at docking due to interface air bubbles, the third attempt was successful. Laser treatment and cataract surgery proceeded uneventfully until intraocular lens (IOL) implantation. While positioning the IOL within the capsular bag, the anterior chamber began to shallow, intraocular pressure became high by palpation, and the optic of the IOL prolapsed partially out of the bag. A segmental suprachoroidal hemorrhage was identified in the superior peripheral retina by intraoperative indirect ophthalmoscopy. Following an hour of waiting in the recovery room, the anterior chamber deepened and the intraocular pressure was low enough to position the IOL centrally within the bag. Her subsequent postoperative course was uneventful.

Conclusions and Importance: To our knowledge, this is the first report of suprachoroidal hemorrhage during FLACS. We speculate that repeated sudden drops in intraocular pressure associated with multiple undockings triggered the suprachoroidal hemorrhage in this case.

© 2016 The Authors. Published by Elsevier Inc. This is an open access article under the CC BY-NC-ND license (<http://creativecommons.org/licenses/by-nc-nd/4.0/>).

1. Introduction

Suprachoroidal hemorrhage (SCH) is a major complication of intraocular surgery including cataract surgery.¹ To the best of our knowledge, SCH has not been reported during femtosecond laser assisted cataract surgery (FLACS). Herein, we present a patient with no high-risk characteristics other than high myopia who developed a SCH at the time of cataract surgery following three femtosecond laser docking attempts, the first two of which were unsuccessful due to air bubbles in the interface.

2. Case report

A 67-year old woman with high myopia underwent FLACS with multifocal posterior chamber intraocular lens (IOL) implantation in her left eye due to a 3 + nuclear sclerotic cataract. She underwent uneventful right eye cataract surgery many years earlier without femtosecond laser assistance. Preoperatively, the corrected

distance corrected visual acuity of her left eye was 20/50 with a refractive error of $-18.50 + 0.75 \times 015$. Axial length was 27.57 mm as measured by an optical biometer (IOLMaster, Carl Zeiss Meditec AG, Jena, Germany).

Under topical anesthesia, the patient was positioned beneath a femtosecond laser (LenSx, Alcon Laboratories, Inc., Ft. Worth, TX). The first two attempts at docking were unsuccessful due to air bubbles in the interface. The third attempt was successful. Software was programmed to produce a main incision, paracentesis, capsulorrhexis, and lens fragmentation pattern. Docking time was under 2 minutes. Laser treatment and phacoemulsification proceeded in standard fashion until IOL implantation.

A single-piece multifocal intraocular lens was implanted to match the style of IOL in her right eye. It was a 10.0 D model SN6AD3 with a 4.0 D add (Alcon Laboratories). While positioning the IOL within the capsular bag, the anterior chamber began to shallow progressively over the next 2 minutes. The subincisional iris rose up to the main incision, without prolapsing, and the optic of the IOL prolapsed partially out of the capsular bag. Eventually the IOL was pressed against the cornea because of high vitreous pressure. Intraocular pressure (IOP) appeared to be high by tactile estimation. She began to experience mild discomfort. There was no

* Corresponding author. Kolokotronis Chair in Ophthalmology, Stein Eye Institute, 300 Stein Plaza, 2nd Floor, UCLA, Los Angeles, CA, 90095-7000, USA.

E-mail address: miller@jsei.ucla.edu (K.M. Miller).

external pressure on the eye from the lid speculum and she was not holding her breath or performing a valsalva maneuver. After several unsuccessful attempts at deepening the anterior chamber and positioning the IOL, a 10-0 nylon suture was placed to secure the primary incision and the paracentesis was hydrated.

Intraoperative indirect ophthalmoscopy revealed a 1.5-clock-hour wedge-shaped SCH in the superior fundus that extended from the peripheral retina to just posterior to the equator. It was estimated to be 3–5 mm in height centrally. The complication was explained to the patient and surgery was terminated. She was transferred to the recovery room with the expectation that she would be reevaluated in an hour.

She had not been taking any antiplatelet or anticoagulant medications preoperatively. The length of time between opening the incisions and shallowing of the anterior chamber was about 15 minutes.

After an hour, she was brought back to the operating room. Her anterior chamber was deeper and IOP by tactile estimation was lower. The optic of the IOL was placed fully inside and centered within the capsular bag using a balanced salt solution cannula inserted through the paracentesis.

On postoperative day 1, her uncorrected distance visual acuity was 20/25 and her uncorrected near visual acuity was J1. IOP was 18 mmHg. Repeat fundus examination revealed a SCH from 11 to 12:30 o'clock, extending just posterior to the equator. Fig. 1 shows the appearance of the resolving SCH at the 2-week postoperative examination, at which time it was much flatter.

3. Discussion

Risk factors for the development of SCH include ocular hypertension or glaucoma, system hypertension, high myopia, intraoperative valsalva, and prolonged ocular hypotony.¹ Most risk factors for SCH are associated with increased choroidal vascular pressure that is unopposed by intraocular pressure. Choroidal hemorrhages were more common in the era of extracapsular cataract extraction than they are in the era of small incision phacoemulsification.

Although high axial myopia is an established risk factor for SCH,^{2,3} we hypothesize that repeated attempts at achieving a bubble-free dock with the patient's eye may have played a role in

this particular case. More specifically, repeated undocking from the femtosecond laser caused several rapid depressurizations of the eye from the supra-physiologic to the physiologic range, one of which may have caused a small rupture in a choroidal vessel and the subsequent hemorrhage. Given the length of time it took for the hemorrhage to shallow the anterior chamber after incision opening, we surmise it was venous and not arterial. This is all speculative, of course. One wonders, however, why a SCH would develop during an otherwise uneventful surgery.

There are two reports of macular hemorrhage following laser in situ keratomileusis (LASIK). The two cases in the first report were associated with pre-existing macular pathology.⁴ One eye had a choroidal neovascular membrane and the other had lacquer cracks. A mechanical microkeratome was used to make the flap in these two eyes. The single case in the second report had no pre-existing macular pathology. A femtosecond laser was used to make the flap.⁵ Clearly the incidence of choroidal hemorrhage associated with the use of docking devices in LASIK is rare.

In FLACS, successful docking is a necessary step of the procedure. Any bubbles trapped in the patient interface can cause surgical difficulty if they are located over areas that will be treated. To ignore them might result in skip areas in the capsulorrhexis or difficulty opening corneal incisions. Unfortunately, one is forced to undock, rewet the cornea, and try again if air bubbles cannot be moved away from treatment areas by manipulating the interface under suction. As such, there is no way to prevent this complication short of not performing FLACS, if indeed there is a relationship between undocking and SCH.

4. Conclusion

This case report demonstrates that SCH can occur during FLACS. We think ophthalmologists should keep in mind this possibility after repeated docking attempts, even in eyes without other obvious risk factors. It is possible that small, subclinical hemorrhages are more common following FLACS than we are aware, especially after repeated docking attempts.

5. Patient consent

Consent to publish this report was obtained in writing.

Conflicts of interest

Dr. Miller is a consultant and investigator for Alcon Laboratories and a consultant for Abbott Medical Optics. Dr. Bozkurt has no financial disclosures.

References

- Ling R, Kamalarajah S, Cole M, James C, Shaw S. Suprachoroidal haemorrhage complicating cataract surgery in the UK: a case control study of risk factors. *Br J Ophthalmol*. 2004;88:474–477.
- Tabandeh H, Sullivan PM, Smaliuk P, Flynn Jr HW, Schiffman J. Suprachoroidal hemorrhage during pars plana vitrectomy. Risk factors and outcomes. *Ophthalmology*. 1999;106:236–242.
- Chu TG, Green RL. Suprachoroidal hemorrhage. *Surv Ophthalmol*. 1999;43:471–486.
- Ellies P, Pietrini D, Lumbroso L, Lebuissou D. Macular hemorrhage after laser in situ keratomileusis for high myopia. *J Cataract Refract Surg*. 2000;26:922–924.
- Principe A, Lin D, Small K, Aldave A. Macular hemorrhage after laser in situ keratomileusis (LASIK) with femtosecond laser flap creation. *Am J Ophthalmol*. 2004;138:657–659.

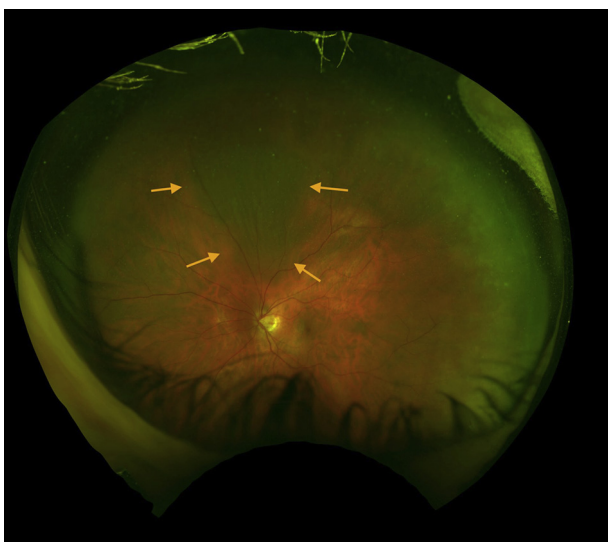


Fig. 1. Appearance of a resolving suprachoroidal hemorrhage in the left eye of a 67-year-old woman two weeks after femtosecond laser assisted cataract surgery.