



Original Article

# Morphometric parameters of the odontoid process of C2 vertebrae, in Indian population, a CT evaluation

Shankar Acharya<sup>1</sup>, Manoj Kumar<sup>1</sup>, Jay Deep Ghosh<sup>2</sup>, Nitin Adsul<sup>1</sup>, R. S. Chahal<sup>1</sup>, K. L. Kalra<sup>1</sup>

<sup>1</sup>Department of Ortho-Spine Surgery, Sir Ganga Ram Hospital, New Delhi, <sup>2</sup>Department of Spine Surgery, Apollo Hospital, Guwahati, Assam, India.

E-mail: Shankar Acharya - spineshankar@gmail.com; Manoj Kumar - drmanojkumar25@gmail.com; Jay Deep Ghosh - jaydeepxp@gmail.com;

\*Nitin Adsul - no1.nitinadsul@gmail.com; R. S. Chahal - rupinder72@hotmail.com; K. L. Kalra - kashkalra55@hotmail.com



**\*Corresponding author:**

Nitin Adsul,  
Department of Ortho-Spine  
Surgery, Sir Ganga Ram  
Hospital, New Delhi, India.

no1.nitinadsul@gmail.com

Received : 26 April 2021  
Accepted : 30 August 2021  
Published : 30 September 2021

DOI  
10.25259/SNI\_417\_2021

Quick Response Code:



## ABSTRACT

**Background:** Osteosynthesis of odontoid fractures, especially for type II odontoid fractures, is often achieved by the placement of screws. Here, utilizing CT, we evaluated the normal anatomy of the odontoid process in an Indian population to determine whether one or two screws could be anatomically accommodated to achieve fixation.

**Methods:** CT-based morphometric parameters of the odontoid process were assessed in 200 normal Indian patients (2018–2020).

**Results:** Of 200 patients, 127 were male, and 73 were female. The mean minimum external transverse diameter (METD) was 8.80 mm (range 6.1–11.9 mm). Six (3%) patients had a minimum internal transverse diameter (TD) of >8.0 mm that would allow for the insertion of two 3.5-mm cortical screws without tapping, while 10 (5%) patients had TDs of <7.4 mm; none had diameters of <5.5 mm. The mean length of the implant was 36.45 mm in females and 36.89 mm in males, and the mean angle of screw insertion was 60.34° in females and 60.53° in males.

**Conclusion:** About two-thirds (59%) of the 200 subjects in our study had a METD of <9 mm, indicating the impracticality for introducing second screws for odontoid fixation.

**Keywords:** Indian odontoid, Normal morphometric dimensions, Screw fixation of odontoid

## INTRODUCTION

The accurate radiological evaluation and assessment of the morphometric parameters of the odontoid are critical in achieving stable fixation and fusion of odontoid fractures.<sup>[1]</sup> Fractures of the odontoid process account for 50–60% of all fractures of C2, 7–27% of all cervical vertebral column fractures and 1–2% of all vertebral column fractures.<sup>[6]</sup> The technique of internal fixation of the odontoid process is directly related to the dimensions of the odontoid process.<sup>[8]</sup> Fixation with two screws has high consolidation rates, better rigidity, and gives higher rotational stability.<sup>[3]</sup> Here, utilizing CT, we determined how many patients' odontoid processes could accommodate 1 versus 2 screws for odontoid spinal fixation.

## MATERIALS AND METHODS

This is a retrospective analysis of the CT studies of the odontoid process performed in 200 asymptomatic adults (2018–2020). The measurements were performed by a single observer.

This is an open-access article distributed under the terms of the Creative Commons Attribution-Non Commercial-Share Alike 4.0 License, which allows others to remix, tweak, and build upon the work non-commercially, as long as the author is credited and the new creations are licensed under the identical terms.

©2021 Published by Scientific Scholar on behalf of Surgical Neurology International

The CT scans were randomly collected from our hospital radiology archives along with relevant variables; there were multiple inclusion and exclusion criteria [Tables 1 and 2].

### Statistical analysis

Statistical comparisons between variables within gender were tested using the Student's *t*-test after verifying that the distribution of the variables was normal ( $P < 0.05$  is significant). The Fisher's exact test was used to examine the significance of the association between sex and minimum external transverse diameter (METD) smaller than 9 mm (Statistical Package for Social Sciences – Version 11.0).

### RESULTS

There were 200 CT studies of odontoid processes. Ten (5%) patients had transverse diameter (TD) <7.4 mm, while none of the patients had diameters of <5.5 mm. The mean minimal external antero-posterior (AP) diameter

of the entire population was 10.17 mm (range 7.10–13.05 mm, SD 1.09 mm), while the mean length of the implant was 36.45 mm. The mean angle of screw insertion was 60.34° [Table 3]. The two-tailed *P* value equals 0.446 and this difference was considered to not be statistically significant.

### DISCUSSION

In this study, we evaluated the morphology of the odontoid process using an accurate and reliable CT-based measurement method. The external CT measurements correlated well with calliper-derived data.<sup>[4]</sup>

#### Several studies evaluated the size of the odontoid process

Kulkarni *et al.*,<sup>[5]</sup> found that AP and TD were 11.52 mm and 9.85 mm, respectively. Yusof *et al.*<sup>[12]</sup> found that 28% of odontoid processes had a cross-sectional diameter of <9.0 mm, making it impossible to perform fixation with two 3.5 mm screws. Daher *et al.* similarly found 39% of Brazilian subjects had similar measurements, while,<sup>[2]</sup> Nucci *et al.*<sup>[9]</sup> found in the American population, that only 5% of subjects had a minimum TD of less than 9.0 mm.<sup>[2,9]</sup> In our study 118 (59.0%) subjects had a METDs of <9 mm, precluding two screw fixation. Hence, two 2.7 mm screws could be used safely in 95% of patients, while a single 4.5 mm Herbert screw could be used safely in the entire population. We also found that 82 (41%) of patients required an implant screw length of < 36 mm [Table 4].

#### Angle of screw insertion

The mean angle of screw insertion was 60.34° (60° on average in females and 60.53° average in males). In Tun *et al.*,<sup>[11]</sup> the mean value of the angle of the odontoid screw

Table 1: Patient demographics, inclusion and exclusion criteria.	
Total number	200
M:F	127:73
Mean age	47 years (Range 18–60)
Inclusion criteria	Skeletally mature, age range of 18–60 years
Exclusion criteria	Fracture, tumour, infection, or metabolic disease affecting the dens like rheumatoid arthritis.

Table 2: CT variables	
LI	Distance between the apex of the odontoid process and anterior border of the axis [Figure 1] (Signifies the length of the implant).
AI	Angle between the line of the apex of the odontoid process to the anterior edge of the axis and tangent to the plateau below the axis [Figure 2]. (Denotes the trajectory the screw has to be placed in).
MITD	Smallest measurement of internal cortex of odontoid in coronal plane [Figure 3a].
METD	Smallest measurement of external diameter of odontoid in the coronal plane [Figure 3b].
MEAD	Smallest measurement external diameter of odontoid in the sagittal plane [Figure 4a].
MIAD	Smallest measurement of the internal cortex of odontoid in the sagittal plane [Figure 4b].
C2 AP base/LI	Indicates the shape of the odontoid [Figure 5].
AP: Anterior-posterior, LI: Estimated length of the implant, MIAD: Minimum internal antero-posterior diameter, MEAD: Minimum external antero-posterior diameter, METD: Minimum external transverse diameter, MITD: Minimum internal transverse diameter, AI: Angle of implant	

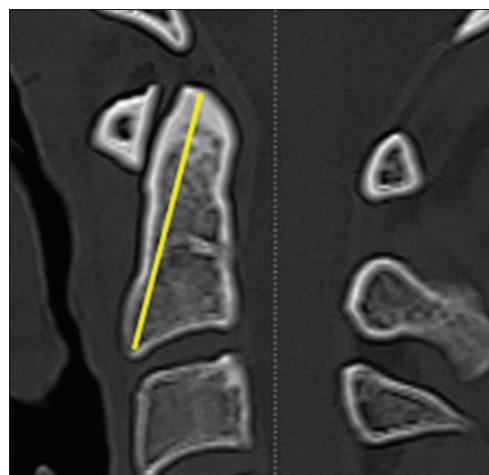


Figure 1: Estimated length of the implant (LI) (distance between the apex of the odontoid process and anterior border of the axis).

**Table 3:** The dimensions of the odontoid by CT morphometry.

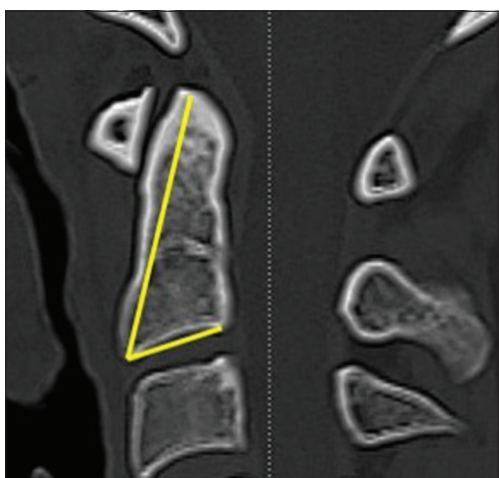
Number of subject	Age	Minimum transverse diameter (mm)		Minimum antero-posterior diameter (mm)		LI	AI	C2 AP base/LI
		External (METD)	Internal (MITD)	External (MEAD)	Internal (MIAD)			
Total, n=200								
Mean	47.31	8.80	6.08	10.17	7.26	36.45	60.34	0.37
Min	19	6.1	3.16	7.10	3.29	24.74	48	0.17
Max	79	11.9	9.97	13.05	12.74	49.30	72	1.33
Female n=73								
Mean	45.52	8.62	5.96	10.15	7.40	35.70	60	0.35
Min	619	6.2	3.16	8.01	4.15	24.74	48	0.17
Max	173	10.6	9.09	12.38	12.74	42.12	69	0.55
Male n=127								
Mean	48.34	8.90	6.15	10.17	7.18	36.89	60.53	0.38
Min	20	6.1	3.80	7.10	3.29	26.47	49	0.19
Max	79	11.9	9.97	13.05	10.18	49.30	72	1.33

LI: Length of implant, AI: Angle of implant, METD: Minimum external transverse diameter, MITD: Minimum internal transverse diameter, MEAD: Minimum external anteroposterior diameter, MIAD: Minimum internal anteroposterior diameter, C2 AP base/LI: Anteroposterior diameter of the axis (C2) divided by the estimated length of the implant

**Table 4:** Comparing the odontoid dimensions from the study by Daher et al. 2011 and the C.S.

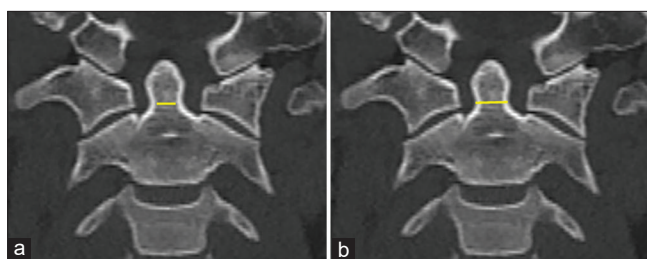
	METD (mm)		MITD (mm)		MEAD (mm)		MIAD (mm)	
	Daher et al	C. S.	Daher et al.	C. S.	Daher et al.	C. S.	Daher et al.	C. S.
Male	9.36	8.90	6.37	6.15	11.59	10.17	8.17	7.18
Female	9.04	8.62	5.82	5.96	10.20	10.15	7.0	7.40
Total	9.19	8.80	6.07	6.08	10.83	10.17	7.53	7.26

C.S.: Current study, METD: Minimum external transverse diameter, MITD: Minimum internal transverse diameter, MEAD: Minimum external antero-posterior diameter, MIAD: Minimum internal antero-posterior diameter



**Figure 2:** Angle of implant (AI): Angle between the line of the apex of the odontoid process to the anterior edge of the axis and tangent to the plateau below the axis).

was  $62.4 \pm 4.7^\circ$  on CT and  $64.2 \pm 4.1^\circ$  on X-rays (i.e., A statistically significant difference in the two measurements of the screw angle).



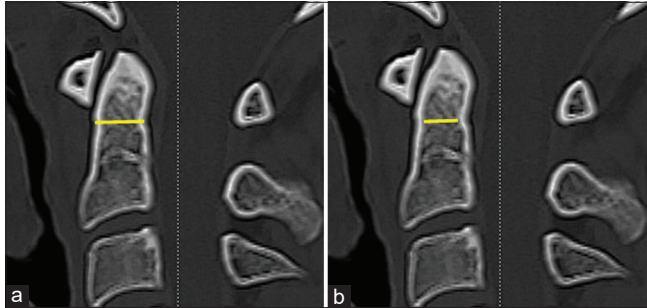
**Figure 3:** (a) Minimum internal transverse diameter and (b) External transverse diameter of the odontoid process.

**Pros for 2 screw fixation**

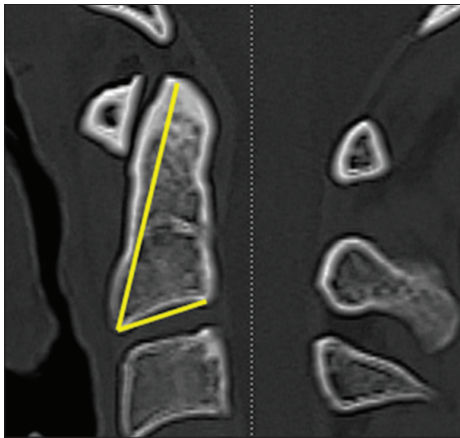
There are considerably higher rates of union with dual screw osteosynthesis.<sup>[8]</sup> Two 3.5 mm screws versus one 4.0 mm screw give a greater surface area to penetrate the cortical bone of the odontoid tip, and increases the bone/screw interface, especially in osteoporotic patients.<sup>[10]</sup>

**Pros for single Herbert screw placement**

For TD measurements of the dens <5.5 mm, only a single 4.5 mm Herbert screw can be safely used. Notably, Lee and



**Figure 4:** Minimum external (a) and internal (b) anteroposterior diameter of the odontoid process.



**Figure 5:** C2 Antero-posterior (AP) diameter at its base divided by the estimated length of the implant (C2 AP base/Length of implant).

Sung reported a good union rate and no implant failures using single 4.5 mm Herbert screws.<sup>[7]</sup>

#### Use of CT to calculate appropriate screw length and diameter

CT reconstructed images make it possible to calculate the diameter and length of the odontoid process and to estimate the quality of bone and size of the odontoid for the safety/efficacy of anticipated one to two screw fixation.

#### CONCLUSION

About two-thirds (59%) of the subject in our Indian population had a METD of the odontoid process of <9 mm. This meant that only one screw could be safely placed in an odontoid process for these individuals.

#### Declaration of patient consent

Patient's consent not required as patients identity is not disclosed or compromised.

#### Financial support and sponsorship

Nil.

#### Conflicts of interest

There are no conflicts of interest.

#### REFERENCES

1. Chadha M, Balain B, Maini L, Dhaon B. Pedicle morphology of the lower thoracic, lumbar, and S1 vertebrae: An Indian perspective. *Spine (Phila Pa 1976)* 2003;28:744-9.
2. Daher MT, Daher S, Defino HL. Tomographic evaluation of odontoid parameters related to its internal fixation. *Coluna Columna* 2010;9:322-7.
3. Dailey AT, Hart D, Finn MA, Schmidt MH, Apfelbaum RI. Anterior fixation of odontoid fractures in an elderly population. *J Neurosurg Spine* 2010;12:1-8.
4. Heller J, Alson M, Schaffler M, Garfin S. Quantitative internal dens morphology. *Spine (Phila Pa 1976)* 1992;17:861-6.
5. Kulkarni AG, Shah SM, Marwah RA, Hanagandi PB, Talwar IR. CT based evaluation of odontoid morphology in the Indian population. *Indian J Orthop* 2013;47:250-4.
6. Laurer H, Sander A, Maier B, Marzi I. Fractures of the cervical spine. *The orthopedist*. 2010;39:237-46.
7. Lee SH, Sung JK. Anterior odontoid fixation using a 4.5-mm Herbert screw: The first report of 20 consecutive cases with odontoid fracture. *Surg Neurol* 2006;66:361-6.
8. Nourbakhsh A, Patil S, Vannemreddy P, Ogden A, Mukherjee D, Nanda A. The use of bioabsorbable screws to fix Type II odontoid fractures: A biomechanical study. *J Neurosurg Spine* 2011;15:361-6.
9. Nucci RC, Seigal S, Merola AA, Gorup J, Mroczek KJ, Dryer J, et al. Computed tomographic evaluation of the normal adult odontoid: Implications for internal fixation. *Spine (Phila Pa 1976)* 1995;20:264-70.
10. Puchwein P, Jester B, Freytag B, Tanzer K, Maizen C, Gumpert R, et al. The three-dimensional morphometry of the odontoid peg and its impact on ventral screw osteosynthesis. *Bone Joint J* 2013;95:536-42.
11. Tun K, Kaptanoglu E, Cemil B, Yorubulut M, Karahan ST, Tekdemir I. Anatomical study of axis for odontoid screw thickness, length, and angle. *Eur Spine J* 2009;18:271-5.
12. Yusof M, Yusof A, Abdullah M, Hussin T. Computed tomographic evaluation of the odontoid process for two-screw fixation in Type-II fracture: A Malaysian perspective. *J Orthop Surg* 2007;15:67-72.

**How to cite this article:** Acharya S, Kumar M, Ghosh JD, Adsl N, Chahal RS, Kalra KL. Morphometric parameters of the odontoid process of C2 vertebrae, in Indian population, a CT evaluation. *Surg Neurol Int* 2021;12:494.