

Mediastinal Paraganglioma: Complete Resection Using Video-Assisted Thoracoscopic Surgery

Dohun Kim, M.D., Si-Wook Kim, M.D., Jong-Myeon Hong, M.D.

Mediastinal paragangliomas are very rare neuroendocrine tumors. Complete resection is the standard treatment of a paraganglioma because of the tumor's potential malignancy and poor response to chemo- or radiotherapy. However, the highly vascular nature of the tumor and its characteristic anatomic location make complete resection difficult. We report a case of an anterior mediastinal paraganglioma, which was incidentally found on a chest computed tomography scan for chronic cough work-up of a 55-year-old woman. Complete resection was accomplished using video-assisted thoracoscopic surgery, and the patient recovered without any complications.

Key words: 1. Video-assisted thoracic surgery (VATS)
2. Mediastinal neoplasms
3. Paraganglioma

CASE REPORT

Mediastinal paragangliomas are very rare neuroendocrine tumors. Most of the tumors are benign, but some of them can be diagnosed as malignant [1]. Complete resection is the standard treatment of paragangliomas [2]. However, the highly vascular nature of these tumors and their characteristic anatomic locations make complete resection difficult. Therefore, cardiopulmonary bypass through median sternotomy is often required to perform complete resection [3,4]. However, whether minimally invasive surgery is unsuitable for this highly vascular mass if the mass is sufficiently small for video-assisted thoracoscopic surgery (VATS) is still uncertain. Therefore, here, we report a case of the complete resection of a paraganglioma using VATS.

A 55-year-old woman was admitted to the hospital because of a mass in the anterior mediastinum. Her past medical his-

tory was unremarkable, but she was suffering from ongoing cough. Computed tomography was performed in a local hospital, and an anterior mediastinal mass was found (Fig. 1). Physical examination revealed normal blood pressure, and the routine blood work results, including complete blood count, electrolytes, and chemistry, were within the normal limits. The mass was located under the sternum; therefore, percutaneous biopsy was not easy. Hence, to achieve the pathological and surgical goal, complete mass resection was planned. The mass was located near the great vessels (under the left innominate vein, immediately above the aortic arch), but there was no sign of local invasion. Therefore, we planned the surgical resection of the tumor using VATS.

A double lumen ET tube was inserted under general anesthesia, and the position was changed to the right decubitus position. A 10-mm-scope port was created in the 4th intercostal space (ICS) close to the anterior axillary line, and a

Department of Thoracic and Cardiovascular Surgery, Chungbuk National University College of Medicine

Received: September 5, 2013, Revised: September 24, 2013, Accepted: October 1, 2013

Corresponding author: Jong-Myeon Hong, Department of Thoracic and Cardiovascular Surgery, Chungbuk National University College of Medicine, 52 Naesudong-ro, Heungdeok-gu, Cheongju 361-804, Korea
(Tel) 82-43-269-6062 (Fax) 82-43-269-6969 (E-mail) hongjm@chungbuk.ac.kr

© The Korean Society for Thoracic and Cardiovascular Surgery. 2014. All right reserved.

© This is an open access article distributed under the terms of the Creative Commons Attribution Non-Commercial License (<http://creativecommons.org/licenses/by-nc/3.0>) which permits unrestricted non-commercial use, distribution, and reproduction in any medium, provided the original work is properly cited.

window measuring 30 mm was created in the 3th ICS close to the anterior scapular border. An additional 5-mm port for a left-hand instrument was created in the 5th ICS close to the mid-axillary line. The mass was totally surrounded by mediastinal fat tissue. After confirming that the mass did not invade the neighboring organ, we dissected the mass with the surrounding fat tissue. We tried not to manipulate the mass directly but to push or pull the surrounding fat tissue. The mass was completely resected using a Harmonic scalpel (Ethicon Endosurgery, Cincinnati, OH, USA). The mass was

assumed to be thymoma type A by frozen biopsy. A small chest tube (12 Fr.) was inserted, and the operation was completed without any accident, including a hypertensive crisis or sudden bleeding. The chest tube was removed on post-operative day 2, and the patient was discharged without complications. The final pathological report revealed the typical characteristics of a paraganglioma (Fig. 2A). The tumor cells stained positive for synaptophysin (Fig. 2B). The resection margin was clear, but the tumor cells invaded into the pericapsular connective tissue and the mitosis was considerable (10/10 high-power field).

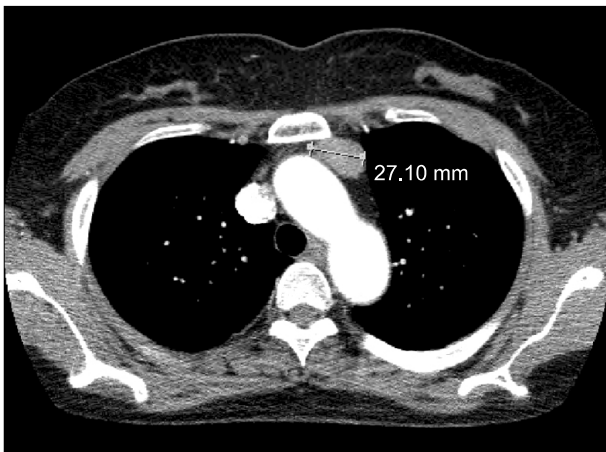


Fig. 1. The computed tomography image showing an anterior mediastinal mass (arrow mark) having a diameter of 27 mm.

DISCUSSION

Paragangliomas are rare neuroendocrine tumors that arise in sympathetic and parasympathetic paraganglia. Most of them (range, 80% to 85%) arise from the adrenal medulla, but the remaining 15% to 20% are located in the extra-adrenal chromaffin tissue. Malignancy is defined by the presence of metastasis and tumor invasion in sites where the chromaffin tissue is normally absent, such as lungs, liver, and bones. The mass considered in this study did not show metastasis but had an invasion into the pericapsular tissue and considerable mitosis. Therefore, after consulting a pathologist, we defined the mass as a malignancy.

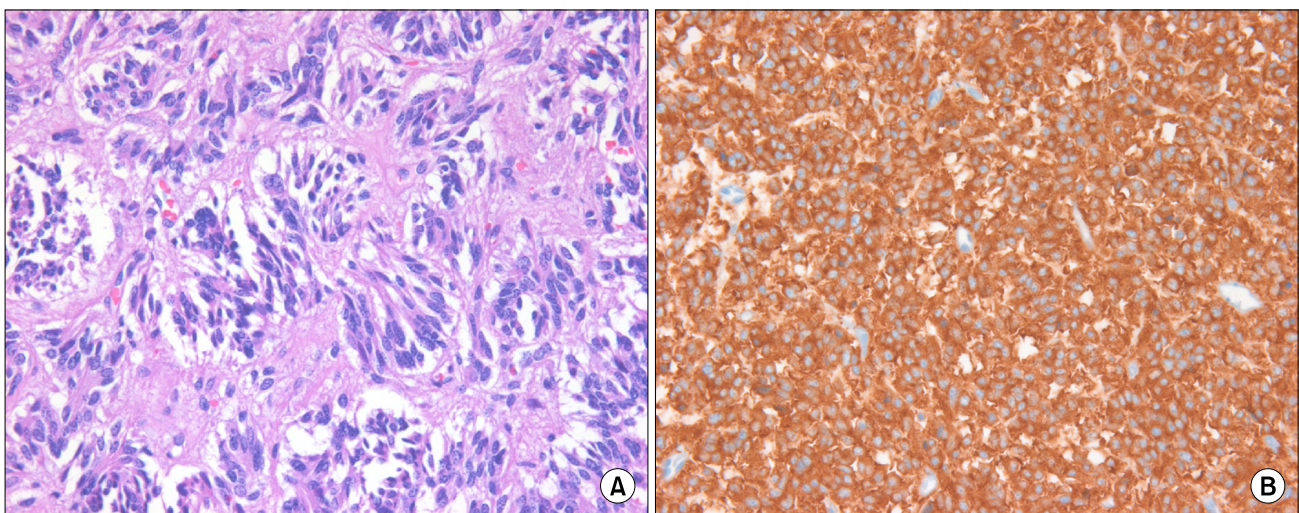


Fig. 2. Microscopic slides showed the typical characteristics of the paraganglioma. (A) H&E stain ($\times 400$) and (B) immunohistochemical stain ($\times 400$).

Complete resection of the paraganglioma using VATS was feasible. Complete resection is the treatment of choice in the case of paragangliomas. However, this treatment is sometimes difficult because of the tumor's vascular nature and anatomical location. Therefore, preoperative embolization or cardiopulmonary bypass is used for the safe resection of huge masses [3-5]. However, minimally invasive surgery has also been attempted in the case of this risky tumor. Thus far, a laparoscopic attempt has been successful, but a thoracoscopic approach has not been successful [6,7]. An indirect manipulation of the tumor and the tumor's small size are thought to be the key to the safe and complete resection of this tumor.

The prognosis in the case considered here is not certain. Prognosis after complete resection is encouraging. Lamy et al. [2] reported the results of a follow-up of 79 patients with paragangliomas over a period of 180 months. In the case of patients undergoing complete resection, the survival rate was 84.6% and the mean survival time was 125 months; in contrast, in the case of patients undergoing incomplete resection, the survival rate was 50.0% and the mean survival time was 71 months [2]. However, the latest study on the subject reported that the large size and the anterior mediastinal location of this tumor were the poor prognostic factors [8]. The patient in this case had a relatively small tumor, but the mass was located in the anterior mediastinum. Moreover, pericapsular invasion and considerable mitosis were found. However, the role of adjuvant treatment was not established. Therefore, a short-term outpatient clinic visit without adjuvant treatment was decided upon as the follow-up plan.

In summary, paragangliomas might be incorporated in the differential diagnosis of an anterior mediastinal mass. Surgical management using VATS can be successfully achieved for the complete resection of a small paraganglioma, and careful manipulation is required to prevent intraoperative complications.

CONFLICT OF INTEREST

No potential conflict of interest relevant to this article was reported.

ACKNOWLEDGMENTS

This work was supported by the research grant of Chungbuk National University in 2012.

REFERENCES

1. Eisenhofer G, Bornstein SR, Brouwers FM, et al. *Malignant pheochromocytoma: current status and initiatives for future progress*. *Endocr Relat Cancer* 2004;11:423-36.
2. Lamy AL, Fradet GJ, Luoma A, Nelems B. *Anterior and middle mediastinum paraganglioma: complete resection is the treatment of choice*. *Ann Thorac Surg* 1994;57:249-52.
3. Paul S, Jain SH, Gallegos RP, Aranki SF, Bueno R. *Functional paraganglioma of the middle mediastinum*. *Ann Thorac Surg* 2007;83:e14-6.
4. Andrade CF, Camargo SM, Zanchet M, Felicetti JC, Cardoso PF. *Nonfunctioning paraganglioma of the aortopulmonary window*. *Ann Thorac Surg* 2003;75:1950-1.
5. Shakir M, Blossom G, Lippert J. *Anterior mediastinal paraganglioma: a case for preoperative embolization*. *World J Surg Oncol* 2012;10:134.
6. Mitchell J, Siperstein A, Milas M, Berber E. *Laparoscopic resection of abdominal paragangliomas*. *Surg Laparosc Endosc Percutan Tech* 2011;21:e48-53.
7. Lin MW, Chang YL, Lee YC, Huang PM. *Non-functional paraganglioma of the posterior mediastinum*. *Interact Cardiovasc Thorac Surg* 2009;9:540-2.
8. Ayala-Ramirez M, Feng L, Johnson MM, et al. *Clinical risk factors for malignancy and overall survival in patients with pheochromocytomas and sympathetic paragangliomas: primary tumor size and primary tumor location as prognostic indicators*. *J Clin Endocrinol Metab* 2011;96:717-25.