

Original Article



Feasibility of laparoscopic diaphragmatic peritonectomy during Visceral-Peritoneal Debulking (VPD) in patients with stage IIIC-IV ovarian cancer

Roberto Tozzi , Hooman Soleymani Majd , Riccardo Garruto Campanile ,
Federico Ferrari

Department of Women's and Reproductive Health, University of Oxford, Old Road, Headington, Oxford, UK

OPEN ACCESS

Received: Mar 30, 2020

Revised: Apr 24, 2020

Accepted: May 8, 2020

Correspondence to

Roberto Tozzi

Department of Gynaecologic Oncology,
Nuffield Department of Women's and
Reproductive Health, Oxford University
Hospital, Old Road OX3 7LJ, Oxford, UK.
E-mail: Roberto.tozzi@wrh.ox.ac.uk

Copyright © 2020. Asian Society of
Gynecologic Oncology, Korean Society of
Gynecologic Oncology

This is an Open Access article distributed
under the terms of the Creative Commons
Attribution Non-Commercial License (<https://creativecommons.org/licenses/by-nc/4.0/>)
which permits unrestricted non-commercial
use, distribution, and reproduction in any
medium, provided the original work is properly
cited.

ORCID iDs

Roberto Tozzi

<https://orcid.org/0000-0001-6123-1628>

Hooman Soleymani Majd

<https://orcid.org/0000-0003-3293-5321>

Riccardo Garruto Campanile

<https://orcid.org/0000-0003-0009-8389>

Federico Ferrari

<https://orcid.org/0000-0001-7065-2432>

Conflict of Interest

No potential conflict of interest relevant to this
article was reported.

ABSTRACT

Objective: To describe the surgical technique and evaluate the safety, feasibility and efficacy of laparoscopic diaphragmatic peritonectomy during Visceral-Peritoneal Debulking (VPD) in patients with stage IIIC-IV ovarian cancer (OC).

Methods: This report is part of a Service Evaluation Protocol (Trust number 3267) on laparoscopy in patients with OC following neo-adjuvant chemotherapy. Between April 2015 and November 2017, all patients underwent to exploratory laparoscopy and a selected court was offered laparoscopic VPD. Laparoscopic diaphragmatic surgery was considered if there was no full thickness involvement. Primary endpoints of this part of the study were the safety, feasibility and efficacy of laparoscopic diaphragmatic peritonectomy. We report the surgical technique and outcomes.

Results: Ninety-six patients underwent diaphragmatic surgery during the study period. Fifty patients (52.1%) had intra-operative exclusion criteria and/or full thickness diaphragmatic resection, 46 (47.9%) had peritonectomy and were included in the study. Laparoscopic diaphragmatic peritonectomy was performed in 21 patients (45.4%, group 1), while in 25 patients (54.6%, group 2) laparotomy was necessary. Extent of disease and complexity of surgery were similar. Reasons for conversions were disease coalescing the liver to the diaphragm preventing safe mobilization (22 patients) and accidental pleural opening (3 patients). Overall, intra- and post-operative morbidity was lower in group 1 and pulmonary specific morbidity was very low.

Conclusion: Diaphragmatic peritonectomy can be safely accomplished by laparoscopy in almost half of the patients with OC whose disease is limited to the diaphragmatic peritoneum.

Keywords: Ovarian Cancer; Laparoscopy; Diaphragmatic Peritonectomy

INTRODUCTION

Ovarian cancer is an aggressive disease. It is estimated that 200,000 women are diagnosed globally every year, 75% of them at stage IIIC-IV [1,2]. For these patients, the standard of treatment is the combination of surgery and chemotherapy. Many studies demonstrate that the residual disease following surgery is the strongest independent prognostic factor. In

Author Contributions

Conceptualization: T.R. Data curation: T.R., S.M.H., C.R.G., F.F.; Formal analysis: T.R.; Investigation: T.R.; Methodology: T.R.; Project administration: T.R.; Resources: T.R.; Supervision: T.R., F.F.; Validation: T.R., F.F.; Visualization: T.R., F.F.; Writing - original draft: T.R.; Writing - review & editing: T.R., S.M.H., C.R.G., F.F.

addition, a complete resection (CR) of all visible disease is associated to the best survival rates [3-12]. To achieve the highest rate of CR gynecological oncologists are commonly performing upper abdominal surgery [13,14]. Diaphragm involvement in patients with stage IIIC-IV ovarian cancer (OC) has an estimated incidence of 40%–91% [15-18]. Diaphragmatic surgery was already described two decades ago [19-31] and, in the past, it was reported as the limit to a CR by 76% of the U.S. surgeons [31]. The current literature suggests that diaphragmatic surgery increases the rate of CR and survival outcome [22-25]. Usually diaphragmatic surgery is confined to stripping the peritoneum, but sometimes, it may involve the muscle and pleura requiring a full thickness resection with access to pleural cavity. Allegedly, diaphragmatic surgery increases the morbidity of debulking operations [26-28]. Since 2006, we offer ultra-radical surgery which we named visceral-peritoneal debulking (VPD) to all patients with OC. In 2014 we registered a service evaluation on the feasibility of VPD by laparoscopy. In this report, we investigate if diaphragmatic peritonectomy could be safely and effectively performed by laparoscopy, reproducing the same technique described at laparotomy, including liver mobilization.

MATERIALS AND METHODS

This report is part of a study on the feasibility of laparoscopic VPD which was registered as a service evaluation project and obtained Oxford University Hospital Trust approval (number 3267). The objectives of the study were the safety (rate of complications specifically caused by the technique), feasibility (rate of surgery completed by laparoscopy) and efficacy (rate of surgery ended with CR of all visible disease). The study was offered to all consecutive patients with OC who underwent neo-adjuvant chemotherapy and displayed response or stable disease by GCIG and RECIST criteria. At our Institution the greatest credit is given to the CT scan review. We classified response as complete (no visible disease), good partial (>50% reduction), partial (<50% reduction), or stable disease. Laparoscopic VPD was offered at time of interval debulking surgery to all patients with disease limited to the pelvis, omentum, peritoneum and diaphragm on CT scan. Details of the VPD protocol were previously reported [28]. The single accepted goal for the VPD was CR of all visible tumor. Patients with disease precluding CR were not offered VPD. Exclusion criteria from laparoscopic VPD were the need for multiple bowel resections, disease on the mesentery or at the porta hepatis [17], which would mandate a conversion to laparotomy (**Table 1**). By study protocol we decided to exclude patients who needed a full thickness resection and electively converted surgery to laparotomy because of the complexity of ventilating the lungs with an open pleural cavity and concomitant CO2 insufflation. Surgery started with an exploratory laparoscopy (EXL) to implement the diagnostic accuracy of the CT scan. Details of the laparoscopic En-bloc resection of the pelvis (EnBRP) were previously published [29]. This report is focused on the

Table 1. Criteria for laparoscopic Visceral-Peritoneal Debulking

Inclusion criteria	Exclusion criteria
Pre-operative	Pre-operative
<ul style="list-style-type: none"> - Histology proven or suspected stage IIIC-IV ovarian cancer - Performance status <2 - Any response or stable disease to chemotherapy 	<ul style="list-style-type: none"> - Computed tomography scan demonstrating lung metastases, 3 or more liver segments involvement, disease progression following chemotherapy
Intra-operative	Intra-operative
<ul style="list-style-type: none"> - Disease limited to pelvis, omentum, peritoneum and diaphragm 	<ul style="list-style-type: none"> - Diffuse small bowel serosal deposits, porta hepatis encasement - Multiple bowel resection - Extensive disease on the mesentery or mesocolon - Disease on the diaphragm requiring full thickness resection

diaphragmatic surgery. The presence of diaphragmatic disease was suggested by CT scan and confirmed by EXL. The surgical plan was to perform a peritonectomy, but all patients consented to a full thickness resection. The final decision was based on the direct inspection of the disease at time of surgery. If no cleavage plane was found, if the peritonectomy would leave tumor behind or if disease was involving all layers including the pleura a full thickness resection was performed. We found EXL very useful also in this type of assessment. Since no data were found in the literature, we also electively decided not to adopt a double lumen tube (DLT) to limit the level of novelty introduced in the study. Our surgical technique was previously reported [28,30] and only supports resection of cancer, no coagulation or ablation. We recently introduced a classification for diaphragmatic surgery [31] and, in this study, it was used to define the type of surgery and the breakdown in the groups. We recorded the surgical outcomes of patients whose diaphragmatic surgery was completed by laparoscopy and the one who needed a conversion to laparotomy. However, since the latter group was built by patients whose surgery was not achievable by laparoscopy and therefore more complex, we found a comparison to bear limited significance. Data were analyzed using the χ^2 test or Fisher's exact test for categorical variables, and the Student's t-test for continuous variables. A p value of 0.05 or minor was considered statistically significant.

1. Surgical technique of laparoscopic diaphragmatic peritonectomy

The operation always started by EXL to confirm that CR was possible. We used 2×10 mm (in the umbilicus and the Palmer's point) and 3×5 mm trocars (in the lower abdomen) which were placed in the usual positions (**Fig. 1**). Only atraumatic instruments, bipolar scissors and graspers (Karl Storz, Tuttlingen, Germany) were used for the diagnostic part including adhesiolysis and dissection. The extension of the disease on the diaphragm was examined thoroughly by direct vision applying gentle dorsal and ventral pressure to the liver. In patients where the diaphragmatic disease was stuck to the liver, a proper mobilization was completed until the extent of disease could properly be assessed. Additional ports were placed when necessary below the subcostal margin either in the right pararectal line, the anterior axillary line or the posterior axillary line. The technique mimicked the open surgery one. Usually a silicon band was placed around the porta hepatis after dissection of the space to enable a Pringle maneuver if necessary. The falciform ligament was coagulated, cut and used for traction when helpful (**Fig. 1**). Once its membranous part was fully displayed, the liver was pushed dorsally, and the right anterior coronary ligament was coagulated to release the anterior attachment of the liver to the diaphragm (**Fig. 1D**). Once the ventral disease was fully exposed, the diaphragmatic peritoneum was excised away from the disease starting from the ventral part closest to the ribs (**Figs. 2 and 3**). Because of the limited amount of traction possible at laparoscopy, the dissection of the liver was continued from the dorsal-posterior side aiming at the right triangular ligament (**Fig. 4**). To help lifting the liver from dorsal to ventral and caudal a 10 mm Snake retractor (Karl Storz) was used. It was placed below the 6th segment along the longest axis of the organ to elevate the liver towards ventral (**Fig. 5**). Once the right triangular ligament was coagulated and cut, the Snake retractor was articulated in a hook shape between the 6th and the 7th segment to pull the liver towards medial so to expose the bare area of the liver (**Supplementary Fig. 1**). The peritonectomy proceeded from dorsal to ventral in a centripetal fashion going towards the tendon and same was done from the right paracolic gutter, over the right kidney and at the edge with the right lateral aspect of the IVC (**Supplementary Fig. 2**). Once the peritoneum below the bare area of the liver was freed, the surgery carried on from the ventral part aiming for the tendon in a ventral-dorsal direction until the peritoneum was fully resected (**Supplementary Figs. 3 and 4**). The use of a bipolar coagulation to facilitate the peritoneal stripping was essential in limiting the blood

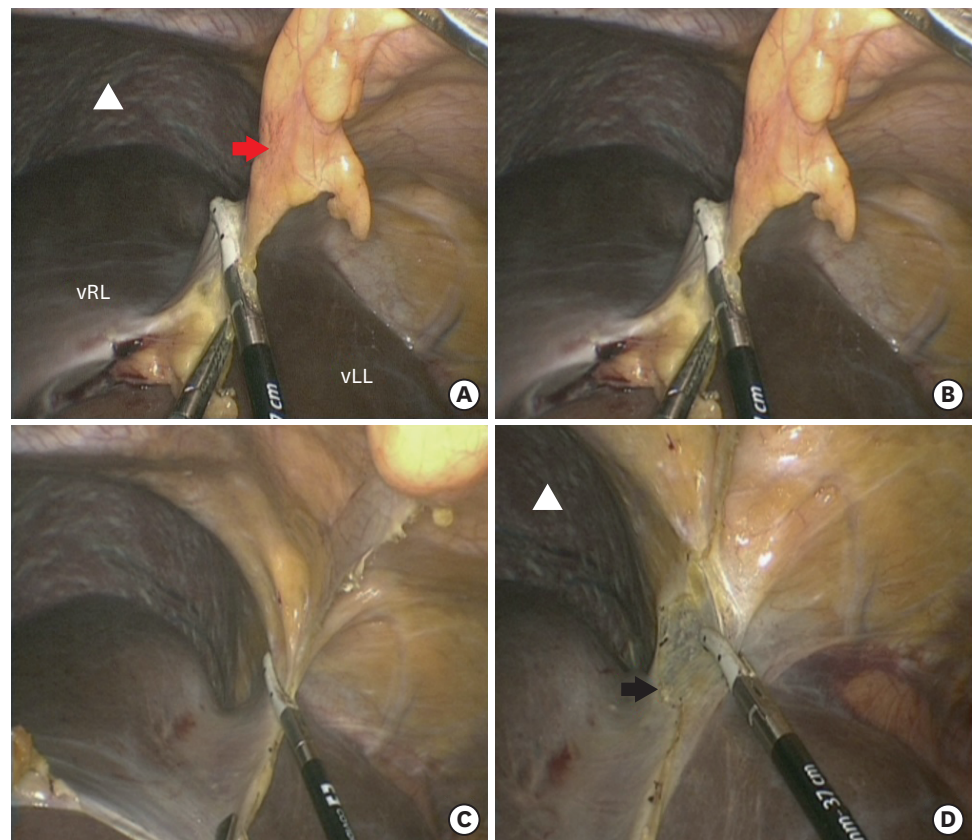


Fig. 1. Resection of the falciform ligament (A, B, C) and right anterior coronary ligament (D). The falciform ligament connects the liver (in the lower part the picture) to the anterior parietal abdominal wall (in the upper part of the picture) dividing in the right and left coronary ligaments (D). Black arrow, right anterior coronary ligament; Red arrow, falciform ligament; vLL, ventral left liver; vRL, ventral right liver; White triangle, right diaphragm.

loss. If further disease was found while approaching the bare area of the liver an additional subcostal trocar was placed. Any disease found on the left hemi-diaphragm was treated in the same way with bipolar coagulation and stripping. The peritoneal specimen was removed through endo-bags. To confirm the integrity of the diaphragm the patient was placed in steep Trendelenburg position and the diaphragm was covered with irrigation solution. The anesthetist will then ventilate the patient manually to perform a Valsalva maneuver to expose any defect in the diaphragm. If accidental opening of the pleura occurred, the CO₂ insufflation was stopped, and the procedure converted to open surgery.

RESULTS

A flowchart of the study is reported in **Supplementary Fig. 5**. Patient demographics and tumor characteristics are reported in **Supplementary Table 1**. Hundred twenty-eight patients had VPD in the study period. All patients underwent surgery after a minimum of 3 cycles of platinum-based chemotherapy. Ninety-six out of 128 patients (75%) underwent diaphragmatic surgery. Twenty one out of 96 patients (21.8%) had the procedure completed by laparoscopy, while 75 patients (78.2%) needed a laparotomy. Fifty patients were found with intra-operative exclusion factors or disease involving the diaphragm in its full thickness

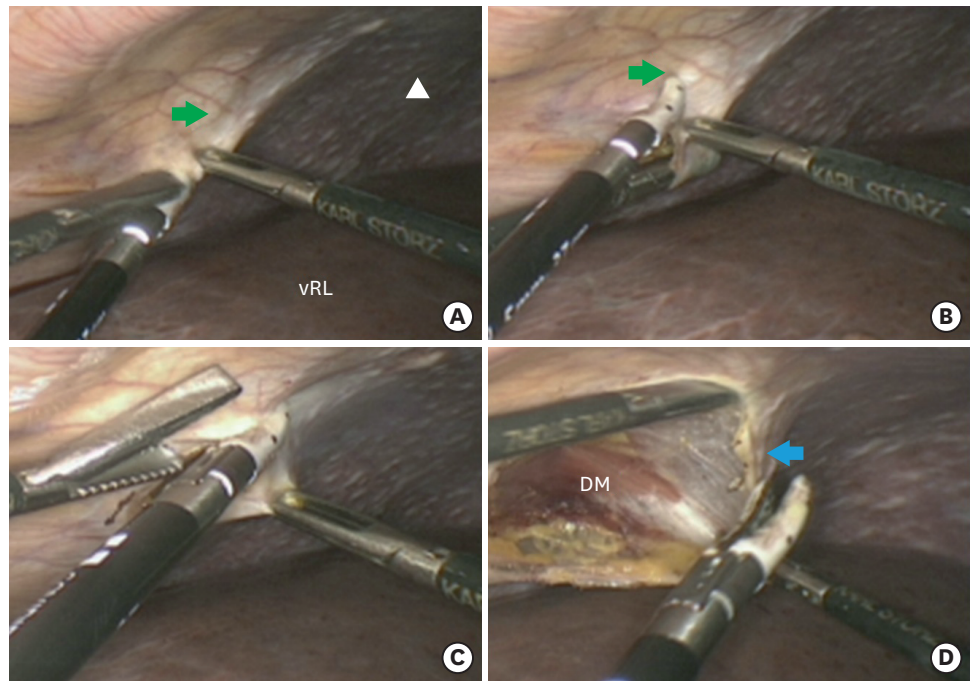


Fig. 2. Incision of the peritoneum and peritonectomy, ventral approach. The ventral peritoneum is incised from the lateral side of the diaphragm starting from disease-free tissue. The liver is recognizable in the lower part of the picture and the disease covering the diaphragm in the upper part. In 2-D the space between the peritoneum and the muscle is dissected. Blue arrow, peritoneum; DM, diaphragm muscle; Green arrow, disease free diaphragm; vRL, ventral right liver; White triangle, right diaphragm.

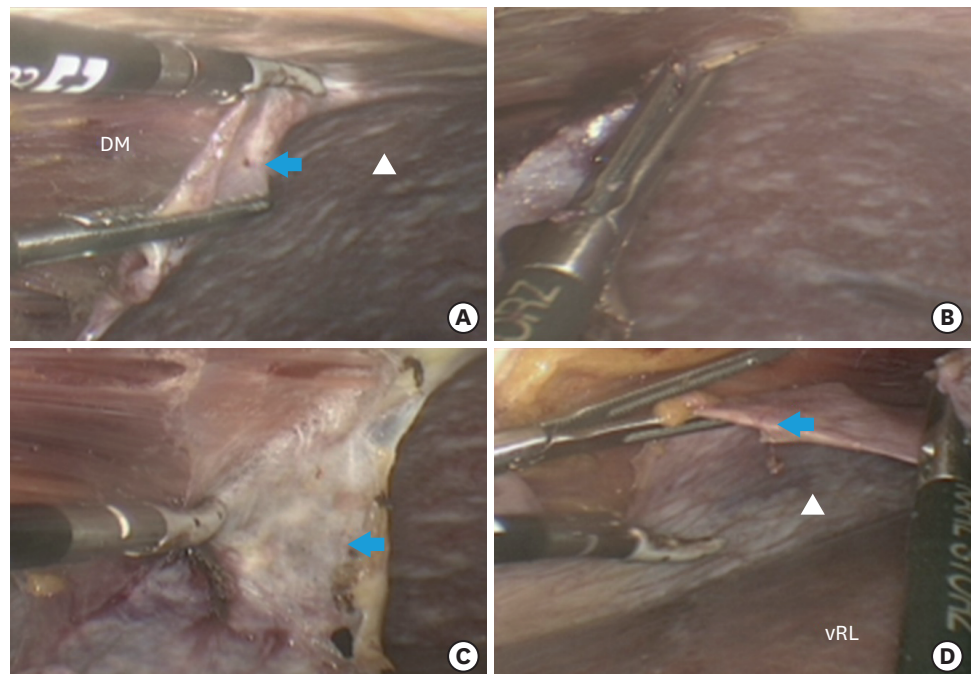


Fig. 3. Peritonectomy, ventral approach. The incision of the ventral peritoneum continues from lateral to medial. Traction of the peritoneum flap is essential to proceed with the incision. Diaphragm muscle is more exposed. Blue arrow, peritoneal flap; DM, diaphragmatic muscle; vRL, ventral right liver; White triangle, right diaphragm.

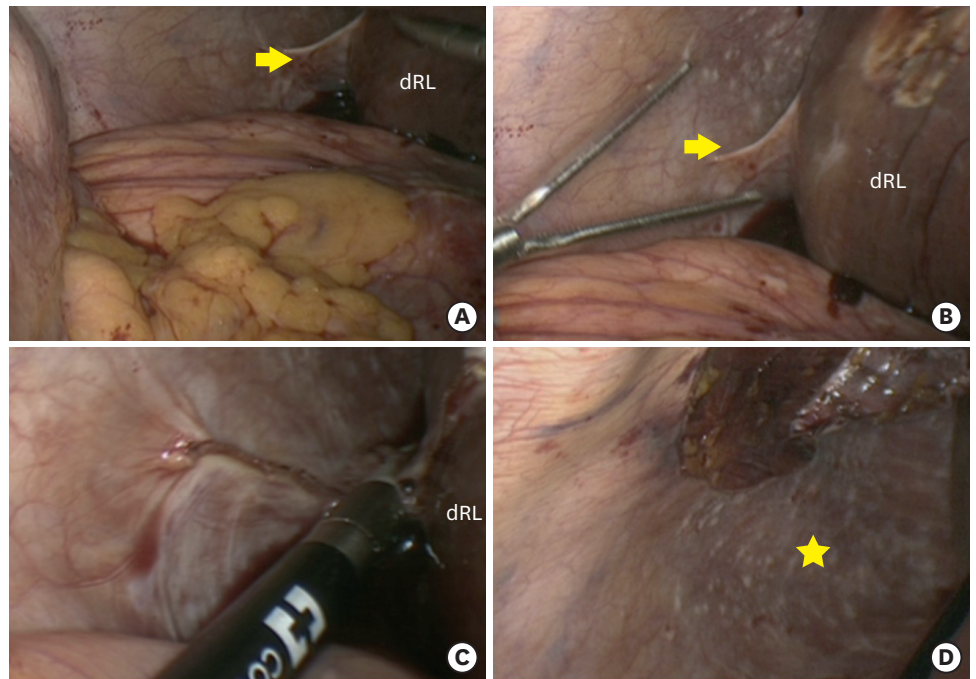


Fig. 4. Resection of triangular ligament (A, B, C) with exposure of disease not seen before mobilization (D). The red arrow indicates the triangular ligament. (C) Resected triangular ligament. (D) The exposure of disease behind the liver.
dRL, dorsal right liver; Yellow arrow, triangular ligament; Yellow star, disease exposed after mobilization.

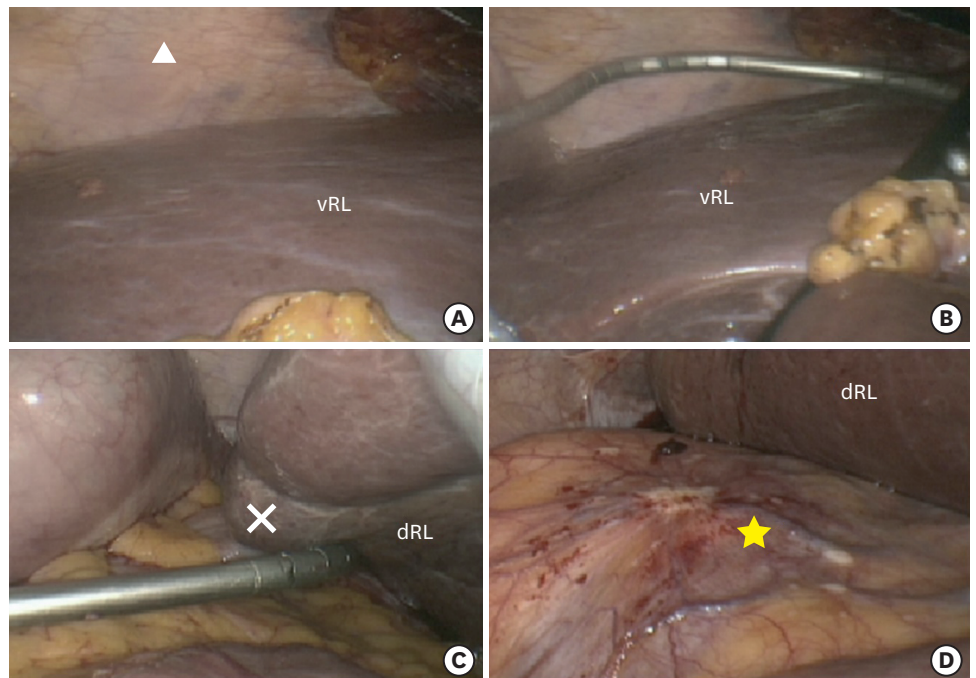


Fig. 5. Position of “Snake” retractor applied to the 6th hepatic segment (A, B, C) with exposure of disease on the right renal capsule (D).
Stepwise shaping and positioning of the Snake retractor with view of the ventral aspect of the liver (A, B). (C) The retractor is rotated and placed below the 6th segment. (D) The retractor is used to lift ventrally the partially mobilized liver.
vRL, ventral right liver; White cross, 6th hepatic segment; White triangle, right diaphragm; Yellow star, disease on renal capsule.

and needed laparotomy. Forty-six had disease limited to the peritoneum and represent the study population. Twenty-one patients out of 46 (45.4%) had diaphragmatic peritonectomy and VPD by laparoscopy (group 1) and 25 patients out of 46 (54.6%) underwent laparotomy (group 2). There were no statistically significant differences between the two groups with regards to age, treatment type, FIGO stage, histology, previous treatments, number and type of chemotherapy cycles and response to chemotherapy. In group 1, 16 patients had diaphragmatic type I surgery and 5 type II (31). In group 2, 18 patients had type II surgery and 7 had type III surgery (31). The difference in the type of surgery was statistically significant among the groups (type I 76% in group 1 vs. 0% in group 2, $p=0.02$; type II 24% in group 1 vs. 73% in group 2, $p=0.034$; type III in group 1 0% vs. 27% in group 2, $p=0.03$). Feasibility of laparoscopic diaphragmatic peritonectomy was calculated as 45.4% (21 patients out of 45). Overall reason for conversion to laparotomy were as following: 50 patients had intra-operative exclusion criteria and/or disease involving the diaphragm full thickness and they all required pleurectomy at laparotomy (surgery was continued up to a point when it became clear that there were exclusion criteria or full thickness involvement), 22 had disease stuck between the liver and the diaphragm preventing safe mobilization (surgery was attempted and interrupted because of the findings) and 3 had accidental access to the thorax. Of note, in group 1, all patients had right diaphragmatic peritonectomy and 10 patients also had left diaphragmatic peritonectomy. Other procedures in group 1 were sigmoid-rectum resection as part of the EnBRP in 15 patients, supracolic omentectomy in all patients and pelvic peritonectomies in 21 patients. A CR was accomplished in all patients, resulting in 100% efficacy. The study groups were not significantly different for extent of disease, number and complexity of procedures. The operative time was not significantly different. All surgical outcomes are reported in **Supplementary Table 2**. Patients in group 1 had shorter time of catheterization and hospitalization, lower rate of post-operative infections and lower estimated blood loss. The morbidity data are reported in **Supplementary Table 3**. There was no specific morbidity related to the laparoscopic diaphragmatic peritonectomy. Pulmonary morbidity was remarkably low in the laparoscopic group with no case of pneumothorax or pleural effusion. Overall intra- and post-operative morbidity was lower in group 1. One patient in group 1 had a G3 complication, a mechanic ileus secondary to a surgical complication. The CT scan showed an ileal loop prolapsed through the 10 mm trocar incision in the Palmer's point. The patient had a second laparoscopy to mobilize the small bowel loop and went home within 48 hours. Final histology confirmed the presence of gross disease in all patients. To our knowledge, no patient has experienced trocar metastasis. All patients in the laparoscopic group started chemotherapy as planned, while 10 patients out of 75 (13.3%) in group 2 experienced a delay, although all patients started chemotherapy within 7 weeks of the surgery. At 35 months median follow-up time no significant difference was found with regards to overall survival (51% group 1 vs. 48% group 2).

DISCUSSION

Diaphragmatic surgery is part of the standard portfolio of gynecologic oncologist treating patients with stage IIIC-IV ovarian cancer [32]. Considering an involvement rate of over 70%, the time when surgeons reported diaphragmatic disease as the limit to achieve a CR is long gone [31-34]. However, the morbidity of such surgery is still considered significant, in terms of short- and long-term complications [35-38]. In a previous report we investigated the morbidity of the full thickness resection/pleurectomy and failed to find a significant difference when compared to diaphragmatic peritonectomy [30]. In this study we explored

the feasibility of diaphragmatic peritonectomy by laparoscopy. Several studies demonstrated reduced invasiveness, decreased intra- and post-operative morbidity, shorter hospitalization and faster recovery when surgery was done by laparoscopy. Very few reports were found on the use of laparoscopy in patients with OC [29]. The few published confirmed the advantages of such technique over a laparotomy. The main aim of this study was to investigate the feasibility of laparoscopic diaphragmatic peritonectomy in a selected group of patients. The result shows that overall, only 21.8% of the patients were spared a xifo-pubic laparotomy in the study period. However, 45% of the patients who met the study criteria, had the procedure completed by laparoscopy. This is a very initial experience on laparoscopic diaphragmatic surgery with substantial exclusion factors. The main one was the immediate conversion to laparotomy if the pleural cavity was accessed. This cannot be regarded as an absolute surgical contra-indication, because it requires a different approach from the anesthetic team. In fact, once the pleura is open, the circulating CO₂ will enter the pleural cavity and compress the lung. The latter is ventilated through the traditional tube but unable to properly expand because of the CO₂. The consequences can be serious leading to acidosis, respiratory failure and even mediastinal dislocation. Hence the need to discontinue the insufflation and evacuate the remaining CO₂. Without the gas distension it is impossible to continue the surgery thus the need to convert to laparotomy. This issue could possibly be overcome by the placement of a DLT as it is usually done during thoracic surgery. The latter is without the CO₂ insufflation though. The DLT has the advantage to ventilate one lung and isolate the other, allowing to work in the thoracic cavity with the collapsed lung. That would however not circumvent the need for higher ventilatory pressure and the risk of mediastinal dislocation. In this study we did not consider using the DLT because that would add a further element of research and complexity. No report has so far been published on patients with ovarian cancer operated on with a DLT. This study was not designed to determine if a pleurectomy and closure of the diaphragm could be done by laparoscopy because it was excluded by protocol. For completeness we reported all 75 patients who had surgery converted to laparotomy as failed laparoscopic diaphragmatic surgery. However, per study protocol, 50 patients were excluded because of intra-operative exclusion criteria and/or full thickness diaphragmatic disease. That leaves, as true study failures, 23 patients whose type of disease precluded the safe mobilization of the liver and/or had the liver cohered to the diaphragmatic disease. Also leaves 21 patients with a successful laparoscopic diaphragmatic peritonectomy and whole VPD. These patients experienced a remarkably good outcome in terms of overall and specific morbidity, let alone fast recovery and short hospitalization. The encouraging results should take in account that the study included a limited and highly selected population. Patients in group 1 and 2 had lower disease load and less complex procedures than the rest of the population (50 patients) initially excluded from the study. Also, patients in group 2 had surgical findings that were not safely manageable by laparoscopy. Hence, the comparison must be made with caution. In fact, the aim of the study was not a comparison but to explore the feasibility, safety and efficacy of diaphragmatic peritonectomy by laparoscopy. In other words, if pursuing laparoscopy in these patients could benefit them rather than just being an academic surgical exercise [39]. With that respect, the results are reassuring and support further investigation. Clearly, these results cannot be applied to all patients with OC. We attempted to find prognostic factors to predict feasibility of diaphragmatic peritonectomy by laparoscopy. The only significant factor was the extent of disease on the diaphragm. Therefore, based on the findings of this study, we currently recommend this procedure in patients with a type I diaphragmatic disease [31]. Because most of the technique limits could be overcome, a subsequent study will test the feasibility of any diaphragmatic surgery by using a DLT during laparoscopic VPD.

SUPPLEMENTARY MATERIALS

Supplementary Table 1

Patients and tumor characteristics of the study groups

[Click here to view](#)

Supplementary Table 2

Surgical outcomes in the study groups

[Click here to view](#)

Supplementary Table 3

Morbidity outcomes (Clavien-Dindo classification)

[Click here to view](#)

Supplementary Fig. 1

Position of “Snake” retractor below the 6th/7th hepatic segment with incision of dorsal peritoneum.

[Click here to view](#)

Supplementary Fig. 2

Peritonectomy, ventral medial approach.

[Click here to view](#)

Supplementary Fig. 3

Peritonectomy, ventral dorsal approach.

[Click here to view](#)

Supplementary Fig. 4

Peritonectomy final centripetal step.

[Click here to view](#)

Supplementary Fig. 5

Flow-chart of the study.

[Click here to view](#)

REFERENCES

1. Cancer Research UK. Ovarian cancer statistics [Internet]. Oxford: Cancer Research UK; 2020 [cited 2020 Mar 17]. Available from: <http://www.cancerresearchuk.org/cancer-info/cancerstats/keyfacts/ovarian-cancer/>.
2. Parkin DM, Bray F, Ferlay J, Pisani P. Global cancer statistics, 2002. *CA Cancer J Clin* 2005;55:74-108.
[PUBMED](#) | [CROSSREF](#)

3. Vergote I, Tropé CG, Amant F, Kristensen GB, Ehlen T, Johnson N, et al. Neoadjuvant chemotherapy or primary surgery in stage IIIC or IV ovarian cancer. *N Engl J Med* 2010;363:943-53.
[PUBMED](#) | [CROSSREF](#)
4. Chi DS, Liao JB, Leon LF, Venkatraman ES, Hensley ML, Bhaskaran D, et al. Identification of prognostic factors in advanced epithelial ovarian carcinoma. *Gynecol Oncol* 2001;82:532-7.
[PUBMED](#) | [CROSSREF](#)
5. Winter WE 3rd, Maxwell GL, Tian C, Carlson JW, Ozols RF, Rose PG, et al. Prognostic factors for stage III epithelial ovarian cancer: a Gynecologic Oncology Group Study. *J Clin Oncol* 2007;25:3621-7.
[PUBMED](#) | [CROSSREF](#)
6. Chi DS, McCaughy K, Diaz JP, Huh J, Schwabenbauer S, Hummer AJ, et al. Guidelines and selection criteria for secondary cytoreductive surgery in patients with recurrent, platinum-sensitive epithelial ovarian carcinoma. *Cancer* 2006;106:1933-9.
[PUBMED](#) | [CROSSREF](#)
7. Harter P, du Bois A, Hahmann M, Hasenburg A, Burges A, Loibl S, et al. Surgery in recurrent ovarian cancer: the Arbeitsgemeinschaft Gynaekologische Onkologie (AGO) DESKTOP OVAR trial. *Ann Surg Oncol* 2006;13:1702-10.
[PUBMED](#) | [CROSSREF](#)
8. Zang RY, Harter P, Chi DS, Sehouli J, Jiang R, Tropé CG, et al. Predictors of survival in patients with recurrent ovarian cancer undergoing secondary cytoreductive surgery based on the pooled analysis of an international collaborative cohort. *Br J Cancer* 2011;105:890-6.
[PUBMED](#) | [CROSSREF](#)
9. Tsolakidis D, Amant F, Leunen K, Cadron I, Neven P, Vergote I. Comparison of diaphragmatic surgery at primary or interval debulking in advanced ovarian carcinoma: an analysis of 163 patients. *Eur J Cancer* 2011;47:191-8.
[PUBMED](#) | [CROSSREF](#)
10. du Bois A, Reuss A, Pujade-Lauraine E, Harter P, Ray-Coquard I, Pfisterer J. Role of surgical outcome as prognostic factor in advanced epithelial ovarian cancer: a combined exploratory analysis of 3 prospectively randomized phase 3 multicenter trials: by the Arbeitsgemeinschaft Gynaekologische Onkologie Studiengruppe Ovarialkarzinom (AGO-OVAR) and the Groupe d'Investigateurs Nationaux Pour les Etudes des Cancers de l'Ovaire (GINECO). *Cancer* 2009;115:1234-44.
[PUBMED](#) | [CROSSREF](#)
11. Bristow RE, Tomacruz RS, Armstrong DK, Trimble EL, Montz FJ. Survival effect of maximal cytoreductive surgery for advanced ovarian carcinoma during the platinum era: a meta-analysis. *J Clin Oncol* 2002;20:1248-59.
[PUBMED](#) | [CROSSREF](#)
12. Soleymani Majd H, Ismail L, Hardern K, Ferrari F, Kehoe S. Comparison of survival outcome of patients with primary peritoneal and fallopian tube carcinoma treated with neoadjuvant chemotherapy versus primary debulking surgery. *J Obstet Gynaecol* 2017;37:89-92.
[PUBMED](#) | [CROSSREF](#)
13. Eisenkop SM, Spirtos NM. Procedures required to accomplish complete cytoreduction of ovarian cancer: is there a correlation with "biological aggressiveness" and survival? *Gynecol Oncol* 2001;82:435-41.
[PUBMED](#) | [CROSSREF](#)
14. Cliby W, Dowdy S, Feitoza SS, Gostout BS, Podratz KC. Diaphragm resection for ovarian cancer: technique and short-term complications. *Gynecol Oncol* 2004;94:655-60.
[PUBMED](#) | [CROSSREF](#)
15. Eisenhauer EL, Chi DS. Liver mobilization and diaphragm peritonectomy/resection. *Gynecol Oncol* 2007;104 Suppl 1:25-8.
[PUBMED](#) | [CROSSREF](#)
16. Einenkel J, Ott R, Handzel R, Braumann UD, Horn LC. Characteristics and management of diaphragm involvement in patients with primary advanced-stage ovarian, fallopian tube, or peritoneal cancer. *Int J Gynecol Cancer* 2009;19:1288-97.
[PUBMED](#) | [CROSSREF](#)
17. Tozzi R, Traill Z, Garruto Campanile R, Ferrari F, Soleymani Majd H, Nieuwstad J, et al. Porta hepatis peritonectomy and hepato-eliac lymphadenectomy in patients with stage IIIC-IV ovarian cancer: Diagnostic pathway, surgical technique and outcomes. *Gynecol Oncol* 2016;143:35-9.
[PUBMED](#) | [CROSSREF](#)
18. Montz FJ, Schlaerth JB, Berek JS. Resection of diaphragmatic peritoneum and muscle: role in cytoreductive surgery for ovarian cancer. *Gynecol Oncol* 1989;35:338-40.
[PUBMED](#) | [CROSSREF](#)
19. Fiorica JV, Hoffman MS, LaPolla JP, Roberts WS, Cavanagh D. The management of diaphragmatic lesions in ovarian carcinoma. *Obstet Gynecol* 1989;74:927-9.
[PUBMED](#)

20. Tsolakidis D, Amant F, Van Gorp T, Leunen K, Neven P, Vergote I. The role of diaphragmatic surgery during interval debulking after neoadjuvant chemotherapy: an analysis of 74 patients with advanced epithelial ovarian cancer. *Int J Gynecol Cancer* 2010;20:542-51.
[PUBMED](#) | [CROSSREF](#)
21. Tang J, Liu DL, Tian WJ, Liu Y, Wu XH, Wang HY, et al. A matched case-control study of diaphragmatic peritonectomy in bulky stages IIIC and IV ovarian cancer. *Int J Gynecol Cancer* 2012;22:E506.
22. Curtin JP, Malik R, Venkatraman ES, Barakat RR, Hoskins WJ. Stage IV ovarian cancer: impact of surgical debulking. *Gynecol Oncol* 1997;64:9-12.
[PUBMED](#) | [CROSSREF](#)
23. Redman JR, Petroni GR, Saigo PE, Geller NL, Hakes TB. Prognostic factors in advanced ovarian carcinoma. *J Clin Oncol* 1986;4:515-23.
[PUBMED](#) | [CROSSREF](#)
24. Fanfani F, Fagotti A, Gallotta V, Ercoli A, Pacelli F, Costantini B, et al. Upper abdominal surgery in advanced and recurrent ovarian cancer: role of diaphragmatic surgery. *Gynecol Oncol* 2010;116:497-501.
[PUBMED](#) | [CROSSREF](#)
25. Chéreau E, Ballester M, Selle F, Cortez A, Pomel C, Darai E, et al. Pulmonary morbidity of diaphragmatic surgery for stage III/IV ovarian cancer. *BJOG* 2009;116:1062-8.
[PUBMED](#) | [CROSSREF](#)
26. Devolder K, Amant F, Neven P, van Gorp T, Leunen K, Vergote I. Role of diaphragmatic surgery in 69 patients with ovarian carcinoma. *Int J Gynecol Cancer* 2008;18:363-8.
[PUBMED](#) | [CROSSREF](#)
27. Tozzi R, Giannice R, Cianci S, Tardino S, Campanile RG, Gubbala K, et al. Neo-adjuvant chemotherapy does not increase the rate of complete resection and does not significantly reduce the morbidity of Visceral-Peritoneal Debulking (VPD) in patients with stage IIIC-IV ovarian cancer. *Gynecol Oncol* 2015;138:252-8.
[PUBMED](#) | [CROSSREF](#)
28. Tozzi R, Gubbala K, Majd HS, Campanile RG. Interval laparoscopic en-bloc resection of the pelvis (L-EnBRP) in patients with stage IIIC-IV ovarian cancer: Description of the technique and surgical outcomes. *Gynecol Oncol* 2016;142:477-83.
[PUBMED](#) | [CROSSREF](#)
29. Soleymani Majd H, Ferrari F, Manek S, Gubbala K, Campanile RG, Hardern K, et al. Diaphragmatic peritonectomy vs. full thickness resection with pleurectomy during visceral-peritoneal debulking (VPD) in 100 consecutive patients with stage IIIC-IV ovarian cancer: a surgical-histological analysis. *Gynecol Oncol* 2016;140:430-5.
[PUBMED](#) | [CROSSREF](#)
30. Eisenkop SM, Spirtos NM. What are the current surgical objectives, strategies, and technical capabilities of gynecologic oncologists treating advanced epithelial ovarian cancer? *Gynecol Oncol* 2001;82:489-97.
[PUBMED](#) | [CROSSREF](#)
31. Tozzi R, Ferrari F, Nieuwstad J, Campanile RG, Soleymani Majd H. Tozzi classification of diaphragmatic surgery in patients with stage IIIC-IV ovarian cancer based on surgical findings and complexity. *J Gynecol Oncol* 2020;31:e14.
[PUBMED](#) | [CROSSREF](#)
32. Aletti GD, Dowdy SC, Podratz KC, Cliby WA. Surgical treatment of diaphragm disease correlates with improved survival in optimally debulked advanced stage ovarian cancer. *Gynecol Oncol* 2006;100:283-7.
[PUBMED](#) | [CROSSREF](#)
33. Kapnick SJ, Griffiths CT, Finkler NJ. Occult pleural involvement in stage III ovarian carcinoma: role of diaphragm resection. *Gynecol Oncol* 1990;39:135-8.
[PUBMED](#) | [CROSSREF](#)
34. Chéreau E, Ballester M, Lesieur B, Selle F, Coutant C, Rouzier R, et al. Complications of radical surgery for advanced ovarian cancer. *Gynecol Obstet Fertil* 2011;39:21-7.
[PUBMED](#)
35. Eisenhauer EL, D'Angelica MI, Abu-Rustum NR, Sonoda Y, Jarnagin WR, Barakat RR, et al. Incidence and management of pleural effusions after diaphragm peritonectomy or resection for advanced mullerian cancer. *Gynecol Oncol* 2006;103:871-7.
[PUBMED](#) | [CROSSREF](#)
36. Gadducci A, Tana R, Landoni F, Ferrari F, Peiretti M, Perrone F, et al. Analysis of failures and clinical outcome of advanced epithelial ovarian cancer in patients with microscopic residual disease at second-look reassessment following primary cytoreductive surgery and first-line platinum-based chemotherapy. *Eur J Gynaecol Oncol* 2013;34:213-7.
[PUBMED](#)

37. Chéreau E, Rouzier R, Gouy S, Ferron G, Narducci F, Bergzoll C, et al. Morbidity of diaphragmatic surgery for advanced ovarian cancer: retrospective study of 148 cases. *Eur J Surg Oncol* 2011;37:175-80.
[PUBMED](#) | [CROSSREF](#)
38. Dowdy SC, Loewen RT, Aletti G, Feitoza SS, Cliby W. Assessment of outcomes and morbidity following diaphragmatic peritonectomy for women with ovarian carcinoma. *Gynecol Oncol* 2008;109:303-7.
[PUBMED](#) | [CROSSREF](#)
39. Soleymani Majd H, Ferrari F, Gubbala K, Campanile RG, Tozzi R. Latest developments and techniques in gynaecological oncology surgery. *Curr Opin Obstet Gynecol* 2015;27:291-6.
[PUBMED](#) | [CROSSREF](#)