CASE REPORT – OPEN ACCESS

International Journal of Surgery Case Reports 51 (2018) 404–408

Contents lists available at ScienceDirect

International Journal of Surgery Case Reports

journal homepage: www.casereports.com

Hepatic myomatous angiomyolipoma diagnosedpreoperatively from specific imaging features: A case report

Yuhki Sakuraoka[a,*], Takashi Suzuki[a], Gennki Tanaka[a], Takayuki Shimizu[a], Takayuki Shiraki[a], Park Kyongha[a], Shozo Mori[a], Yukihiro Iso[a], Masato Kato[a], Taku Aoki[a], Keiichi Kubota[a], Hidetsugu Yamagishi[b], Yasukazu Shioyama[c]

[a] Second Department of Surgery, Dokkyo Medical University, 880 Kitakobayashi, Mibu, Tochigi 321-0293, Japan
[b] Department of Diagnostic Pathology, Dokkyo Medical University, 880 Kitakobayashi, Mibu, Tochigi 321-0293, Japan
[c] Department of Radiology, Dokkyo Medical University, 880 Kitakobayashi, Mibu, Tochigi 321-0293, Japan

ARTICLE INFO

Article history:
Received 24 July 2018
Received in revised form 6 September 2018
Accepted 12 September 2018
Available online 17 September 2018

Keywords:
Hepatic angiomyolipoma
Laparoscopic liver resection

ABSTRACT

INTRODUCTION: Hepatic angiomyolipoma is a rare tumour and is difficult to obtain the accurate diagnosis preoperatively because the imaging features are similar to hepatocellular carcinoma.
PRESENTATION OF CASE: We present a case study of an 80-year old woman with a liver tumour measuring 6.2 cm × 6.0 cm. We were able to diagnose the tumour preoperatively as a rare hepatic myomatous angiomyolipoma based on the presence of early venous return evident on angiography and small low-intensity areas corresponding to fat within the tumour revealed by out-of-phase EOB-MRI. The tumour was removed by minimally invasive surgery and our preoperative diagnosis was confirmed by positive immunoreactivity for both angiomyolipoma-specific human melanoma black 45 and smooth muscle cell positivity for melanin.
DISCUSSION: We consider that the information obtained in this case will be useful for preoperative diagnosis of other hepatic angiomyolipomas, thus facilitating more appropriate and less invasive surgery and improving the overall outcome.
CONCLUSION: Hepatic myomatous angiomyolipoma is a rare tumour. We illustrated the two specific imaging features to diagnose it preoperatively.
© 2018 The Authors. Published by Elsevier Ltd on behalf of IJS Publishing Group Ltd. This is an open access article under the CC BY-NC-ND license (http://creativecommons.org/licenses/by-nc-nd/4.0/).

1. Introduction

Angiomyolipoma (AML) is a unique and rare tumour containing varying percentages of blood vessels, smooth muscle, and adipose cells [1]. These tumours generally arise in the kidneys [2], but can also affect several other organs, including the liver, albeit less frequently [3,4]. Hepatic AML was first reported by Ishak et al. in 1976 [5], and the first case in Eastern Asia was reported in Japan by Kawarada et al. in 1983 [3]. Around 120 cases have now been reported worldwide, and the majority have been defined as benign, only a few showing marginal malignant potential [6,7]. Despite this, invasive liver resection for potentially malignant lesions can rarely be avoided for hepatic AML because its clinical characteristics demonstrated by preoperative imaging are similar to those of malignant hepatocellular carcinoma (HCC). Generally, differential diagnosis can only be achieved postoperatively based on immunohistochemical staining of tissue sections for human melanoma black 45 (HMB-45) and melanin (Melan-A) [8,9]. More accurate and effective imaging techniques would be highly valuable for characterization of focal solid hepatic lesions, and in fact a few case studies have reported that more informative surgical decisions can be made on the basis of magnetic resonance imaging (MRI) and angiography in this area [10–12]. Here we present a rare case of hepatic myomatous AML, which we identified preoperatively based on certain features demonstrated by MRI and angiography. The work has been reported in line with the SCARE criteria [13].

2. Presentation of case

An 80-year-old woman was admitted to our institute with a feeling of abdominal distension. Abdominal ultrasound (US) revealed a large liver tumour located in the lateral segment. The patient had no history of liver disease or hepatitis and did not drink alcohol. A range of diagnostic tests and examinations were carried out to evaluate the possibility of malignancy. Hepatitis B

Abbreviations: AML, angiomyolipoma; HMB-45, human melanoma black 45; Melan-A, melanin polyclonal antibody; EOB-MRI, gadolinium-ethoxybenzyl-diethylenetriamine pentaacetic acid- enhanced magnetic resonance imaging; MRI, magnetic resonance imaging; US, ultrasound; AFP, alpha-foetoprotein; PIVKA II, vitamin K absence or antagonist-2; IVC, inferior vena cava.

* Corresponding author.
E-mail address: sakuraoka812@gmail.com (Y. Sakuraoka).

https://doi.org/10.1016/j.ijscr.2018.09.022
2210-2612/© 2018 The Authors. Published by Elsevier Ltd on behalf of IJS Publishing Group Ltd. This is an open access article under the CC BY-NC-ND license (http://creativecommons.org/licenses/by-nc-nd/4.0/).

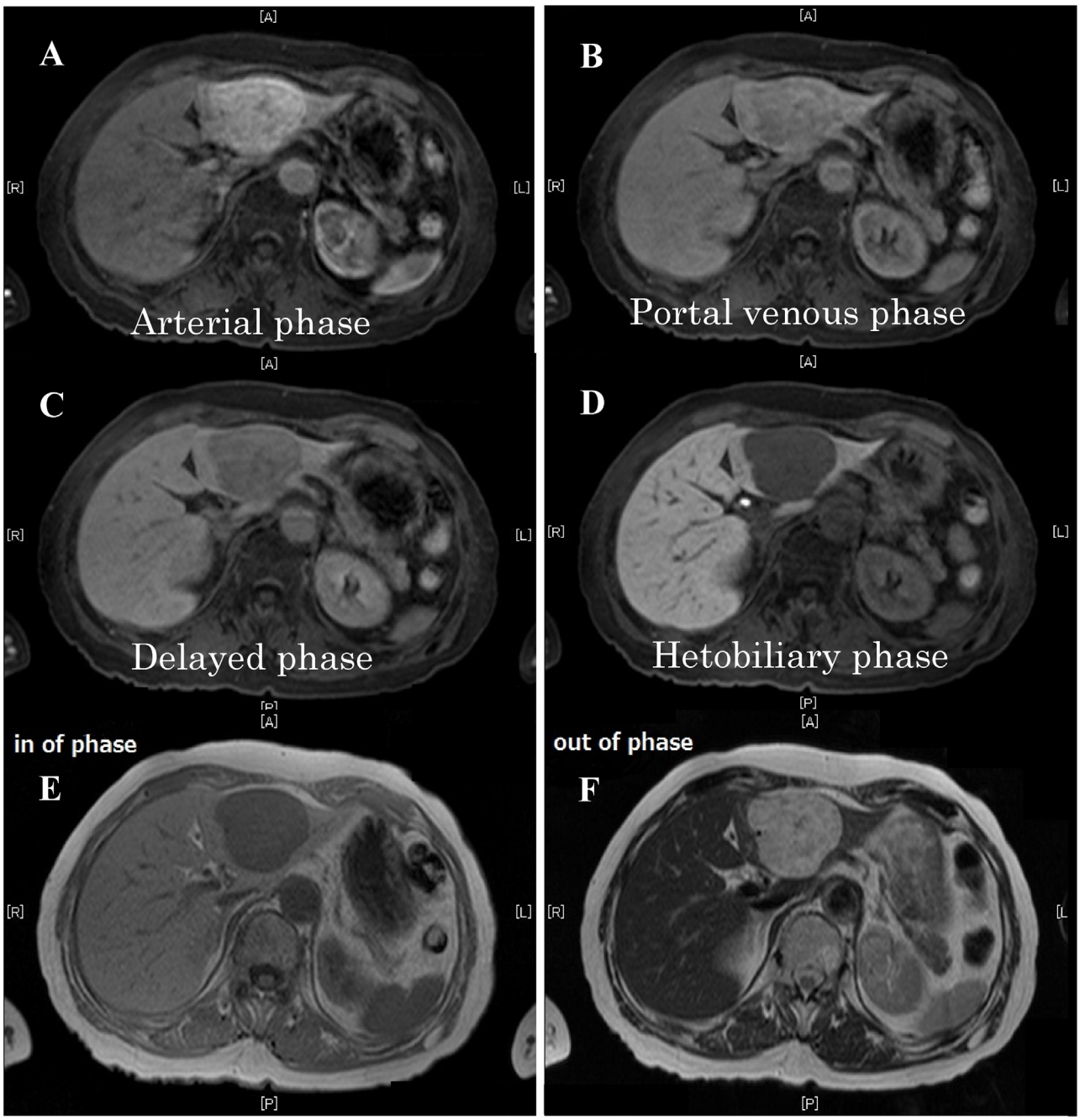

Fig. 1. EOB-MRI showed a hepatic mass with early-phase hyperattenuation and portal-phase hypoattenuation with gradually wash out the medium (Fig. 1A and B). This was followed by a decreasing the tumour signal in the delayed phase. The hepatobiliary phase showed a wash-out pattern and low signal, which was hypoattenuation, measuring 6.2 cm × 6.0 cm (Fig. 1C and D). The opposed phase of EOB-MRI revealed high intensity of whole the tumour with small low intensity inside the tumour.

surface antigen and anti-hepatitis C antibody were negative. Laboratory tests revealed a white blood cell count of 3000/mm^3, haemoglobin 12.5 g/dL, platelet count 17.9 × 10^4/mm^3, albumin 3.2 g/dL, total bilirubin 0.5 mg/dL, and direct bilirubin 0.3 mg/dL. Serum levels of transaminase, alpha-foetoprotein (AFP) and protein induced by vitamin K absence or antagonist- 2 (PIVKA II) were within the normal ranges (Table 1). Gadolinium-ethoxybenzyl-diethylenetriamine pentaacetic acid enhanced magnetic resonance imaging (EOB-MRI) showed a hepatic mass with early-phase hyperattenuation and portal-phase hypoattenuation with gradual wash-out in the lateral segment (Fig. 1A and B). This was followed by a decrease of the tumour signal in the delayed phase. The hepatocyte phase showed a typical wash-out pattern and low signal, indicating a hypo-enhanced lesion, measuring 6.2 cm × 6.0 cm (Fig. 1C and D). In addition, out-of-phase EOB-MRI revealed high intensity in the whole tumour (Fig. 1E), with several remarkable small areas of low intensity (Fig. 1F). This pattern indicated that, overall, the tumour contained a minimal amount of fluid but a small amount of fat, suggesting either hepatic AML or hepatocellular carcinoma including some fat components. Subsequent angiography revealed the tumour as a well circumscribed hypervascular mass (Fig. 2A) with central vessels, and notably a drainage vein from the tumour to the inferior vena cava (IVC) (Fig. 2B). This latter feature is known as early venous return and is specific to AML [14]. Therefore, on the basis of imaging alone, we diagnosed this tumour as AML containing a small amount of fat. However, given the large size of

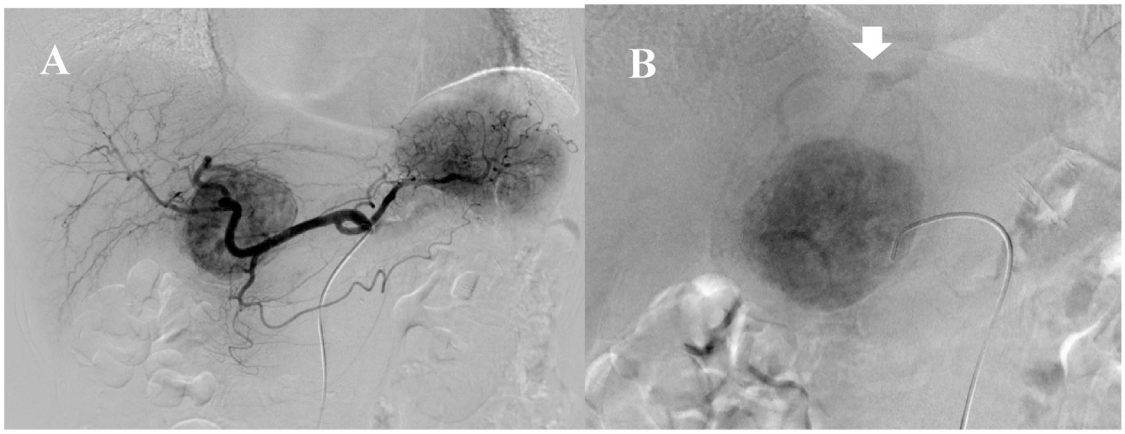

Fig. 2. On angiography, the tumour was shown as a circumscribed hypervascular mass (Fig. 2A) and central vessels were detected, which illustrated drainage vein from tumour to IVC (Fig. 2B).

Fig. 3. The tumour measured 6.3 cm × 6.0 cm in diameter, distinct boundaries, no capsule, light brown tone, solid mild accompanying bleeding inside. Histologically, the tumor was mainly composed of smooth muscle cells and contained small amounts of adipose cells and blood vessels.

Table 1
Laboratory data.

Variables	Figures
HBsAg	negative
HCVAb	negative
AST (U/L)	18
ALT(U/L)	14
γ-GTP (mU/mL)	166
ALP (U/L)	32
T-Bil (mg/dL)	0.5
Alb (mg/dL)	3.2
AFP (ng/mL)	3.0
PIVKA II (U/mL)	19

Abbreviations, HBsAg; hepatitis B virus surface antigen, HCVAb; hepatitis C virus antibody, AST: Aspartate Aminotransferase, ALT: alanine aminotransferase, γ-GTP: γ-glutamyl transpeptidase, ALP: alkaline phosphatase, T-Bil: total bilirubin, Alb; albumin, AFP; arfapheto protein, PIVKA II; vitamin K absence or antagonist- 2.

the tumour and the low but notable probability of malignancy [15], we decided to remove the tumour using minimally invasive surgery after obtaining informed consent from the patient. Laparoscopic resection of the lateral segment containing the tumour was performed. The light brown tumour measured 6.2 cm × 6.0 cm and had no capsule but distinct boundaries, with mild internal hemorrhage (Fig. 3). Histologically, hematoxylin and eosin staining showed that the tumour was composed mainly of smooth muscle cells, with only small numbers of adipose cells and blood vessels (Fig. 4). Immunohistochemical staining revealed that the tumour had no evident hepatocyte structure, but was strongly positive for HMB-45, which is the most sensitive marker of AML, and the smooth muscle cells were positive for Melan-A (Fig. 5). Consequently, our final diagnosis was myomatous-type hepatic AML, which was the same as our preoperative diagnosis. The patient was discharged 8 days after the operation and the postoperative period was uneventful. She is currently doing well after 3 years of follow-up.

3. Discussion

In this case study, we were able to diagnose a hepatic myomatous AML preoperatively based on both the tumour composition and the presence of early venous return, identified by MRI and

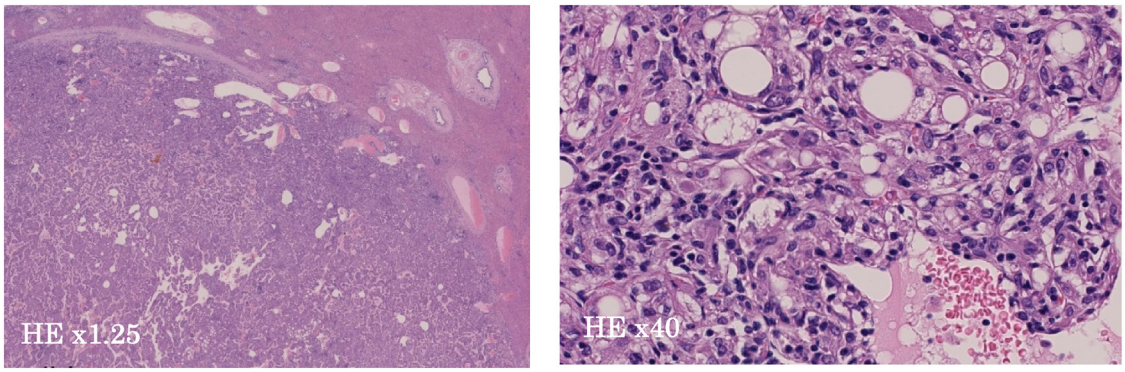

Fig. 4. On hematoxylin-Eosin staining, the tumour was mainly composed of smooth muscle cells and contained small amounts of adipose cells and blood vessels.

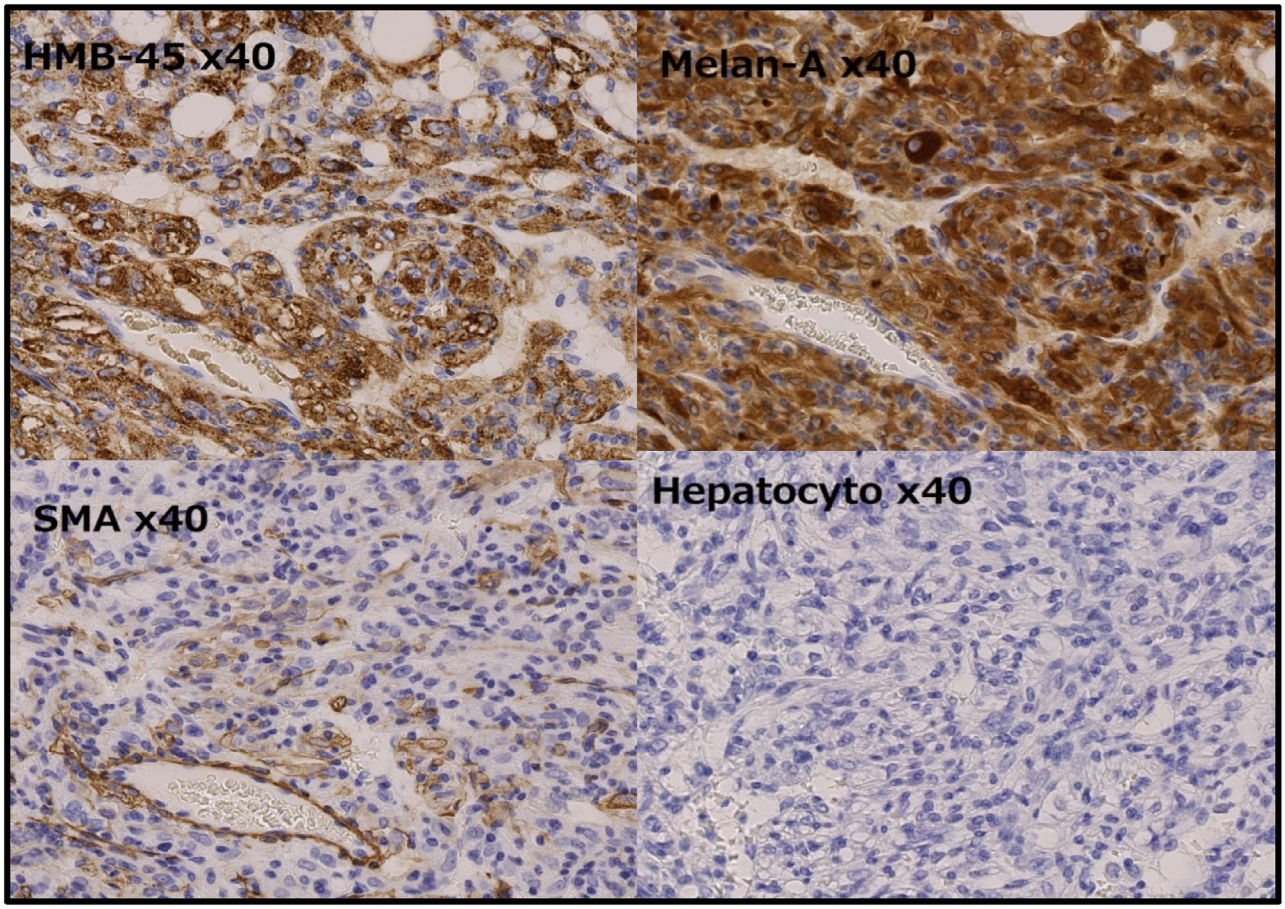

Fig. 5. On immunohistochemical staining, the tumour was negative for hepatocyte structure, but positive for human melanin black 45(HMB-45) and the smooth muscle cells were positive for a melanocytic cell-specific monoclonal antibody (Melan-A).

angiography, respectively. AML tumours are composed of three components – fat, smooth muscle and blood vessels – and they can be classified into four tumour types based on the predominance of these components. The most common is the mixed or lipomatous type, in which the tumour contains more than 70% fat. The others include the angiomatous, epithelioid, and myomatous types, the latter being the type reported here and containing less than 10% fat [1,6]. This small fat component makes it more difficult to distinguish AML from hepatocellular carcinoma, as when fat is the dominant component, some distinctive imaging features are discernible, thus increasing the possibility of a differential diagnosis. In spite of this, we were able to favour a diagnosis of AML from the EOB-MRI findings based on both the lack of a fluid component within the tumour, as identified by the in-phase image, as well as the presence of a small fat component, as identified by the out-of-phase image. These MRI results were subsequently confirmed by immunohistochemical staining, the tumour being negative for a hepatocyte marker, thus ruling out HCC, but positive for HMB-45 and the smooth muscle cells were positive for Melan-A, which is only weakly to moderately positive in epithelioid AML [16], thereby indicating that the tumour was of the myomatous type.

We therefore suggest that EOB-MRI is a valuable modality for clarifying the tumour components, thus allowing distinction between hepatic AML and HCC [17]. Moreover, AML has been shown to exhibit early intense contrast enhancement on MRI, which peaks later than that of hepatocellular carcinoma [18]. If we had compared the timing of the contrast in early-phase MRI, we might have obtained data on a further imaging feature that would have contributed to the diagnosis of AML.

Another distinctive feature identified in the tumour that led to the preoperative diagnosis was the presence of early venous return, which was identified via angiography, and has previously been reported as a typical feature of AML [14,19]. Iwao et al. reported the presence of anomalous circulatory pathways in tissue sections from three out of four of the hepatic AML cases they studied. Specifically, there were many well-defined thick-walled vessels, such as arteries, that entered the tumour, and were directly connected within the tumour to thin-walled vessels, resembling arteriovenous fistulae. These thin-walled vessels were in turn connected directly to the hepatic vein. These histological features suggest that the rich arterial flow into the tumour is rapidly drained into the hepatic vein via arteriovenous connections within the tumour [19]. To our knowledge, however, the present case study is the first to have demonstrated both of these unique characteristic clearly, and therefore we believe that our findings would be informative for differential diagnosis of AML from other hypervascular liver tumours.

In addition to our imaging results, the laboratory data from the patient's blood sample also contributed to the preoperative diagnosis; the fact that the tumour markers we tested were all within the normal ranges made hepatocellular carcinoma unlikely. In the past, when AML tumours were considered benign, diagnosis by transdermal needle biopsy was standard, but given the potential for malignancy, an accurate diagnosis from imaging and laboratory data is desirable.

Despite the accurate preoperative diagnosis in the present case, we were unable to avoid a lateral liver segmentectomy, as the tumour occupied the entire lateral segment even though partial liver resection is sufficient for AML. In addition, despite the chal-

lenges involved in accurate preoperative diagnosis of AML, there is a chance for selection of a less invasive and more appropriate surgical procedure, thus potentially improving the overall outcome. Therefore we consider that the data from the present case study add important information that would allow further preoperative diagnoses of AML in the future.

Conflicts of interest

We have no financial relationships to disclose and there are not any financial and personal relationships with other people or organisations about all authors.

Sources of funding

We have no financial relationships to disclose and there is not any sponsor with funding.

Ethical approval

We obtained ethical certification with the approval number 1808-002 from ethic committee in Dokkyo Medical University.

Consent

Written informed consent was obtained from the patient for publication of this case report and accompanying images. A copy of the written consent is available for review by the Editor-in-Chief of this journal on request.

Authors contribution

Yuhki Sakuraoka: Literature review and writing the article.

Gennki Tanaka, Takayuki Shimizu, Takayuki Shiraki and Park Kyongha mainly managed the patient and led the patient to discharge earlier as well as they helped author collect the clinical data smoothly.

The other authors (Shozo Mori, Yukihiro Iso, Masato Kato and Taku Aoki) significantly contributed to revising the manuscript. Thanks to their suggestion, the author designed and organized this article.

Keiichi Kubota: Editing the article mainly and he per-formed the surgery. He is the chief professor of our department.

Hidetsugu Yamagishi; the pathologist detected the specific pathological features and provided all microscopic pictures.

Yasukazu Shioyama; the radiologist contributed to identify the specific features of imaging.

Registration of research studies

researchregistry4258.

Guarantor

Dr Yuhki Sakuraoka.

Provenance and peer review

Not commissioned, externally peer-reviewed.

References

[1] W.M. Tsui, R. Colombari, B.C. Portmann, et al., Hepatic angiomyolipoma: a clinicopathologic study of 30 cases and delineation of unusual morphologic variants, Am. J. Surg. Pathol. 23 (1999) 34–48.
[2] J.P. Zeng, J.H. Dong, W.Z. Zhang, J. Wang, et al., Hepatic angiomyolipoma: a clinical experience in diagnosis and treatment, Dig. Dis. Sci. 55 (2010) 3235–3240.
[3] I. Dalle, R. Sciot, R. de Vos, et al., Malignant angiomyolipoma of the liver: a hitherto unreported variant, Histopathology 36 (5) (2000) 443–450.
[4] L. Insabato, G. De Rosa, L.M. Terracciano, et al., Primary monotypic epithelioid angiomyolipoma of bone, Histopathology 40 (3) (2002) 286–290.
[5] K.G. Ishak, Mesenchymal tumors of the liver, in: K. Okuda, R.L. Peters (Eds.), Hepatocellular Carcinoma, John Wiley and Sons, New York, 1976, pp. 247–307.
[6] M. Takahara, Y. Miyake, K. Matsumoto, et al., A case of hepatic angiomyolipoma difficult to distinguish from hepatocellular carcinoma, World J. Gastroenterol. 15 (2009) 2930–2932.
[7] P. Chen, T. Yuan, H. Liu, Hepatic angiomyolipoma mimicking hepatic clear cell carcinoma, J. Int. Med. Res. 37 (2009) 257–263.
[8] A.A. Petrolla, W. Xin, Hepatic angiomyolipoma, Arch. Pathol. Lab. Med. 132 (2008) 1679–1682.
[9] A. Nonomura, Y. Mizukami, N. Takayanagi, et al., Immunohistochemical study of hepatic angiomyolipoma, Pathol. Int. 46 (1996) 24–32.
[10] D. Le Bihan, E. Breton, D. Lallemand, et al., Separation of diffusion and perfusion in intravoxel incoherent motion MR imaging, Radiology 168 (1988) 497–505.
[11] T. Namimoto, Y. Yamashita, S. Sumi, et al., Focal liver masses: characterization with diffusion-weighted echo-planar MR imaging, Radiology 204 (1997) 739–744.
[12] M.R. Onur, M. Çiçekçi, A. Kayalı, et al., The role of ADC measurement in differential diagnosis of focal hepatic lesions, Eur. J. Radiol. 81 (2012) e171–176.
[13] R.A. Agha, A.J. Fowler, A. Saetta, et al., The SCARE Statement: consensus-based surgical case report guidelines, Int. J. Surg. 34 (2016) 180–186.
[14] K. Kuramoto, T. Beppu, T. Namimoto, et al., Hepatic angiomyolipoma with special attention to radiologic imaging, Surg. Case Rep. 1 (1) (2015) 38.
[15] W.T. Wang, Z.Q. Li, G.H. Zhang, et al., Liver transplantation for recurrent posthepatectomy malignant hepatic angiomyolipoma: a case report, World J. Gastroenterol. 21 (12) (2015) 3755–3758.
[16] G. Tryggvason, S. Blöndal, R.D. Goldin, et al., Epithelioid angiomyolipoma of the liver: case report and review of the literature, APMIS 112 (9) (2004) 612–616.
[17] N.C. Balci, A. Akinci, E. Akun, et al., Hepatic angiomyolipoma: demonstration by out of phase MRI, Clin. Imaging 26 (6) (2002) 418–420.
[18] T. Ahmadi, Y. Itai, M. Takahashi, et al., Angiomyolipoma of the liver: significance of CT and MR dynamic study, Abdom. Imaging 23 (5) (1998) 520–526.
[19] Y. Iwao, H. Ojima, H. Onaya, et al., Early venous return in hepatic angiomyolipoma due to an intratumoral structure resembling an arteriovenous fistula, Hepatol. Res. 44 (6) (2014) 700–706.

Open Access
This article is published Open Access at sciencedirect.com. It is distributed under the IJSCR Supplemental terms and conditions, which permits unrestricted non commercial use, distribution, and reproduction in any medium, provided the original authors and source are credited.