



## Mini Review

## Iatrogenic parasitic myoma and iatrogenic adenomyoma after laparoscopic morcellation: A mini-review



Natalia Darii<sup>a</sup>, Emil Anton<sup>a,\*</sup>, Bogdan Doroftei<sup>a</sup>, Alin Ciobica<sup>b</sup>, Radu Maftei<sup>a</sup>, Sorana C. Anton<sup>c</sup>, Taymour Mostafa<sup>d</sup>

<sup>a</sup> Department of Gynecology, Cuza Voda Hospital, University of Medicine and Pharmacology Gr T Popa, 700038 Iasi, Romania

<sup>b</sup> Department of Research, Faculty of Biology, Alexandru Ioan Cuza University, B dul Carol I, 700506, no 11, Iasi, Romania

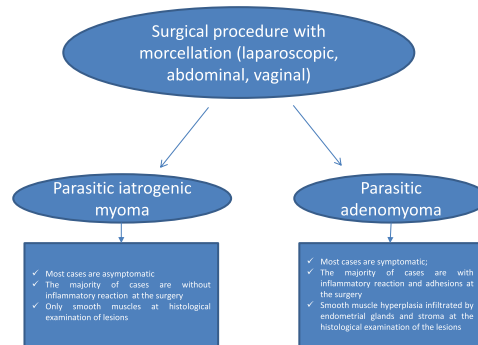
<sup>c</sup> "Grigore T.Popa" University of Medicine and Pharmacy, 16, Universitatii Street, 700115 Iasi, Romania

<sup>d</sup> Department of Andrology and Reproduction, Faculty of Medicine, Cairo University, Al-Saray Street, El Manial Cairo 11956, Egypt

## HIGHLIGHTS

- Parasitic myoma and adenomyoma are two different pathologies.
- Both diseases are iatrogenic conditions developed after morcellation.
- Each entity has different clinical and paraclinical findings.
- The common point of pathogenesis is morcellation.
- Both diseases may be avoided by using in-bag morcellation or by switching to other surgical procedures.

## GRAPHICAL ABSTRACT



## ARTICLE INFO

## Article history:

Received 9 November 2018

Revised 17 April 2019

Accepted 18 April 2019

Available online 19 April 2019

## Keywords:

Parasitic myoma

Iatrogenic adenomyosis

Laparoscopic subtotal hysterectomy

Myomectomy

Morcellation

Clinical characteristics

## ABSTRACT

Laparoscopy is widely recognized as a procedure of choice for gynaecological surgery. Myomectomy and hysterectomy are the most frequently performed surgical procedures in gynaecology. A morcellator is often used in myomectomies or subtotal hysterectomies, but morcellation may cause rare complications, such as parasitic iatrogenic myoma or adenomyoma. To improve patient counselling, proper risk estimation as well as risk factor identification should be acknowledged. This article aimed to review the literature on parasitic myoma and adenomyoma and to compare these diseases in terms of clinical, surgical, and prognostic factors. All published literature (case series and case reports) on iatrogenic myoma and adenomyoma was reviewed using PubMed/MEDLINE and ScienceDirect resources. Despite both conditions having an iatrogenic origin, iatrogenic parasitic myoma and adenomyoma are two different entities in terms of clinical manifestations as well as intraoperative particularities, with a common point: iatrogenic complication. A possible solution to avoid these iatrogenic complications is by using in-bag morcellation or switching to another surgical procedure (e.g., a vaginal or abdominal approach). It is concluded that parasitic myoma and iatrogenic adenomyoma are two different iatrogenic morcellator-related complications. In patients with a history of uterus or myoma morcellation who report pelvic symptoms, iatrogenic parasitic myoma or adenomyoma should be considered in the differential diagnosis.

© 2019 The Authors. Published by Elsevier B.V. on behalf of Cairo University. This is an open access article under the CC BY-NC-ND license (<http://creativecommons.org/licenses/by-nc-nd/4.0/>).

Peer review under responsibility of Cairo University.

\* Corresponding author.

E-mail address: [emil.anton@yahoo.com](mailto:emil.anton@yahoo.com) (E. Anton).

<https://doi.org/10.1016/j.jare.2019.04.004>

2090-1232/© 2019 The Authors. Published by Elsevier B.V. on behalf of Cairo University.

This is an open access article under the CC BY-NC-ND license (<http://creativecommons.org/licenses/by-nc-nd/4.0/>).

## Introduction

Laparoscopy has become the surgical treatment of choice for several benign pathologies [1]. It has many advantages, such as magnification of the pelvis, short hospitalisation, rapid recovery, low rate of infection, and good cosmetic results [2–4]. Additionally, hysterectomy is one of the most common gynaecological procedures, with approximately 600,000 hysterectomies performed per year in the US [5]. Laparoscopic subtotal/supracervical hysterectomy (LASH) is a surgical option when hysterectomy is indicated in the absence of cervical or endometrial malignant pathology [6]. This technique has many advantages, such as low perioperative morbidity, and faster postoperative recovery [7]. However, leiomyoma is still the most common indication for hysterectomy [8,9]. Both LASH and laparoscopic myomectomy are surgical procedures that could be proposed in cases of uterine myoma, depending on the patient's age and their wish to preserve fertility. Both techniques require laparoscopic tissue extraction through small incisions to avoid the need for a mini-laparotomy. Intra-abdominal fragmentation is performed with the use of a morcellator. Since 1993, with the development of the Steiner morcellator [10], several systems of electromechanical morcellation have become available. A rapidly circulating sharp cylinder with a coring knife/cutter at its intra-abdominal end is placed inside the trocar sleeve and is rotated by an electrical micro-engine attached to the trocar. Cylindrical tissue blocks are cut out of the main specimen in a stepwise fashion and removed from the peritoneal cavity through the cannula [11]. Morcellation can induce different sizes of tissue specimens. Fragments that are microscopic or even larger may be unnoticed and may remain in the abdominal cavity, tract incisions, or trocars, resulting in the appearance of an unrecognized pathology such as iatrogenic parasitic myoma (IPM) [12] or iatrogenic adenomyoma (IA) [2,13–16].

The incidence of retained uterine fragments remains unknown because this complication of morcellation is underestimated due to the small series and because the majority of such pathologies are published as case reports. In the largest series, the incidence of IPM was 1.2% [17], and that of IA was 0.57% [13]. In the Van der Meulen et al. [18] review, the incidence was 0.12% to 0.94%. The majority of case reports and series have been published in

the last few decades after electromechanical morcellator introduction. Many types of morcellators (motor coring, motor peeling, or bipolar cutting as the working principle) with four types of blade diameters (12, 13, 15, and 20 mm) and increased morcellation rates (6.2–40.4 g/min) [19] were available from 1993 to 2014 (after the FDA warning concerning morcellator use) [20]. Following this communication regarding power morcellation, the utilization of minimally invasive hysterectomy and morcellation decreased. However, asymptomatic cases of IPM are not reported, and these cases will likely be diagnosed and reported in the next period.

This article aimed to review the literature on parasitic myoma and adenomyoma and to compare these diseases in terms of clinical, paraclinical, surgical, and prognostic factors. Available articles were reviewed using PubMed/ MEDLINE and ScienceDirect resources, and the differences between these two entities were analysed. Thirty-six cases of IPM (13 case reports and 5 case series) and 10 cases of IA (2 case reports and one series) were found (Fig. 1).

## Parasitic myoma [12,15,16,21–34]

Myoma was the initial surgical indication for myomectomy or hysterectomy in all cases of IPM, except in 3 cases in which the initial indication of hysterectomy was not stated. In 7 of 10 cases (70%), when the myoma location was indicated, a posterior location in the uterine wall was cited. Myomectomy was performed for large uterine myomas (>5 cm) in all cases when their size was described (fibroids measuring  $8.3 \pm 2.2$  cm). A myoma size exceeding 6 cm was described in 9 cases (29%); in 25 cases, the data were not available, and in 2 cases, the myoma size was measured at 5 cm (Table 1). The initial surgical procedure (myomectomy/hysterectomy) was performed by laparoscopy in 88.8% of cases ( $n = 32$ ) and by laparotomy in 11% of cases ( $n = 4$ ) in women aged 23–50 years. In the laparoscopic group, 78.8% ( $n = 25$ ) of the procedures were myomectomies, whereas 21.8% ( $n = 7$ ) were hysterectomies (3 cases of total hysterectomy and 4 cases of subtotal hysterectomy). When the laparoscopic approach was performed, an electromechanical morcellator was used in 90% of cases ( $n = 29$ ). In the other 3 cases, manual morcellation with a cold knife was performed. Manual morcellation was described even in the

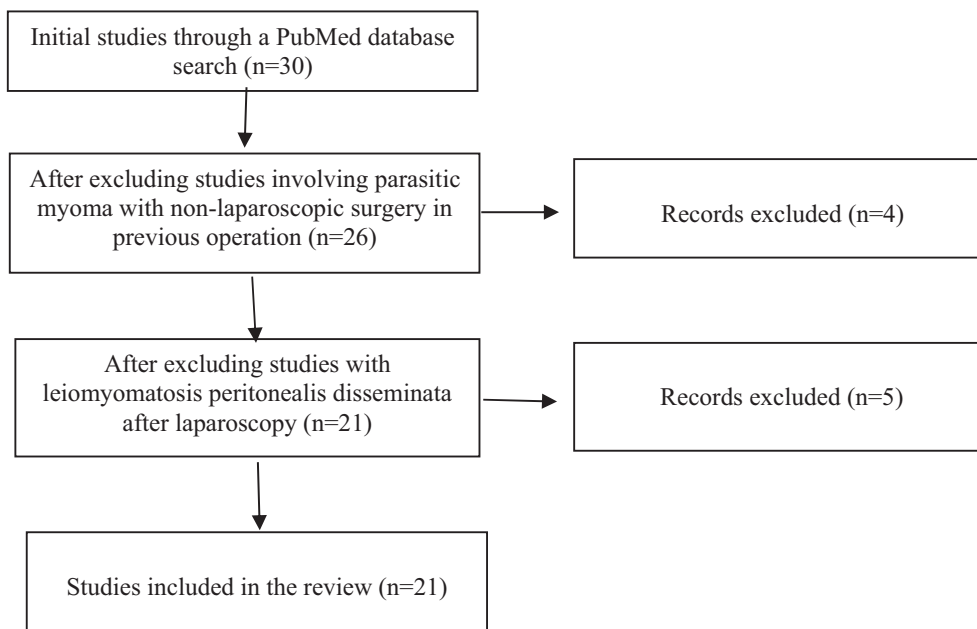


Fig. 1. Flow chart for literature search.

**Table 1**

Initial pathologic characteristics and surgery performed in cases of iatrogenic parasitic myoma and iatrogenic adenomyoma.

References (year)	n	Initial pathology	Myomas n°	Location	Size (cm)	U/M weight	Surgery	Morcellator used
La Coursiere et al. (2005) [16]	1	Myoma	5	NA	6	205 g	LTH	Yes
Paul and Koshy (2006) [21]	1	Myoma	1	Posterior	9	NA	LM	Yes
Rakesh et al. (2007) [22]	1	Myoma	1	NA	NA	NA	LM	Yes
Rakesh et al. (2007) [23]	2	Myoma	1	Posterior	10	390 g > ut	LM > 3 years LTH	Yes
		Myoma	1	Posterior	5	920 g 135 g > ut	LM –8 years LASHnR + excision	Yes
Takeda et al. (2007) [24]	1	Myoma	1	Intraligamental	NA	300 g	LM	Yes
Thian YL et al. (2009) [12]	1	Myoma	1	Posterior	9.7	NA	LM	Yes?
Moon HS et al. (2008) [25]	1	Myoma	1	Posterior	6.3	NA	LM	Yes
Rakesh et al. (2009) [26]	1	Myoma	1	Posterior	10	620 g	LM	Yes
Epstein JH et al. (2009) [27]	1	Myoma	1	Anterior	5	NA	LM	Yes
Wada-Hiraike et al. (2009) [28]	1	Myoma	1	Posterior	9.3	NA	LAM	Cold knife
Kho KA (2009) [29]	12	Myoma		NA		NA	LM, AM	Yes (6) + 2 cold knife
Larrain et al. (2010) [15]	4	Myoma						
	1		1	NA		NA	LM	Yes
	1		1	NA		600 g	LM	Yes
	1					NA	LTH	Yes
	1					NA	LTH	Yes
Cuccinella et al. (2011) [17]	4							
	1	Myoma		NA		NA	LM + 2 years TAH	Yes
	1	Myoma		NA		NA	LM	Yes
	1	Myoma		NA		NA	LM + 2 years TAH	Yes
	1	Myoma		NA		NA	LM	Yes
Sesti F (2011) [30]	1	Myoma	5	NA		NA	GLM	Cold knife
Yamazume et al. (2012) [31]	1	Myoma	10	Fundal		NA	AM	No
Takeda A (2012) [32]	1	Myoma	1	Posterior	11	262 g	GLM	Cold knife
Leren et al. (2012) [33]	3	NA	NA	NA	NA	NA	LASH	Yes
		UtrosCT	1	NA			LH	Yes
Ehdaivand et al. (2014) [34]	2	Myoma	NA	NA	NA	NA	LM	Yes

abdominal approach (n = 3). The interval between the initial surgery and the diagnosis of IPM or IA varied depending on symptoms. For asymptomatic cases, the average time was longer (6.2 years) than that for the symptomatic case (4.2 years). In the Kho and Nezat [29] series, the average time between the previous abdominal surgery and surgery during which an IPM was diagnosed was 75 months. In this review overall, 63.8% of patients presenting with IMP were asymptomatic at the time of the diagnosis, while Van der Meulen et al. [35] reported that 21.7% of patients were asymptomatic, in both parasitic myoma and adenomyoma cases. Common symptoms of IPM include abdominal discomfort, fatigue, backache, dyspareunia, and urinary/bowel complaints.

There was no relationship between the size of IPM and symptomatic patients, as asymptomatic cases were described with 8–10-cm parasitic myomas [12,23,30], and a 15-mm parasitic myoma was described as causing pelvic or abdominal pain [17]. Pain was usually described in cases of IPM located in the pelvic region [15,16,26]. These iatrogenic lesions were identified by vaginal ultrasound and more accurately by magnetic resonance imaging (MRI). Masses similar to uterine myoma were observed in the cases of IPM.

The location of these iatrogenic pathologies may be on any abdominal organ or peritoneal area, especially if an electromechanical morcellator is used. However, the majority of IPMs were found in the pelvis (67.7%), along the gastrointestinal tract, and less frequently in the upper abdomen, along the urinary tract, or along the trocar or abdominal scar. Cuccinella et al. [17] identified the pelvic location of IPMs by movement of the fragments to the lower part of the abdomen. Kho and Nezat [29] noted that the most likely locations of IPMs are in the pelvis. The number of IPMs varies depending on the type of morcellation. After mechanical morcellation, one lesion is usually cited. In cases in which an electrical morcellator is used, the number can reach up to seven or more. This difference could be explained by the fact that when manual morcellation is used, the tissue fragments are larger and can be seen easily, which is not the case in electromechanical morcellation

due to the force of the rotating blade, causing very small fragments to be dispersed away from the field. The size of nodules varies from 3 mm to 30 cm.

Concerning intraoperative macroscopic analysis of the lesions, the majority of IPMs were not described as causing an inflammatory reaction or adhesions (69.2%, n = 18/26 of available data). In two case reports and in one series, there were no available data regarding the adhesions. All cases of IPM were confirmed by histological findings to be composed only of smooth muscles (Table 2). The pathogenesis of IPM is still not clearly understood. Pieces of the endometrium, such as the myometrium, can implant and proliferate [36]. According to Kho and Nezat [29], the greater risk factor for the development of parasitic myomas is the presence of a uterine leiomyoma. It was shown that myomas >6.5 cm had a significantly higher proportion of abnormal karyotypes than myomas <6.5 cm (75% vs. 34%) and subsequently more mitotic activity [37,38]. This finding suggests that small fragments coming from a myoma that is >6.5 cm could have a higher implantation and growth potential. In this review, 29% (9 cases) of the laparoscopic myomectomies that were performed were for fibroids >6 cm, whereas in 2 cases, the size of the fibroid was <6 cm; in 20 cases, no data were provided. A posterior location of uterine myomas was frequently described for the previous laparoscopic myomectomy, and this position may have made the surgical intervention more difficult, contributing to the formation of IPMs.

As with uterine myoma [39], the theory of response to injury may explain the pathogenesis of IPM. Experimental data on mice showed that primary myoma cells are able to form xenograft tumour. Associated stromal cells, such as myoma-derived fibroblasts or microvasculature endothelial cells, could account for tumour formation by providing a supportive tumour stroma or a microvascular network [40]. Huang et al. [41] suggested that increased angiogenesis and cell proliferation occur in implanted xenografted myomas (compared with primary myomas) and are involved in the pathogenesis of iatrogenic myomas.

**Table 2**  
Clinical characteristics and intraoperative data for iatrogenic parasitic myoma.

References (Year)	Symptoms	Interval (years)	Iatrogenic myomas N°	Location of iatrogenic lesions	Size of the developed nodules	CA125	Adhesions	Anatomopathology
LaCoursiere et al. (2005) [16]	DPP, pelvic pain, dysuria	1	5	Pelvis	0.4–0.7 cm	NA	Yes	Leiomyoma, fibrosis, cervical and endocervical tissue
Paul and Koshy (2006) [21]	DPP, pelvic pain	2, 5	Nr	Parietal peritoneum at the trocar site, uterine fundus, paracolic gutter	NA	NA	NA (no)	Leiomyoma
Rakesh et al. (2007) [22]	Asymptomatic	5	2	Right dome diaphragm + rectovaginal septum	5 cm, 3 cm	NA	No	Leiomyoma
Rakesh et al. (2007) [23]	Pain and mass	3	3	Pelvis > liver, sigmoid colon broad pedicle; lateral pelvic wall; urinary bladder left paraumbilical region; sigmoid colon and left lateral abdominal wall	15 cm, 7 cm, 8 cm			Leiomyoma
Takeda et al. (2007) [24]	Abdominal mass Asymptomatic	6 6	1 1	Omentum, round ligament, vesicouterine peritoneum, peritoneum	10 cm NA	NA		Leiomyoma Leiomyoma
Thian YL et al. (2009) [12]	Asymptomatic	1	50	Right adnexa, umbilical nodule, peritoneal cavity, colon	8, 4, 2 cm	N		Leiomyomas
Moon HS et al. (2008) [25]	Mass, left lower quadrant of the abdomen	3	1	Abdominal wall (subfascial area)	3 cm	NA	No	Leiomyoma
Rakesh S et al. (2009) [26]	Abdominal pain	3	2	Pouch D + right lumbar region	6, 7 cm	NA		Leiomyoma
Epstein JH et al. (2009) [27]	Pelvic pain	1, 5	2	Omentum, sigmoid	3, 8 cm	NA	NA (no)	Leiomyoma
Wada-Hiraike et al. (2009) [28]	Mass, left lower quadrant of the abdomen	4	1	Rectus muscle at the suprapubic incisional scar	10 cm	NA		Desmoid tumour
Kho KA (2009) [29]					NA	NA		
Larrain et al. (2010) [15]	Pelvic mass Pelvic mass Pelvic pain, pelvic mass	16 8 6	1 1 1	Pouch of Douglas Pouch of Douglas Presacral peritoneum	3 cm 7 cm 6 cm	NA NA N	No No Yes	Calcified leiomyoma Leiomyoma Adenomyosis
Cuccinella et al. (2011) [17]	Vaginal mass Pelvic pain, abdominal masses	3 7	1 3	Vaginal scar	5 cm 15–60 mm	NA NA	No NA (no)	Leiomyoma Leiomyoma
	Asymptomatic	2	1	Pelvic peritoneum, along the gastrointestinal tract	18 mm	NA	NA (no)	Leiomyoma
	DPP, left side tenderness	9	5		4–35 mm	NA	NA (no)	Leiomyoma
Sesti F (2011) [30]	Asymptomatic Palpable masses of the abdominal wall	6 10	2 6	Abdominal wall: umbilical area, rectus muscles, left abdominal region	43–60 mm 0.3–10 cm	NA NA	NA (no) No	Leiomyoma Leiomyoma
Yanazume et al. (2012) [31]	Painful subcutaneous mass	16	1	Abdominal subcutaneous adipose tissue	12 cm	N	No	Leiomyoma
Takeda A (2012) [32]	Asymptomatic	2	1	Vesicouterine pouch	1, 4 cm	NA	NA (no)	Leiomyoma
Leren et al. (2012) [33]	Pain, mass in the abdomen	3, 6–8	1–12	Peritoneum, abdominal wall, colon transversum, caecum, in the pelvic abdominal wall, rectum, cervix and small intestine, pouch of Douglas	1–11 cm	N51 kU/L	NoNo Yes	Leiomyoma Leiomyoma + adenomyoma
Ehdaivand et al. (2014) [34]	Asymptomatic	0, 15–1.7	1 NA	Omentum Peritoneal sites	NA NA	NA	Yes No	Leiomyoma Leiomyoma

LM, laparoscopic myomectomy; LTH, laparoscopic total hysterectomy; LASHnR, laparoscopic subtotal nonradical hysterectomy; LAM, laparoscopically assisted myomectomy; GLM, gasless laparoscopic myomectomy; AM, abdominal myomectomy; NA, not available; N, normal; UTROSCT, uterine tumour resembling ovarian sex cord tumour.

Kho and Nezat [29] described the parasitic myoma as follows: after administration of gonadotropin-releasing hormone, which restricts blood supply to the myoma, a subserosal or pedunculated myoma may lose its uterine blood supply and parasitise to an adjacent organ. In the review of Van der Meulen et al. [18], the duration of steroid exposure seems to be a risk factor that contributes to the development of either IPM or IA. All patients in this review had a premenopausal status at the time of the first surgery (myomectomy or hysterectomy). Even if leiomyomatosis peritonealis disseminata is described after a surgical procedure, it may not be an iatrogenic condition. In this pathology, the pathogenesis differs from the clinical picture, and the evolution is different from IPM. Regarding this pathology that developed after a surgical procedure, in the majority of cases, morcellation was not performed; other theories could explain this pathology as being caused by hormonal or genetic factors [42]. Even in asymptomatic patients, removal of this iatrogenic pathology is necessary because the risk of malignant transformation is higher than that with uterine myoma (2–5% [43] versus 2.33–3.6 per 1000 hysterectomies for uterine myoma [44]), as genetic disorders in this tumour are more frequent.

### Iatrogenic adenomyoma [13–15]

All described cases of IA (n = 10) were found after total (n = 1) or subtotal hysterectomy (n = 9) with morcellation (Table 3). The hysterectomy was performed for a large uterus with myomas or a large uterus with myomas and adenomyosis weighing  $211.6 \pm 5$  g in women aged 39–48 years. The average interval between hysterectomy and symptoms of IA varied within  $7.42 \pm 1.03$  years. Common symptoms of IA included abdominal discomfort, moderate-to-severe deep dyspareunia, and pelvic mass. Pelvic pain was described in all cases, mostly due to the existence of adhesions and nerve involvement. Dyspareunia was another common symptom in patients with this entity, explained by rectal retraction and the presence of adhesions. Clinical examination was painful when the pouch of Douglas and lateral Cul-de-sac were explored, and vaginal examination showed the presence of retrocervical or laterocervical masses. The preoperative blood sample analysis showed elevated CA 125 in 9 cases (90%). Pelvic MRI showed an irregular mass overhanging the cervix, extending up into the pelvis, pressing against the rectum or rectosigmoid, or a pelvic mass fixed to the vaginal vault. These heterogeneous masses were composed of hypo- and hyperintense signals on T2-weighted images. Gadolinium injection evidenced vascularisation of the lesions. Hyperintense signals on T1-weighted images with saturation of fatty tissue suggested the presence of old blood.

Laparoscopic excision was proposed for patients with retrocervical masses filling the pouch of Douglas. The number of lesions varied between 1 and 2, which was not the case for IPM, which had seven lesions in one case. The iatrogenic nodule size measured  $34.5 \pm 28.7$  mm. Despite the use of an electromechanical morcellator in the case of IA masses, the usual location was in the pelvic area, especially in the retrocervical zone. A macroscopic inflammatory reaction was observed, creating retraction of the surrounding organs, such as the cervix and rectum. Adhesions between the pelvic masses and the rectum were found in all cases. Extensive dissection of the rectum and pararectal fossa were required to isolate the lesions. During resection of the masses, bluish lesions

were identified corresponding to haemorrhagic spots observed on MRI. In the physiology of adhesion formation, the inflammatory process is commonly implicated [45], and adenomyosis is associated with a more inflammatory reaction than uterine fibroids. Additionally, the junctional zone is more inflammatory for the peritoneum. In peritoneal endometriosis, according to Sampson's theory, viable endometrial cells are able to implant, proliferate and create an inflammatory reaction [46]. The experimental baboon model confirmed these data with more adhesions after grafting the endometrium or endometrium and junctional zone, as the inflammatory response is more important in IAs than in myomatous lesions [13]. Histological examination of the excised iatrogenic lesions confirmed smooth muscle hyperplasia infiltrated by endometrial glands and stroma. An inflammatory reaction was also observed around the dilated glands, probably due to old blood retention in the lumen of these glands (Table 4).

Concerning IA, all cases were described after morcellation of an adenomyotic uterus. We thus agreed with Donnez et al. [36] that retained uterine fragments containing both endometrium and myometrium are able to survive in the peritoneal cavity, resulting in adenomyotic lesions. The most important difference between IPMs and IAs is the presence of endometrium associated with subendometrial myometrium (junctional zone). When this association is found in forgotten specimens, these iatrogenic lesions are able to develop tumours characterised by dense tissue composed of smooth muscle hyperplasia with isolated foci of endometrial mucosa and stroma. Experimental studies conducted by Donnez et al. [36] on baboons showed that 20–24 months after grafting of the myometrium alone, smooth muscle lesions associated with fibrotic tissue were found in all cases except one. After grafting the endometrium together with the junctional zone and total uterine thickness, novel lesions composed of endometrial glands and stroma associated with smooth muscle hyperplasia were found. Induced nodular endometriotic lesions were significantly larger and showed a stronger invasion process when tissue specimens containing the junctional zone were grafted. Adenomyosis was the initial indication for LASH in the Donnez et al. [36] series, which means that the junctional zone was larger with a higher risk of having more junctional zone fragments able to induce the formation of iatrogenic adenomyosis. Based on an experimental model [47], the adhesion of human endometrial cells to mouse peritoneum was increased by treatment with pro-inflammatory cytokines, and surgical intervention creates an inflammatory reaction because of peritoneal damage, crush-induced ischaemia, suture ligation, coagulation, or CO<sub>2</sub> use [45].

In cases of uterine morcellation, both types of iatrogenic lesions may develop, but IA lesions were more commonly described. The duration of steroid exposure seems to be a risk factor in the case of IPM, and all patients were in the premenopausal period at the time of first surgery. Removal of this iatrogenic pathology is necessary because of the risk of malignant transformation. Rabischong [48] described one case with atypical endometrial hyperplasia as an initial pathology without this atypia. Methods to avoid these iatrogenic complications may include laparoscopic morcellation in a bag, as suggested by Kanade et al. [49], or culdotomy or mini-laparotomy with manual morcellation within a specimen bag [50]. There are no limitations of in-bag morcellation, with the possibility of use even with single-site access. Morcellation in

**Table 3**  
Initial pathology and initial surgery performed in the case of iatrogenic adenomyoma.

References (Year)	N° c	Initial pathology	U/M weight	Surgery	Morcellator used
Hilger et al. (2006) [14]	1	Myomas	225 g	LASHnR	Yes
Donnez et al. (2007) [13]	8	Myomas + ADM	210 ± 59 g	LASHnR/R	Yes
Larrain et al. (2010) [15]	1	Myomas	-	LH	Yes

**Table 4**  
Clinical characteristics and intraoperative data for iatrogenic adenomyoma.

References (Year)	Symptoms	Interval (years)	Adenomyoma N°	Location of novel pathology	Size of developed nodules	CA125	Adhesions	Anatomopathology
Hilger et al. (2006) [14]	Pelvic pain, pelvic mass	5	2	Cervical stump, rectosigmoidal junction, near the right ovary	3,2, 4 cm	High	Yes	Adenomyosis
Donnez et al. (2007) [13]	Pelvic pain, DPP	2–9	1 for each case	Latero- and retrocervical masses	2–8 cm	N/ high	Yes	Adenomyosis
Larrain et al. (2010) [15]	Pelvic pain, pelvic mass	6	1	Presacral peritoneum	6 cm	N	Yes	Adenomyosis

LH, laparoscopic hysterectomy; LASHnR, laparoscopic subtotal nonradical hysterectomy; NA, not available; N, normal; DPP, dyspareunia; ADM, adenomyosis.

a bag is proposed for myomas and for the uterus and does not require additional advanced surgical skills. In cases of uterine morcellation (subtotal or total hysterectomy), the use of a bag may systematically include conditions without anatomopathological modifications, such as uterine prolapse [51]. In 2016, the FDA approved the first bag for contained morcellation [52]. However, an *in vitro* study demonstrated that the risk of leakage and tissue dissemination still exists, depending on the insufflation pressure and material type of the bag [53], and the case of Süleyman Salman confirmed this issue [54]. Another *in vivo* study showed that some types of bags seem to be safe [55,56], but the existing bags were not designed for power morcellation and, thus, risk spillage in the case of multiport laparoscopy. The authors of that study suggested that the absence of leakage be assessed by visual inspection. Akdemir et al. [57] proposed the use of surgical gloves for enclosed morcellation in cases of multiport laparoscopy to decrease tissue spillage, but the myoma size is a limiting factor for this in-bag morcellation technique. In addition to the concern of spreading malignant cells, morcellation raises new challenges in the pathological interpretation of disrupted tissue specimens. Pathologic evaluation of morcellated uteri is more challenging, and there is a possibility that smaller uterine tumours would be missed. Furthermore, the complexity of this technique may require more advanced training to ensure safety in the hands of novice users [58]. In the review titled “Contained Morcellation: Review of Current Methods and Future Directions”, the authors concluded that there is currently no available method for tissue extraction that completely eliminates the risk of cellular dissemination [59]. The FDA discouraged the use of laparoscopic power morcellation to avoid the spread and worsened clinical outcomes of unsuspected uterine malignancy with a first safety communication warning in April 2014 [60,61]. Following this communication regarding power morcellation, utilization of minimally invasive hysterectomy and morcellation decreased [35]. In patients with a history of uncontained uterus or myoma morcellation who report pelvic symptoms, IPM or adenomyoma should be considered in the differential diagnosis.

## Conclusions and future perspectives

Retained uterine or myoma fragments after laparoscopic surgery are able to survive and grow in the peritoneal cavity under hormonal steroid exposure when the uterine blood supply is lost. The lack of systematic follow-up after laparoscopic morcellation could result in an underestimation of the incidence because many cases are asymptomatic. Iatrogenic myoma and adenomyoma have a possible different pathogenetic mechanism, but both pathologies have a common point: they originate after a surgical procedure involving morcellation. In-bag morcellation might decrease the incidence of these iatrogenic conditions and is technical feasible but has some limitations and risks. When a morcellator is used, a thorough inspection of the peritoneal cavity and the observation of no leakage from the bag are required. In addition, the patient should be informed concerning this potential, rare iatrogenic com-

plication and the remaining risk potential of in-bag morcellation as well as provided balanced information on alternative treatment options, particularly when a laparoscopic approach is employed. Although the studies discussed in this review provide a good understanding of the risk factors of IPM and adenomyoma, other prospective data collection is necessary to establish other risk factors in addition to morcellator use to develop an algorithm for patient selection for laparoscopic morcellation of the uterus or myoma, with the aim of improving patient safety.

## Conflict of interest

*The authors have declared no conflict of interest*

## Compliance with Ethics Requirements

*This article does not contain any studies with human or animal subjects*

## Acknowledgements

The authors would like to thank Professor Donnez Olivier for his advice regarding publication at the beginning of this work.

## References

- [1] Chapron C, Pierre F, Querleu D. Complication of laparoscopy in gynecology. *Gynecol Obstet Fertil* 2001;29:605–12.
- [2] Donnez O, Jadoul P, Squifflet J, Donnez J. A series of 3190 laparoscopic hysterectomies for benign disease from 1990 to 2006: evaluation of complications compared with vaginal and abdominal procedures. *BJOG* 2009;116:492–500.
- [3] Malinowski A, Makowska J, Antosiak B. Total laparoscopic hysterectomy – indications and complications of 158 patients. *Ginekol Pol* 2013;84:252–7.
- [4] Wood C, Maher PJ. Laparoscopic hysterectomy. *Baill Clin Obstet Gynecol* 1997;11:111–36.
- [5] Wallenstein MR, Ananth CV, Kim JH, Burke WM, Hershman DL, Lewin SN, Neugut AI, et al. Effect of surgical volume on outcomes for laparoscopic hysterectomy for benign indications. *Obstet Gynecol* 2012;119:709–16.
- [6] Donnez J, Smets M, Polet R, Bassil S, Nisolle M. LASH: laparoscopic supracervical (subtotal) hysterectomy. *Zentralbl Gynakol* 1995;117:629–32.
- [7] Bojahr BL, Raatz D, Schonleber G, Abri C, Ohlinger R. Perioperative complication rate in 1706 patients after a standardized laparoscopic supracervical hysterectomy technique. *J Minim Invasive Gynecol* 2006;13:183–9.
- [8] Whiteman MK, Hillis SD, Jamieson DJ, Morrow B, Podgornik MN, Brett KM, Marchbanks PA. Inpatient hysterectomy surveillance in the United States, 2000–2004. *Am J Obstet Gynecol* 2008;198(34):e1–7.
- [9] Huang JQ, Lathi RB, Lemyre M, Rodriguez HE, Nezhat CH, Nezhat C. Coexistence of endometriosis in women with symptomatic leiomyomas. *Fertil Steril* 2010;94:720–3.
- [10] Steiner RA, Wight E, Tadir Y, Haller U. Electrical cutting device for laparoscopic removal of tissue from the abdominal cavity. *Obstet Gynecol* 1993;81:471–4.
- [11] Erian J, Hassan M, Hill N. Electromechanical morcellation in laparoscopic subtotal hysterectomy. *Int J Gynaecol Obstet* 2007;99:67–8.
- [12] Thian YL, Tan KH, Kwek JW, Wang J, Chern B, Yam KL. Leiomyomatosis peritonealis disseminata and subcutaneous myoma- a rare complication of laparoscopic myomectomy. *Abdom Imaging* 2009;34:235–8.
- [13] Donnez O, Squifflet J, Leconte I, Jadoul P, Donnez J. Posthysterectomy pelvic adenomyotic masses observed in 8 cases out of a series of 1405 laparoscopic subtotal hysterectomies. *J Minim Invasive Gynecol* 2007;14:156–60.

- [14] Hilger WS, Magrina JF. Removal of pelvic leiomyomata and endometriosis five years after supracervical hysterectomy. *Obstet Gynecol* 2006;108:772–4.
- [15] Larraín D, Rabischong B, Khoo CK, Botchorishvili R, Canis M, Mage G. « Iatrogenic » parasitic myomas: unusual late complication of laparoscopic morcellation procedures. *J Minim Invasive Gynecol* 2010;28:719–24.
- [16] LaCoursiere DY, Kennedy J, Hoffman CP. Retained fragments after total laparoscopic hysterectomy. *J Minim Invasive Gynecol* 2005;12:67–9.
- [17] Cucinella G, Granese R, Calagna G, Somigliana E, Perino A. Parasitic myomas after laparoscopic surgery: an emerging complication in the use of morcellator ? Description of four cases. *Fertil Steril* 2011;96:e90–6.
- [18] Van der Meulen JF, Pijnenborg JMA, Boomsma CM, Verberg MFG, Geomini PMAJ, Bongers MY. Parasitic myoma after laparoscopic morcellation: a systematic review of the literature. *BJOG* 2016;123:69–75.
- [19] Driessen SR, Arkenbout EA, Thurkow AL, Jansen FW. Electromechanical morcellators in minimally invasive gynecologic surgery: an update. *J Minim Invasive Gynecol* 2014;21:377–83.
- [20] <https://www.fda.gov/downloads/MedicalDevices/Safety/AlertsandNotices/UCM424444.pdf>.
- [21] Paul PG, Koshy AK. Multiple peritoneal parasitic myomas after laparoscopic myomectomy and morcellation. *Fertil Steril* 2006;85:492–3.
- [22] Rakesh S, Hegde A, Mahajan C. Parasitic myoma under the diaphragm. *J Minim Invasive Gynecol* 2007;14:1.
- [23] Rakesh S, Sundaram M, Mahajan C, Sambhus A. Multiple leiomyomas after laparoscopic hysterectomy: report of two cases. *J Minim Invasive Gynecol* 2007;14:123–7.
- [24] Takeda A, Mori M, Sakai K, Mitsui T, Nakamura H. Parasitic peritoneal leiomyomatosis diagnosed 6 years after laparoscopic myomectomy with electric tissue morcellation: report of a case and review of the literature. *JMIG* 2007;14:770–5.
- [25] Moon HS, Koo JS, Park SH, Park GS, Choi JG, Kim SG. Parasitic leiomyoma in the abdominal wall after laparoscopic myomectomy. *Fertil Steril* 2008;90:1201.e1–e2.
- [26] Rakesh S, Sundaram M, Lakhota S, Kadam P, Rao G, Mahajan C. Parasitic myoma after morcellation: case report. *J Gynec Endosc Surg* 2009;1:113–5.
- [27] Epstein JH, Nejat EJ, Say T. Parasitic myomas after laparoscopic myomectomy: case report. *Fertil Steril* 2009;91:932.e13–14.
- [28] Wada-Hiraike O, Yamamoto N, Osuga Y, Yano T, Kozuma S, Taketani Y. Aberrant implantation and growth of uterine leiomyoma in the abdominal wall after laparoscopically assisted myomectomy. *Fertil Steril* 2009;92(5):1747. doi: <https://doi.org/10.1016/j.fertnstert.2009.07.968>. e13–5. Epub 2009 Sep 17.
- [29] Kho K, Nezat C. Parasitic myomas. *Obstet Gynecol* 2009;114:611–5.
- [30] Sesti F. Multiple ectopic leiomyomas of the abdominal rectus muscles after gasless laparoscopic uterine myomectomy. *Arch Gynecol Obstet* 2012;285:883–5.
- [31] Yanazume S, Tsuji T, Yoshioka T, Yamasaki H, Yoshinaga M, Douchi T. Large parasitic myomas in abdominal subcutaneous adipose tissue along a previous myomectomy scar. *J Obstet Gynaecol Res* 2012;38:875–9.
- [32] Takeda A, Imoto S, Mori M, Yamada J, Nakamura H. Rapid growth of parasitic myoma in early pregnancy: previously undescribed manifestation of a rare disorder after laparoscopic-assisted myomectomy. *Eur J Obstet Gynecol Reprod Biol*. 2012 May;162(1):117–8. doi: <https://doi.org/10.1016/j.ejogrb.2012.01.015>. Epub 2012 Feb 19.
- [33] Leren V, Langebrekke A, Qvigstad E. Parasitic leiomyomas after laparoscopic surgery with morcellation. *Acta Obstet Gynecol Scand* 2012;91:1233–6.
- [34] Ehdavand S, Simon RA, Sung CJ, Steinhoff MM, Lawrence WD, Quddus MR. Incidental gynecologic neoplasms in morcellated uterine specimens: a case series with follow-up. *Hum Pathol* 2014;45:2311–7.
- [35] Van der Meulen JF, Pijnenborg JM, Boomsma CM, Verberg MF, Geomini PM, Bongers MY. Parasitic myoma after laparoscopic morcellation: a systematic review of the literature. *BJOG* 2016;123:69–75.
- [36] Donnez O, Van Langendonck A, Defrère S, Colette S, Van Kerk O, Dehoux JP, Squifflet J, et al. Induction of endometriotic nodules in an experimental baboon model mimicking human deep nodular lesions. *Fertil Steril* 2013;99:783–9.
- [37] Flake GP, Andersen J, Dixon D. Etiology and pathogenesis of uterine leiomyomas: a review. *Environ Health Perspect* 2003;111:1037–54.
- [38] Rein MS, Powell WL, Walters FC, Weremowicz S, Cantor RM, Barbieri RL, Morton CC. Cytogenetic abnormalities in uterine myomas are associated with myoma size. *Mol Hum Reprod* 1998;4:83–6.
- [39] Parker WH. Etiology, symptomatology, and diagnosis of uterine myomas. *Fertil Steril* 2007;87:725–36.
- [40] Drosch M, Bullerdielk J, Zollner TM, Prinz F, Koch M, Schmidt N. A novel mouse model that closely mimics human uterine leiomyomas. *Fertil Steril* 2013;99:927–35.
- [41] Huang BS, Yang MH, Wang PH, Li HY, Chou TY, Chen YJ. Oestrogen-induced angiogenesis and implantation contribute to the development of parasitic myomas after laparoscopic morcellation. *Reprod Biol Endocrinol* 2016;14:64.
- [42] Al-Talib A, Tulandi T. Pathophysiology and possible iatrogenic cause of leiomyomatosis peritonealis disseminata. *Gynecol Obstet Invest* 2010;69:239–44.
- [43] Halama Niels. Silke A Grauling-Halama, and Isam Daboul. Familial clustering of Leiomyomatosis peritonealis disseminata: an unknown genetic syndrome? *BMC Gastroenterol* 2005;5:33.
- [44] Raine-Bennett T, Tucker LY, Zaritsky E, Littell RD, Palen T, Neugebauer R, Axtell A, Schultze PM, Kronbach DW, Embry-Schubert J, Sundang A, Bischoff K, Compton-Phillips AL, Lentz SE. Occult uterine sarcoma and leiomyosarcoma: incidence of and survival associated with morcellation. *Obstet Gynecol* 2016;127(1):29–39.
- [45] Davey AK, Maher PJ. Surgical adhesions: a timely update, a great challenge for the future. *J Minim Invasive Gynecol* 2007;14:15–22.
- [46] Van der Linden PJ. Theories on the pathogenesis of endometriosis. *Hum Reprod* 1996;11:53–65.
- [47] Beliard A, Noël A, Goffin F, Francken F, Foidart JM. Adhesion of endometrial cells labeled with 111Indium-tropolonate to peritoneum: a novel *in vitro* model to study endometriosis. *Fertil Steril* 2003;79:724–9.
- [48] Rabischong B, Beguinot M, Compan C, Bourdel N, Kaemmerlen AG, Pouly JL, Canis M, et al. Long-term complication of laparoscopic uterine morcellation: iatrogenic parasitic myomas. *J Gynecol Obstet Biol Reprod (Paris)* 2013;42:577–84.
- [49] Kanade TT, McKenna JB, Choi S, Tsai BP, Rosen DM, Cario GM, Chou D. Sydney contained in bag morcellation for laparoscopic myomectomy. *J Minim Invasive Gynecol* 2014;21:981.
- [50] Paul PG, Shintre H, Mehta S, Gulati G, Paul G, Mannur S. Parasitic myomas: an unusual risk after morcellation. *Gynecol Minim Invasive Ther* 2018;7:124–6.
- [51] Rimbach S, Schempershofe M. In-bag morcellation as a routine for laparoscopic hysterectomy. *Biomed Res Int* 2017;2017:6701916.
- [52] <http://www.fda.gov/NewsEvents/Newsroom/PressAnnouncements/ucm494650.htm>.
- [53] Cohen SL, Greenberg JA, Wang KC, Srouji SS, Gargiulo AR, Pozner CN, Hoover N, et al. Risk of leakage and tissue dissemination with various contained tissue extraction (CTE) techniques: an *in vitro* pilot study. *J Minim Invasive Gynecol* 2014;21:935–9.
- [54] Salman S, Ketenci Gencer F, Babaoğlu B, Bestel M, Kumbasar S, Tuna G, et al. Unsuspected diagnosis of uterine leiomyosarcoma after laparoscopic myomectomy in an isolated bag. *Case Rep Obstet Gynecol* 2018;2018:6342081.
- [55] Cohen SL, Einarsson JI, Wang KC, Brown D, Boruta D, Scheib SA, Fader AN, et al. Contained power morcellation within an insufflated isolation bag. *Obstet Gynecol* 2014;124:491–7.
- [56] Steller C, Cholkeri-Singh A, Sasaki K, Miller CE. Power morcellation using a contained bag system. *JLSL* 2017;21(1). pii: e2016.00095.
- [57] Akdemir A, Taylan E, Zeybek B, Ergenoglu AM, Sendag F. Innovative technique for enclosed morcellation using a surgical glove. *Obstet Gynecol* 2015;125(5):1145–9.
- [58] Dotson S, Landa A, Ehrisman J, Secord AA. Safety and feasibility of contained uterine morcellation in women undergoing laparoscopic hysterectomy. *Gynecol Oncol Res Pract* 2018;5:8.
- [59] Taylan E, Sahin C, Zeybek B, Akdemir A. Contained morcellation: review of current methods and future directions. *Front Surg* 2017;4:15. doi: <https://doi.org/10.3389/fsurg.2017.00015>. eCollection 2017.
- [60] <https://wayback.archiveit.org/7993/20170406071822/https://www.fda.gov/MedicalDevices/Safety/AlertsandNotices/ucm393576.htm>.
- [61] Harris JA, Swenson CW, Uppal S, Kamdar N, Mahner N, As-Sanie S, et al. Practice patterns and postoperative complications before and after US Food and Drug Administration safety communication on power morcellation. *Am J Obstet Gynecol* 2016;214:98.e1–98.e13.



**Natalia Darii** is a specialist in gynecology with focus on minimal invasive surgery. She is focusing on surgery for benign conditions and fertility and in finding new risk factors for iatrogenic parasitic myoma.




**Anton Emil** is an Associate professor at the University of Medicine and Pharmacy Gr. T. Popa Iasi, Romania. He is a senior specialist in obstetrics and gynecology, with focus on premature birth, breast cancer, oxidative stress in cancer, and minimal invasive surgery.



**Bogdan Doroftei** is a Lecturer at the University of Medicine and Pharmacy Gr. T. Popa from Iasi, Romania and a member of the Steering committee Eshre-IVF Monitoring (EIM) Consortium. His interests include minimally invasive gynaecological surgery, human assisted reproduction and medical genetics.



**Sorana Caterina Anton** is an undergraduate student at the University of General Medicine and Pharmacy Gr. T. Popa Iasi, Romania. Right now she is focusing on obstetrics and gynecology.



**Alin Ciobica** is a Researcher interested in various biochemical, molecular and histological studies, especially correlated with relevance of oxidative stress status in some diseases of both humans and animal models.



**Taymour Mostafa** is a full Professor of “Andrology, Sexology & STIs” at the University of Cairo, Egypt since 1998 to date. He is an author of more than 160 local as well as international publications in the field of Andrology, Sexology, Reproduction, and STIs. His scientific points of interest include; reproduction, male infertility, apoptosis, stem cells, varicocele, sexual health, erectile dysfunction, oxidative stress, human health, and pollution. He is the winner of ISSM/Pfizer congress celebration award (2005), Jean Francois Genetese Award for the best basic research paper 2006 (Cairo) and 2008 (Brussels) successively from ISSM. He also awarded the State Prize for Appreciation in Medical Sciences 2017.