

Delayed cerebral pseudoaneurysm following surgical and combined-modality therapy for glioblastoma multiforme: illustrative case

Hari N. Krishnakumar, BS,¹ and Colin Son, MD^{2,3}

¹Long School of Medicine, University of Texas Health Science Center, San Antonio, Texas; ²Neurosurgical Associates of San Antonio, San Antonio, Texas; and ³School of Osteopathic Medicine, University of the Incarnate Word, San Antonio, Texas

BACKGROUND Post–radiation therapy and chemotherapy cerebral pseudoaneurysms are rare entities. Within previous tumor treatment areas on nonvascular imaging, they are potentially confused as recurrent tumor.

OBSERVATIONS A 61-year-old man was a long-term survivor of glioblastoma multiforme whose treatment consisted of open biopsy followed by radiotherapy to 60 Gy and systemic carmustine. On surveillance imaging, enlargement of a posttreatment cyst and new enhancing lateral “mural nodule” was first noticed approximately 16 years after initial treatment. Over 12 months, both continued to enlarge. Initially referred to as recurrence, subsequent angiography showed the mural nodule to be an unruptured distal middle cerebral artery pseudoaneurysm within the previous tumor bed. The patient underwent repeat craniotomy for clipping of the aneurysm and biopsy of the cyst wall, which was negative for malignancy.

LESSONS Delayed pseudoaneurysms following radiation therapy and chemotherapy for malignant brain tumors are rare but have been previously reported. Their appearance on cross-sectional imaging can mimic recurrence, and they should be kept in the differential of new, circumscribed enhancement within such treatment areas.

<https://thejns.org/doi/abs/10.3171/CASE22129>

KEYWORDS glioblastoma multiforme; cerebral aneurysm; pseudoaneurysm

In this case, we report an unusual finding of an unruptured cerebral pseudoaneurysm on a distal branch of the right M3 middle cerebral artery within the previous tumor bed of a treated glioblastoma multiforme (GBM). Although rare, the potential for radiation-induced or surgery-induced aneurysms introduces another aspect of consideration on surveillance imaging for recurrence.

Illustrative Case

A 61-year-old man was initially diagnosed with a right temporal mass following a new-onset seizure. Open biopsy and subtotal resection at an outside facility diagnosed a stage IV glioma. He recovered well from surgery and, on phenytoin, suffered no further seizures. In the pre-temozolomide era, he received combined-modality therapy, with radiotherapy to 60 Gy over 5 weeks and systemic carmustine. He obtained a great therapeutic result with complete resolution of pathological enhancement on subsequent

magnetic resonance imaging (MRI) scans. The baseline scans after treatment showed a nonenhancing cyst within the right temporal lobe where the malignancy had once been.

Approximately 16 years later, he continued to receive annual surveillance MRI for recurrence. In that year, the scan ordered by his oncologist demonstrated some enlargement of the cyst as well as a new circumscribed enhancement along the cyst’s lateral border. This scan was followed in short order with a 3-month scan that demonstrated stability of both and was then followed with a 9-month scan that showed enlargement of the enhancing portion to approximately 6 mm (Fig. 1). This well-circumscribed lesion was described as a “mural nodule” on these initial scans.

The patient was referred to our neurosurgical practice for potential recurrence of his malignant tumor. On review of his MRI, there was some question as to the diagnosis of a recurrent tumor. However, he was tentatively scheduled for repeat craniotomy. At the

ABBREVIATIONS CTA = computed tomography angiography; GBM = glioblastoma multiforme; MRI = magnetic resonance imaging.

INCLUDE WHEN CITING Published July 11, 2022; DOI: 10.3171/CASE22129.

SUBMITTED March 15, 2022. **ACCEPTED** May 18, 2022.

© 2022 The authors, CC BY-NC-ND 4.0 (<http://creativecommons.org/licenses/by-nc-nd/4.0/>).

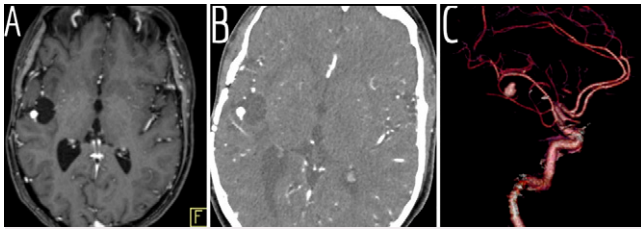


FIG. 1. Axial postcontrast T1-weighted MRI (A) with posttreatment cyst and enhancing structure in lateral wall described as a mural nodule. CTA with axial image (B) and three-dimensional reconstruction (C) showing a distal middle cerebral artery branch aneurysm.

same time preoperatively, he received computed tomography angiography (CTA) to rule out a vascular lesion. This CTA showed his enhancing mural nodule as a distal middle cerebral artery branch pseudoaneurysm (Fig. 1). The plans for repeat craniotomy were paused. He received formal digital subtraction angiography (Fig. 2), which showed delayed flow into a superiorly projecting aneurysm arising from a nonbranching point off a distal M3 middle cerebral artery. There was irregularity and approximately 40% stenosis of the parent vessel proximal to the aneurysm. These findings were consistent with a pseudoaneurysm.

Because of the distal position of the aneurysm as well as small caliber of the parent vessel and its irregularity, he was considered a poor candidate for reconstructive endovascular repair. After discussion, he elected to undergo repeat craniotomy and open repair of the aneurysm. The aneurysm was found amenable to primary clipping. Intraoperative angiography demonstrated exclusion of the aneurysm and a patent parent vessel (Fig. 3). He had an uneventful postoperative course and was discharged to home on postoperative day 3. On follow-up, his modified Rankin Scale score remained 0 without obvious evidence of recurrent aneurysm or brain tumor.

Discussion

Observations

GBM is the most common primary malignant brain tumor.¹ Treatment typically consists of maximum safe resection followed by combined therapy with radiation and chemotherapy. Even with these treatments, the current median survival is approximately 15 months, and in the pre-temozolomide era, as with our patient, survival time was even less.² Still, although rare, long-term survival is achieved in some patients.³ The length of observation in long-term survivors may make unusual posttreatment complications more likely to be observed.

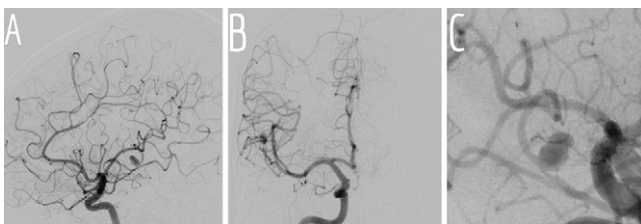


FIG. 2. Diagnostic angiograms in lateral (A), anteroposterior (B), and magnified oblique (C) projections demonstrating the distal middle cerebral artery pseudoaneurysm.

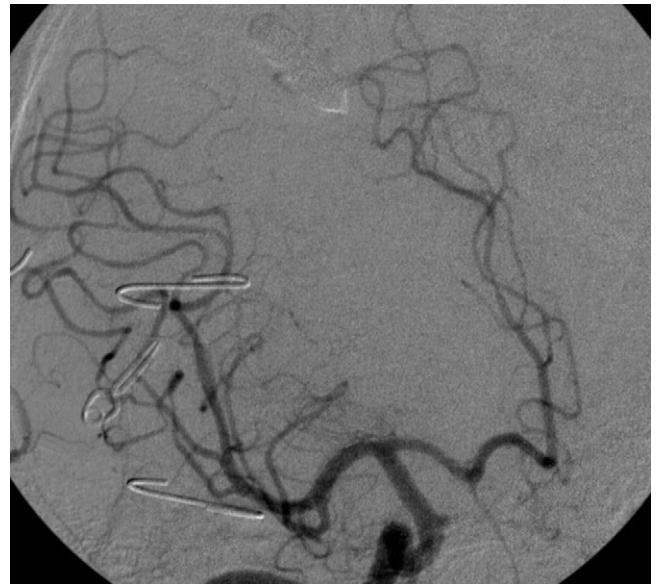

FIG. 3. Intraoperative angiogram showing exclusion of the aneurysm and patent distal vessel.

MRI is an important aid for surveillance of recurrence of GBM after treatment.⁴ However, imaging can often be confounded by radiographic changes caused by tumor therapies as opposed to the tumor itself.⁴ Notably, these include pseudoprogression,⁵ but other changes, including vascular changes, are rarely reported.^{6–10}

Multiple reports exist of concurrent cerebral aneurysm and GBM, presumably from tumor involvement and weakening of en passage or feeding vessels.¹¹ In addition, previous cranial irradiation, certain chemotherapies, and even surgery are known risk factors for cerebral aneurysm formation, with multiple reports of such.^{6,7,10,12–14} It is not uncommon for these pseudoaneurysms to present in a delayed fashion, likely because of the total short observation time afforded most patients with glioblastoma; however, case reports of delayed cerebral pseudoaneurysm formation as a result of glioblastoma treatment are particularly rare. It is likely, however, that the etiology of the delayed pseudoaneurysm in our patient is similar to those reported in other patients after cranial radiation and chemotherapy.

The typical observation for posttreatment glioblastoma involves contrast-enhanced, cross-sectional MRI. Contrast-enhanced MRI is likely inferior to MR angiography or CTA in the detection of cerebral aneurysms and is not routinely used to search for or follow aneurysms.¹⁵ Confusion of enhancement of a cerebral aneurysm within the vicinity of previous tumor with tumor recurrence therefore may not be surprising.¹⁶

In hindsight, our patient's MRIs showed the enhancing "mural nodule" clearly continuous with a distal middle cerebral artery branch visible with contrast, raising the suspicion of an aneurysm on his referral to our practice despite the possibility of an aneurysm not being raised in the initial radiologist reports.

Lessons

While rare, posttreatment cerebral pseudoaneurysm should be considered in follow-up imaging for patients with glioblastoma. The differential on follow-up MRI should include tumor recurrence.

This may be true particularly in long-term survivors of glioblastoma. Careful attention to contrast within feeding vessels that connect with the enhancing nodule may help distinguish a cerebral pseudoaneurysm from recurrence on MRI.

References

1. Wang J, Bettgowda C. Genomic discoveries in adult astrocytoma. *Curr Opin Genet Dev.* 2015;30:17–24.
2. Alifieris C, Trafalis DT. Glioblastoma multiforme: pathogenesis and treatment. *Pharmacol Ther.* 2015;152:63–82.
3. Tykocki T, Eltayeb M. Ten-year survival in glioblastoma. A systematic review. *J Clin Neurosci.* 2018;54:7–13.
4. Strauss SB, Meng A, Ebani EJ, Chiang GC. Imaging glioblastoma posttreatment: progression, pseudoprogression, pseudoresponse, radiation necrosis. *Radiol Clin North Am.* 2019;57(6):1199–1216.
5. Chu HH, Choi SH, Ryoo I, et al. Differentiation of true progression from pseudoprogression in glioblastoma treated with radiation therapy and concomitant temozolomide: comparison study of standard and high-b-value diffusion-weighted imaging. *Radiology.* 2013;269(3):831–840.
6. Sano K, Kawanami K, Yamaki T, Matsuda K, Kokubo Y, Sonoda Y. Intracranial pseudoaneurysm arising after radiotherapy for oligodendroglioma: a case report. Article in Japanese. *No Shinkei Geka.* 2020;48(1):25–32.
7. Yoon WS, Lee KS, Jeun SS, Hong YK. De novo aneurysm after treatment of glioblastoma. *J Korean Neurosurg Soc.* 2011;50(5):457–459.
8. Sato K, Dan M, Yamamoto D, Miyajima Y, Hara A, Kumabe T. Chronic phase intracranial hemorrhage caused by ruptured pseudoaneurysm induced by carmustine wafer implantation for insulo-ocular anaplastic astrocytoma: a case report. *Neurol Med Chir (Tokyo).* 2015;55(11):848–851.
9. Pesce A, Palmieri M, Zancana G, et al. Radiation-induced brain aneurysms: institutional experience and state of the art in the contemporary literature. *World Neurosurg.* 2020;135:339–351.
10. Jensen FK, Wagner A. Intracranial aneurysm following radiation therapy for medulloblastoma. A case report and review of the literature. *Acta Radiol.* 1997;38(1):37–42.
11. Tan D, Daly C, Xenos C, Lai LT, Chandra RV. Glioblastoma presenting as spontaneous subarachnoid hemorrhage: technical case note of combined endovascular and microsurgical vision-sparing treatment. *World Neurosurg.* 2019;128:426–430.
12. Pereira P, Cerejo A, Cruz J, Vaz R. Intracranial aneurysm and vasculopathy after surgery and radiation therapy for craniopharyngioma: case report. *Neurosurgery.* 2002;50(4):885–888.
13. Scodary DJ, Tew JM Jr, Thomas GM, Tomsick T, Liwnicz BH. Radiation-induced cerebral aneurysms. *Acta Neurochir (Wien).* 1990;102(3-4):141–144.
14. Nanney AD 3rd, El Tecle NE, El Ahmadi TY, et al. Intracranial aneurysms in previously irradiated fields: literature review and case report. *World Neurosurg.* 2014;81(3-4):511–519.
15. Yoon NK, McNally S, Tausky P, et al. Imaging of cerebral aneurysms: a clinical perspective. *Neurovasc Imaging.* 2016;2(1):6.
16. Donahue JH, Patel SH, Fadul CE, Mukherjee S. Imaging mimics of brain tumors. *Radiol Clin North Am.* 2021;59(3):457–470.

Disclosures

The authors report no conflict of interest concerning the materials or methods used in this study or the findings specified in this paper.

Author Contributions

Conception and design: Son. Acquisition of data: Son. Analysis and interpretation of data: Son. Drafting the article: both authors. Critically revising the article: both authors. Reviewed submitted version of manuscript: both authors. Approved the final version of the manuscript on behalf of both authors: Son.

Correspondence

Colin Son: Neurosurgical Associates of San Antonio, San Antonio, TX. colinson@gmail.com.