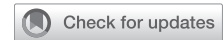

See Article page 20.



## Commentary: Repairing the rheumatic mitral valve in the young—definitively worthwhile!

Manuel J. Antunes, MD, PhD, DSc

Mitral valve repair was initially thought for and applied to the rheumatic pathology. The first large reports included a majority of patients with this pathology. Subsequently, the method was extended to degenerative valves and, when results were compared, the rheumatic series came second. With the improved sanitary conditions in the developed countries, in the second half of the 20th century, rheumatic disease gradually disappeared in these countries and rapidly became a nonproblem. Surgeons forgot or never learned how to do it and the rare, chronic, distorted, calcified valve in patients in their fifties is usually replaced. However, the results of repair in chronic cases of older patients were shown to be almost as good as those of repair in degenerative disease.<sup>1,2</sup>

By contrast, in less-developed regions of the world, of the southern hemisphere and some areas of Asia, rheumatic fever is still prevalent. The patients are usually very young (in their teens and twenties), poor, uneducated, and have little access to medical care. The valve disease is in the acute phase or still in evolution. In these regions, cardiac surgery facilities are largely nonexistent or perform few procedures, which means surgeons with little experience. Not only is rheumatic valve repair challenging, thus with less certain perioperative results, but also the evolving disease leads to further scarring, which results in recurrent valve dysfunction, often requiring reoperation.<sup>3</sup> Hence, replacement is often preferred.

From the Faculty of Medicine, Clinic of Cardiothoracic Surgery, University of Coimbra, Coimbra, Portugal.

Disclosures: The authors reported no conflicts of interest.

The *Journal* policy requires editors and reviewers to disclose conflicts of interest and to decline handling or reviewing manuscripts for which they may have a conflict of interest. The editors and reviewers of this article have no conflicts of interest.

Received for publication Feb 25, 2020; revisions received Feb 25, 2020; accepted for publication Feb 26, 2020; available ahead of print April 3, 2020.

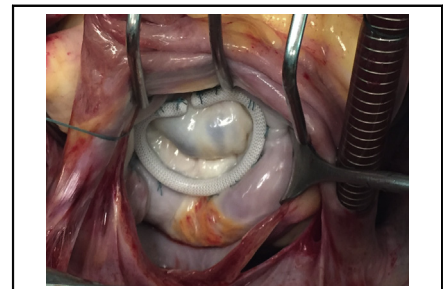
Address for reprints: Manuel J. Antunes, MD, PhD, DSc, Faculty of Medicine, University of Coimbra, 3000-075 Coimbra, Portugal (E-mail: [mjantunes48@sapo.pt](mailto:mjantunes48@sapo.pt)).

JTCVS Open 2020;1:31-2

2666-2736

Copyright © 2020 by The Authors. Published by Elsevier Inc. on behalf of The American Association for Thoracic Surgery. This is an open access article under the CC BY-NC-ND license (<http://creativecommons.org/licenses/by-nc-nd/4.0/>).

<https://doi.org/10.1016/j.xjon.2020.02.007>



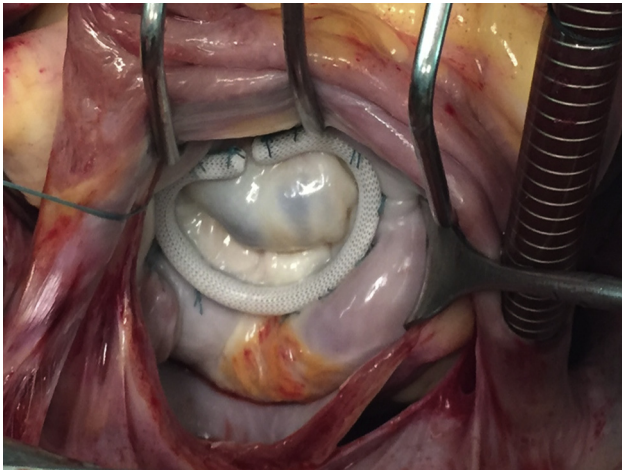
Repaired rheumatic mitral valve regurgitation.

### CENTRAL MESSAGE

Repair of the mitral valve in children with rheumatic disease is increasingly accepted, with ever better results, favorably comparable with replacement, in experienced hands. Definitely worthwhile!

Indeed, initial reports tended to present a negative outlook of repair for rheumatic disease. However, when compared with valve replacement, the results of repair are generally better.<sup>4</sup> In these populations, biological prostheses degenerate faster, with half-lives much inferior to 10 years, and the lack of compliance to anticoagulation makes replacement with mechanical valves a poor option, because of the high incidence of thromboembolism. In addition to improving knowledge of the disease and its pathophysiology, better and newer techniques of repair made for significantly better results. In experienced hands, the vast majority of these valves (in my experience, nearly 100%) can be repaired with good short- and long-term outcomes.<sup>5</sup>

In this issue of the *Journal*, Ananthanarayanan and colleagues,<sup>6</sup> from India, report their early experience with mitral valve repair in young patients. It consists of 102 consecutive children (<18 years; mean 13.1 years.) who underwent mitral valve repair for rheumatic etiology during a 4-year period ending in 2017. Four patients required valve replacement after failure of attempted repair. Almost one third of the patients had recent rheumatic activity, defined as <8 weeks. The results are good, with actuarial, event-free, and reoperation free survival of 96%, 92%, and 97%, respectively, but the series is relatively small, particularly for their country, and with a mean follow-up of just over 2 years, which is far too short for such pathology



**FIGURE 1.** Repaired rheumatic mitral valve regurgitation.

and surgery. Most series show that the attrition rate starts after a longer period. All patients had annuloplasty, which is correct, but a number of devices were used (ring, band, or other). In my view and of others, preshaped, rigid rings are needed in this type of pathology (Figure 1). In contrast, 40% of the patients had chordal procedures, which is a current trend, and 33.3% underwent autologous pericardial augmentation of either or both leaflets, which is currently under scrutiny, with comparative studies having not yet proved the benefit.

But the principal value of this paper lies, in my view, in drawing, again, the attention of the surgical fraternity to this problem and the need for repairing these valves. It also emphasizes the importance of acquiring experience. Most importantly by doing, but also by seeing it being done by surgeons and in places with experience with this specific procedure in these specific populations. Difficult, because, with a few exceptions (Brazil, India, and Australia, for example), the largest centers and the most senior surgeons of the world do not see or treat these patients.

In the recent years, several reports of mitral valve repair in the young have been published, showing excellent results.<sup>7-9</sup> Hence, the superiority of repair is gradually becoming scientifically proven. The newer guidelines now specifically mention repair for the treatment of rheumatic

valves. We are gradually approaching Class I indication (must do).<sup>10</sup> Hence, surgeons working in this environment must prepare themselves for this new “commandment.” Scores of risk have been developed that give surgeons the capability to predict which patients are better suited for repair.<sup>10</sup>

Finally, several of us participate in surgical missions, usually of humanitarian nature, in these developing countries and have the responsibility not only of treating the patients but also teaching local surgeons. It is of the utmost importance that we are prepared for it.<sup>11</sup>

Definitively worthwhile!

## References

1. DiBardino DJ, ElBardissi AW, McClure RS, Razo-Vasquez OA, Kelly NE, Cohn LH. Four decades of experience with mitral valve repair: analysis of differential indications, technical evolution, and long-term outcome. *J Thorac Cardiovasc Surg.* 2010;139:76-83.
2. Kim WK, Kim HJ, Kim JB, Jung SH, Choo SJ, Chung CH, et al. Clinical outcomes in 1731 patients undergoing mitral valve surgery for rheumatic valve disease. *Heart.* 2018;104:841-8.
3. Antunes MJ, Magalhaes MP, Colsen PR, Kinsley RH. Valvuloplasty for rheumatic mitral valve disease. A surgical challenge. *J Thorac Cardiovasc Surg.* 1987;94:44-56.
4. Antunes MJ. Challenges in rheumatic valvular disease: surgical strategies for mitral valve preservation. *Glob Cardiol Sci Pract.* 2015;2015:9.
5. Talwar S, Rajesh MR, Subramanian A, Saxena A, Kumar AS. Mitral valve repair in children with rheumatic heart disease. *J Thorac Cardiovasc Surg.* 2005;129:875-9.
6. Ananthanarayanan C, Malhotra A, Siddiqui S, Shah P, Pandya H, Sharma P, et al. Repairing the rheumatic mitral valve in the young: the horizon revisited. *J Thorac Cardiovasc Surg Open.* 2020;1:20-8.
7. Remenyi B, Webb R, Gentles T, Russell P, Finucane K, Lee M, et al. Improved long-term survival for rheumatic mitral valve repair compared to replacement in the young. *World J Pediatr Congenit Heart Surg.* 2013;4:155-64.
8. McGurty D, Remey B, Ceunget M, Engelman D, Zannino D, Milne C, et al. Outcomes after rheumatic mitral valve repair in children. *Ann Thorac Surg.* 2019;108:792-7.
9. Krishna Moorthy PS, Sivalingam S, Dillon J, Kong PK, Yakub MH. Is it worth repairing rheumatic mitral valve disease in children? Long-term outcomes of an aggressive approach to rheumatic mitral valve repair compared to replacement in young patients. *Interact Cardiovasc Thorac Surg.* 2019;28:191-8.
10. Baumgartner H, Falk V, Bax JJ, De Bonis M, Hamm C, Holm PJ, et al. 2017 ESC/EACTS guidelines for the management of valvular heart disease. *Eur Heart J.* 2017;38:2739-91.
11. Mejia OAV, Antunes MJ, Goncharov M, Dallan LRP, Veronese E, Lapenna GA, et al. Predictive performance of six mortality risk scores and the development of a novel model in a prospective cohort of patients undergoing valve surgery secondary to rheumatic fever. *PLoS One.* 2018;13:e0199277.