

# Associating Liver Partition and Portal vein ligation for Staged hepatectomy procedure using ischemic bipartition

## Two case reports

Marcel C. C. Machado, MD, FACS, Emerson S. Abe, MD, Rodrigo Dumarco, MD, Públío Viana, MD, Marcel Autran C. Machado, MD, FACS\*

### Abstract

**Rationale:** The associating liver partition and portal vein ligation for staged hepatectomy (ALPPS) procedure is a recently introduced treatment strategy for patients with advanced primary or metastatic liver tumors and small future liver remnants. ALPPS procedure using ischemic bipartition of the liver is a modified technique that may reduce complications compared to classical ALPPS.

**Patient concerns:** Two patients with multiple colorectal liver metastasis with extensive involvement of the liver were considered unresectable before treatment because of small future liver remnant (FLR).

**Diagnoses:** Two patients were diagnosed by imaging examination with volumetry of the liver.

**Interventions:** In the first stage, ischemic bipartition of the liver is achieved using radiofrequency ablation. The Glissonian pedicles from Segment 4 are identified and ablated, the FLR is cleared, and the right portal vein is ligated. In the second stage, the typical procedure is performed, and an extended liver resection is performed.

**Outcomes:** The procedure was feasible with acceptable hypertrophy of FLRs. Blood transfusions were unnecessary, and severe postoperative complications were avoided.

**Lessons:** The ALPPS procedure with ischemic bipartition is safe and feasible and can produce results that are the same as those of the classical ALPPS procedure while reducing invasiveness during the first stage.

**Abbreviations:** ALPPS = Associating Liver Partition and Portal vein ligation for Staged hepatectomy, CT = computed tomography, FLR = future liver remnant, RF = radiofrequency.

**Keywords:** ALPPS, colorectal metastases, liver, radiofrequency, technique

## 1. Introduction

The associating liver partition and portal vein ligation for staged hepatectomy (ALPPS) procedure is a recently introduced treatment strategy for patients with advanced primary or metastatic liver tumors and small future liver remnants (FLRs). It induces greater liver hypertrophy, but initial reports show significant morbidity and mortality.<sup>[1]</sup> Since then, better patient selection and precise indications have led to better results.<sup>[2–5]</sup> Simultaneously, important technical modifications<sup>[6–11]</sup> have reduced complications, and today, the ALPPS procedure has been established and accepted worldwide.<sup>[5]</sup> However, additional

technical improvements can further reduce morbidity. We report 2 cases of modified ALPPS procedure using ischemic bipartition of the liver. This new technique may decrease complications related to the standard bipartition of the liver such as biliary leakage and infected collections that can hinder or delay the second stage. This study was approved by the review board of the Department of Surgery from our institution.

## 2. Patients and methods

### 2.1. Study

This study was approved by the review board of the Department of Surgery from our institution. Two patients underwent this new technique of ALPPS and are the object of this study. The patients gave their consent to be included in the present study.

### 2.2. Technique

In the first stage, the abdominal cavity is explored, and the liver is examined. An ischemic bipartition of the liver is then performed using radiofrequency ablation. The Glissonian pedicles from segment 4 (4a and 4b) are identified using ultrasound and color Doppler, and the point of entry for the needle is planned to ensure a safe trajectory. Ultrasound image guidance is used to precisely place the single 17-gauge ablation probes connected to the Cool-Tip 200-W RF generator (Covidien, Mansfield, MA) into the

Editor: N/A.

The authors report no conflicts of interest.

Department of Surgery, University of São Paulo, Brazil.

\* Correspondence: Marcel Autran C. Machado, Rua Dona Adma Jafet 74 cj 102, 01308-050 São Paulo, Brazil (e-mail: dr@dmarcel.com.br).

Copyright © 2018 the Author(s). Published by Wolters Kluwer Health, Inc. This is an open access article distributed under the terms of the Creative Commons Attribution-Non Commercial License 4.0 (CCBY-NC), where it is permissible to download, share, remix, transform, and buildup the work provided it is properly cited. The work cannot be used commercially without permission from the journal.

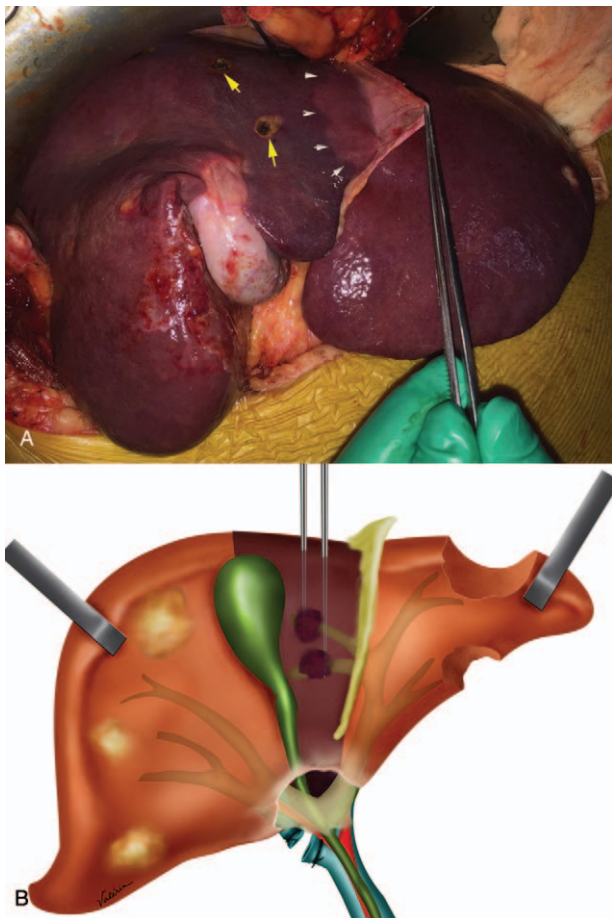
Medicine (2018) 97:31(e11656)

Received: 12 April 2018 / Accepted: 27 June 2018

<http://dx.doi.org/10.1097/MD.0000000000011656>

pedicles 1.0 cm from the left main portal trunk. Pedicle ablation is performed assuring that energy delivery is controlled to achieve a tissue temperature between 60°C and 100°C, producing coagulative necrosis and thrombosis of the pedicles over 12 minutes. All of Segment 4 becomes ischemic immediately after ablation (Fig. 1A). The lateral margin of the segment does not always follow the falciform ligament (Fig. 1A). The FLR can then be cleared by performing multiple non-anatomical resections on the left side of the liver, guided by ultrasound. The right branch of the portal vein is then ligated and transected (Fig. 1B). The Pringle maneuver is not routinely used in this step. Liver partition and liver mobilization are not performed. The patient is closed without drains.

In the second stage, the right side of the liver is fully mobilized from the retroperitoneum, diaphragm, and inferior vena cava. The procedure is carried out as usual. The right Glissonian pedicle is encircled and divided using an intrahepatic technique.<sup>[12]</sup> The liver is divided between segment 4 and the left lateral segment, and the middle and right hepatic veins are divided. A right trisectionectomy ( $\pm$  segment 1) is completed, and a closed suction drain is left in place after fixation of the FLR to the abdominal wall.



**Figure 1.** Ischemic bipartition Associating Liver Partition and Portal vein ligation for Staged hepatectomy. (A) Intraoperative photograph after radiofrequency ablation of the segment 4 pedicles (entrance points, yellow arrows). Note that the margin between segment 3 and left lateral section (segments 2 and 3) does not correspond to the falciform ligament (white arrows). (B) Schematic drawing of the technique. Ischemic bipartition of the liver along with right portal vein ligation and clearance of the future liver remnant.

### 3. Case report

#### 3.1. Case 1

The first patient was a 51-year-old woman with multiple liver metastasis. The patient had undergone right colectomy for removal of the primary tumor 5 months earlier and received irinotecan neoadjuvant chemotherapy before the liver surgery. The patient was considered unresectable because of the number of metastases (20) and the number of liver segments involved (7/8). The FLR was extremely small (Fig. 2A), and the only option would be an ALPPS procedure. The patient presented objective response after chemotherapy and was eligible to this complex liver procedure. The patient was submitted to a modified ALPPS procedure using ischemic bipartition of the liver that resulted in hypertrophy of the FLR with increase of 87.5% in volume (Fig. 2B). The second stage of ALPPS was then performed 3 weeks after first stage. Blood loss was 120 mL and 160 mL, respectively, and no blood transfusion was necessary. No severe postoperative complications were found, and the patient was discharged at 4<sup>th</sup> and 6<sup>th</sup> postoperative day after first and second stage, respectively.

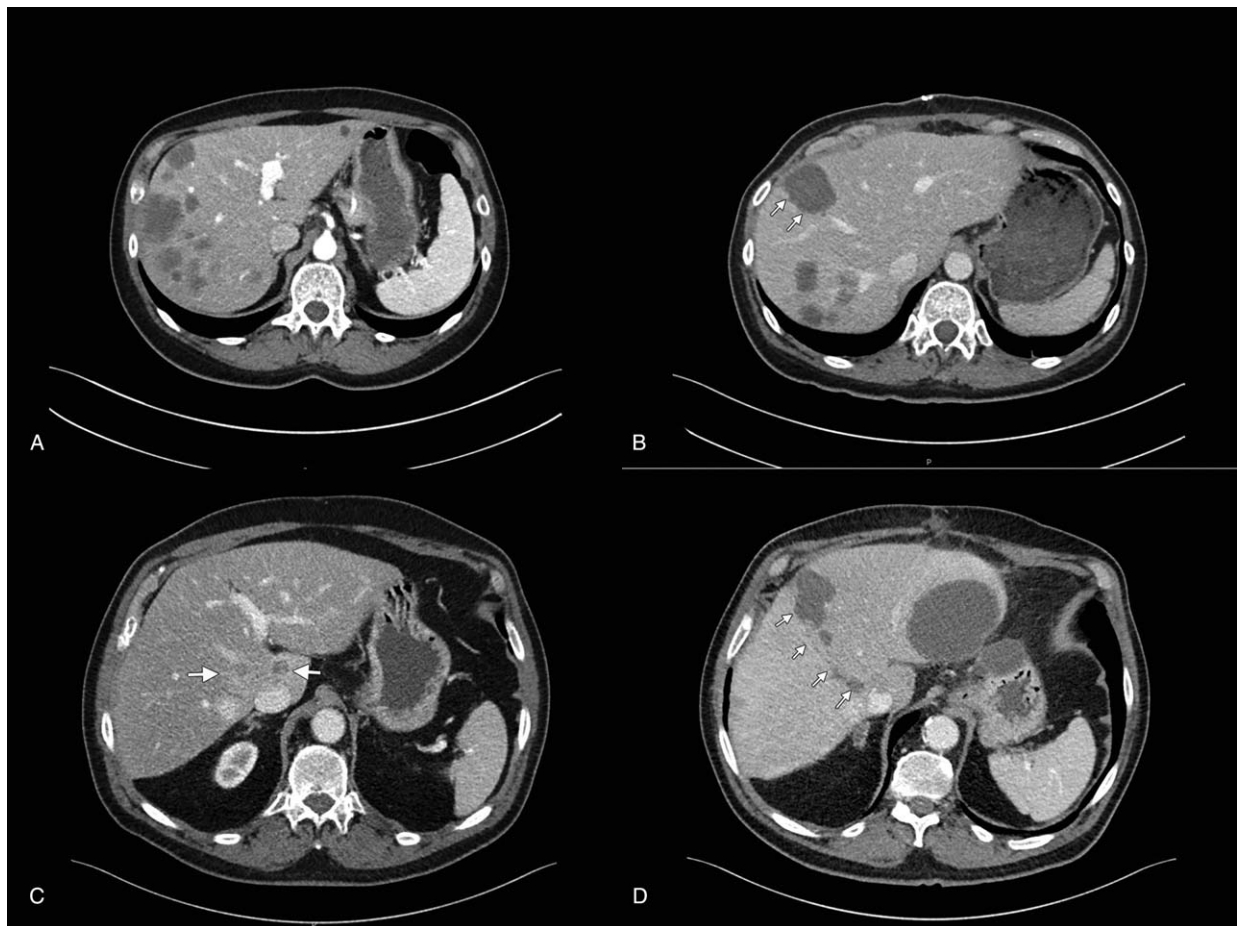
#### 3.2. Case 2

The second patient was a 69-year-old man with multiple liver metastases. The patient presented with medical history of pulmonary emphysema and systemic arterial hypertension. The patient had undergone left colon resection for removal of the primary tumor (upper rectum) 12 months earlier and received oxaliplatin-based neoadjuvant chemotherapy before the liver surgery. The patient was considered unresectable because of the number of metastases (12) and the number of liver segments involved (8/8). The FLR was extremely small (Fig. 2C), and the only option would be an ALPPS procedure. Objective response after chemotherapy was obtained and conversion to resectable disease was achieved and the patient was submitted to a modified ALPPS procedure using ischemic bipartition of the liver. The hypertrophy of the FLR was 50% in volume (Fig. 2D). The second stage of ALPPS was then performed 24 days after the first stage. Blood loss was 350 mL and 530 mL, respectively, but no blood transfusion was necessary. The patient presented mild respiratory distress (pulmonary emphysema) that was treated conservatively, resulting in a good outcome involving a prolonged hospitalization. The patient was discharged at 7<sup>th</sup> and 13<sup>th</sup> postoperative day after first and second stage, respectively.

### 4. Discussion

The ALPPS procedure emerged with exceptionally fast liver growth, enabling a greater resectability rate compared to classical ALPPS, even in patients with extremely small FLRs. As with many new surgical procedures, the ALPPS procedure experienced unfavorable initial outcomes, and some hepatobiliary centers ceased performing it. However, the ALPPS procedure continuously improved through better patient selection and technical refinements. Recent analysis by the International ALPPS Registry showed that technically modified ALPPS procedures were developed, and safety was improved by reducing the invasiveness of Stage 1.<sup>[5]</sup> Our modified ALPPS procedure uses ischemic bipartition, eliminating liver transection via a tourniquet or radiofrequency ablation along the planned transection line.

We successfully used the procedure in 2 consecutive patients. In one, complete ischemia of Segment 4 was not reached, likely the



**Figure 2.** Ischemic bipartition Associating Liver Partition and Portal vein ligation for Staged hepatectomy radiological study. (A) Case 1. Preoperative computed tomography (CT) scan shows bilateral colorectal liver metastases with small future liver remnant (FLR). (B) Case 1. CT scan after stage 1 shows partial ischemic segment 4 (arrows) with great hypertrophy of FLR. (C) Case 2. Preoperative CT scan shows liver metastases in the caudate lobe extended to segment 4 (arrows). There are other numerous small lesions spread in the right liver (not shown). (D) Case 2. CT scan after stage 1 shows complete ischemic segment 4 (arrows), area of previous resection of metastases on the FLR and great hypertrophy of FLR.

result of technical problems experienced during radiofrequency ablation of the pedicles, resulting in a partial ALPPS. However, this patient presented considerable liver hypertrophy (85%) consistent with that seen in the available literature on partial ALPPS.<sup>[9]</sup> In another, ischemia of Segment 4 was complete, and a postoperative computed tomography scan showed clear definition of the FLR. However, hypertrophy in the FLR was comparatively inferior in this patient, possibly related to the quality of the tissue (it was relatively more damaged) and to longer chemotherapy involving >1 regimen.<sup>[13]</sup> A study by the International ALPPS Registry showed that chemotherapy itself does not negatively affect growth of the FLR.<sup>[13]</sup> Regardless the hypertrophy rate, both patients achieved enough growth to warrant proceeding to the second stage.

The primary advantage of this technique is that it allows a degree of liver hypertrophy that typically requires liver transection. Liver partition is typically followed by collection of tissue that could contain bile or blood and that could impose an infection that compromises or postpones the second stage. Ablation of the pedicles from Segment 4 is not technically demanding, and it yields the exact anatomical line between Segment 4 and the left lateral segment, which is not always along the falciform ligament (Fig. 1A). The tourniquet technique is an

effective technique,<sup>[7]</sup> but requires that a certain amount of pressure be applied along the compressed liver to produce the same effect, possibly causing disruption of the liver parenchyma. Radiofrequency-assisted ALPPS is also effective, but the correct plane of transection is not always easy to define, and great expertise is required to reproduce it.<sup>[8]</sup> When clearance of the FLR is unnecessary, ischemic bipartition ALPPS or radiofrequency-assisted ALPPS can be performed, wherein the first stage can be performed percutaneously.<sup>[14]</sup>

In the ischemic bipartition ALPPS procedure, an ischemic Segment 4 can safely be left in place, promoting a degree of FLR hypertrophy similar to that seen with the classical ALPPS procedure, at least in these 2 initial cases. Use of this new variant of the ALPPS procedure would avoid interstage complications and improve the safety of the procedure by reducing invasiveness in the first stage. Other variations of the ALPPS procedure also reduced invasiveness, thus improving safety.<sup>[5]</sup>

In conclusion, ischemic bipartition ALPPS is a safe and feasible procedure that could produce results that are the same as those seen with classical ALPPS while reducing invasiveness in the first stage. It could improve the safety of the ALPPS procedure. Further comparative studies employing more patients are needed to confirm these preliminary results.

## Author contributions

**Conceptualization:** Marcel C Machado, Emerson S Abe, Rodrigo Dumarco.

**Formal analysis:** Marcel C Machado, Emerson S Abe, Rodrigo Dumarco, Publio Viana, Marcel Autran Machado

**Investigation:** Marcel C Machado, Emerson S Abe, Rodrigo Dumarco, Publio Viana, Marcel Autran Machado

**Methodology:** Marcel C Machado, Emerson S Abe, Rodrigo Dumarco, Marcel Autran Machado.

**Writing – original draft:** Marcel Autran Machado.

**Writing – review & editing:** Marcel C Machado, Publio Viana, Marcel Autran Machado.

## References

- [1] Schnitzbauer AA, Lang SA, Goessmann H, et al. Right portal vein ligation combined with in situ splitting induces rapid left lateral liver lobe hypertrophy enabling 2-staged extended right hepatic resection in small-for-size settings. *Ann Surg* 2012;255:405–14.
- [2] Schadde E, Raptis DA, Schnitzbauer AA, et al. Prediction of mortality after ALPPS stage-1: an analysis of 320 patients from the International ALPPS Registry. *Ann Surg* 2015;262:780–5.
- [3] Herman P, Krüger JA, Perini MV, et al. High mortality rates after ALPPS: the devil is the indication. *J Gastrointest Cancer* 2015;46:190–4.
- [4] Linecker M, Stavrou GA, Oldhafer KJ, et al. The ALPPS risk score: avoiding futile use of ALPPS. *Ann Surg* 2016;264:763–71.
- [5] Linecker M, Björnsson B, Stavrou GA, et al. Risk adjustment in ALPPS is associated with a dramatic decrease in early mortality and morbidity. *Ann Surg* 2017;266:779–86.
- [6] Machado MA, Makdissi FF, Surjan RC. Totally laparoscopic ALPPS is feasible and may be worthwhile. *Ann Surg* 2012;256:e13.
- [7] Robles R, Parrilla P, Lopez-Conesa A, et al. Tourniquet modification of the associating liver partition and portal ligation for staged hepatectomy procedure. *Br J Surg* 2014;101:1129–34.
- [8] Gall TM, Sodergren MH, Frampton AE, et al. Radio-frequency-assisted Liver Partition with Portal vein ligation (RALPP) for liver regeneration. *Ann Surg* 2015;261:e45–6.
- [9] Petrowsky H, Gyori G, de Oliveira M, et al. Is partial-ALPPS safer than ALPPS? A single-center experience. *Ann Surg* 2015;261:e90–2.
- [10] de Santibanes E, Alvarez FA, Ardiles V, et al. Inverting the ALPPS paradigm by minimizing first stage impact: the Mini-ALPPS technique. *Langenbecks Arch Surg* 2016;401:557–63.
- [11] Machado MA, Makdissi FF, Surjan RC, et al. Transition from open to laparoscopic ALPPS for patients with very small FLR: the initial experience. *HPB (Oxford)* 2017;19:59–66.
- [12] Machado MA, Herman P, Machado MC. A standardized technique for right segmental liver resections. *Arch Surg* 2003;138:918–20.
- [13] Hasselgren K, Malagò M, Vyas S, et al. Neoadjuvant chemotherapy does not affect future liver remnant growth and outcomes of associating liver partition and portal vein ligation for staged hepatectomy. *Surgery* 2017;161:1255–65.
- [14] Hong de F, Zhang YB, Peng SY, et al. Percutaneous microwave ablation liver partition and portal vein embolization for rapid liver regeneration: a minimally invasive first step of ALPPS for hepatocellular carcinoma. *Ann Surg* 2016;264:e1–2.