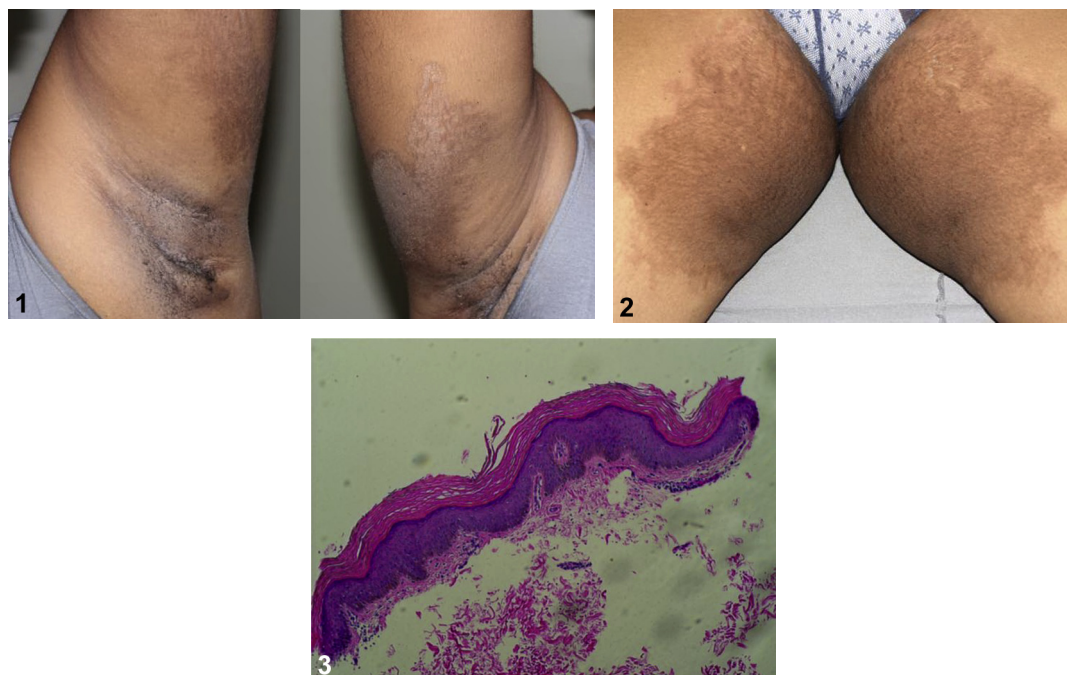


# Chronic symmetrically distributed hyperpigmented plaques in a middle-age woman



Etsubdenk Ajebo, BS, Weston B. Wall, MD, and Loretta S. Davis, MD  
Augusta, Georgia

**Key words:** erythrokeratoderma variabilis; progressive symmetric erythrokeratoderma.



A healthy woman complained of brown spots on her extremities. They began in childhood as fluctuating, migratory erythematous patches that worsened during pregnancy and eventually became fixed and darker. Her brother has similar findings. Topical corticosteroids did not help. Examination found well-defined hyperpigmented plaques with scalloped borders and fine scale symmetrically distributed on her upper arms, medial thighs, elbows, and gluteal cleft (Figs 1 and 2). The thigh plaques had erythematous borders. Palms, soles, nails, hair, teeth, and mucosa were normal. Biopsy found hyperkeratosis, foci of parakeratosis, mild epithelial hyperplasia, papillomatosis, and mild superficial perivascular lymphocytic infiltrate (Fig 3). Potassium hydroxide preparation (KOH prep) and Wood's lamp examination were negative.

## Question 1: What is the most likely diagnosis?

- A. Erythrokeratolysis hiemalis
- B. Erythrasma
- C. Tinea corporis and cruris
- D. Erythrokeratoderma variabilis (EKV)
- E. Progressive symmetric erythrokeratoderma (PSEK)

From the Department of Dermatology at the Medical College of Georgia at Augusta University.

Funding sources: None.

Conflicts of interest: None disclosed.

Correspondence to: Weston Wall, MD, 1004 Chafee Ave, Augusta, GA 30904. E-mail: [wwall@augusta.edu](mailto:wwall@augusta.edu).

JAAD Case Reports 2019;5:249-51.

2352-5126

Published by Elsevier on behalf of the American Academy of Dermatology, Inc. This is an open access article under the CC BY-NC-ND license (<http://creativecommons.org/licenses/by-nc-nd/4.0/>).

<https://doi.org/10.1016/j.jdc.2018.12.008>

**Answers:**

**A.** Erythrokeratolysis hiemalis – Incorrect. This autosomal dominant condition is characterized by episodic/seasonal circinate, erythematous plaques with scaling, and centrifugal peeling. It predominantly involves palms and soles and may extend up the extremities. It rarely involves the trunk and face. Blisters occasionally occur in the center of new plaques.<sup>1</sup>

**B.** Erythrasma – Incorrect. Erythrasma is caused by *Corynebacterium minutissimum* overgrowth in the stratum corneum. Well-defined scaly plaques involve intertriginous sites of the trunk and toes. Coral red fluorescence on Wood's lamp examination is classic and was negative in this patient's case.

**C.** Tinea corporis and cruris – Incorrect. Tinea corporis and cruris are dermatophyte infections of the trunk, extremities, and groin, respectively. Classic lesions have advancing, scaly border and central clearing. Hyphae are seen on histopathology and potassium hydroxide preparation (KOH prep).

**D.** EKV – Correct. EKV, an autosomal dominant disorder, presents with transient erythematous patches and stable hyperkeratosis. Individual erythematous lesions persist for minutes to hours, although they may last for days. Simultaneously or over time hyperkeratosis evolves. Sharply demarcated, yellow-brown to pink-brown plaques with figurate borders progressively develop on the limbs, buttocks, and trunk in nearly symmetrical distribution. Histopathology shows orthokeratosis, basket-weave hyperkeratosis, moderate-to-severe acanthosis with prominent granular layer, papillomatosis, and dilated elongated capillaries with minimal perivascular inflammation in the papillary dermis.<sup>2</sup>

**E.** PSEK – Incorrect. PSEK begins during infancy or early childhood with fixed, sharply demarcated polycyclic hyperkeratotic plaques on erythematous base with fine scale or a rough, verrucous surface. They are symmetrically distributed on extremities, buttocks, face, and occasionally the trunk. Transient erythema and relative sparing of the face differentiate EKV from PSEK.<sup>2</sup>

**Question 2: What is the most likely mutation associated with this patient's disease?**

- A.** *GJB3* and *GJB4*
- B.** *SPINK5*
- C.** *KRT14*
- D.** *LOR*

**E. *KRT1* and *KRT10*****Answers:**

**A.** *GJB3* and *GJB4* – Correct. EKV is a disorder of cornification associated with noninflammatory erythema caused by dominant mutations in the connexin genes *GJB3* and *GJB4* clustered on human chromosome 1p35.1.<sup>2</sup> Connexins are transmembrane proteins that form intercellular channels. Mutations result in altered activity of gap junctions and cause impaired epidermal differentiation. Commercial genetic testing is available to identify missense mutations in the coding sequence of the *GJB3* and *GJB4* genes. Further information can be found at <https://www.genedx.com/test-catalog/disorders/erythrokeratoderma-variabilis-ekv>.

**B.** *SPINK5* – Incorrect. *SPINK5* is a serine protease inhibitor kazal type 5 gene that is expressed in the lamellar granules of epithelium; its mutation results in increased proteolytic activity in the stratum corneum. *SPINK5* mutation causes Netherton syndrome, an autosomal recessive disorder that may include clinical features of ichthyosis linearis circumflexa.<sup>3</sup>

**C.** *KRT14* – Incorrect. *KRT14* plays a role in regulating apoptosis during morphogenesis of cutaneous appendages; its mutation results in susceptibility of keratinocytes to tumor necrosis factor  $\alpha$ -induced apoptosis. *KRT14* mutation causes dermatopathia pigmentosa reticularis, an autosomal dominant disorder.<sup>4</sup>

**D.** *LOR* – Incorrect. The *LOR* gene encodes loricrin, a glycine-rich cornified envelope protein. Mutation in loricrin interferes with the regulation of cornification and causes loricrin keratoderm.<sup>5</sup>

**E.** *KRT1* and *KRT10* – Incorrect. *KRT1* and *KRT10* are expressed in the spinous and granular layers of epidermis and are active in the barrier function of epidermis. Mutations in *KRT1* and *KRT10* cause annular epidermolytic ichthyosis.<sup>5</sup>

**Question 3: What is the treatment of choice in patients with extensive skin involvement from this disease?**

- A.** Topical pimecrolimus
- B.** Oral retinoids
- C.** Narrow-band ultraviolet B therapy
- D.** Topical tretinoin
- E.** Ketoconazole cream

**Answers:**

**A.** Topical pimecrolimus — Incorrect. Topical pimecrolimus has shown no benefit in the treatment of EKV but can be used to treat ichthyosis linearis circumflexa.<sup>3</sup>

**B.** Oral retinoid — Correct. Treatment of EKV is symptomatic and depends on the severity and extent of hyperkeratosis. Topical management with keratolytic agents such as lactic acid, urea,  $\alpha$  hydroxy acids and tretinoin might be sufficient for mild disease. Systemic retinoids such as acitretin and isotretinoin are the treatment of choice for extensive EKV.<sup>2</sup>

**C.** Narrow-band ultraviolet B therapy — Incorrect. Narrow-band ultraviolet B therapy has shown no benefit in the treatment of EKV but can be used to treat ichthyosis linearis circumflexa.<sup>3</sup>

**D.** Topical tretinoin — Incorrect. Topical tretinoin helps in mild cases of EKV but not in severe or more extensive EKV.<sup>2</sup>

**E.** Ketoconazole cream — Incorrect. Ketoconazole cream has shown no benefit in the treatment of EKV but can be used to treat cutaneous dermatophyte infections.

**Abbreviations used:**

EKV: erythrokeratoderma variabilis

PSEK: progressive symmetric erythrokeratoderma

**REFERENCES**

1. Starfield M, Hennies HC, Jung M, et al. Localization of the gene causing keratolytic winter erythema to chromosome 8p22-p23, and evidence for a founder effect in South African Afrikaans-speakers. *Am J Hum Genet.* 1997;61(2):370-378.
2. Karadag AS, Bilgili SG, Calka O, Bayram I. Erythrokeratoderma variabilis: Two case reports. *Indian Derm Online J.* 2013;4(4):340.
3. Saleem MHK, Shahid MF, Shahbaz A, Sohail A, Shahid MA, Sachmechi I. Netherton syndrome: a case report and review of literature. *Cureus.* 2018;10(7):e3070. <https://doi.org/10.7759/cureus.3070>.
4. Al Saif F. Dermatopathia pigmentosa reticularis: report of a new cases and literature review. *Indian J Dermatol.* 2016;61(4):468.
5. Takeichi T, Akiyama M. Inherited ichthyosis: non-syndromic forms. *J Dermatol.* 2016;43:242-251.