



Case Report

Peritoneal melanosis associated with serous carcinoma of the ovary: A case report and literature review



Mohammed Mhand^{a,b,*}, Rockson Obed^{a,b}, Abdelhakim Harouachi^{a,b}, Anas Haloui^{b,c}, Tariq Bouhout^{a,b}, Amal Bennani^{b,c}, Badr Serji^{a,b}, Tijani EL. Harroudi^{a,b}

^a Surgical Oncology Department, Regional Oncology Center, Mohammed VI University Hospital, Oujda, Morocco

^b Mohammed First University Oujda, Faculty of Medicine and Pharmacy Oujda, Oujda, Morocco

^c Pathology Department, Mohammed VI University Hospital, Oujda, Morocco

ARTICLE INFO

Keywords:

Peritoneal melanosis
Serous carcinoma of the ovary
Ovarian tumor
Peritoneal carcinosis
Chemotherapy

ABSTRACT

Introduction: Melanosis peritonei is an exceptionally benign condition of uncertain origin marked by the deposition of dark pigments on the peritoneal cavity. It's usually associated with other abnormalities and must be differentiated from metastatic melanoma.

Case presentation: We report this case of a 67-year-old female presented for abdominal distension for 16 months. Abdomino-pelvic CT scan showed a right pelvic ovarian mass locally developed with the presence of peritoneal ascites. We performed initially an exploratory laparotomy confirmed the radiological constatations with biopsies of the peritoneal carcinosis. Histologic analysis showed a poorly differentiated carcinomatous cell. The patient benefited from neoadjuvant chemotherapy then an abdomino-pelvic CT scan of control was performed showing the reduction in size of the ovarian mass and dispersion of the abdominal effusion. A second laparotomy was carried out and the exploration showed the appearance of dark nodules on the peritoneum. Hysterectomy associated with appendectomy and omentectomy with biopsy of the dark nodules was performed. Pathological study and immunohistochemical staining confirmed the diagnosis of benign peritoneal melanosis associated with serous carcinoma of the ovary.

Discussion: Peritoneal melanosis is a rare condition with only 18 cases reported on the English literature. It is often associated with other conditions. The origin of this lesion still unclear although some hypotheses were reported. The main differential diagnosis is metastatic melanoma with very poor prognosis.

Conclusion: benign peritoneal melanosis is a rare condition. Its management depends essentially on the associated disease.

1. Introduction

Peritoneal melanosis (PM) is a rare unusual benign entity, characterized by the deposit of diffuse or focal, black to gray or brown pigmentation in the abdominal cavity. The nature of the pigmentation is still unclear as the features are consistent with melanin or non-melanin pigments [1,2]. Although generally considered as a benign condition, it is mostly associated with other disorders such as desmoid ovarian cyst, enteric duplication cyst, gastric triplication, and ovarian cystadenomas [3] (see Table 1).

Herein, we report an unusual case of PM in a 67-year-old patient which was revealed as a surprise during exploratory laparotomy and the diagnosis was confirmed after histopathological study. We decided to

report this case due to its rarity highlighting the unusual mode of revelation and discussing the diagnostic and therapeutic modalities. This case has been reported following the SCARE criteria 2020 [22].

2. Case presentation

A 67-year-old female patient, gravida 6, para 5, with a medical history of type 2 diabetes on insulin, hypertension on amlodipin 5mg 1 tablet/day, WHO status (World health organization performance score) of 1, BMI at 21.2 Kg/m², presented with abdominal distension and altered general health evolving for 16 months. The patient was used a combined oral contraceptive for menstrual regulation. Surgical history was unremarkable. There are no proven genetic abnormalities in her

* Corresponding author. Surgical Oncology Department, Regional Oncology Center, Mohammed VI University Hospital, Oujda, Morocco.

E-mail address: m.mhand@ump.ac.ma (M. Mhand).

<https://doi.org/10.1016/j.amsu.2022.104452>

Received 18 July 2022; Received in revised form 10 August 2022; Accepted 12 August 2022

Available online 18 August 2022

2049-0801/© 2022 The Authors. Published by Elsevier Ltd on behalf of IJS Publishing Group Ltd. This is an open access article under the CC BY-NC-ND license (<http://creativecommons.org/licenses/by-nc-nd/4.0/>).

Table 1
Summary of published reports on comparison with our case.

Author/year	Patient gender and age	Mode of revelation	Association with other tumors	Association with melanoma	Immunohistochemical analysis	Treatment	follow up, and outcomes
Our case	67 F	abdominal distension	-Serous carcinoma of the ovary.	No	–	-Chemotherapy -Hysterectomy + bilateral adnexectomy + appendectomy + Omentectomy + biopsy of epiploic nodules	- 6 months after the operation, the patient is going well.
Barghash et al., 2021 [5]	86 M	-Large right inguinal hernia	-ADK of the sigmoid Colon	No	CD 68: +	-Hernia repair + endoscopic resection of a sigmoidal polyp.	- No surgical resection. - Regular surveillance.
Kwang Kiat Sim et al, 1 2021 [14]	–	–	-Metastatic melanoma evolving the spleen.	Yes	–	–	–
Ea-sle Chang et al. 2015 [6]	23 F	-Fresh blood in the stools.	Adenocarcinoma of the rectum	No	-CD68: + -HMB-45:	-laparoscopic anterior resection of the rectum	- No signs of cancer recurrence
Jamkhandi et al., 2014 [3]	20 F	pre-term labor pains and fetal distress at the 35th week of gestation	In pregnancy	No	Data unavailable	-right salpingo-oophorectomy	–08 months postpartum, both newborn and mother are doing well
Lim et al. 2012 [7]	79F	abdominal pain with history of a desmoplastic melanoma on her right anterior leg had been excised.	metastatic melanoma involving the omentum	Yes	S 100: + HMB 45: + Melan A: +	-Resection of the epiploic mass, the mesocolic nodule and part of the peritoneum.	–02 years after the operation, the patient passed away.
Hirasawa et al, 1 2012 [15]	42 F	polycystic mass of the uterine cervix on Gynecological physical examination	-Lobular endocervical glandular hyperplasia + Peutz–Jeghers syndrome	No	HIK1083 +	-modified radical hysterectomy and bilateral salpingo-oophorectomy	–
Dragoslav Miljković et al., 2011 [16]	76 M	bloody stools with altered general condition	MELANOMA OF THE ANAL CANAL	Yes	S-100: +	-Chemotherapy with remission.	-One year after the initial diagnosis, patient died of intra-abdominal metastases.
Kim et al., 2010 [2]	68 F	lower abdominal pain and distension that	-Mucinous Cystadenoma of the Ovary - Adenocarcinoma of the Colon	None	CD68: + S-100: HMB-45:	- Modified radical hysterectomy with bilateral salpingo-oophorectomy, a bilateral pelvic lymph node dissection, and a low anterior resection.	–
Kim et al., 2002 [13]	23 F	Palpable pelvic mass.	-Serous cystadenoma of the ovary.	None	S100: HMB-45: CD68: + Lysosome: + α-1-antitrypsin: + α-1-antichymotrypsin: + E-cadherin: + N-cadherin: +	-Right salpingo-oophorectomy, appendectomy and omental biopsy were undertaken.	-Free of tumor after 5 year and half of follow up.
Richard et al., 2001 [1]	27 F	Severe left iliac fossa pain	-Ovarian Dermoid Cyst	None	None	A left salpingo-oophorectomy and biopsies of the peritoneal and omental pigmented lesions	–
Nada et al, 1 2000 [17]	1 and a half F	–	-Enteric duplication cyst	None	–	–	–
Luis et al., 1997 [9]	6 months	asymptomatic abdominal mass in the upper abdomen that	-Gastric triplication	None	-LN-5: + -PS-100: + -HMB-45: +	-Resection of 2 gastric masses, Appendectomy, and biopsies of the peritoneum and omentum	- Asymptomatic after 3 years of follow up.
Jung et all 1996 [10]	2 F	–	-Enteric duplication	None	–	–	–
Drachenberg C et all 1990 [8]	–	–	-Melanotic peritoneal cyst	–	–	–	–
Sahin et al, 1 1990 [18]	28 F	–	ovarian mature cystic teratoma	–	–	–	–

(continued on next page)

family. The clinical examination found a distended abdomen with diffuse dullness. The patient reported a chronic pain in the hypogastrium with severity of 3 in 10 of 3 months duration.

The findings of laboratory tests were unremarkable. The tumor marker CA-125 was very high at 4337 IU/ml (normal value < 35 IU/ml). The thoracic and abdomino-pelvic computed tomography scan showed a locally advanced right pelvic ovarian mass measuring 110 × 84 × 82mm. These radiological explorations objected a probable invasion of the uterus and the anterior rectal wall, with presence of several peritoneal carcinosis and abundant pleural effusion (Fig. 1). There was no secondary metastatic lesion of the liver or lungs. Recto-sigmoidoscopy was normal.

The case was analyzed by a multidisciplinary committee, and the decision was to perform an exploratory laparotomy. During exploration, we found an abundant ascitic fluid with generalized peritoneal carcinosis, and a locally advanced bilateral ovarian mass invading the uterus and small bowel. A surgical biopsy of the carcinosis nodule was performed. The pathological study showed enlarged fibrofatty tissue infiltrated by a carcinomatous process arranged in nests and solid, cribriform masses. The tumor cells are enlarged, with hyperchromatic nuclei, marked anisokaryosis and abundant eosinophilic cytoplasm. The immunohistochemical staining objected a poorly differentiated carcinomatous cell expressing WT1, CK7 and CK20 in favor of an ovarian origin (Fig. 2).

The patient was referred to the oncology department and received 7 courses of chemotherapy consisting of a combination of carboplatin (AUC 5), Paclitaxel (175mg/m³), and bevacizumab 7,5mg/kg (used as a maintenance therapy alongside another drug) with good clinical response and radiological stability.

Abdomino-pelvic CT scan of control showed a heterogeneously enhancing, solid-cystic, pelvic mass with lobulated contours, encompassing the uterus, bounded anteriorly by the gastrointestinal tract and laterally by the bladder, of reduced size measuring 46 × 32mm compared to the previous CT scan (Fig. 3). Subsequently, a second exploratory laparotomy (second look) was indicated. Intra-operative exploration found a persistence of the right ovarian mass that remained attached to the sigmoid, rectum and bladder with the appearance of several parietal and pelvic nodules of dark-brown color. We performed a hysterectomy associated with appendectomy and omentectomy with biopsy of the burned nodules (Fig. 4).

Pathological study and immunohistochemical staining revealed tumor residues of a high-grade serous carcinoma on both ovaries, and a well-limited histiocytic proliferation containing numerous large brownish pigments in their cytoplasm, stained by Perls and Fontana on the brown nodules (Fig. 5). Based on these data, a diagnosis of benign peritoneal melanosis associated with serous carcinoma of the ovary was made. The postoperative course was simple and the patient was discharged 7 days after surgery. The multidisciplinary committee decided

clinical and radiological surveillance. No adjuvant chemotherapy was used. The patient is doing well after a follow up of 1 year without recurrence.

3. Discussion

The first case of peritoneal melanosis was reported by Afonso in 1962 secondary to the rupture of a bilateral ovarian cystic teratoma⁴. Up-to-date, only 18 cases have been reported in the English literature [5]. It is an extremely rare condition affecting women between the ages of 18 and 28 year with only 1 of the cases reported in male [6]. It may be incidentally encountered during the course of an exploratory laparotomy [3]. The condition is associated with ovarian lesions in 57% of the cases [7]. organs frequently affected are the ovaries, peritoneum, omentum, appendix, enteric cyst, intestine, liver and gallbladder [3].

The present case is a documented report of peritoneal melanosis discovered after two exploratory laparotomies. In previous cases, there have been conflicting reports regarding the exact source and nature of the pigment. Among the recognized theories, spillage of pigment from ruptured ovarian teratomas is the most accepted. It was proposed that the melanin was produced in the cystic teratoma and with its rupture, the spilled pigment was phagocytosed by histiocytes and deposited within the peritoneum [4,5]. In addition, some authors have hypothesized that the pigmentation originated from hemorrhage in the teratoma containing the gastric mucosa and gastric ulceration [1] but those theories are only validated for cases associated with a ruptured ovarian teratoma.

Another theory proposes that excessive migration of neural crest cells before the 10th week of development leads to the formation of pigmented mesothelial cells and dendritic melanocytes in the peritoneum. An additional hypothesis is that pigmentation originates from neural crest cells through a defect in the regression of the neuroenteric duct [8,9]. A different hypothesis proposed for the case associated with enteric duplication is that the source of melanin was the basal cells of the esophageal mucosa within the ruptured enteric cyst, this hypothesis was confirmed by the observation that megaloblasts can be derived not only from neural crest epithelium, but also from stem cells of the esophageal mucosa [10]. In peritoneal melanosis associated with metastatic melanoma, it has been proposed that the melanin present in macrophages is derived from the pigment of tumor cells [7,11].

The main differential diagnosis, which can associate or no, to the peritoneal melanosis is metastatic melanoma [7,8,11]. It has a poor prognosis in comparison with benign peritoneal melanosis. Metastatic melanoma may share the same macroscopical aspect, although it forms large masses rather than small nodules [12]. It has to be differentiated by identifying the primary lesion, the reason that impose a clear examination of the skin, the anorectal canal and the ocular epithelium [7]. Microscopically, metastatic melanoma cells can be identified using

Table 1 (continued)

Author/year	Patient gender and age	Mode of revelation	Association with other tumors	Association with melanoma	Immunohistochemical analysis	Treatment	follow up, and outcomes
M.Fukushima et al., 1984 [19]	28 F	Large pelvic mass	Dermoid cyst of the ovary	None	None	-Left salpingo-oophorectomy, appendectomy, and peritoneal and omental biopsies.	-Disease free tumor. - 03 years and 3 months.
Lee et al., 1975 [20]	27 F	distended lower abdomen and dysuria	-Ovarien dermoid cyst -Mucinous cystadenoma	None	None	-bilateral oophorectomy and an omental biopsy.	-
Afonso et al, 1962 [21]	18 F	Abdominal swelling	-Ovarien cyst	None	None	Total hysterectomy + Bilateral salpingo-oophorectomy + appendectomy + Biopsies of peritoneum	remained asymptomatic and entirely well since the last operation

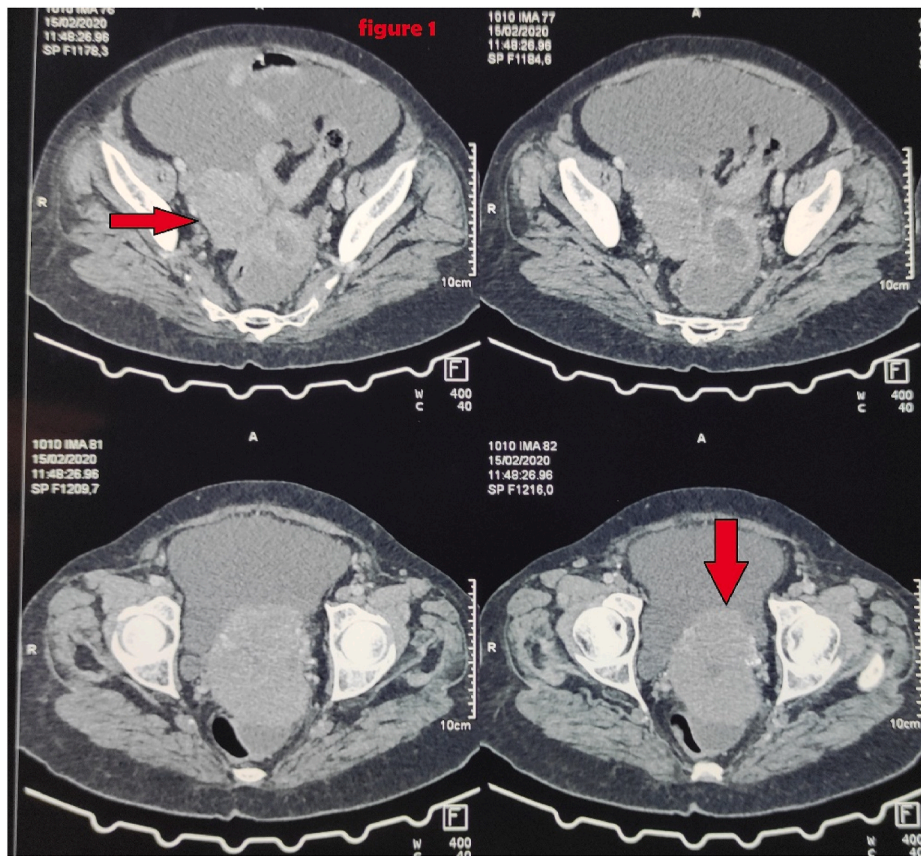


Fig. 1. Enhanced abdomino-pelvic computed tomography scan showed a right pelvic ovarian mass measuring 110 × 84 × 82mm (arrow).

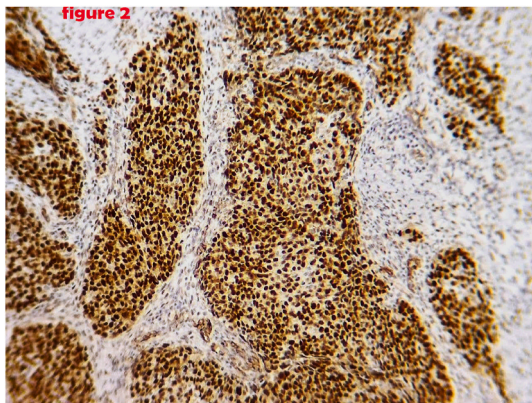


Fig. 2. Immunohistochemical analysis showed diffuse strong WT1 positivity.

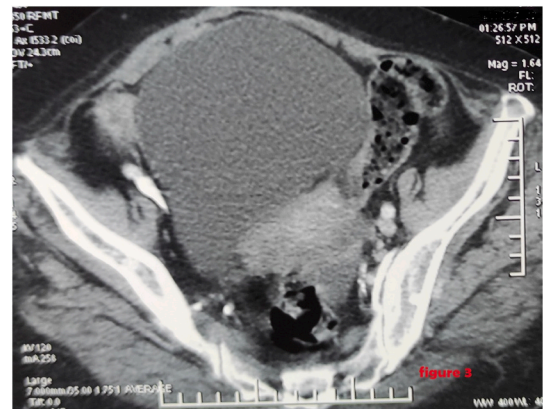


Fig. 3. CT scan of control showed a solid-cystic, pelvic mass with lobulated contours, encompassing the uterus.

hematoxylin and eosin-stained sections, and by using immunohistochemical staining with S-100 and HMB-45 [7,11].

Another condition that can mime peritoneal melanosis is peritoneal endometriosis. It is dark brown in color and can be distinguished histologically by identifying endometrial glands surrounded by stroma and the presence of macrophages carrying hemosiderin. This can be confirmed using immunohistochemical staining with CD10. A rare condition reported that can be distinguished from peritoneal melanosis by histochemical methods using Fontana Masson staining is Peritoneal lipofuscinosis [2,13]. Different condition reported is the diffusion of Indian ink from a preoperative endoscopic tattoo, but without pathological significance.

4. Conclusion

To our best knowledge, this is the first case associated with serous carcinoma of the ovary. The major differential diagnosis with poor prognosis is metastatic melanoma.

Ethical approval

No ethical approval necessary.

Sources of funding

The author(s) received no financial support for the research,

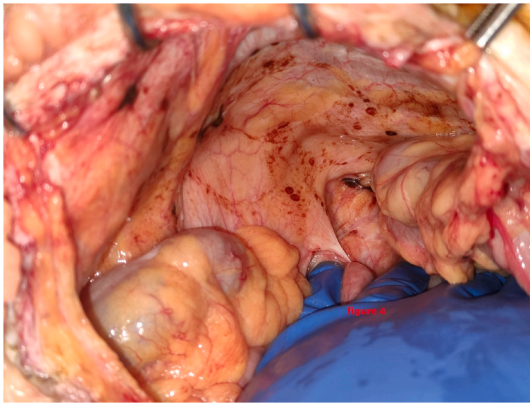


Fig. 4. Intraoperative view of burned nodules.

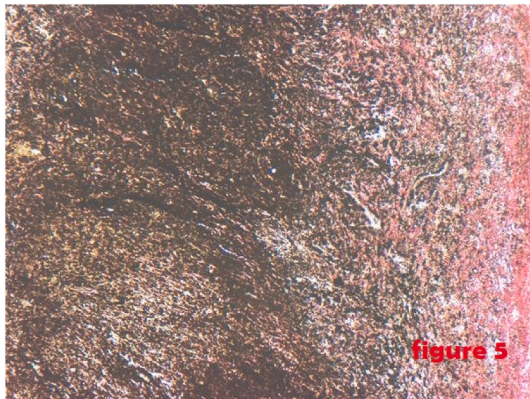


Fig. 5. Photomicrograph showing a well-limited histiocytic proliferation stained by Perls and Fontana on the brown nodules. (For interpretation of the references to color in this figure legend, the reader is referred to the Web version of this article.)

authorship and/or publication of this article.

Author contribution

Dr Mhand Mohammed: m.mhand@ump.ac.ma Have written the article, have consulted the patient, prescribed all of the tests and prepared the patient for surgery and participated in the surgery.

Dr Obed Rockson onnifer1@gmail.com: have helped writing the article, data collection.

Dr Harouachi Abdelhakim Abdelhakim.harouachi@gmail.com: Data collection.

Dr Haloui Anass: Interpretation of histological data.

Pr Bouhout Tariq tariqcard19@hotmail.com (oncology surgery professor): supervised the writing of manuscript.

Pr Bennani Amal bennaniamal@gmail.com (anatomopathology professor): confirm the histological diagnosis.

Pr Serji Badr badr.serji@hotmail.fr (oncology surgery professor): supervised the writing of manuscript.

Pr El Harroudi Tijani el.harroudi@hotmail.com: (oncology surgery professor): have supervised the writing of the paper.

Trial registry number

Our paper is a case report; no registration was done for it.

Guarantor

Mhand Mohammed.

Consent

Written informed consent was obtained from the patient for publication of this case report and accompanying images. A copy of the written consent is available for review by the Editor-in-Chief of this journal on request.

Provenance and peer-review

Not commissioned, externally peer reviewed.

Funding information

This research has not been supported by any private or corporate financial institutions nor has any grant been received for this study.

Declaration of competing interest

The authors declared no potential conflicts of interests with respect to research, authorship and/or publication of the article.

References

- [1] R.C. Jaworski, R. Boadle, J. Greg, P. Cocks, M.B. Bs, Peritoneal "Melanosis" Associated With a Ruptured Ovarian Dermoid Cyst: Report Of a Case With Electron-Probe Energy Dispersive X-Ray Analysis, 2001.
- [2] S.S. Kim, J.H. Nam, S.M. Kim, Y.D. Choi, J.H. Lee, Peritoneal melanosis associated with mucinous cystadenoma of the ovary and adenocarcinoma of the colon, *Int. J. Gynecol. Pathol.* 29 (2) (2010) 113–116, <https://doi.org/10.1097/GGP.0b013e3181bb4182>.
- [3] D.M. Jamkhandi, P. Gaikwad, D. Singh, K. George, Melanosis peritonei in pregnancy: a case report and review of literature, *Gynecol. Surg.* 11 (1) (2014) 59–60, <https://doi.org/10.1007/s10397-013-0820-6>.
- [4] J.F. Afonso, G.M. Martin, F.S. Nisco, R.R. de Alvarez, Melanogenic ovarian tumors, *Am. J. Obstet. Gynecol.* 84 (5) (1962), [https://doi.org/10.1016/0002-9378\(62\)90162-X](https://doi.org/10.1016/0002-9378(62)90162-X).
- [5] Barghash M, Nassif S, Alkurdi Y, Said A, Mansour M. Melanosis peritonei associated with adenocarcinoma of the sigmoid colon. *Cureus*. Published online July 28, 2021. doi:10.7759/cureus.16693.
- [6] E.S. Chang, P. Bachul, M. Szura, J. Szpor, K. Okoń, J.A. Walocha, Peritoneal "melanosis, *Pol. J. Pathol.* 66 (3) (2015) 330–333, <https://doi.org/10.5114/pjp.2015.54967>.
- [7] C.S. Lim, J.F. Thompson, P.R. McKenzie, S.W. McCarthy, R.A. Scolyer, Peritoneal melanosis associated with metastatic melanoma involving the omentum, *Pathology* 44 (3) (2012) 255–257, <https://doi.org/10.1097/PAT.0b013e318283514015>.
- [8] C.B. Drachenberg, J.C. Papadimitriou, Melanotic peritoneal cyst. Light-microscopic and ultrastructural studies, *Arch. Pathol. Lab Med.* 114 (5) (1990).
- [9] Luis De la Torre Mondragh B, Carrasco Daza D, Bustamante P, Fascinetto Mexico City V. *Gastric Triplication And Peritoneal Melanosis*.
- [10] Y.C. Jung, C.J. Chen, C.C. Tzeng, Melanosis peritonei associated with enteric duplication cyst: a case report, *Am. J. Surg. Pathol.* 20 (2) (1996) 181–186, <https://doi.org/10.1097/00000478-199602000-00006>.
- [11] I. Reccia, A. Pisanu, M. Podda, A. Uccheddu, An uncommon presentation of metastatic melanoma, in: *Medicine (United States)*, vol. 94, 2015, <https://doi.org/10.1097/MD.0000000000000319>.
- [12] A.D. Levy, J.C. Shaw, L.H. Sobin, Secondary tumors and tumorlike lesions of the peritoneal cavity: imaging features with pathologic correlation, *Radiographics* 29 (2) (2009).
- [13] Y.L. Suh, N.R. Kim, S.Y. Song, G. Ahn, Case Report 729BES SGML Peritoneal melanosis combined with serous cystadenoma of the ovary: a case report and literature review, *Pathol. Int.* 52 (2002) 724–729, <https://doi.org/10.1046/j.1320-5463.2002.01405.x>.
- [14] K.K. Sim, K. Connell, M. Bhandari, D. Paton, Peritoneal melanosis associated with metastatic melanoma previously treated with targeted and immune checkpoint inhibitor therapy, *BMJ Case Rep.* 14 (1) (2021), <https://doi.org/10.1136/bcr-2020-238235>.
- [15] A. Hirasawa, T. Akahane, T. Tsuruta, et al., Lobular endocervical glandular hyperplasia and peritoneal pigmentation associated with Peutz-Jeghers syndrome due to a germline mutation of STK11, *Ann. Oncol.* 23 (11) (2012), <https://doi.org/10.1093/annonc/mds492>.
- [16] D. Miljković, V. Pecić, M. Nestorović, et al., Melanoma of the anal canal with melanosis of the peritoneum - case report, *Acta. Medica. Medianae.* 15 (2011) 45–48, <https://doi.org/10.5633/amm.2011.0408>. Published online December.

- [17] R. Nada, K. Vaiphei, K.L. Rao, Enteric duplication cyst associated with melanosis peritonei, *Indian J. Gastroenterol.* 19 (3) (2000) 140–141.
- [18] A.A. Sahin, J.Y. Ro, J. Chen, A.G. Ayala, Spindle cell nodule and peptic ulcer arising in a fully developed gastric wall in a mature cystic teratoma, *Arch. Pathol. Lab Med.* 114 (5) (1990).
- [19] Fukushima, 1984.
- [20] D. Lee, A.H. Pontifex, Melanosis peritonei, *Am. J. Obstet. Gynecol.* 122 (4) (1975) 526–527, [https://doi.org/10.1016/S0002-9378\(16\)33548-7](https://doi.org/10.1016/S0002-9378(16)33548-7).
- [21] J.F. Afonso, G.M. Martin, F.S. Nisco, R.R. de Alvarez, Melanogenic ovarian tumors, *Am. J. Obstet. Gynecol.* 84 (5) (1962) 667–676, [https://doi.org/10.1016/0002-9378\(62\)90162-X](https://doi.org/10.1016/0002-9378(62)90162-X).
- [22] R.A. Agha, T. Franchi, C. Sohrabi, et al., The SCARE 2020 guideline: updating consensus surgical CAse REport (SCARE) guidelines, *Int. J. Surg.* 84 (2020) 226–230, <https://doi.org/10.1016/j.ijssu.2020.10.034>.