

¹⁸F-fluoro-deoxy-glucose positron emission tomography combined with computed tomography can reliably rule-out infection and cancer in patients with anti-neutrophil cytoplasmic antibody-associated vasculitis suspected of disease relapse

Evan C. Frary, MD, JD^a, Søren Hess, MD^{a,b,c,*}, Oke Gerke, MSc, PhD^{a,d}, Helle Lastrup, MD, PhD^{c,e}

Abstract

Anti-neutrophil cytoplasmic antibody (ANCA)-associated vasculitis (AAV) is a group of autoimmune diseases characterized by systemic inflammation in small- to medium-sized blood vessels. Although immunosuppressive therapy has greatly improved the prognosis for these patients, there are still significant comorbidities, such as cancer and infection, associated with AAV. These comorbidities are often indistinguishable from an underlying AAV disease relapse, and create a clinical conundrum, as these conditions are normally contraindications for immunosuppressive treatment. Thus, it is important to be able to rule out these comorbidities before initiation of immunosuppressive treatment. We examined ¹⁸F-fluoro-deoxy-glucose positron emission tomography combined with computed tomography (FDG-PET/CT)'s value in ruling out cancer or infection in patients with AAV.

Data were obtained retrospectively for a clinically based cohort of AAV patients who underwent FDG-PET/CT during 2009 to 2014 owing to a suspicion of cancer, infection, or both cancer and infection indistinguishable from disease relapse. FDG-PET/CT conclusions were compared to the final diagnoses after follow-up analysis (mean 43 months).

A total of 19 patients were included who underwent a total of 26 scans. The results of FDG-PET/CT outcome compared to final diagnosis were: 9 true positives, 3 false positives, 13 true negatives, and 1 false negative. The diagnostic probabilities for FDG-PET/CT with respect to overall comorbidity (i.e., cancer or infection) were: sensitivity 90% (95% confidence interval [CI] 60%–98%), specificity 81% (95% CI 57%–93%), positive predictive value 75% (95% CI 47%–91%), negative predictive value 93% (95% CI 68%–99%), and accuracy 84% (95% CI 66%–94%).

FDG-PET/CT had a high negative predictive value and ruled out the comorbidities correctly in all but one case of urinary tract infection, a well-known limitation. Our study showed FDG-PET/CT's promise as an effective tool for ruling out cancer or infection in patients with AAV albeit in a limited population.

Abbreviations: AAV = ANCA-associated vasculitis, ANCA = anti-neutrophil cytoplasmic antibody, EGPA = eosinophilic granulomatosis with polyangiitis, FDG = ¹⁸F-fluoro-deoxy-glucose, FN = false negative, FP = false positive, GPA = granulomatosis with polyangiitis, MPA = microscopic polyangiitis, NPV = negative predictive value, PET/CT = positron emission tomography combined with computed tomography, PPV = positive predictive value, SUVmax = maximum standard uptake values, TN = true negative, TP = true positive.

Keywords: ANCA, anti-neutrophil cytoplasmic antibody-associated vasculitis, FDG, PET/CT, vasculitis

Editor: Hongming Zhuang.

The authors have no conflicts of interest and received no funding for this study.

Authors' contributions: EF, SH, and HL participated in the study design as well as data collation and interpretation; EF and OG carried out the statistical analysis of the data; all authors read and approved the final manuscript.

^a Department of Nuclear Medicine, Odense University Hospital, Odense C, ^b Department of Radiology and Nuclear Medicine, Hospital of Southwest Jutland, Esbjerg,

^c Department of Clinical Research, Faculty of Health Sciences, University of Southern Denmark, Odense C, ^d Center of Health Economics Research, University of Southern Denmark, Odense M, ^e Department of Rheumatology, Odense University Hospital, Odense C, Denmark.

* Correspondence: Søren Hess, MD, Department of Nuclear Medicine, Odense University Hospital Sdr. Boulevard 29, 5000 Odense C, Denmark (e-mail: soeren.hess@rsyd.dk).

Copyright © 2017 the Author(s). Published by Wolters Kluwer Health, Inc.

This is an open access article distributed under the terms of the Creative Commons Attribution-Non Commercial-No Derivatives License 4.0 (CCBY-NC-ND), where it is permissible to download and share the work provided it is properly cited. The work cannot be changed in any way or used commercially without permission from the journal.

Medicine (2017) 96:30(e7613)

Received: 17 May 2017 / Received in final form: 3 July 2017 / Accepted: 5 July 2017

<http://dx.doi.org/10.1097/MD.0000000000007613>

1. Introduction

Anti-neutrophil cytoplasmic antibody (ANCA)-associated vasculitides (AAV) comprise a group of autoimmune diseases affecting small- to medium-sized blood vessels including granulomatosis with polyangiitis (GPA, formerly known as Wegener granulomatosis), microscopic polyangiitis (MPA), and eosinophilic GPA (EGPA, formerly known as Churg Strauss).^[1] AAV's pathology is characterized by systemic inflammation in the blood vessel's walls, which can lead to vascular obstruction and hemorrhage, ultimately resulting in tissue ischemia and necrosis.^[2] Although relatively rare, with 10 to 20 new cases per million annually,^[3] AAV is potentially life-threatening. Historically, the prognosis for AAV has been bleak, but the survival rates have improved drastically during the past few decades increasing from a meager 20% of patients surviving after 1.5 years to a current 10-year survival rate of 75%.^[4–6] This increase has been largely attributed to a 2-tiered individually tailored immunosuppressive therapy based on the disease's stage and severity.^[5–7]

This immunosuppressive therapy, although effective, presents a serious clinical dilemma to the treating physician, as 2 of AAV's associated comorbidities, cancer and infection, are often clinically indistinguishable from a disease relapse of the patient's underlying vasculitis, that is, they present with similar symptoms and findings.^[6,8] These comorbidities may even be exacerbated by immunosuppressive treatment and can actually increase patient morbidity and mortality.^[9] Therefore, there is a clinical need for an effective diagnostic tool, which can help rule out cancer and infection foci in these patients before immunosuppressive therapy is initiated, but hitherto no methods have been firmly established for this clinical challenge.

Positron emission tomography combined with computed tomography (PET/CT) based on high sensitivity detection of the radiolabeled glucose analog ¹⁸F-fluoro-deoxy-glucose (FDG, which is known to accumulate in hypermetabolic cells) is already routinely applied to many cancer types as well as the detection of infection and inflammation.^[10–12] The capacity to identify all 3 of these conditions raises the possibility for FDG-PET/CT's use in diagnosis and monitoring of AAV patients. Although the role of FDG-PET/CT has been explored to some degree in large-vessel vasculitis,^[13,14] the evidence with respect to PET/CT's applicability to AAV is lacking and only includes a few studies with very limited patient populations.^[15–21]

In this article, we report on FDG-PET/CT's ability to reliably rule-out comorbidity in the form of cancer or infection in patients with AAV with nonspecific symptoms suggestive of either comorbidities or disease flares.

2. Materials and methods

2.1. Study population

This study included a retrospective clinical cohort of AAV patients who underwent FDG-PET/CT scans at Odense University Hospital, Denmark. Patients were included in the study if they had a diagnosis of AAV,^[22] and underwent FDG-PET/CT between January 1, 2009 and December 31, 2014 owing to a suspicion of comorbidity (cancer, infection, or both) indistinguishable from disease relapse. Owing to the rarity of the disease, no sample size was defined; we wished to include as many patients as possible in the given period, which was chosen for practical reasons: The local PET/CT-database was accessible from 2009 and onwards, and ending inclusion with 2014 enabled at least a 2-year follow-up period. Patients were not included if

they were referred with a suspicion of a specific cancer with no concomitant suspicion of disease relapse.

The data were collected from the hospital's electronic patient records and diagnostic imaging systems, and the patients' journals were manually reviewed for basic information comprising age and sex as well as AAV diagnosis date, FDG-PET/CT referral indication, FDG-PET/CT date, imaging findings, and histological analysis. Follow-up analysis was performed by reviewing the patients' electronic records. Birmingham Vasculitis Activity Scores (BVAS) were calculated post-hoc.

This study was approved by the local ethics committee (S-20140097) and the Danish Data Protection Agency.

2.2. FDG-PET/CT-protocol

All FDG-PET/CT scans were based on the guidelines from the European Association of Nuclear Medicine,^[23] and performed according to the department's standard protocol as previously described^[24]: All examinations were performed on a GE Discovery PET/CT scanner (GE Healthcare, Milwaukee, WI). The CT imaging was performed as a low-dose CT scan without contrast enhancement. Data were reconstructed with a standard filter into transaxial slices with a field of view of 50 cm, matrix size of 512 × 512 (pixel size 0.98 mm), and a slice thickness of 3.75 mm. The CT scan was followed immediately by a PET scan performed using a standard whole-body acquisition protocol with 6 or 7 bed positions and an acquisition time of 2.5 minutes per bed position (adjusted to patient size). The scan field of view was 70 cm. Attenuation correction was performed from the CT-scan. The PET data were reconstructed into transaxial slices with a matrix size of 128 × 128 or 256 × 256 and a slice thickness of 3.75 mm using iterative 3D OS-EM (with varying iterations and subsets), and displayed in coronal, transverse, and sagittal planes. Corrections for attenuation, randoms, dead time, and normalization were done inside the iterative loop. Analysis of the PET and fused PET/CT data was done using a GE Advantage Workstation v. 4.4 or a GE Advantage Server 2.0 (GE Healthcare). The fused PET/CT scan was described by a nuclear medicine specialist. At the time of FDG administration, all patients had fasted for at least 6 hours. PET/CT image acquisition commenced 60 ± 5 minutes, after the administration of a weight-adjusted dose of 4 MBq/kg (110 μCi/kg) FDG (minimum 200 MBq (5 mCi) and maximum 400 MBq [10 mCi]). Maximum standard uptake values (SUVmax) were calculated post-hoc using Advantage Server 2.0 (GE Healthcare, Milwaukee, WI) by placing a region of interest (ROI) around all areas of increased FDG uptake suggestive of malignancy or infection.

2.3. Interpretation

Infection and malignancy were considered simultaneously and interpreted as overall comorbidity as well as divided into 2 subgroups and interpreted individually.

2.4. Malignancy

All positive FDG-PET/CT findings were confirmed or rejected by histological analysis and/or follow-up. An FDG-PET/CT scan was considered true positive (TP) if there was FDG uptake suggestive of malignancy (Fig. 1), which was subsequently confirmed via histological analysis, and false positive (FP) if ruled out by histological analysis. A true-negative (TN) result was defined as a scan with no abnormal FDG uptake suggestive of malignancy in a patient wherein no novel cancer was diagnosed

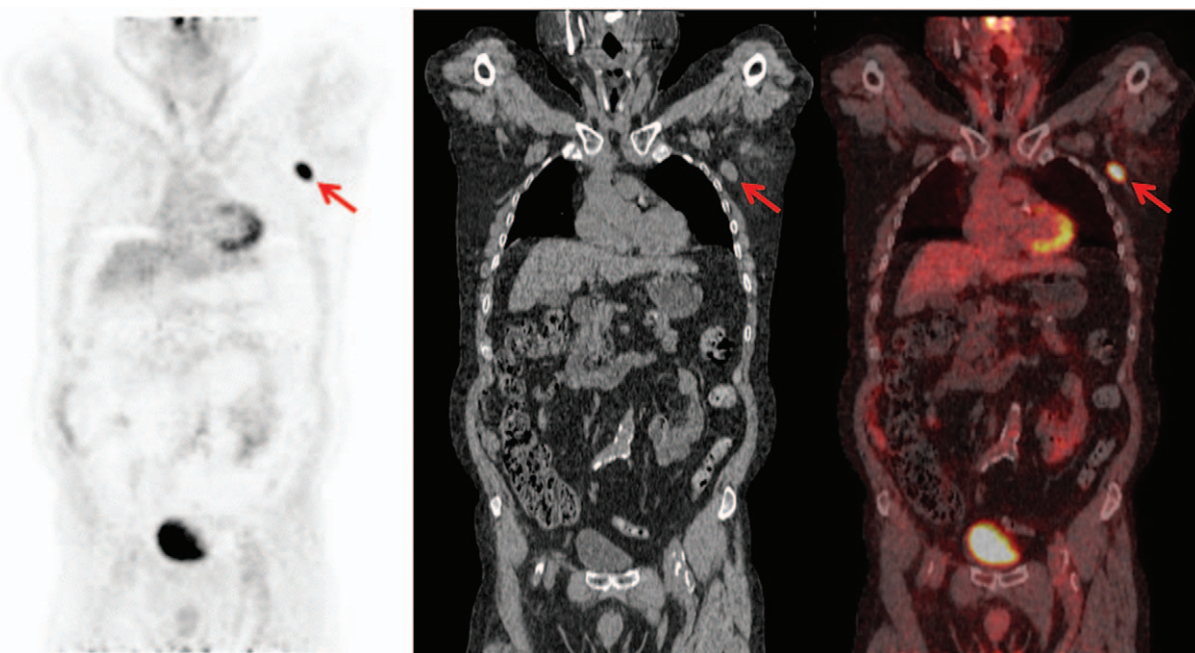


Figure 1. Coronal positron emission tomography image (left), computed tomography image (middle), and fused positron emission tomography/computed tomography image (right) in a patient with known anti-neutrophil cytoplasmic antibody-associated vasculitis referred owing to a suspicion of cancer. There is focally increased ^{18}F -fluoro-deoxy-glucose uptake in an enlarged left axillary lymph node (red arrows). Subsequent biopsy confirmed a diagnosis of diffuse large B-cell lymphoma.

in the subsequent follow-up period. A false negative (FN) was defined as a subsequent novel diagnosis of cancer during follow-up despite negative FDG-PET/CT.

2.5. Infection

All positive FDG-PET/CT findings were confirmed or rejected by a specialist in rheumatology after analysis of all available medical chart evidence (e.g., clinical observations, paraclinical findings, and imaging results from other non-FDG-PET/CT imaging). An FDG-PET/CT scan was considered TP if there was FDG uptake suggestive of infection (Fig. 2), which was subsequently confirmed via the chart data (e.g., positive culture, serology, and/or response to antibiotic treatment) and FP if ruled out because of discordant findings (e.g., negative culture, serology, and/or persistent symptoms despite antibiotic treatment). A TN result was defined as a scan without abnormal FDG uptake suggestive of infection and no subsequent clinical signs or findings consistent with infection (e.g., clinical/paraclinical signs indicative of disease relapse and/or response to immunosuppressive treatment). Conversely, an FN was defined as a normal FDG-PET/CT wherein infection was subsequently confirmed (e.g., positive culture, serology, and/or response to antibiotic treatment).

2.6. Comorbidity

Infection and malignancy were considered together as overall comorbidity. TP was defined as a finding of TP for either cancer or infection. TN was defined as a finding of TN for both cancer and infection. FN was defined as a finding of FN for cancer or infection and no simultaneous TP or FP for infection or cancer. FP was defined as a finding of FP for cancer or infection and no simultaneous TP for infection or cancer. These categories were referral-dependent, for example, if the referral only stated infection, cancer was not considered and vice versa, but if the

referral stated either suspected infection or cancer, both diagnoses were considered. In the individual subgroup statistical analysis, the 6 scans with referral for suspicion of both infection or cancer were counted as 2 separate exposures, that is, once in the category of suspected occult cancer and once in the category of suspected infection, thus resulting in a total of 32 exposures.

2.7. AAV disease activity

A diagnosis of AAV disease relapse was established by a specialist rheumatologist by analyzing all clinical and paraclinical findings (e.g., histological results, increased MPO-ANCA, and/or response to immunosuppressive treatment).

2.8. Statistical analysis

FDG-PET/CT's diagnostic efficacy was analyzed for: sensitivity, specificity, positive predictive value (PPV), negative predictive value (NPV), and accuracy. The corresponding binomial proportion confidence intervals (CIs) were calculated using the Wilson score interval.^[25] Correlation between SUVmax and a TP or TN result with respect to comorbidity was calculated using the Wilcoxon-Mann-Whitney test. The analysis dataset was complete, that is, no data were missing. All statistical analyses were done in STATA/IC 14.0 for Windows (StataCorp LP, College Station, TX).

3. Results

A total of 26 patients were considered for this study, 7 were not included because of referral for FDG-PET/CT with suspicion of a specific cancer and no concomitant suspicion of disease relapse. This left 19 remaining patients with diagnoses of GPA ($n=15$) or MPA ($n=4$). These 10 male and 9 female patients had a mean age of 67 years (range 51–78) at the date of scanning, and underwent a total of 26 FDG-PET/CT scans. Sequential scans carried out within

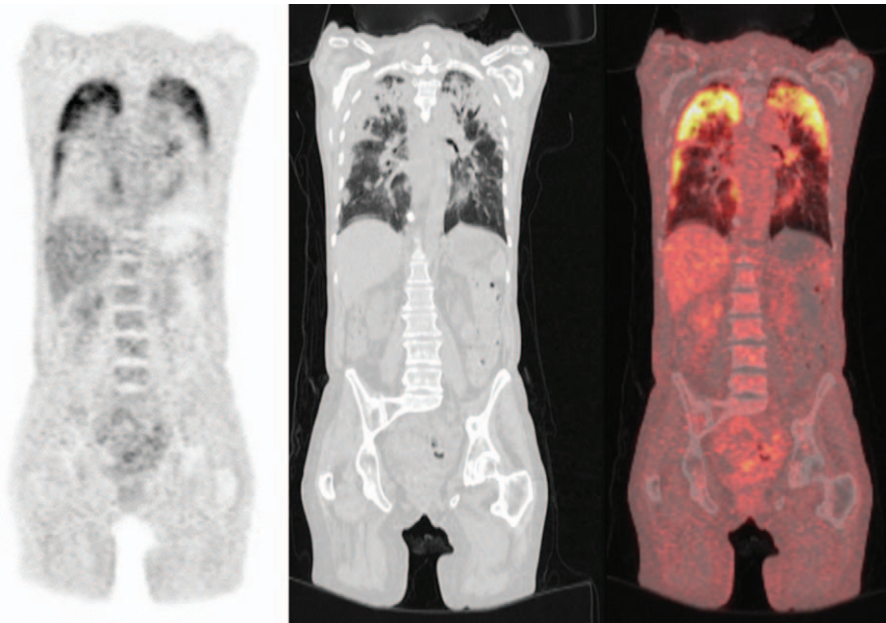


Figure 2. Coronal positron emission tomography image (left), computed tomography image (middle), and fused positron emission tomography/computed tomography image (right) in a patient with known anti-neutrophil cytoplasmic antibody-associated vasculitis referred owing to a suspicion of infection. There is diffusely increased ¹⁸F-fluoro-deoxy-glucose uptake bilaterally consistent with atypical pneumonia and tracheal secretions confirmed pneumocystis carinii pneumonia.

a short timeframe during the same patient course were counted as 1 scan. Patients were followed up for mean 43 months (±3.8 months).

3.1. Comorbidity

Overall, there were 12 of 26 positive and 14 of 26 negative FDG-PET/CT scans. The results of FDG-PET/CT outcome compared

to final diagnosis were: 9 TPs, 3 FPs, 13 TNs, and 1 FN. The overall diagnostic probabilities for FDG-PET/CT with respect to comorbidity (i.e., cancer or infection) were: sensitivity 90% (95% CI 60%–98%), specificity 81% (57%–93%), PPV 75% (95% CI 47%–91%), NPV 93% (95% CI 69%–99%), and accuracy 85% (95% CI 66%–94%). Individual PET/CT findings and final diagnoses for this group are displayed in Table 1. The median

Table 1
PET/CT findings and final diagnoses.

Scan	Referral indication	Symptoms leading to referral	BVAS	FDG-uptake	Final diagnosis	Result
1	Cancer vs. relapse	Fever	7	Lungs	Planocellular carcinoma	True positive
2	Cancer vs. relapse	Fatigue, blood in urine	0	Lungs, lymph nodes	Renal cell carcinoma	True positive
3	Cancer vs. relapse	Axillary pain and swelling	1	Lymph nodes	DLCB lymphoma	True positive
4	Cancer vs. relapse	Weight loss	2	None	No cancer/disease relapse	True negative
5	Cancer vs. relapse	Weight loss, hypercalcemia, pain	0	None	No cancer/disease relapse	True negative
6	Cancer vs. relapse	Inc. CRP despite steroid treatment	2	None	Disease activity	True negative
7	Cancer vs. relapse	Myelodysplasia	0	None	No cancer/disease relapse	True negative
8	Cancer vs. relapse	Weight loss, fever, dyspnea, leukoscintigraphy	2	None	Undetermined cause	True negative
9*	Cancer vs. relapse	Weight loss, Inc. creatinine, hydronephrosis	7	Lungs	Lung Fibrosis	False positive
10	Infection vs. relapse	Inc. CRP, x-ray	4	Lungs	Pneumonia	True positive
11	Infection vs. relapse	Inc. CRP, fever, cough	6	Lungs	Pneumonia	True positive
12	Infection vs. relapse	Inc. CRP, fever	6	Lungs	Pneumonia	True positive
13	Infection vs. relapse	Inc. CRP, fever	12	Lungs, colon, bone	Rotavirus, MGUS	True positive
14	Infection vs. relapse	Inc. CRP, fever	4	Lungs	Pneumonia	True positive
15	Infection vs. relapse	Inc. CRP, fever, dyspnea	9	None	Disease activity	True negative
16	Infection vs. relapse	Inc. CRP, fever, fatigue	10	None	Disease activity	True negative
17	Infection vs. relapse	Fever, fatigue, dizziness, pain	12	None	Unknown cause	True negative
18	Infection vs. relapse	Fever, fatigue, cough	2	None	Disease activity	True negative
19*	Infection vs. relapse	Inc. CRP, fever	2	Lung	Exudative pleuritis	False positive
20	Infection vs. relapse	Fever	2	None	Urinary tract infection	False negative
21	Both vs. relapse	Inc. CRP, fever	7	None	Lunge emboli	True negative
22	Both vs. relapse	Inc. CRP, fever, dyspnea, hypoxemia	4	None	Lunge emboli	True negative
23	Both vs. relapse	CT imaging: lung infiltrates, lymphadenopathy	10	Lungs, colon	Disease activity	False positive
24	Both vs. relapse	Fever, subjective feeling of illness	6	None	Disease activity	True negative
25	Both vs. relapse	Weight loss, night sweats, decreased appetite	3	None	Disease activity	True negative
26	Both vs. relapse	Inc. CRP, fever, Inc. creatinine	11	Lymph nodes	Infection	True positive

BVAS=Birmingham Vasculitis Activity Score, CRP=C-reactive protein, DLBC=diffuse large B-cell, FDG=¹⁸F-fluoro-deoxy-glucose, Inc.=increased, MGUS=Monoclonal gammopathy of unknown significance, PET/CT=positron emission tomography/computed tomography.

Table 2
FDG-PET/CT vs. comorbidity.

Comorbidity vs. disease relapse (n=26)		
	Comorbidity positive (+)	Comorbidity negative (-)
FDG-PET/CT positive (+)	9 TPs	3 FPs
FDG-PET/CT negative (-)	1 FN	13 TNs

Subgroup analysis* (n=32)		
Cancer vs. disease relapse (n=15)		
	Cancer positive (+)	Cancer negative (-)
FDG-PET/CT positive (+)	3 TPs	3 FPs
FDG-PET/CT negative (-)	0 FN	9 TNs

Infection vs. disease relapse (n=17)		
	Infection positive (+)	Infection negative (-)
FDG-PET/CT positive (+)	6 TPs	1 FP
FDG-PET/CT negative (-)	1 FNs	9 TNs

TP=true positive, FDG-PET/CT=F-fluoro-deoxy-glucose-positron emission tomography combined with computed tomography, FP=false positive, FN=false negative, TN=true negative.
*In the individual subgroup statistical analysis, the 6 scans with referral for suspicion of both infection or cancer were counted as 2 separate exposures, i.e., once in the category of suspected occult cancer and once in the category of suspected infection, thus resulting in a total of 32 exposures.

BVAS score for all patients was 4 (range: 0–12), and the median SUVmax for patients with increased FDG uptake suggestive of cancer or infection was 6.9 (range: 3.7–36.2).

3.2. Individual subgroup analysis

Of the 26 total scans, 9 were undertaken because of suspected cancer, 11 because of suspected infection, and 6 because of simultaneous suspicion of either cancer or infection.

In the group referred with suspected cancer, 4 of 9 scans were positive. Biopsy confirmed novel malignancies in 3 and rejected malignancy in 1. The remaining 5 of 9 scans were negative, and no novel cancer was found during follow-up. This resulted in 3 TPs, 1 FPs, 5 TNs, and no FN for this group. Disease relapse of AAV was confirmed in 2 patients during follow-up.

In the group referred with suspected infection, 6 of 11 were positive. Infection was subsequently confirmed in 5 and rejected in 1. Of the remaining 5 of 11 with negative scans, 1 was determined to in fact have an infection, whereas in the remaining 4, infection was ruled out. This resulted in 5 TPs, 1 FP, 4 TNs, and 1 FN for this group. Disease relapse of AAV was confirmed in 4 after follow-up.

In the group referred with a suspicion of cancer or infection, 2 of 6 scans were positive. Infection was subsequently confirmed in one and both cancer and infection were ruled out in the other. In the remaining 4 of 6 with negative scans, infection was ruled

out and no novel cancer was found during follow-up. This resulted in 1 TP, 1 FP, 4 TNs, and no FN for this group. Disease relapse of AAV was confirmed in 3 patients during follow-up. The 2 × 2 tables for overall comorbidity and each subgroup are displayed in Table 2. Statistical analyses of FDG-PET/CT’s diagnostic efficacy for both overall comorbidity as well as the individual comorbidities are displayed in Table 3. We found no statistical significant correlation between SUVmax values and comorbidity (z=0.65, P=.52).

4. Discussion

Although a limited number of case reports and case series have reported on FDG PET/CT’s ability to identify the presence of active disease in AAV patients,^[20,21] we believe this study is the first to evaluate FDG-PET/CT’s role in distinguishing between AAV disease activity and comorbidity, that is, cancer or infection.

This is an important but no trivial undertaking, as all of these clinical entities may induce similar and indistinguishable symptoms and signs such as fever and elevated inflammation markers. If patients are misclassified, it may lead to delayed diagnosis with poorer prognosis, and faulty treatment as the strategies are fundamentally different; for instance, an immunosuppressant for AAV disease activity may seriously worsen symptoms and harm patients with infection or cancer. One may even speculate if part of the morbidity or mortality of AAV is caused by misclassification or misdiagnosis of comorbidities.

Although FDG is nonspecific and as such not able to differentiate infection, inflammation, and cancer per se, the potential of a high NPV is clear; without focal uptake, the probability of focal infection or cancer is very low and, thus, any symptoms and signs are more likely to be attributable to flair of the underlying inflammatory disease. This has also been addressed in similar settings, for instance, febrile neutropenia with unknown origin in cancer patients and in patients with fever of unknown origin wherein FDG-PET/CT has shown considerable potential to establish the origin of infection as well as rule out focal infection with high NPVs.^[26–28]

FDG PET/CT correctly ruled out cancer and infection in all but 1 patient. This patient had a case of urinary tract infection, and although the physiologic urinary excretion of FDG naturally hampers the use in this setting, urinary tract infections are usually relatively easy to diagnose via simple alternative tests.^[29] The inability to assess the urinary tract may pose a potential limitation, however, as cancer of the urinary tract is a known side effect of the immunosuppressant cyclophosphamide.^[9] Even with this solitary FN, the NPV for overall comorbidity was high at 93% (95% CI 68%–99%). In the subgroup analysis, NPV was even higher for malignancy, 100% (95% CI 70%–100%),

Table 3
Diagnostic probabilities of comorbidity.

	Comorbidity analysis		Subgroup analysis*			
	Comorbidity	95% CI	Cancer	95% CI	Infection	95% CI
Sensitivity	90%	60–98%	100%	44%–100%	86%	49%–97%
Specificity	81%	57–93%	75%	47%–91%	90%	60%–98%
PPV	75%	47–91%	50%	19%–81%	86%	49%–97%
NPV	93%	68–99%	100%	70%–100%	90%	60%–98%
Accuracy	84%	66–94%	80%	55%–93%	88%	66%–97%

CI=confidence intervals, NPV=negative predictive value, PPV=positive predictive value.
*In the individual subgroup statistical analysis, the 6 scans with referral for suspicion of both infection or cancer were counted as 2 separate exposures, i.e., once in the category of suspected occult cancer and once in the category of suspected infection, thus resulting in a total of 32.

whereas the FN reduced the NPV for infection to 90% (95% CI 60%–98%).

Although FDG-PET/CT uncovered novel cancers, the PPV was moderate with respect to overall comorbidity, that is, 75% (95% CI 47%–91%). One patient was FP due to extensive lung fibrosis which mimicked cancer. The subgroup analysis showed a relatively high PPV in patients with suspected infection, i.e. 86% (95% CI 49%–97%), but a much lower PPV in patients suspected of cancer, that is 50% (95% CI 19%–81%), in part owing to the FP fibrosis patient. Another reason was the retrospective nature of this study, as 1 of the 3 suspected cancer FPs was owing to a double referral indication, that is, the patient's increased FDG uptake was FP with respect to malignancy but also TP with respect to infection. The use of more targeted clinical referral indications would have alleviated this statistical problem.

Thus, our data show overall that whereas the PPV of FDG-PET/CT is only moderate for cancer or infection, the high NPV indicates a potentially great benefit of FDG-PET/CT to rule out occult cancer or infection in these complicated and systemically ill patients. This is clinically highly relevant, as it allows the rejection of important differential diagnoses and reduces treatment delay, that is, administration of immunosuppressants, in AAV patients suspected of disease relapse.

The lack of statistical significance between SUVmax and comorbidity is not surprising, as the drawbacks of SUVmax are numerous, and it is well established that SUVmax's ability to distinguish between benign or physiologic uptake and infectious or malignant foci is limited.^[30]

The main strengths of our study are that this is the first study ever to report on this particular clinical application of FDG-PET/CT in AAV patients: a novel method for the clinicians to ensure no focal infection or malignancy was present before instituting specific immunosuppressive treatment for AAV flare. Also of interest is the nonselected nature of the clinical cohort, which is representative of the region's patient population. There were, however, a number of limitations in our study. The first was the limited number of patients. AAV is rare, however, and with 19 patients, ours is still one of the largest studies to date (the largest including only 33 patients).^[21] Furthermore, the retrospective design gave rise to inherent drawbacks, for example, the inability to use single targeted referral indications based on specific clinical/paraclinical criteria. However, this was ultimately not detrimental to the promising findings as the removal of the double indication would have actually increased the individual PPV. FDG-PET/CT's technological limitations were also a factor to consider. Owing to FDG-PET/CT's spatial resolution of 4 to 6 mm, it is not possible to directly display the involvement of small-medium vessels,^[31] but only secondary organ involvement. Finally, FDG-PET/CT has well-documented areas where it is difficult to distinguish between physiological and pathological uptake, for example, the brain, urinary tract, heart, and bowel.^[29]

A few future considerations should be addressed as well. For example, the effect of steroid treatments on FDG uptake was not evaluated in our study, although some literature suggests they have a “masking effect” (i.e., reduced FDG uptake) at least in large vessel vasculitides.^[31] Furthermore, some authors have explored other, potentially more specific, radiolabelled tracers (e.g., [¹¹C]-PK11195), and other imaging modalities (e.g., PET/MRI), which may be superior for locating or ruling out the particular comorbidities in AAV patients. However, these subjects have only been sporadically assessed in the literature and were outside the scope of this study

In conclusion, FDG-PET/CT is a promising modality for ruling out focal infection or malignancy in AAV patients with nonspecific symptoms and a need for differentiating suspected disease relapse from malignancy or infection. These comorbidities were correctly ruled out in all but case involving the urinary tract wherein the limited value of FDG-PET/CT is already well established. The ultimate implication of this study is that FDG-PET/CT may be suitable for use in the differential diagnosis in all similarly situated AAV patients. However, owing to the size and nature of the patient cohort, to establish the external validity more firmly, further research in a larger patient population in a prospective setting is desirable to determine whether FDG PET/CT should be applied to all AAV patients suspected of malignancy or infection indistinguishable from disease relapse.

References

- Jennette JC, Falk RJ, Bacon PA, et al. 2012 revised International Chapel Hill Consensus Conference Nomenclature of Vasculitides. *Arthritis Rheum* 2013;65:1–1.
- McGeoch L, Twilt M, Fomorca L, et al. CanVasc recommendations for the management of antineutrophil cytoplasm antibody (ANCA)-associated vasculitides—executive summary. *Can J Kidney Health Dis* 2015;2:43.
- Ntatsaki E, Watts RA, Scott DG. Epidemiology of ANCA-associated vasculitis. *Rheum Dis Clin North Am* 2010;36:447–61.
- Walton EW. Giant-cell granuloma of the respiratory tract (Wegener's granulomatosis). *Br Med J* 1958;2:265–70.
- Schonermark U, Gross WL, de Groot K. Treatment of ANCA-associated vasculitis. *Nat Rev Nephrol* 2014;10:25–36.
- Flossmann O, Berden A, de Groot K, et al. Long-term patient survival in ANCA-associated vasculitis. *Ann Rheum Dis* 2011;70:488–94.
- Jayne D, Rasmussen N, Andrassy K, et al. A randomized trial of maintenance therapy for vasculitis associated with antineutrophil cytoplasmic autoantibodies. *N Engl J Med* 2003;349:36–44.
- Kallenberg CG. Key advances in the clinical approach to ANCA-associated vasculitis. *Nat Rev Rheumatol* 2014;10:484–93.
- Harper L. L42. Morbidity in patients with ANCA-associated vasculitis. *Presse Med* 2013;42:612–6.
- Hoilund-Carlson PF, Gerke O, Vilstrup MH, et al. PET/CT without capacity limitations: a Danish experience from a European perspective. *Eur Radiol* 2011;21:1277–85.
- Hess S, Blomberg BA, Zhu HJ, et al. The pivotal role of FDG-PET/CT in modern medicine. *Acad Radiol* 2014;21:232–49.
- Kristensen SB, Hess S, Petersen H, et al. Clinical value of FDG-PET/CT in suspected paraneoplastic syndromes: a retrospective analysis of 137 patients. *Eur J Nucl Med Mol Imaging* 2015;42:2056–63.
- Balink H, Binnink RJ, van Eck-Smit BL, et al. The role of 18F-FDG PET/CT in large-vessel vasculitis: appropriateness of current classification criteria? *Biomed Res Int* 2014;2014:687608.
- Dellavedova L, Carletto M, Faggioli P, et al. The prognostic value of baseline (18)F-FDG PET/CT in steroid-naive large-vessel vasculitis: introduction of volume-based parameters. *Eur J Nucl Med Mol Imag* 2016;43:340–8.
- Ozmen O, Tatci E, Gokcek A, et al. Integration of 2-deoxy-2-[18F] fluoro-D-glucose PET/CT into clinical management of patients with Wegener's granulomatosis. *Ann Nucl Med* 2013;27:907–15.
- Ito K, Minamimoto R, Yamashita H, et al. 18F-FDG PET/CT findings preceded elevation of serum proteinase 3 antineutrophil cytoplasmic antibodies in Wegener granulomatosis. *Clin Nucl Med* 2014;39:e67–8.
- Ito K, Minamimoto R, Yamashita H, et al. Evaluation of Wegener's granulomatosis using 18F-fluorodeoxyglucose positron emission tomography/computed tomography. *Ann Nucl Med* 2013;27:209–16.
- Almuhaideb A, Syed R, Iordanidou L, et al. Fluorine-18-fluorodeoxyglucose PET/CT rare finding of a unique multiorgan involvement of Wegener's granulomatosis. *Br J Radiol* 2011;84:e202–4.
- Nishiyama Y, Yamamoto Y, Dobashi H, et al. Clinical value of 18F-fluorodeoxyglucose positron emission tomography in patients with connective tissue disease. *Jpn J Radiol* 2010;28:405–13.
- Soussan M, Abisror N, Abad S, et al. FDG-PET/CT in patients with ANCA-associated vasculitis: case-series and literature review. *Autoimmunity reviews* 2014;13:125–31.

- [21] Kemna MJ, Vandergheynst F, Voo S, et al. Positron emission tomography scanning in anti-neutrophil cytoplasmic antibodies-associated vasculitis. *Medicine (Baltimore)* 2015;94:e747.
- [22] Fries JF, Hunder GG, Bloch DA, et al. The American College of Rheumatology 1990 criteria for the classification of vasculitis. Summary. *Arthritis Rheum* 1990;33:1135–6.
- [23] Boellaard R, Delgado-Bolton R, Oyen WJ, et al. FDG PET/CT: EANM procedure guidelines for tumour imaging: version 2.0. *Eur J Nucl Med Mol Imaging* 2015;42:328–54.
- [24] Frary EC, Gad D, Bastholt L, et al. The role of FDG-PET/CT in preoperative staging of sentinel lymph node biopsy-positive melanoma patients. *EJNMMI Res* 2016;6:73.
- [25] Newcombe RGAD, Altman DG, Bryant TN, Gardner MJ. Proportions and Their Differences. *Statistics with Confidence 2nd edition* ednBMJ Books, Bristol, UK:2000;44–56.
- [26] Bleeker-Rovers CP, de Kleijn EM, Corstens FH, et al. Clinical value of FDG PET in patients with fever of unknown origin and patients suspected of focal infection or inflammation. *Eur J Nucl Med Mol Imaging* 2004;31:29–37.
- [27] Vos FJ, Bleeker-Rovers CP, Oyen WJ. The use of FDG-PET/CT in patients with febrile neutropenia. *Semin Nucl Med* 2013;43:340–8.
- [28] Buch-Olsen KM, Andersen RV, Hess S, et al. 18F-FDG-PET/CT in fever of unknown origin: clinical value. *Nucl Med Comm* 2014;35:955–60.
- [29] Basu S, Hess S, Nielsen Braad PE, et al. The basic principles of FDG-PET/CT imaging. *PET Clin* 2014;9:355–70, v.
- [30] Basu S, Zaidi H, Salavati A, et al. FDG PET/CT methodology for evaluation of treatment response in lymphoma: from “graded visual analysis” and “semiquantitative SUVmax” to global disease burden assessment. *Eur J Nucl Med Mol Imaging* 2014;41:2158–60.
- [31] Treglia G, Mattoli MV, Leccisotti L, et al. Usefulness of whole-body fluorine-18-fluorodeoxyglucose positron emission tomography in patients with large-vessel vasculitis: a systematic review. *Clin Rheumatol* 2011;30:1265–75.