

Comparison of a Fistulectomy and a Fistulotomy with Marsupialization in the Management of a Simple Anal Fistula: A Randomized, Controlled Pilot Trial

Bhupendra Kumar Jain, Kumar Vaibhaw, Pankaj Kumar Garg, Sanjay Gupta, Debajyoti Mohanty

Department of Surgery, Guru Teg Bahadur Hospital, University of Delhi College of Medical Sciences, Delhi, India

Purpose: This randomized clinical trial was conducted to compare a fistulectomy and a fistulotomy with marsupialization in the management of a simple anal fistula.

Methods: Forty patients with simple anal fistula were randomized into two groups. Fistulous tracts were managed by using a fistulectomy (group A) while a fistulotomy with marsupialization was performed in group B. The primary outcome measure was wound healing time while secondary outcome measures were operating time, postoperative wound size, postoperative pain, wound infection, anal incontinence, recurrence and patient satisfaction.

Results: Postoperative wounds in group B healed earlier in comparison to group A wounds (4.85 ± 1.39 weeks vs. 6.75 ± 1.83 weeks, $P = 0.035$). No significant differences existed between the operating times (28.00 ± 6.35 minutes vs. 28.20 ± 6.57 minutes, $P = 0.925$) and visual analogue scale scores for postoperative pain on the first postoperative day (4.05 ± 1.47 vs. 4.50 ± 1.32 , $P = 0.221$) for the two groups. Postoperative wounds were larger in group A than in group B ($2.07 \pm 0.1.90$ cm² vs. 1.23 ± 0.87 cm²), however this difference did not reach statistical significance ($P = 0.192$). Wound discharge was observed for a significantly longer duration in group A than in group B (4.10 ± 1.91 weeks vs. 2.75 ± 1.71 weeks, $P = 0.035$). There were no differences in social and sexual activities after surgery between the patients of the two groups. No patient developed anal incontinence or recurrence during the follow-up period of twelve weeks.

Conclusion: In comparison to a fistulectomy, a fistulotomy with marsupialization results in faster healing and a shorter duration of wound discharge without increasing the operating time.

Keywords: *Fistulectomy; Fistulotomy; Anal fistula*

INTRODUCTION

Conventional surgical options for a simple anal fistula include a fistulotomy and a fistulectomy [1]. A fistulectomy involves complete excision of the fistulous tract, thereby eliminating the risk of

missing secondary tracts and providing complete tissue for histopathological examination. A fistulotomy lays open the fistulous tract, thus leaving smaller unepithelized wounds, which hastens the wound healing. Marsupialization of the fistulotomy wounds can reduce the healing time further [2]. The present study was a randomized controlled trial that aimed to compare the fistulectomy to the fistulotomy with marsupialization in the management of simple anal fistula.

METHODS

This study was a randomized, two-arm, open-label, controlled pilot trial and was conducted in a single surgical unit of a tertiary teaching medical college in North India from September 2008 through April 2010. Patients admitted in surgery unit 1 with a clinical diagnosis of a simple anal fistula were included in the study.

Received: August 14, 2011 • Revised: October 25, 2011

Accepted: November 9, 2011

Correspondence to: Bhupendra Kumar Jain, M.S.

Department of Surgery, Guru Teg Bahadur Hospital, University of Delhi College of Medical Sciences, Dilshad garden, Delhi 110 095, India

Tel: +91-011-2269-2536, Fax: +91-986-839-9530

E-mail: bhupendrakjain@gmail.com

© 2012 The Korean Society of Coloproctology

This is an open-access article distributed under the terms of the Creative Commons Attribution Non-Commercial License (<http://creativecommons.org/licenses/by-nc/3.0>) which permits unrestricted non-commercial use, distribution, and reproduction in any medium, provided the original work is properly cited.

We defined a simple anal fistula clinically as one that had one internal opening, one external opening, a completely palpable tract, and no palpable abnormality in the upper anal canal or the lower rectum.

We planned a pilot study with a sample size of 40 patients. Inclusion criteria were as follows: low trans-sphincteric (fistula tract involving less than the lower third of the anal sphincter), inter sphincteric fistula, and subcutaneous fistula; a single internal and a single external opening; the absence of a secondary tract. Patients with a recurrent fistula, patients with associated co-morbid conditions such as anal fissure, hemorrhoids, chronic colitis, etc., and patients refusing consent for inclusion in study were excluded. All patients included in the study were interviewed to ascertain their clinical histories including presenting symptoms; duration of symptoms; and history of anorectal sepsis, previous surgery, and chronic illness. Inquiries were made to assess anal continence in each patient. All patients underwent detailed clinical examination to assess general health, presence of systemic disease, and anorectal pathology. The examination included perineal inspection, palpation, digital rectal examination, and proctoscopic evaluation. The distance of the external opening from the anal verge was measured using a plastic scale at the time of clinical examination.

Informed consent was obtained from patients for participation in the study. Ethical clearance was obtained from the institutional ethical board. The patients were divided randomly with the help of computer-generated random numbers into two groups with respect to operative procedure: the group that underwent a fistulectomy (group A) and the group that underwent a fistulotomy with marsupialization (group B). The randomization was done using computer-generated tables (www.randomization.com) having blocks of four patients in a 1:1 allocation ratio. No blinding was done in this study.

The patients were operated on under regional or general anesthesia. Under anesthesia, an anorectal examination was performed to verify the findings of the clinical examination. A dye study of the fistula tract was performed by placing moist gauze in the anal canal and injecting about 2 mL of methylene blue through the external opening. Staining of the gauze piece denoted patency of the fistula tract. A probe was gently passed into the fistulous tract through the external opening.

In the fistulotomy with marsupialization, the fistula tract was laid open over the probe placed in the tract. After the fistula tract had been laid open, the tract was curetted and examined for secondary extensions. Wound edges were sutured with the edge of fistula tract by using interrupted 3-0 chromic catgut sutures to marsupialize the operative wound from distal to proximal. The marsupialization would prove difficult proximally where the ano-rectal mucosa had been friable. Hemostasis was achieved (Fig. 1A-C).

In the fistulectomy, a keyhole skin incision was made over the fistulous tract and encircled the external opening. The incision was deepened through the subcutaneous tissue, and the tract was removed from surrounding tissues. Towards the anal verge, fibers




Fig. 1. Operative technique: (A-C) fistulotomy with marsupialization and (D-G) fistulectomy.

of the anal sphincters overlying the tract were divided [3]. While the tract was being removed, attention was paid to identifying secondary tracts, if any. Hemostasis was achieved (Fig. 1D, G).

The operating time for the procedure was calculated from the start of the dye test to the beginning of dressing of the postoperative wound. Patients in both groups were administered ciprofloxacin and metronidazole as perioperative antibiotics for a total duration of three days. Diclofenac sodium (50 mg twice a day) was prescribed as an analgesic for a total duration of 3 days. The patients were discharged on the first postoperative day. The patients were advised regarding oral medication, maintenance of local hygiene, sitz bath after defecation, dressings, and regular follow-ups.

The initial postoperative assessment was undertaken at twenty-four hours following surgery. The severity of postoperative pain was assessed on a scale of 0 to 10 with help of the visual analogue scale (VAS). Patients were asked about anal incontinence. Development of incontinence was assessed using the three-point Likert scale (0, never; 1, sometimes; 2, always) according to inability to distinguish between gas and stool, difficulty in holding gas, and soiling of undergarments [4]. All patients were followed up for a total duration of twelve weeks during the postoperative period. Patients were followed up at weekly intervals for the initial 6 weeks and at 2-week intervals for another 6 weeks. During each follow-up visit, the patient was assessed for postoperative pain, wound infection, and anal incontinence. Postoperative wound discharge was defined as a non-infected sero-sanguinous secretion from the open postoperative wound. Wound infection was defined as the presence of erythema, induration surrounding the wound or constitutional symptoms such as fever. Time required for complete healing of the postoperative wound, which was defined as the time for complete healing to take place with no area with an unepithelialized surface, was noted. The patients were observed for recurrence of the fistula during the follow-up period. No patients were lost during the follow-up period.

Patients were interviewed to assess their levels of satisfaction with respect to the treatment. The patients were requested to report whether the treatment affected their lifestyles during the post-operative period in terms physical activities, social activities, and sexual activities. For purposes of comparison, healing time was the primary outcome while size of the operative wound, operating time, postoperative pain, postoperative incontinence, patient satisfaction on the Lickert scale in terms of physical, social and sexual activities, and recurrence were secondary outcomes.

Analyses were performed using the SPSS ver. 10.0 (SPSS Inc., Chicago, IL, USA). Qualitative data from the two groups were compared using the chi square test or Fischer's exact test while quantitative data were compared using the Mann-Whitney U test.

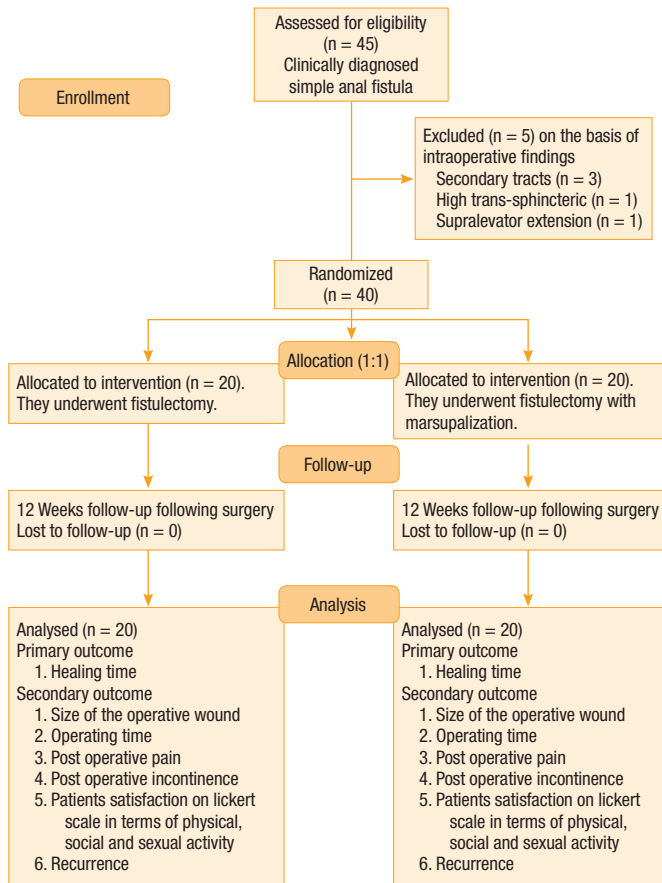


Fig. 2. Trial flow diagram.

Table 2. Pain score in the two groups

Mean VAS score	24 hr	1 wk	2 wk	3 wk	4 wk	8 wk	12 wk
Group A	4.05	2.60	1.85	0.95	0.88	0.10	0.00
Group B	4.50	2.85	2.30	1.05	0.30	0.00	0.00
P-value	0.221	0.495	0.242	0.968	0.383	0.799	1.00

VAS, visual analogue scale.

RESULTS

Forty-five patients clinically diagnosed to be suffering from a simple anal fistula were enrolled in this study. Five patients were excluded as they were subsequently found to have a complex anal fistula (Fig. 2). The mean age of the patients in group A was 34.55 ± 1.96 years with a male-to-female ratio of 16/4 while the mean age of the patients in group B was 34.30 ± 3.03 years with a male-to-female ratio of 18/2. The mean durations of symptoms in groups A and B, respectively, were 8.02 ± 3.90 days and 9.97 ± 2.84 days. There were 7 cases of subcutaneous fistulae, 12 cases of inter-sphincteric fistulae and 1 case of a low trans-sphincteric fistula in group A and 8 cases of subcutaneous fistulae, 11 cases of inter-sphincteric fistulae and 1 case of a low trans-sphincteric fistula in group B. The mean radial distances of the external opening from the anal verge were 2.27 ± 0.98 cm and 1.92 ± 0.84 cm in groups A and B, respectively. Both groups were comparable with respect to age, sex ratio, duration of symptoms, type of fistula and radial distance of the external opening from the anal verge (Table 1).

Postoperative wounds healed earlier in group B (4.85 ± 1.39 weeks) than in group A (6.75 ± 1.83 weeks). This difference in healing time reached statistical significance with a P-value of 0.003. Postoperative wounds ceased to ooze earlier in group B than in group A (2.75 ± 1.71 weeks vs. 4.10 ± 1.91 weeks, $P = 0.035$). No difference in the operating times was noted between the two groups. Though wound size was smaller in group B (1.23 ± 0.87 cm²) than in group A (2.06 ± 1.90 cm²), this difference did not reach statistical significance. None of the marsupialized wounds broke down in group B. No difference in pain score was noted between the two groups (Table 2). None of the patient in either group had recurrence or was found to have incontinence. No differences in the extents

Table 1. Preoperative and operative characteristics of the two groups

Characteristic	Group A	Group B	P-value
Age (yr)	34.55	34.30	0.718 ^a
Sex ratio (male/female)	10:1	5:1	0.662 ^b
Duration of symptoms (mo)	8.02 ± 3.90	9.97 ± 2.84	0.127 ^a
Radial distance of the external opening from the anal verge (cm)	2.27 ± 0.98	1.92 ± 0.84	0.301 ^a
Type of fistulous tract (subcutaneous/inter-sphincteric/trans-sphincteric)	7/12/1	8/11/1	0.946 ^b

^aMann Whitney U test. ^bChi square test.

Table 3. Adverse effects on the lifestyles of fistulectomy (group A) and fistulotomy-with-marsupialization (group B) patients

Adverse effect on lifestyle	Group A (n = 20)	Group B (n = 20)
Physical activity		
Not at all	14	17
To some extent	6	3
Greatly	0	0
Social activity		
Not at all	19	19
To some extent	1	1
Greatly	0	0
Sexual activity		
Not at all	20	20
To some extent	0	0
Greatly	0	0

of adverse effects of surgery on the physical, social and sexual lives of the patients in the two groups (Table 3).

DISCUSSION

The difference in the operating times for the two groups was not significant (28.00 ± 6.35 minutes vs. 28.20 ± 6.57 minutes, $P = 0.92$). The fistulectomy operation requires dissection of the fistula tract from the surrounding tissues, followed by coagulation of bleeding to control homeostasis. During a fistulotomy with marsupialization, the fistula tract is laid open, so dissection of the fistula tract is not required, but several minutes are required to suture the edges of the laid-open fistula tract to the skin incision. Thus, both procedures are likely to require almost similar times. In a study of 103 patients with anal fistulae who underwent a fistulotomy or a fistulectomy with marsupialization, Ho et al. [2] concluded that a longer operating time was required for marsupialization (8.0 ± 0.5 minutes vs. 10.0 ± 0.7 minutes, $P < 0.05$).

Postoperative wound size was measured after completion of surgery. Though the wound size was smaller in group A (2.06 ± 1.90 cm²), in comparison to group B (1.23 ± 0.87 cm²), the difference did not reach statistical significance ($P = 0.19$). In a study done by Pescatori et al. [5], the mean wound size was 1.17 ± 0.31 in patients who underwent either a laying open or an excision of the fistula in comparison to 0.81 ± 0.38 cm² in the case of marsupialized wounds.

Though the mean postoperative VAS score was higher for the fistulotomy with marsupialization, on statistical analysis, no difference in the pain score was noted between the groups. Pain scores at various follow-up times were evaluated and compared for any statistical significant difference. No significant statistical difference was seen between the two group ($P > 0.05$, Mann-Whitney test). In both groups, subsidence of pain (VAS score < 1) was noted at

about three weeks. Similar results have been reported by Pescatori et al. [5] who found that the mean pain score at 12 hours postoperatively was 3.4 ± 1.6 and 3.5 ± 1.5 in the non-marsupialized group and the marsupialized group, respectively; however, the difference between the two groups was statistically insignificant ($P > 0.05$).

Anal incontinence was not noticed in any of the patients in either group. This is logical as all the internal openings were located in the lower anal canal in our patients. A study conducted by Kronborg [1] to compare the fistulectomy with the fistulotomy demonstrated development of anal incontinence in 3 of 17 patients after the fistulectomy in comparison to 1 of 20 patients after the fistulotomy. They included all patients with a single-tract anal fistula below the anorectal ring in their study. In a study to compare clinical and anometric outcomes of marsupialization on the fistulotomy wound, Ho et al. [2] observed temporary anal incontinence in one patient (2%) in the marsupialized group compared with 6 (12%) in the non-marsupialized group. Lindsey et al. [6] conducted a randomized controlled trial to compare the fistulotomy with fibrin glue for a simple anal fistula. The maximum resting and squeeze pressures were not significantly changed in either the glue ($P = 0.56$) or the fistulotomy ($P = 0.48$) groups in that study.

None of the patients reported fever or increasing pain during the postoperative period. On examination, neither erythema nor induration around the operative wound was seen in any of the patients. Persistent wound discharge was observed in group A for a mean period of 4.10 ± 1.91 weeks and in group B for 2.75 ± 1.71 weeks. This difference on statistical analysis was found to be significant ($P = 0.035$, Mann-Whitney test). A study conducted by Pescatori et al. [5] demonstrated a 14% postoperative sepsis rate in the marsupialized group in comparison to 21% in the non-marsupialized group.

In the present study, statistically significant difference in healing times was noted between the two groups, the mean healing time was longer in group A (6.75 ± 1.83 weeks) than in group B (4.85 ± 1.39 weeks). The difference in healing rates was found to be statistically significant ($P = 0.003$, Mann-Whitney test). The fistulotomy with marsupialization wounds were smaller than the fistulectomy wounds (1.23 ± 0.87 cm² vs. $2.06 \pm 0.1.90$ cm²), though this difference did not reach statistical significance. Further in the case of the fistulotomy with marsupialization, the fistula tract, which could have been epithelized to varying extent, formed the floor of the wound. These facts explain earlier healing of the wound in the fistulotomy-with-marsupialization group in comparison to the fistulectomy group. A study conducted by Kronborg [1] showed a median healing time of 5.85 weeks for fistulectomy wounds in comparison to 4.55 weeks for fistulotomy wounds ($P < 0.02$). In a study conducted by Ho et al. [2], marsupialized wounds had significantly faster healing than non-marsupialized wounds (6.0 ± 0.4 weeks vs. 10.0 ± 0.5 weeks, $P < 0.001$).

No recurrence was reported in any patient in either group for a follow-up period of 12 weeks in our study. However, the duration of observation in the present study was not sufficient to draw any

definite correlation with respect to recurrence. Kronborg [1] reported that the recurrence rates following a fistulectomy and a fistulotomy were 9.52% and 12.5%, respectively, during a follow-up period of 12 months. In a retrospective study conducted to determine satisfaction following surgery, 12% of the patients expressed dissatisfaction following surgery [4]. The majority of those patients attributed their dissatisfaction to recurrence and anal incontinence following surgery. In the present study, no patient developed any incontinence or recurrence during the follow-up period. Six patients in group A indicated that their physical activities had been impacted in comparison to three patients in group B, but this difference groups was not significant ($P = 0.429$). No differences with respect to social activity and sexual activity were noted.

The small sample size is one of the limitations of this study. Another limitation is the large number of subcutaneous fistulae in both groups of patients because surgical treatment of a subcutaneous fistula is unlikely to compromise continence. This may be the reason for the better functional outcome seen in our patients in both groups.

This study demonstrated shorter wound healing time and shorter duration of postoperative wound discharge following a fistulotomy with marsupialization in comparison to a fistulectomy. Limitations of this study include small sample size and short follow-up period. The findings of the present study need to be substantiated further with studies involving larger sample sizes and longer follow-ups.

CONFLICT OF INTEREST

No potential conflict of interest relevant to this article was reported.

REFERENCES

1. Kronborg O. To lay open or excise a fistula-in-ano: a randomized trial. *Br J Surg* 1985;72:970.
2. Ho YH, Tan M, Leong AF, Seow-Choen F. Marsupialization of fistulotomy wounds improves healing: a randomized controlled trial. *Br J Surg* 1998;85:105-7.
3. Farquhasan EL. Operations in rectum and anal canal: Fistula-in-ano. In: Rintoul HF, editor. *Textbook of operative surgery*. 5th ed. Edinburgh: Churchill Livingstone; 1971. p.732-3.
4. García-Aguilar J, Davey CS, Le CT, Lowry AC, Rothenberger DA. Patient satisfaction after surgical treatment for fistula-in-ano. *Dis Colon Rectum* 2000;43:1206-12.
5. Pescatori M, Ayabaca SM, Cafaro D, Iannello A, Magrini S. Marsupialization of fistulotomy and fistulectomy wounds improves healing and decreases bleeding: a randomized controlled trial. *Colorectal Dis* 2006;8:11-4.
6. Lindsey I, Smilgin-Humphreys MM, Cunningham C, Mortensen NJ, George BD. A randomized, controlled trial of fibrin glue vs. conventional treatment for anal fistula. *Dis Colon Rectum* 2002; 45:1608-15.