

Toxicological evaluation of subchronic use of pioglitazone in mice

Said Said Elshama¹, Ayman El-Meghawry El-Kenawy^{2,3*}, Hosam-Eldin Hussein Osman⁴

¹ Department of Forensic Medicine and Clinical Toxicology, College of Medicine, Taif University, Suez Canal University, Taif, KSA

² Department of Pathology, College of Medicine, Taif University, Taif, KSA

³ Department of Molecular Biology, GEBRI, University of Sadat City, Egypt

⁴ Department of Anatomy, College of Medicine, Taif University, Al-Azhar University, Taif, KSA

ARTICLE INFO

Article type:

Original article

Article history:

Received: Sep 6, 2015

Accepted: Nov 5, 2015

Keywords:

Mice
Pioglitazone
Sub-chronic use
Toxicity

ABSTRACT

Objective(s): Pioglitazone (Actos) is one of the most controversial recent oral antidiabetic drugs. It was originally authorized in the European Union in 2000, and approved as an oral monotherapy for overweight second type of diabetic patients in 2002. It belongs to the thiazolidinedione group which some of its members have been withdrawn from the market due to the hepatotoxicity or cardiotoxicity effects. This study investigates sub-chronic use of pioglitazone induced toxicity in mice by the assessment of renal and liver function tests, cardiac enzymes, and some hematological indices with histological changes of liver, kidney, heart, and bladder.

Materials and Methods: 120 albino mice were divided into four groups; 30 in each. The first group (control) received water, second (diabetic) group received alloxan only, while the third and the fourth groups received alloxan with 200 and 400 mg/kg/day of pioglitazone, respectively for 90 days.

Results: Prolonged use of pioglitazone induced significant abnormalities of hepatic, renal, and cardiac biomarkers and some hematological indices associated with histopathological changes in the liver, kidney, heart, and bladder that increased based on administered dose.

Conclusion: Subchronic use of pioglitazone leads to hepatic, renal, cardiac, hematological, and bladder affection depending on the applied dose.

► Please cite this article as:

Elshama S, El-Kenawy A, Osman HE. Toxicological evaluation of sub-chronic use of pioglitazone in mice. Iran J Basic Med Sci 2016; 19:712-719.

Introduction

Pioglitazone (Actos) is one of the most recent oral antidiabetic drugs for treating the second type of diabetes mellitus as a common chronic and lifelong disease which affects the ability of the body to use the energy found in the food. Diabetes represents a major clinical and public health problem in the world, an estimated 1.5 million deaths were directly caused by diabetes in 2012, according to World Health Organization (1). It is classified into type 1, type 2, and the gestational type; diabetes type 2 is the most common form and represents 95% of diabetes cases in the adults (2).

Pioglitazone was originally authorized in the European Union in 2000 at doses of 15 or 30 mg once daily, but it was approved as an oral monotherapy for overweight diabetic patients and uncontrolled cases by diet and exercise in 2002 (3). It is also considered a thiazolidinedione compound and peroxisome proliferator activating receptor agonist. Its activity depends on the presence of insulin,

however, it does not stimulate insulin secretion nor inhibit glucose absorption (4), moreover, it improves dyslipidemia, hypertension, and insulin sensitivity in the diabetic patients by improving the sensitivity of hepatic and peripheral (muscle) tissue to insulin (5). It is highly bound to plasma proteins and metabolized in the liver inducing six metabolites which have pharmacological activity (hypoglycemic activity) (6). It has a slow clearance from the blood, despite the small volume of distribution with negligible renal elimination (7).

Pioglitazone has additional multiple benefits, as an antiparkinsonian, antibacterial, hypolipidemic agent, and influences on the learning, memory, and oxidative stress in addition to glucose lowering effect. It also improves cardiovascular parameters such as lipids, blood pressure, endothelial function, inflammatory biomarkers, and fibrinolytic status (8). In spite of its beneficial effects, there are emerging harmful issues regarding effects on congestive heart failure and bladder cancer (9).

*Corresponding author: Ayman El-Meghawry El-Kenawy. Department of Molecular Biology, GEBRI, University of Sadat City, Egypt. Tel: 00966535869616; Fax: 0096627250528; email: elkenawyay@yahoo.com

There are many previous supportive studies about pioglitazone safety, but they do not provide a conclusive evidence for the safety. Some studies indicated to an idiosyncratic hepatic reaction, liver failure, and death due to the use of pioglitazone, while the others referred to liver failure without associated deaths (10). Until now, no long term studies are available about toxicity of pioglitazone repeated administration, whereas, its clinical use is currently under scrutiny because of the safety issues. Although most of the insulin-resistant patients might be the best candidates for treatment with pioglitazone as an important therapeutic option for type 2 diabetes mellitus, there is a need for further studies about its safety (11, 12). Therefore, the current study aims to evaluate the toxicity of pioglitazone subchronic use in mice by the assessment of liver and renal function tests, cardiac enzymes, hematological indices, and histopathological changes of liver, kidney, bladder, and heart.

Materials and Methods

120 albino mice, 6-8 weeks of age, weighing 25-35 g were obtained from the animal house of King Abdulaziz University-Jeddah. Mice were exposed to 12 hr day and night cycles, and were fed with water and the standard rat pellet during the experimental period. They were divided into four groups; each group consists of 30 mice. The first group (negative control) received distilled water (0.5 ml), while the second group (positive control, diabetics) received an intraperitoneal single dose of alloxan (100 mg/kg) (13). The third group received an intraperitoneal single dose of alloxan (100 mg/kg) with oral dose of 10% pioglitazone LD₅₀ (200 mg/kg/day), while the fourth group received an intraperitoneal single dose of alloxan (100 mg/kg) with oral dose of 20% of pioglitazone LD₅₀ (400 mg/kg/day). LD₅₀ of pioglitazone was calculated practically as a 2000 mg/kg/day given orally before the beginning of this study, in consistent with the calculated LD₅₀ of pioglitazone reported by in 2012 (14). Administration of pioglitazone and distilled water was done by gastric gavage for 90 days. Pioglitazone was available in 30 mg tablet, manufactured by Hi Pharm for Manufacturing Pharmaceuticals and chemicals, Al Obour City-Cairo, Egypt. Alloxan was available in a monohydrate powder that was produced by Research-Lab Fine Chem., Industries, Mumbai 400 002 India.

Diabetes was induced by a single intraperitoneal injection of alloxan in overnight fasted mice. Mice had free access to 5% glucose solution to overcome the initial hypoglycemia after alloxan administration, and the blood glucose level was measured after 72 hr. Blood samples were collected from the tail to confirm diabetes using a glucometer (ACCU- Chek

Active- Ref. 05144469); if the blood glucose level was 200 mg/dl or more, mice were considered diabetics (15).

Blood sample collection

On the last day of the experiment, mice were anesthetized by diethyl ether, blood samples were collected from the orbital sinus using heparinized capillary tubes and transferred into EDTA tubes for blood cells and platelet counts, and hematocrit and hemoglobin values measurement. Samples were centrifuged at 3000 rounds, 4 °C for 10 min to separate the serum. Alanine aminotransferase (ALT), aspartate aminotransferase (AST), alkaline phosphatase (ALP), and the renal function tests (urea and creatinine) were determined by routine colorimetric methods using the commercial kits and quantified on clinical biochemistry autoanalyzer (16). Prothrombin time test was done with a coagulometer (Sysmex® CA-1500-Siemens-Healthcare Diagnostics) (17). Cardiac enzymes (cTnI and CK-MB mass) were measured using an Elecsys analyzer by the troponin I STAT third generation and CK-MB STAT methods (Roche Diagnostics, Tutzing, Germany). These assays were based on electrochemiluminescence immunoassay technology (ECLIA) using two mouse monoclonal antibodies in a sandwich format, two step assay. They were done on Elecsys 1010 and 2010 immunoassay analyzers according to the manufacturer's instructions (Roche Diagnostics, Tutzing, Germany). Myoglobin concentration was determined using the respective Stratus fluorometric enzyme immunoassay (Dade Behring, Newark, Delaware, USA) (18).

Histopathological studies

After 24 hr from the last administration of pioglitazone, mice were sacrificed under an excess anesthesia. An incision was performed in the chest and abdomen for heart, liver, kidney, and the bladder excision. Cardiac, hepatic, renal, and bladder tissue specimens were collected from the four groups and fixed in 10% neutral buffered formalin, then the fixed specimens were trimmed, washed, and dehydrated in ascending grades of alcohol, cleared in the xylene, embedded in paraffin, sectioned at 4-6 µm thickness, and stained with haematoxylin and eosin for examination by light microscope (19).

Statistical analysis

Statistical analysis was performed using SPSS version 17. Variability of the results was expressed as mean±SD. Results were analyzed using one-way ANOVA with *post hoc* multiple comparisons test (Tukey) to investigate the difference between the biomarker levels among the groups. *P*-value of 0.05 was considered statistically significant.

Table 1. The effect of low and high doses of pioglitazone on hepatic biomarkers in mice.

Group Parameter	First M±SD	Second M±SD	Third M±SD	Fourth M±SD	F
AST(IU/l)	29.50±3.285	48.90±4.090	80.35±6.800*	150.70±15.246**	739.265
ALT(IU/l)	28.60±3.016	48.15±5.851	68.25±9.662*	127.40±15.686**	381.452
ALP (IU/l)	79.45±10.570	48.55±4.861	173.90±13.992*	229.65±11.940**	1.183

Number per group: 30; SD: standard deviation; AST: Aspartate aminotransferase; ALT: Alanine aminotransferase; ALP: Alkaline phosphatase; First group (control) received distilled water; Second diabetic group received alloxan only; Third group received alloxan and 200 mg/kg/day of pioglitazone; Fourth group received alloxan and 400 mg/kg/day of pioglitazone

* $P < 0.001$ (significant difference in comparison with the second group); ** $P < 0.001$ (significant difference in comparison with the third group)

Ethical considerations

Mice were chosen as the most appropriate animal species for this research. High standards of the care and animal well-being at all times were regarded. The sample size was calculated using the fewest number of animals to obtain statistically valid results. Painful procedures were performed under anesthesia to avoid any distress and pain. Our standards of the animal care and administration met those required by an applicable international laws and regulations.

Results

Biochemical findings

Hepatic biochemical markers

Table 1 shows mean±SD values of hepatic biochemical markers in the control group (distilled water), the second diabetic group (alloxan only), the third group (alloxan and 200 mg/kg/day of pioglitazone), and the fourth group (alloxan and 400 mg/kg/day of pioglitazone). Mean±SD values of AST, ALT, and ALP in the third group were increased significantly in comparison with the second group; however, mean±SD values of AST, ALT, and ALP in the fourth group were increased significantly in comparison with the third group.

Renal biochemical markers

Table 2 shows mean±SD values of the renal function

Table 2. The effect of low and high doses of pioglitazone on renal biomarkers in mice

Parameter	Group	First M ± SD	Second M ± SD	Third M ± SD	Fourth M ± SD	F
Urea (mg/dl)		30.2 ± 7.49	35.6 ± 1.46	45.1 ± 1.07*	54.4 ± 2.56**	98.7
Creatinine (mg/dl)		0.51 ± 0.17	0.76 ± 0.13	1.10 ± 0.18*	1.88 ± 0.21**	33.28

Number per group: 30; SD: standard deviation; First group (control) received distilled water; Second diabetic group received alloxan only; Third group received alloxan and 200 mg/kg/day of pioglitazone; Fourth group received alloxan and 400 mg/kg/day of pioglitazone;

* $P < 0.001$ (significant difference in comparison with the second diabetic group)

** $P < 0.001$ (significant difference in comparison with the third group)

Table 3. The effect of low and high doses of pioglitazone on cardiac enzymes in mice

Group Parameter	First M ± SD	Second M ± SD	Third M ± SD	Fourth M ± SD	F
Troponin-1 (ng/ml)	0.0028±0.00132	0.0046±0.0005	0.1645±0.01605*	0.762±0.01436**	2.230
CK-MB (ng/ml)	20.4±1.903	27.6±2.542	135.1±14.92*	249.70±17.52**	1.727
Myoglobin (ng/ml)	127.85±3.977	125.8±3.318	171.5±7.09*	295.45±12.996**	2.066

Number per group: 30; SD: standard deviation CK-MB: Creatine kinase-MB; First group (control) received distilled water; Second diabetic group received alloxan only; Third group received alloxan and 200 mg/kg/day of pioglitazone; Fourth group received alloxan and 400 mg/kg/day of pioglitazone

* $P < 0.001$ (significant difference in comparison with the second diabetic group)

** $P < 0.001$ (significant difference in comparison with the third group)

tests in all the experimental groups. Mean±SD values of urea and creatinine in the third group were increased significantly in comparison with the second group. However, mean±SD values of urea and creatinine in the fourth group were increased significantly in comparison with the third group.

Cardiac enzymes assay

Table 3 shows mean±SD values of cardiac enzymes in all the experimental groups. Mean±SD values of troponin I, CK-MB, and myoglobin in the third group were increased significantly in comparison with the second group, however, they were also increased significantly in the fourth group compared to the third group.

Hematological findings

Table 4 shows mean±SD values of hematological indices in all experimental groups. Mean±SD values of hemoglobin, haematocrit, white blood cells, red blood cells, and platelets count in the third group were increased significantly in comparison with the second group. Although they were elevated significantly in the fourth group in comparison with the third group, mean±SD value of prothrombin time in the fourth group was decreased significantly in comparison with the third group.

Table 4. The effect of low and high doses of pioglitazone on hematological indices in mice

Group Parameter	First M±SD	Second M±SD	Third M±SD	Fourth M±SD	F
HB	15.534±1.0051	11.905±0.8817	14.4±0.6836*	16.675±0.4327**	136.235
WBCs	5.706±0.1873	5.775±213.3108	7.6±1.5379*	9.32±0.4595**	1.112
RBCs	4.719±0.1869	3.794±0.7182	8.557±0.6033*	11.233±0.912**	546.548
HCT	39.326±1.7324	39.030±4.0669	41.2±3.1556*	48.1±0.9679**	47.127
PLAT	300.5±59.5134	155.34±76.830	867.7±57.2364*	1363±63.9499**	1.228
PT	25.55±0.2503	25.535±0.2455	26.345±0.1905	24.01±0.4789**	196.233

Number per group: 30; SD: standard deviation; HB: Hemoglobin; WBCs: White blood cells; RBCs: Red blood cells; HCT: Haematocrit; PLAT: Platelet; First group (control) received distilled water; Second diabetic group received alloxan only; Third group received alloxan and 200 mg/kg/day of pioglitazone; Fourth group received alloxan and 400 mg/kg/day of pioglitazone

* P<0.001 (significant difference in comparison with the second diabetic group)

** P< 0.001 (significant difference in comparison with the third group)

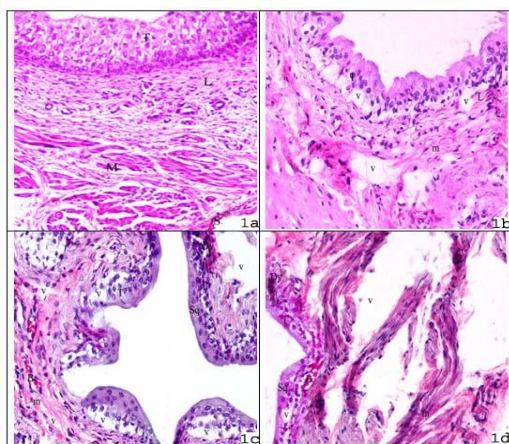


Figure 1. 1a) First group urinary bladder section shows normal transitional epithelium (T), lamina propria (L) of mucosa, the inner and outer longitudinal layers of muscosa with thicker middle circular layers (M), and fibroelastic connective tissue (S) of adventitia, (H&E X400). 1b) Second group urinary bladder section shows a mild disorganization in the transitional epithelial cells (T), the lamina propria (L) of mucosa with presence of vacuoles (V), mild disorganization, and atrophy of the muscular layer (m), (H&E X400). 1c) Third group urinary bladder section shows marked decrease in cell thickness of the transitional epithelial superficial cells (T) with cloudy swelling and vacuoles (v), some cellular squamous metaplasia changes (Sq) with mild dysplasia (Dy) in other areas, congestion of the blood vessels (B) with lamina propria (V) vacuoles, and marked atrophy and disorganization (m) in the muscular layer, (H&E X400). 1d) Fourth group urinary bladder section shows marked disorganization, necrosis and atrophy of the transitional epithelial cells (T) with vacuoles in other cells, squamous metaplasia changes (Sq) in some areas, with dysplasia (Dy) in other areas, congestion of the blood vessels (B) with cavities in the lamina propria (L), and marked disorganization and atrophy (m) in the muscular layer, (H&E X400)

Histopathological findings

Urinary bladder histopathological findings

Urinary bladder tissues of the first group (negative control) showed normal urinary bladder structure (Figure 1a). However, urinary bladder tissues of the second group (positive control “diabetic group”) showed a mild disorganization of the mucosa transitional epithelial cells and the lamina propria and decreased thickness of the superficial cells with a mild atrophy of the three muscular layers (Figure 1b). Transverse section of the urinary bladder tissues of the third group

showed necrosis of the superficial cells of the mucosal transitional epithelial cells with marked decrease in the cell thickness, cloudy swelling and vacuoles, cellular squamous metaplasia changes in some areas with mild dysplasia in other areas, blood vessels congestion, lamina propria vacuoles, and marked disorganization and atrophy of the three muscular layers (Figure 1c). The urinary bladder tissues of the fourth group showed marked necrosis and atrophy of the mucosal transitional epithelial cells with disorganization and vacuolation, squamous metaplasia changes with dysplasia in different areas, vascular congestion with cavities in lamina propria, and marked muscular layer disorganization and atrophy in all its three layers (Figure 1d).

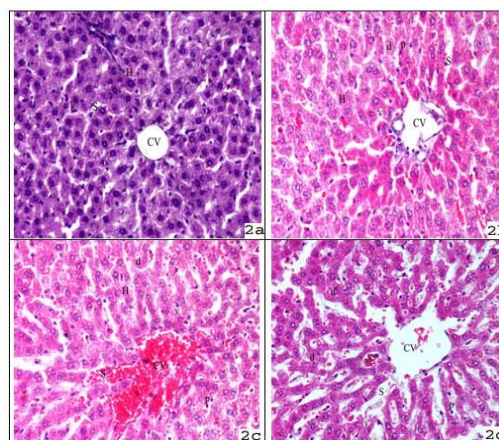


Figure 2. 2a) First group liver section shows normal hepatic architecture, central vein (CV) in the middle, and hepatocytes (H) arranged in hepatic cords around the central vein and separated by the adjacent blood sinusoids (S) containing Kupffer cells, (H&E X400). 2b) Second group liver section shows congestion and dilatation of the central vein (CV) and the blood sinusoids (S), some hepatocytes (H), light and foamy cytoplasm with vacuoles (V), pyknotic nuclei (P), and hepatocytes degeneration (d), (H&E X400). 2c) Third group liver section shows a cloudy swelling in the cytoplasm of the hepatocytes with vacuoles (V), small fragmented pyknotic nuclei (P), hepatocytes degeneration (d), congested and dilated central vein (CV), and blood sinusoids (S), (H&E X400). 2d) Fourth group liver section shows marked fragmented pyknotic nuclei (P), degenerated hepatocytes (d), marked hepatocytes shrinkage with marked vacuoles (V) in the cytoplasm and massive necrosis of hepatocytes, widening and congestion of the central vein (CV) and blood sinusoids (S), (H&E X400)

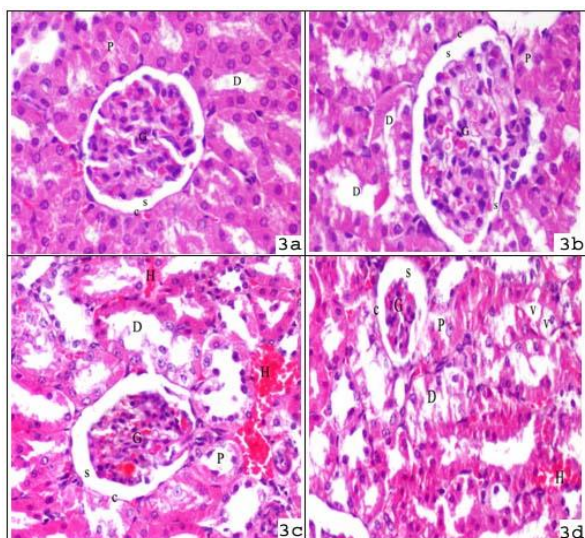


Figure 3. 3a) First group kidney section shows normal renal glomeruli (G), glomerular capsule (c) with distinct capsular space (s), and proximal (P) and distal (D) renal tubules, (H&E X400). 3b) Second group kidney section shows congested and enlarged glomeruli (G), tight filling of the glomerular capsular space (c), and the flat epithelium lining the Bowman's capsule (c), and oedema and degeneration in some cells of the proximal (P) and distal (D) renal tubular epithelium, (H&E X400). 3c) Third group kidney section shows a slight shrinkage glomeruli (G), widening of the glomerular capsular space (s), degeneration of the epithelial lining of the Bowman's capsule (c), and damage of some epithelial cells of the proximal (P) and distal (D) renal tubules with lumen widening by an inter tubular hemorrhage (H), (H&E X400). 3d) the fourth group kidney section shows marked shrinkage glomeruli (G), widening of the glomerular capsular space (s), degeneration of the epithelial lining of the Bowman's capsule (c), and damage of the most epithelial cells of the proximal (P) and distal (D) renal tubules with lumen widening by an inter tubular hemorrhage (H), (H&E X400)

Hepatic histopathological findings

Hepatic tissues of the first group (negative control) showed normal hepatic architecture (Figure 2a). However, hepatic tissues of the second group (positive control "diabetic group") showed central vein congestion with mild dilatation of the blood sinusoids, and pyknosis of hepatocytes nuclei (Figure 2b). Transverse section of hepatic tissues of the third group showed mild loss of normal hepatic architecture and cloudy degeneration in the cytoplasm of hepatocytes, increased number of vacuoles with small fragmented pyknotic nuclei, congestion and dilatation of the blood sinusoids with the degenerated areas (Figure 2c). Hepatic tissues of the fourth group showed massive necrosis of hepatocytes around the central vein of hepatic lobules, shrinkage of hepatic cells, and increased number of vacuoles in the cytoplasm with small fragmented pyknotic nuclei around the central vein (Figure 2d).

Renal histopathological findings

Renal sections of the first group (negative control) revealed entirely normal histological features, as illustrated in (Figure 3a), while the renal

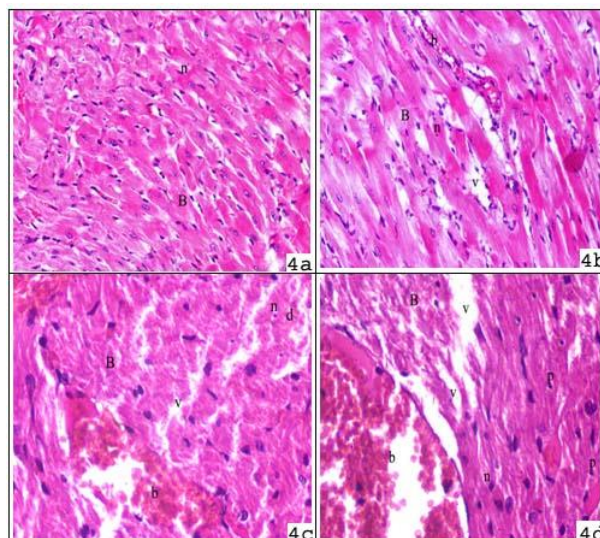


Figure 4. 4a) First group heart section with normal branching and anastomosis of cardiac muscle fibers (B), acidophilic sarcoplasm, and central oval vesicular nuclei (n), (H&E X400). 4b) Second group heart section shows disturbances of cardiac muscle fibers (B), acidophilic sarcoplasm, with deformed nuclei (n), vacuoles (v), and congested blood vessels (b), (H&E X400). 4c) Third group heart section shows fragmentation and degeneration of the cardiac muscle fibers (B), large size of vacuoles (v), acidophilic sarcoplasm, degenerated area (d) with degenerated nuclei (n), and congested blood vessels (b), (H&E X400). 4d) Heart section of the fourth group shows widespread fragmentation and degeneration of the cardiac muscle fibers (B), huge number and size of vacuoles (v), acidophilic sarcoplasm, degenerated (n) and pyknotic nuclei (p), increased number and size of the degenerated areas (d), and increased size of congested blood vessels (b), (H&E X400)

sections of the second group (positive control "diabetic group") showed mild areas of tubular damages, hypertrophy of renal tubules epithelium, some enlarged glomeruli, and tight filling of Bowman's capsule with the absence of capsular spaces (Figure 3b). The renal tissues of the third group showed mild degeneration of the renal tubules epithelial, mononuclear cells infiltration, single epithelial cells desquamation in the lumen of few renal tubules, shrinkage of small number of glomeruli, and hyperemia of the renal vessels (Figure 3c). The renal sections of the fourth group showed marked degeneration of the renal tubules epithelial, single epithelial cells desquamation in the lumen of a large number of the renal tubules, and glomerular atrophy (Figure 3d).

Cardiac histopathological findings

Cardiac sections of the first group revealed normal appearance of myocardium (Figure 4a). However, the cardiac tissues of the second group showed a moderate disruption of cardiac myofibrils pattern in comparison to the negative control group, with deformation of cardiomyocytes nuclei in the size and shape (Figure 4b). The cardiac sections of the third group showed mild loss of normal cardiac architecture, small fragmented pyknotic nuclei, and

inflammatory cell infiltration in the cytoplasm of the cardiomyocytes with increased number of vacuoles and mild disturbance of cardiac myofibrils in comparison with the second group (Figure 4c). Moreover, cardiac sections of the fourth group showed marked loss of normal cardiac architecture, shrinkage of cardiomyocytes, small fragmented pyknotic nuclei, marked number of vacuoles in the cytoplasm, marked disarray of cardiac myofibrils in comparison with the second and third groups (Figure 4d).

Discussion

Pioglitazone is a controversial new oral antidiabetic drug, belongs to the thiazolidinedione group that some of its members have been withdrawn from the market because of hepatotoxicity, such as troglitazone, (20) while the other was prohibited because of cardiotoxicity, such as rosiglitazone (21). Many studies focused on acute use of large doses of pioglitazone, while the chronic and subchronic use are usually the most common methods. Therefore, this study attempts to assess the systemic toxicity related to the subchronic administration of lower doses of pioglitazone in mice compared to the doses applied in the previous studies.

Our results showed a statistical significant increase of hepatic biomarkers, mild loss of normal hepatic architecture, and cloudy degeneration in the cytoplasm of hepatocytes with small fragmented pyknotic nuclei, congestion and dilatation of the blood sinusoids, in the third group (alloxan and 200 mg/kg/day of pioglitazone) in comparison with the second diabetic group. These hepatic biochemical findings become more severe in the fourth group (alloxan and 400 mg/kg/day of pioglitazone) which were associated with severe histopathological changes, such as massive necrosis of hepatocytes around the central vein of hepatic lobules with hepatic cells shrinkage, in comparison with the third group. These results are in consistent with previous studies (22, 23) suggesting that pioglitazone prevents ATP production and induces cytotoxicity and oxidative stress which lead to reactive metabolite formation and hepatocyte mitochondrial impairment involved in hepatotoxicity mechanism, according to Pessayre *et al* 1999 (24). However, these results are in contrast with the study of Elgawly *et al* 2009 (25) who indicated that pioglitazone has no harmful effect on liver, if used for a short period of time.

The present study demonstrated a statistically significant increase of renal biomarkers levels (urea and creatinine) and histopathological changes, such as mild degeneration of the epithelial renal tubules, single epithelial cells desquamation in the lumen of few renal tubules, and shrinkage of small number of

glomeruli in the third group in comparison with the second diabetic group. These findings become more severe in the fourth group which were associated with severe histopathological findings, such as marked degeneration of the epithelial renal tubules, single epithelial cells desquamation in the lumen of a large number of the renal tubules, and shrinkage of a large number of glomeruli. This is in contrast with previous reports about the mild renal effects of pioglitazone, only representing as mild renal congestion; also indicated that serum concentration of pioglitazone and its metabolites do not raise after the repeated doses and the elimination of pioglitazone with its metabolites is primarily hepatic, so, the renal pioglitazone clearance is little (14, 26).

The current study showed a statistically significant increase of all cardiac enzymes levels (creatinine kinase "CK-MB", troponin I "CTnI", and myoglobin) in the third group associated with mild loss of cardiac architecture, cardiac myofibrils disturbances with small fragmented pyknotic nuclei, and inflammatory cell infiltration in the cytoplasm of cardiomyocytes in comparison with the second diabetic group. These cardiac biochemical and histopathological findings become more marked in the fourth group in comparison with the third group. Our cardiac histopathological results are in consistent previous studies suggested (14, 27) that cardiac toxic effect of pioglitazone leads to cardiac muscle hypertrophy and then ventricular hypertrophy. But, Lincoff *et al* 2007 (28) indicated that the risk of myocardial infarction decreases with the use of pioglitazone; this is in contrast with our results regarding statistically significant increase of cardiac biomarkers levels (creatinine kinase "CK-MB" and troponin I "CTnI") as the highly specific and the gold standard markers of myocardial infarction proposed in people and small animals (29, 30).

The present study also showed a statistically significant increase in the values of hematological indices (red blood cells, white blood cells, platelets, hemoglobin, and haematocrit) in the third group in comparison to the second diabetic group. However, the values of hematological indices in the fourth group were significantly higher compared to the third group. This is in contrast with a recent study (31) that showed reduced red blood cells count, haematocrit, and haemoglobin levels due to hemodilution as a result of pioglitazone induced fluid retention. However, reduced values of hematological indices have been also reported due to the suppressive effect of pioglitazone (32). Although, prothrombin time in the fourth group was significantly decreased in comparison with the third group, prolonged prothrombin time due to pioglitazone use has been reported before (23).

Our results showed many histopathological changes in the urinary bladder, such as disorganiza-

tion and atrophy of the muscular layers, necrosis of the mucosal transitional epithelial cells, squamous metaplasia alternating with mild dysplasia in the third group, while these urinary bladder histopathological changes become more marked in the fourth group. Urinary bladder dysplasia is considered as a putative precursor of urothelial carcinoma in situ and metaplastic change which is a premalignant condition (33), so, the association between the pioglitazone administration and bladder cancer development could be possible (34). Pioglitazone as a peroxisome proliferator activating receptor agonist, has shown a direct effect on peroxisome proliferator-activated receptors (PPAR γ 1) in the urothelial cells leading to bladder carcinogenesis via non-DNA reactive agents (35, 36). No relation between the pioglitazone administration and the bladder cancer development has been also proposed in one study, although they reported the increased risk of chronic kidney disease development following pioglitazone application (37).

Conclusion

Subchronic use of pioglitazone may lead to hepatotoxicity, renal toxicity, cardiotoxicity, hematological disorders, and bladder affection, which are manifested by biochemical abnormalities and histopathological changes; however, the severity of toxicity depends on its dose.

Recommendations

Performing clinical studies on human might confirm out experimental results. Further studies with different doses and periods of time are also suggested to complete this work. Thus, the use of pioglitazone should be restricted as much as possible because of its probable toxicity on the vital organs, until proven otherwise.

References

1. World Health Organization "WHO". Global Health Estimates: Deaths by Cause, Age, Sex and Country, 2000-2012. Geneva: 2014.
2. Mizrachi E, Bernel-Mizrachi C. Diabetes mellitus and related disorders. In: Cooper DH, Krainik AJ, Lubner SJ, Reno HEL, editors. Washington manual of medical therapeutics. 32nd ed. Philadelphia, PA: Wolters Kluwer/Lippincott Williams and Wilkins; 2007.p. 600-623.
3. Belfort R, Harrison SA, Brown K, Darland C, Finch J, Hardies J, *et al*. A placebo-controlled trial of pioglitazone in subjects with nonalcoholic steatohepatitis. *N Engl J Med* 2006; 355:2297-2307.
4. Nolte MS. Pancreatic hormones and antidiabetic drugs. In: Katzung BG, Masters SB, Trevor AJ, editors. Basic and clinical pharmacology. 11th ed. New Delhi: Tata McGraw Hill Education Private Limited; 2009.p. 727-751.
5. Schernthaner G, Matthews DR, Charbonnel B, Hanefeld M, Brunetti P. Quartet Study Group. Efficacy and safety of pioglitazone versus metformin in patients with type 2 diabetes mellitus: a doubleblind, randomized trial. *J Clin Endocrinol Metab* 2004; 89:6068-6076.
6. Saha SK, Das SC, Abdullah AE, Sarker M, Uddin MA, Chowdhury AK, *et al*. Biochemical alterations and liver toxicity analysis with pioglitazone in healthy subjects. *Drug Chem Toxicol* 2012; 36:149-154.
7. Brunton LL, Lazo JS, Parker KL. Goodman and Gilman's the Pharmacological Basis of Therapeutics, 11th ed. United States of America: McGraw Medical Publishing Division; 2006.p.1613-1645.
8. Patel C, Wyne KL, McGuire DK. Thiazolidinediones, peripheral oedema and congestive heart failure: what is the evidence? *Diabetes Vasc Dis Res* 2005; 2:61-66.
9. Shukla R, Karla S. Pioglitazone: Indian perspective. *Indian J Endocrinol Metab* 2011; 15:294-297.
10. Tolman KG, Chandramouli J. Hepatotoxicity of the thiazolidinediones. *Clin Liver Dis* 2003; 7:369-79.
11. Saha SK, Chowdhury AK, Bachar SC, Das SC, Kuddus RH, Uddin MA. Comparative *in vitro*-*in vivo* correlation analysis with pioglitazone tablets. *Asian Pac J Trop Dis* 2013; 3:487-491.
12. Schernthaner G, Currie C, Schernthaner GH. Do we still need pioglitazone for the treatment of Type 2 Diabetes? *Diabetes Care* 2013; 36:155-161.
13. Lenzen S. The mechanisms of alloxan and streptozotocin-induced diabetes," *Diabetologia* 2008; 2:216-226.
14. Chinnam P, Mohsin M, Shafee LM. Evaluation of acute toxicity of pioglitazone in mice. *Toxicol Int* 2012; 19:250-254.
15. Ankur R, Shahjad A. Alloxan induced diabetes: mechanisms and effects. *Int J Res Pharm Biomed Sci* 2012; 3:819-823.
16. Alexander RH, Griffith JM. Clinical/Nutritional Biochemistry. Basic Biochemical Methods. 2nd ed. Wiley-Liss, New York: John Wiley & Sons; 1992.
17. McKenzie M. Clinical Laboratory Hematology. 2nd ed. Prentice Hall; 2010.p. 411- 422.
18. Wu AH, Apple FS, Valdes RJ. National academy of clinical Biochemistry Standards of Laboratory Practice: recommendations for use of cardiac markers in coronary artery diseases. *Clin Chem* 1999; 45:1104-1121.
19. Bancroft JD, Gamble M. Theory and Practice Histological Techniques, 5th ed., Churchill Livingstone. New York: Edinburgh and London: 2002.p. 173-175.
20. Chojkier M. Troglitazone and liver injury: in search of answers. *Hepatology* 2005; 41:237-246.
21. Nathan DM. Rosiglitazone and cardiotoxicity-weighing the evidence. *N Engl J Med* 2007; 357:64- 66.
22. Chase MP, Yarze JC. Pioglitazone-associated fulminant hepatic failure. *Am J Gastroenterol* 2002; 97: 502-503.
23. Farley-Hills E, Sivasankar R, Martin M. Fatal liver failure associated with pioglitazone. *BMJ* 2004; 329:429.
24. Pessayre D, Mansouri A, Haouzi D, Fromenty B. Hepatotoxicity due to mitochondrial dysfunction. *Cell Biol Toxicol* 1999; 15:367-373.

25. Elgawly H, Tawfik MK, Rashwan MF, Baruzai AS. The effect of pioglitazone on the liver of streptozotocin-induced diabetic albino wistar rats. *Eur Rev Med Pharm Sci* 2009; 13:443-451.
26. Budde K, Neumayer HH, Fritsche L, Sulowicz W, Stompor T, Eckland D. The pharmacokinetics of pioglitazone in patients with impaired renal function. *Br J Clin Pharmacol* 2003; 55:368-374.
27. Yang H, Kim WS, Kim DH, Kang JS. Histopathological Evaluation of Heart Toxicity of a Novel Selective PPAR- γ Agonists CKD-501 in db/db Mice. *Biomol Ther* 2013; 21:84-88.
28. Lincoff AM, Wolski K, Nicholls SJ, Nissen SE. Pioglitazone and risk of cardiovascular events in patients with type 2 diabetes mellitus: a meta-analysis of randomized trials. *JAMA* 2007; 298:1180-1188.
29. Jeremias A, Gibson CM. Narrative review: alternative causes for elevated cardiac troponin levels when acute coronary syndromes are excluded. *ANN Intern Med* 2005; 142:786-791.
30. O'Brien PJ. Cardiac troponin is the most effective translational safety biomarker for myocardial infarction in cardiotoxicity. *Toxicology* 2008; 245:206-218.
31. Lin KD, Lee MY, Feng CC, Chen BK, Yu ML, Shin SJ. Residual effect of reductions in red blood cell count and haematocrit and haemoglobin levels after 10-month withdrawal of pioglitazone in patients with Type 2 diabetes. *Diabet Med* 2014; 31:1341-1349.
32. Berria R, Glass L, Mahankali A, Miyazaki Y, Monroy A, De Filippis E, et al. Reduction in hematocrit and hemoglobin following pioglitazone treatment is not hemodilutional in Type II diabetes mellitus. *Clin Pharmacol Ther* 2007; 82:275-281.
33. Cheng L, Cheville JC, Neumann RM, Bostwick DG. Natural history of urothelial dysplasia of the bladder. *Am J Surg Pathol* 1999; 23:443-447.
34. Piccinni C, Motola D, Marchesini G, Poluzzi E. Assessing the association of pioglitazone use and bladder cancer through drug adverse event reporting. *Diabetes Care* 2011; 34:1369-1371.
35. Berger J, Moller DE. The mechanisms of action of PPARs. *Annu Rev Med* 2002; 53:409-435.
36. Varley CL, Southgate J. Effects of PPAR agonists on proliferation and differentiation in human urothelium. *Exp Toxicol Pathol* 2008; 60:435-441.
37. Lee MY, Hsiao PJ, Yang YH, Lin KD, Shin SJ. The Association of Pioglitazone and Urinary Tract Disease in Type 2 Diabetic Taiwanese: Bladder Cancer and Chronic Kidney Disease. *PLoS One* 2014; 9:e85479.