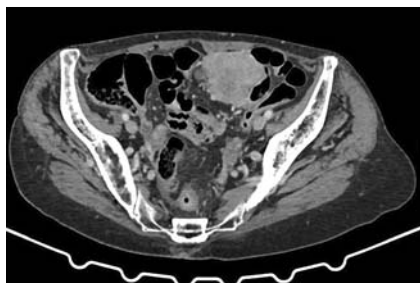
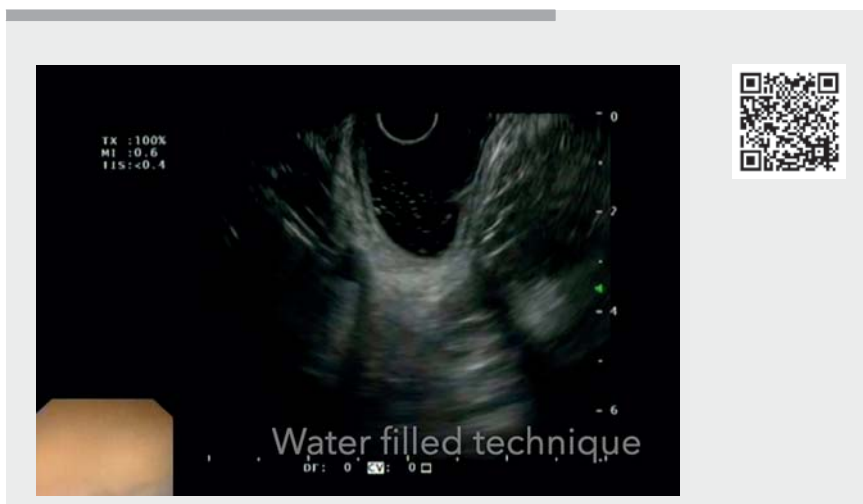


Underwater colonic endoscopic ultrasonography-guided fine-needle biopsy of a hypogastric neoplastic lesion



► **Fig. 1** Image from a computed tomography scan showing a 6-cm mass involving an area between the ileal loops.

An 86-year-old woman was admitted to our endoscopy unit, having been referred by the oncologists. She had undergone a computed tomography scan because of weight loss and abdominal pain, and had been found to have a 6-cm hypogastric mass with contrast enhancement (► **Fig. 1**). Her case was discussed by our multidisciplinary team and endoscopic ultrasonography (EUS) plus fine-needle biopsy (FNB) was proposed. Before performing EUS, we decided to perform an underwater colonoscopy, using a standard colonoscope and filling the bowel with tap water, to prepare the bowel for the water-filled technique. After colonic irrigation had been performed, an echoendoscope was advanced using the water-filled technique [1] and EUS guidance until the splenic flexure was reached, and the examination was performed by withdrawing the scope with rotational movement until the mass was visualized from the mid-sigmoid colon (► **Video 1**). After visualization of the mass, an FNB was performed with two passes of a 22G needle (Acquire; Boston Scientific; Natick, Massachusetts, USA) and macroscopic on-site evaluation (MOSE) [2]. Histology revealed a gastrointestinal stromal tumor (GIST) and the patient was referred to the surgeons for further management.



► **Video 1** Endoscopic ultrasonography-guided fine-needle biopsy of a mass is performed from the mid-sigmoid colon after the scope had been advanced to the splenic flexure using the water-filled technique and slowly withdrawn until the mass was visualized.

EUS-FNB in the lower GI tract is generally performed only through the rectum, because of the difficulties encountered in advancing a linear echoendoscope as far as the right-sided colon. The water-filled technique is an easy technique that allows the echoendoscope to be advanced under EUS guidance only, without using the endoscopic vision. With this technique, operative EUS could also be performed in difficult sites, such as the transverse or right-sided colon, or in patients who had undergone upper gastrointestinal surgical reconstruction [3].

Endoscopy_UCTN_Code_TTT_1AS_2AG

Competing interests

The authors declare that they have no conflict of interest.

The authors

Benedetto Mangiavillano^{1,2}, **Laura Lamonaca**¹, **Francesco Auriemma**¹, **Daniilo Paduano**¹, **Federica Spatola**¹, **Alessandro Repici**^{2,3}

- 1 Gastrointestinal Endoscopy Unit, Humanitas Mater Domini, Castellanza (VA), Italy
- 2 Department of Biomedical Sciences, Humanitas University, Rozzano, Milan, Italy
- 3 Endoscopy Unit, Humanitas Clinical and Research Center IRCCS, Rozzano, Milan, Italy

Corresponding author

Benedetto Mangiavillano, MD
Gastrointestinal Endoscopy Unit, Humanitas – Mater Domini, Via Gerenzano n.2, 21053, Castellanza (VA), Italy
bennymangiavillano@gmail.com

References

- [1] Mangiavillano B, Carrara S, Eusebi LH et al. Water-filled technique for therapeutic pancreato-biliary EUS in patients with surgically altered anatomy. *Endosc Int Open* 2021; 9: E487–E489
- [2] Mangiavillano B, Frazzoni L, Togliani T et al. Macroscopic on-site evaluation (MOSE) of specimens from solid lesions acquired during EUS-FNB: multicenter study and comparison between needle gauges. *Endosc Int Open* 2021; 9: E901–E906
- [3] Mangiavillano B, Auriemma F, Mezzananza M et al. Fine needle biopsy plus EUS-guided cholecystojejunostomy by LAMS with a water-filled technique in a patient with Roux-en-Y reconstruction. *Am J Gastroenterol* 2020; 115: 1572

Bibliography

Endoscopy 2022; 54: E822–E823

DOI 10.1055/a-1816-7521

ISSN 0013-726X

published online 13.5.2022

© 2022. The Author(s).

This is an open access article published by Thieme under the terms of the Creative Commons Attribution-NonDerivative-NonCommercial License, permitting copying and reproduction so long as the original work is given appropriate credit. Contents may not be used for commercial purposes, or adapted, remixed, transformed or built upon. (<https://creativecommons.org/licenses/by-nc-nd/4.0/>)

Georg Thieme Verlag KG, Rüdigerstraße 14,
70469 Stuttgart, Germany



ENDOSCOPY E-VIDEOS

<https://eref.thieme.de/e-videos>



Endoscopy E-Videos is an open access online section, reporting on interesting cases and new techniques in gastroenterological endoscopy. All papers include a high quality video and all contributions are freely accessible online. Processing charges apply (currently EUR 375), discounts and waivers acc. to HINARI are available.

This section has its own submission website at

<https://mc.manuscriptcentral.com/e-videos>