

Jejunal perforation after a trivial trauma: A case report

SAGE Open Medical Case Reports
Volume 10: 1–3
© The Author(s) 2022
Article reuse guidelines:
sagepub.com/journals-permissions
DOI: 10.1177/2050313X221110032
journals.sagepub.com/home/sco



Thukten Chopel¹, Sangay Tshering² and Namkha Dorji² 

Abstract

Jejunal perforation after a trivial trauma is a rare event. We present a case of a 23-year-old man, a truck driver who suffered jejunal perforation following a jump from the Indian jumbo truck, approximately 2 m height from the ground. This case report highlights the importance of careful evaluation of a symptomatic patient after a trivial injury, and the challenges faced by surgeons in the low recourse-setting.

Keywords

Small bowel injury, jejunal perforation, trivial injury

Date received: 7 March 2022; accepted: 10 June 2022

Introduction

Small bowel injury resulting from a blunt abdominal trauma is rare with a reported incidence of less than 1%.¹ The diagnosis is delayed when small bowel injury occurs as an isolated incidence leading to a greater morbidity and mortality.² Although the mechanism of injury can give a clinical clue, especially in penetrating and blunt trauma to the abdomen, there were instances where the mechanism of injury was trivial and unsuspecting. Cases of small bowel perforation were reported following a trivial fall on the ground or low impact blow to the abdomen.^{3–5} We report a case of jejunal perforation after jumping from about 2 m height in a 23-year-old, male truck driver, with the aim of creating an awareness among clinicians about the possibility of such injuries, and the necessity for complete evaluation including a diagnostic laparotomy in low resource-setting.

Case description

A 23-year-old, male truck driver presented to the emergency room (ER) with 1 h history of diffuse abdominal pain, which developed suddenly after jumping from the driver's door of his Indian jumbo truck, which is approximately about 2 m high from the ground. He landed on the ground on his feet. He denied any blunt trauma to his abdomen. He did not report any gastrointestinal symptoms such as nausea or vomiting. He doesn't have medical comorbidities such as peptic ulcer disease.

On examination, he was conscious, afebrile, and not pale. Pulse rate was 110 beats per minute (bpm) and blood

pressure was 110/60 mmHg. Abdominal examination revealed distended abdomen with diffuse guarding and rigidity. The bowel sounds were sluggish. Digital rectal examination was unremarkable. There were no visible external injuries such as bruises in the skin, and fractured bones. The neurological examination of both upper and lower limbs was unremarkable.

Complete blood count (CBC) was within the normal range—leukocytes of 2700/mm³, neutrophil—79%, hemoglobin—11 gm%, and platelet count of 367,000/mm³. Serum amylase was within the normal range of 40 U/L. Focused assessment with sonography in trauma (FAST) revealed minimal free fluid in the pelvis. A postero-anterior (PA) chest X ray revealed air under the right hemi-diaphragm (Figure 1).

Possibility of bowel perforation, and the need for an emergency exploratory laparotomy to look for the cause of pneumoperitoneum and appropriate treatment was explained, and a written informed consent obtained. Exploratory laparotomy with midline incision under general anesthesia was performed. On exploring the abdominal cavity, there was minimal hemoperitoneum with bile-stained fluid. There was a full thickness perforation involving two-third of the

¹Department of Surgery, Jigme Dorji Wangchuck National Referral Hospital, Thimphu, Bhutan

²Department of Obstetrics and Gynaecology, Jigme Dorji Wangchuck National Referral Hospital, Thimphu, Bhutan

Corresponding Author:

Namkha Dorji, Department of Obstetrics and Gynecology, Jigme Dorji Wangchuck National Referral Hospital, Thimphu, Bhutan.
Email: namji2002@gmail.com



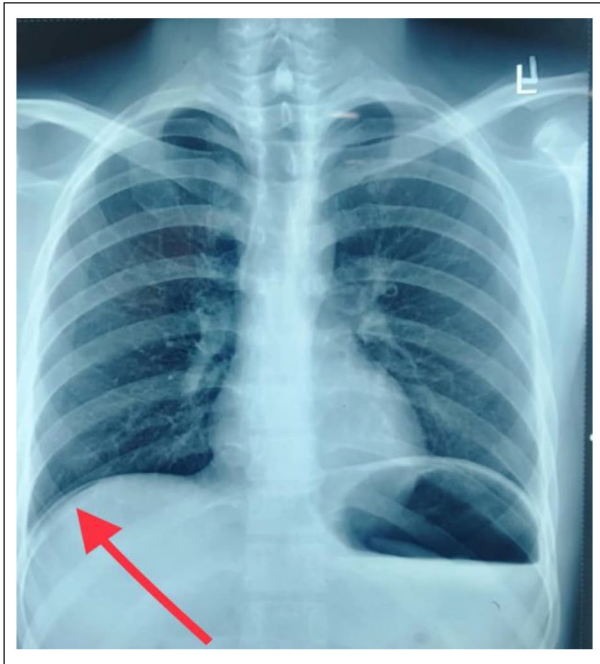

Figure 1. Erect chest X ray showing air under right hemidiaphragm (red arrow) in a 23-year-old man with the history of jumping from the door of Indian jumbo truck.

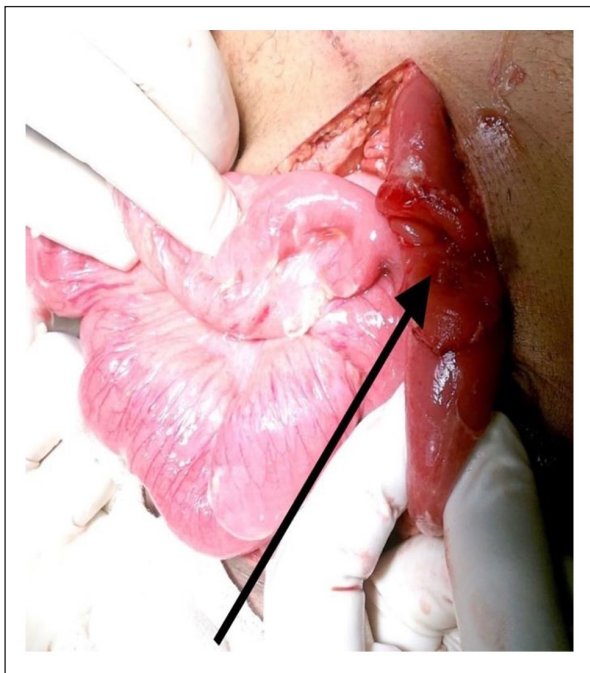


Figure 2. Intraoperative image showing the perforation of jejunum (black arrow) in a 23-year-old man with the history of jumping from the door of Indian jumbo truck.

circumference of the proximal jejunum near the ligament of Treitz (Figure 2). There were no other bowel injuries or other pathologies suggestive of malignancies or intestinal tuberculosis noted during the exploration. Peritoneal lavage

with copious amount of normal saline, was followed by primary repair of the injury. The perforated segment of the jejunum was repaired in two layers using 3-0 vicryl. The first layer was sutured continuously, and the second layer was sutured with Lembert suture. An 18 French drain tube was placed in close proximity to the repaired jejunal segment and the abdomen was closed in the standard steps.

He was initiated on oral liquids on the third postoperative day. He tolerated oral intake, and gradually converted to normal diets. The drainage was removed on the second postoperative day. He made an uneventful recovery in the postoperative period, and was discharged home on the seventh postoperative day. On follow-up at the 30th postoperative day, his wound was healed, and abdomen was soft with normal bowel habits.

Discussion

The clinical dictum which teaches that only the high impact trauma to the abdomen causes serious injury is not always true.⁶ Despite the history of abdominal pain following a jump from his jumbo truck, the history did not alert the surgeon to suspect the possibility of intestinal perforation. However, signs of diffuse peritonitis in the abdominal examination and tachycardia, with chest X ray (Figure 1) showing air under right hemidiaphragm was suggestive of hollow viscus perforation. The abdominal organs, unlike others, have no protective bony structure. Hollow viscus organs like jejunum, ileum, and transverse colon are suspended via their mesentery in the peritoneum. Thus, these organs are more prone to biomechanics of injury such as compression-deceleration. Similar to seat-belt injuries, our case probably developed jejunal perforation following compression-deceleration in relation to the fixed retroperitoneal duodenum.⁷ Although case reports reminded us of finding intestinal pathologies in such clinical setting, our case did not show any features of pathologies like tuberculosis, inflammatory bowel disease, or malignancy.⁵

Delayed diagnosis of bowel injury is known to cause severe morbidity and mortality. Hemorrhagic shock, ischemia, necrosis coupled with sepsis, and multiorgan failure are the major contributors of morbidity and mortality in bowel injuries.⁸ Our patient recovered without any postoperative complications. The younger age, early presentation to the health facility, stable vitals on admission, low injury severity score and immediate surgical intervention were some of the favorable prognostic factors in our case.⁸⁻¹⁰ In our case, there were no indications for bowel resection and anastomosis such as malignancy, ischemic necrosis, diverticular disease, inflammatory bowel disease or complete transection of the bowel.¹¹

Although preoperative computed tomography (CT) scan of the whole abdomen with oral water-soluble contrast could have delineated the site of bowel perforation, it was not done in our case. In our setting, waiting for CT scan could have delayed the management, thereby increasing the morbidity

and mortality of the patient.¹² Moreover, the decision to perform exploratory laparotomy would not change based on the CT scan result in our case.

Conclusion

Patients presenting with acute abdomen following trivial injury, such as jumping from a short height, should be carefully evaluated keeping in mind the possibility of bowel perforation. Exploratory laparotomy with primary suturing of perforated bowel can be a life-saving procedure.

Acknowledgements

The authors thank the patient for giving them consent to publish his de-identified clinical information and photos.

Declaration of conflicting interests

The author(s) declared no potential conflicts of interest with respect to the research, authorship, and/or publication of this article.

Ethical approval

Our institution does not require ethical approval for reporting de-identified individual case reports.

Funding

The author(s) received no financial support for the research, authorship, and/or publication of this article.

Informed consent

Written informed consent was obtained from the patient for his anonymized information to be published in this article. This informed consent is available with the principal author.

ORCID iD

Namkha Dorji  <https://orcid.org/0000-0003-3594-3159>

References

1. Fakhry SM, Watts DD, Luchette FA, et al. Current diagnostic approaches lack sensitivity in the diagnosis of perforated blunt small bowel injury: analysis from 275,557 trauma admissions from the EAST Multi-Institutional HVI Trial. *J Trauma Acute Care Surg* 2003; 54(2): 295–306, https://journals.lww.com/jtrauma/Fulltext/2003/02000/Current_Diagnostic_Approaches_Lack_Sensitivity_in.13.aspx
2. Brownstein MR, Bunting T, Meyer AA, et al. Diagnosis and management of blunt small bowel injury: a survey of the membership of the American Association for the Surgery of Trauma. *J Trauma* 2000; 48(3): 402–407.
3. Okello M, Batte C and Buwembo W. Jejunal transection following trivial trauma: case report and review of literature. *Int J Surg Case Rep* 2016; 27: 41–43.
4. Sandiford NA, Sutcliffe RP and Khawaja HT. Jejunal transection after blunt abdominal trauma: a report of two cases. *Emerg Med J* 2006; 23(10): e55.
5. Onwubiko C, Pennington EC, Mooney DP, et al. Intestinal perforation due to minor blunt abdominal trauma: a harbinger of underlying disease pathology. *J Pediatr Surg Case Rep* 2015; 3(1): 35–37.
6. Matsui Y, Oikawa S, Sorimachi K, et al. Association of impact velocity with risks of serious injuries and fatalities to pedestrians in commercial truck-pedestrian accidents. *Stapp Car Crash J* 2016; 60: 165–182.
7. Santschi M, Echavá© V, Laflamme S, et al. Seat-belt injuries in children involved in motor vehicle crashes. *Can J Surg* 2005; 48(5): 373–376.
8. Jha NK, Yadav SK, Sharma R, et al. Characteristics of hollow viscus injury following blunt abdominal trauma; a single centre experience from Eastern India. *Bull Emerg trauma* 2014; 2(4): 156–160.
9. Mingoli A, La Torre M, Brachini G, et al. Hollow viscus injuries: predictors of outcome and role of diagnostic delay. *Ther Clin Risk Manag* 2017; 13: 1069–1076.
10. Ntundu SH, Herman AM, Kishe A, et al. Patterns and outcomes of patients with abdominal trauma on operative management from northern Tanzania: a prospective single centre observational study. *BMC Surg* 2019; 19(1): 1–10.
11. Clatterbuck B and Moore L. Small bowel resection. Treasure Island, FL: StatPearls, 2022, <https://www.ncbi.nlm.nih.gov/books/NBK507896/?report=classic>
12. Pouli S, Kozana A, Papakitsou I, et al. Gastrointestinal perforation: clinical and MDCT clues for identification of aetiology. *Insights Imaging* 2020; 11(1): 31.