

# Wall Shear Stress and T1 Contrast Ratio Are Associated With Embolic Signals During Carotid Exposure in Endarterectomy

Sotaro Oshida, MD, PhD; Futoshi Mori, PhD; Makoto Sasaki, MD, PhD;  
Yuiko Sato, MD, PhD; Masakazu Kobayashi, MD, PhD; Kenji Yoshida, MD, PhD;  
Shunrou Fujiwara, PhD; Kuniaki Ogasawara, MD, PhD

**Background and Purpose**—The frictional force because of blood flow may dislodge masses present on the surface of a plaque. Such frictional force is calculated as wall shear stress (WSS) using computational fluid dynamics. The aims of the present study were to determine whether, in addition to carotid plaque intensity on T1-weighted magnetic resonance (MR) imaging, WSS calculated using computational fluid dynamics analysis for carotid arteries is associated with development of an embolism during exposure of carotid arteries during carotid endarterectomy.

**Methods**—One hundred patients with internal carotid artery stenosis ( $\geq 70\%$ ) underwent carotid plaque imaging with MR, and 54 patients with a vulnerable plaque (intraplaque hemorrhage or lipid/necrotic core) displayed as a high-intensity lesion underwent additional cervical 3-dimensional MR angiography. The maximum value of WSS within the most severe stenotic segment of the internal carotid artery was calculated using MR angiography. Transcranial Doppler monitoring of microembolic signals (MES) in the ipsilateral middle cerebral artery was performed during carotid endarterectomy.

**Results**—Although none of the 46 patients with a nonvulnerable carotid plaque had MES during exposure of carotid arteries, 24 of the 54 patients with a vulnerable carotid plaque (44%) had MES. Logistic regression analysis showed that higher plaque intensity ( $P=0.0107$ ) and higher WSS ( $P=0.0029$ ) were significantly associated with the development of MES. When both cutoff points of plaque intensity and WSS in the receiver operating characteristic curves for predicting development of MES were combined, specificity (from 63% to 93%) and positive predictive value (from 66% to 90%) became greater than those for plaque intensity alone.

**Conclusions**—In addition to carotid plaque intensity on T1-weighted MR imaging, WSS calculated using computational fluid dynamics analysis for carotid arteries is associated with development of an embolism during exposure of carotid arteries during carotid endarterectomy. (*Stroke*. 2018;49:2061-2066. DOI: 10.1161/STROKEAHA.118.022322.)

**Key Words:** angiography ■ carotid arteries ■ embolism ■ endarterectomy ■ magnetic resonance imaging

Endarterectomy for carotid artery stenosis because of atherosclerosis is an effective method to prevent stroke in appropriately selected patients.<sup>1-3</sup> However, intraoperative procedure-related ischemic events sometimes develop, and  $>70\%$  of these events are caused by cerebral emboli from the surgical site.<sup>4</sup> Intraoperative transcranial Doppler (TCD) monitoring of the middle cerebral artery can detect microembolic signals (MES) that indicate cerebral emboli.<sup>4</sup> MES during exposure of the carotid arteries in carotid endarterectomy (CEA) is most strongly associated with development of new postoperative ischemic lesions or neurological deficits.<sup>5-10</sup> Although plaque as a source of emboli remains exposed to blood flow, manipulation of the carotid arteries for their

exposure can dislodge emboli from the plaque into the intracranial arteries.<sup>11</sup>

Several investigators have demonstrated that vulnerable carotid plaques consisting primarily of an intraplaque hemorrhage or lipid/necrotic core are related to development of MES during exposure of the carotid arteries in CEA.<sup>12,13</sup> Magnetic resonance (MR) plaque imaging can assess plaque characteristics in patients with cervical carotid stenosis: a vulnerable plaque is displayed as a relatively high-intensity lesion on T1-weighted MR imaging.<sup>12,14</sup> A recent study also has shown that carotid plaques that show such high intensity are significantly associated with development of MES during exposure of the carotid arteries in CEA.<sup>15</sup> However, although

Received February 19, 2018; final revision received May 25, 2018; accepted June 8, 2018.

From the Department of Neurosurgery (S.O., Y.S., M.K., K.Y., S.F.) and Division of Ultrahigh Field MRI, Institute for Biomedical Sciences (F.M., M.S.), Iwate Medical University, Morioka, Japan.

The online-only Data Supplement is available with this article at <https://www.ahajournals.org/doi/suppl/10.1161/STROKEAHA.118.022322>.

Correspondence to Kuniaki Ogasawara, MD, PhD, Department of Neurosurgery, Iwate Medical University, 19-1 Uchimarui, Morioka, 020-8505, Japan. Email kuogasa@iwate-med.ac.jp

© 2018 The Authors. *Stroke* is published on behalf of the American Heart Association, Inc., by Wolters Kluwer Health, Inc. This is an open access article under the terms of the [Creative Commons Attribution Non-Commercial-NoDerivs](https://creativecommons.org/licenses/by-nc-nd/4.0/) License, which permits use, distribution, and reproduction in any medium, provided that the original work is properly cited, the use is noncommercial, and no modifications or adaptations are made.

*Stroke* is available at <https://www.ahajournals.org/journal/str>

DOI: 10.1161/STROKEAHA.118.022322

the sensitivity and negative predictive value for high-intensity carotid plaques on T1-weighted MR imaging for predicting the development of MES during carotid exposure are high, the specificity and positive predictive value are <50%.<sup>15</sup> Thus, additional factors may be associated with the development of MES during exposure of the carotid arteries in CEA. We hypothesize that when a solid mass, such as a thrombus or lipid/necrotic core is present on the surface of the plaque and is exposed to blood flow, the strong frictional force because of the blood flow in addition to manipulation of the carotid arteries by the surgeon may dislodge this mass from the plaque and allow it travel to the intracranial arteries.

Blood flow, by virtue of its viscosity, imposes on the luminal vessel wall a frictional force per unit area known as hemodynamic wall shear stress (WSS).<sup>16,17</sup> Flow impingement at arterial bifurcations, such as the cervical carotid arteries, causes high WSS.<sup>18</sup> Further, a cervical carotid bifurcation with severe stenosis may exhibit higher WSS. The geometry of the lumen of the cervical carotid bifurcation can be reconstructed 3-dimensionally using MR angiography, which enables calculation of WSS using computational fluid dynamics (CFD).<sup>19–22</sup>

The aims of the present study were to determine whether, in addition to carotid plaque intensity on T1-weighted MR imaging, WSS that is preoperatively calculated using CFD analysis for the carotid arteries is associated with development of MES on TCD during exposure of the carotid arteries during CEA.

## Methods

We will not make our data, analytical methods, and study materials available to other researchers because the privacy of the study patients is protected by the institutional review board regulation.

All procedures performed in studies involving human participants were conducted in accordance with the ethical standards of the institutional research committee, and written informed consent was obtained from all patients or their next of kin before participation.

## Subjects

The present study was a prospective observational study. Patients with the following conditions were considered candidates for CEA: ipsilateral internal carotid artery (ICA) stenosis  $\geq 70\%$  as per the North American Symptomatic Carotid Endarterectomy Trial criteria on angiography with MR, computed tomography, or arterial catheterization<sup>3</sup>; peak systolic velocity<sup>3</sup> 200 cm/s on cervical color duplex ultrasound in the affected ICA<sup>23</sup>; and useful residual function (modified Rankin Scale score, 0–2). After obtaining written informed consent, each patient who was considered a candidate for CEA underwent carotid plaque MR imaging (see the MR plaque imaging section in the [online-only Data Supplement](#)). Only patients who were determined to have a vulnerable carotid plaque on MR imaging then underwent cervical angiography with gadolinium-enhanced MR (see the CFD analyses section in the [online-only Data Supplement](#)). Each patient who underwent CEA was finally included in the present study. Patients without reliable TCD monitoring throughout the entire operation because of failure to obtain an adequate bone window were excluded from analysis.

## Intraoperative TCD Monitoring

TCD was performed by using a PIONEER TC2020 system (EME, Uberlingen, Germany; software version 2.50, 2-MHz probe; diameter, 1.5 cm; insonation depth, 40–66 mm; scale, –100 and +150 cm/s; sample volume, 2 mm; 64-point fast Fourier transform; fast Fourier transform length, 2 mm, fast Fourier transform overlap, 60%; high-pass

filter, 100 Hz; detection threshold, 9 dB; minimum increase time, 10 ms) for insonation of the middle cerebral artery ipsilateral to the carotid artery undergoing CEA.<sup>15</sup> TCD data were stored on a hard disk using a coding system and were later analyzed manually by a clinical neurophysiologist who was blinded to patient information. MES were identified during exposure of the carotid arteries (from skin incision until ICA clamping) according to the recommended guidelines.<sup>24</sup>

## Preoperative, Intraoperative, and Postoperative Management

All patients received antiplatelet drugs until the morning of the day when CEA was performed. Patients were placed under general anesthesia, and a microscope was inserted through a skin incision by a senior neurosurgeon who was blinded to the MR plaque and CFD data. The surgery was performed regardless of the results of intraoperative TCD. The preoperative systolic blood pressure was maintained while the carotid arteries were exposed. If required, patients were given nicardipine or nitroglycerin for vasodilation or theoadrenalin for vasoconstriction. No intraluminal shunts or patch grafts were used in any patients. Before clamping of the ICA, a 5000-IU bolus of heparin was administered.

A neurologist who was blinded to information about the patient performed neurological examination of all patients immediately before they were placed under general anesthesia and after waking from anesthesia. New or absent neurological deficits were noted.

## Statistical Analysis

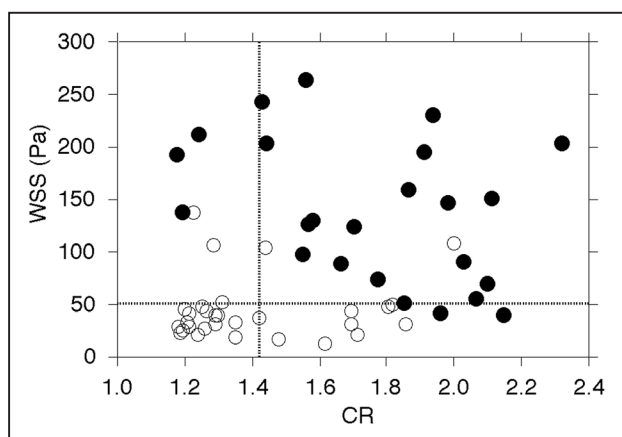
Data are expressed as the mean $\pm$ SD. The relationship between variables in 2 groups was evaluated with univariate analysis by using the Mann-Whitney *U* or  $\chi^2$  test. Logistic regression analysis of factors related to the development of MES during exposure of the carotid arteries was performed by using the sequential backward elimination approach. When the *P* value of all remaining variables became <0.2, the exclusion of variables was stopped. Receiver operating characteristic curves was used to assess the accuracy of the contrast ratio (CR) and WSS in predicting the development of MES during exposure of the carotid arteries. Pair-wise comparisons of the area under the receiver operating characteristic curve for the CR or WSS were performed as proposed by Pepe and Longton.<sup>25</sup> For all statistical analyses, significance was set at *P*<0.05. Exact 95% CIs of sensitivity, specificity, and positive and negative predictive values were computed with binomial distributions. Differences in the sensitivity, specificity, and positive and negative predictive values among the CR, WSS, and combination of these 2 were analyzed using 95% CIs: when the 95% CIs of any 2 items did not overlap, the difference in these 2 was determined to be significant.

## Results

Study subjects included 96 males (96%) and 4 females (4%) with a mean age of 70 $\pm$ 6 years (range, 54–82 years). Co-morbidities included diabetes mellitus (n=45; 45%), dyslipidemia (n=66; 66%), and hypertension (n=86; 86%). Symptoms related to the ipsilateral carotid territory were reported by 79 patients (79%) within 6 months before surgery. The time from the last ischemic event to surgery ranged from 10 to 179 days (58 $\pm$ 50 days). In other 21 patients (21%), the ICA stenosis was asymptomatic. Twenty-two (22%), 46 (46%), or 32 (32%) patients preoperatively received 100 mg/d aspirin alone, 75 mg/d clopidogrel alone, or dual antiplatelet therapy with these two, respectively. ICA stenosis ranged from 70% to 99% (mean 87 $\pm$ 10%). The time from MR plaque imaging to surgery ranged from 4 to 6 days (4.9 $\pm$ 0.8 days). In the 54 patients with a vulnerable carotid plaque, the time from gadolinium-enhanced 3-dimensional MR angiography to surgery ranged from 1 to 3 days (2.0 $\pm$ 0.8 days).

During exposure of the carotid sheath, ICA manipulation resulted in MES in 24 of the 100 patients (24%). Compared with before anesthesia, new neurological deficits, all of which involved hemiparesis contralateral to the CEA, were noted in 4 of 24 patients (17%) after waking from general anesthesia. In 3 patients, all neurological problems disappeared completely within 12 hours. In 1 patient, the deficits persisted 24 hours after surgery. Seventy-six patients did not develop MES during exposure of the carotid arteries, and none of them developed new neurological problems after surgery.

Although none of the 46 patients with a nonvulnerable carotid plaque had MES during exposure of carotid arteries, 24 of the 54 patients with a vulnerable carotid plaque (44%) had MES. The relationship among CR, WSS, and development of MES during exposure of the carotid arteries in patients with a vulnerable carotid plaque is shown in Figure 1, and results of univariate analysis of factors related to the development of MES during exposure of the carotid arteries are summarized in Table 1. The incidences of symptomatic lesions, CR, and WSS were significantly higher in patients with MES than in those without. No other variables showed a significant association with the development of MES during exposure of the carotid arteries. For the 43 patients with ischemic symptoms within 6 months before surgery, the time from the last ischemic event to surgery did not differ between patients with ( $61\pm 59$  days) and without ( $50\pm 34$  days) MES during exposure of the carotid arteries ( $P=0.7148$ ). For the 37 patients who received single antiplatelet therapy, the incidence of treatment with clopidogrel alone did not differ between patients with (12/16: 75%) and without (14/21: 67%) MES during exposure of the carotid arteries ( $P=0.7228$ ). Logistic regression analysis with a sequential backward elimination approach revealed that a higher CR (95% CI, 8.31–881.82;  $P=0.0107$ ) and higher WSS (95% CI, 1.02–1.11;  $P=0.0029$ ) were significantly associated with the development of MES during exposure of the carotid arteries in patients with a vulnerable carotid plaque. Symptomatic lesions (95% CI, 0.32–804.25;  $P=0.1636$ ) were not associated with this development.



**Figure 1.** Relationship among the contrast ratio (CR), wall shear stress (WSS), and development of microembolic signals (MES) during exposure of the carotid arteries in patients with a vulnerable carotid plaque. Closed and open circles denote patients with and without MES, respectively. Vertical and horizontal lines denote the cutoff points lying closest to the upper left corner of the receiver operating characteristic curves for the CR and WSS in predicting the development of MES, respectively.

**Table 1.** Univariate Analysis of Factors Related to the Development of MES During Exposure of the Carotid Arteries in Patients With a Vulnerable Carotid Plaque

Variables	Development of MES		P Value
	Yes (n=24)	No (n=30)	
Age, y (mean±SD)	70.6±6.1	69.4±6.8	0.6948
Male sex	24 (100%)	29 (97%)	>0.9999
Hypertension	22 (92%)	24 (80%)	0.2771
Diabetes mellitus	10 (42%)	14 (47%)	0.7869
Dyslipidemia	16 (67%)	20 (67%)	>0.9999
Symptomatic lesion	23 (96%)	20 (67%)	0.0147
Dual antiplatelet therapy	8 (33%)	9 (30%)	>0.9999
Degree of ICA stenosis, % (mean±SD)	88.9±7.0	85.0±11.5	0.3182
CR	1.76±0.32	1.41±0.24	0.0003
WSS, Pa	137.3±69.6	45.3±30.9	<0.0001

CR indicates contrast ratio; ICA, internal carotid artery; MES, microembolic signals; and WSS, wall shear stress.

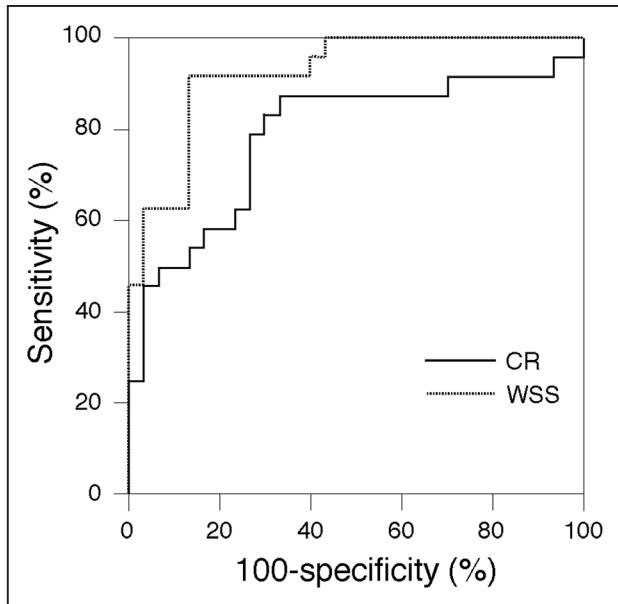
The receiver operating characteristic curves for the CR and WSS for predicting development of MES during exposure of the carotid arteries in patients with a vulnerable carotid plaque are shown in Figure 2. The area under the receiver operating characteristic curves for the CR and WSS were 0.788 (95% CI, 0.655–0.887) and 0.921 (95% CI, 0.814–0.977), respectively. No significant difference between these 2 area under the receiver operating characteristic curves was observed (difference between areas, 0.133;  $P=0.0969$ ). Sensitivity, specificity, and positive and negative predictive values for the CR and WSS at the cutoff point lying closest to the upper left corner of the receiver operating characteristic curve in patients with a vulnerable carotid plaque are summarized in Table 2. When both cutoff points of the CR and WSS were combined, the specificity and positive predictive value became significantly greater than those for CR alone (Table 2).

T1-weighted MR and WSS images in a patient with MES during exposure of the carotid arteries and a patient without MES are shown in Figure 3.

## Discussion

The present study demonstrated that in addition to carotid plaque intensity on T1-weighted MR imaging, WSS that was preoperatively calculated using CFD analysis for the carotid arteries is associated with development of MES on TCD during exposure of the carotid arteries during CEA.

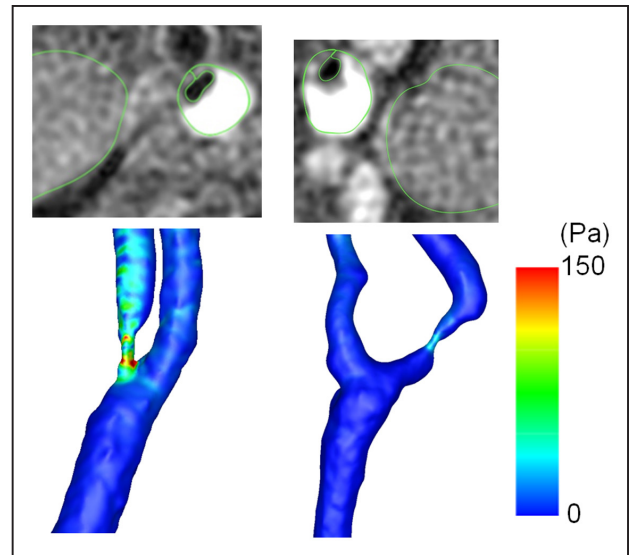
T1-weighted MR imaging with nongated spin echo used in the present study provides accurate evaluation of the composition of excised carotid plaques compared with histopathologic findings in patients undergoing CEA<sup>26</sup>: carotid plaques showing a CR >1.17 mainly consist of an intraplaque hemorrhage or lipid/necrotic core, and those showing a CR ≤1.17 mainly consist of fibrous tissue. Furthermore, no patients with a carotid plaque showing a CR <1.16 on the same MR sequence had MES during exposure of the carotid arteries in CEA.<sup>15</sup> Thus, carotid plaques showing a CR >1.17 or ≤1.17 were defined as vulnerable or nonvulnerable, respectively. As a result, although none of the patients with a nonvulnerable



**Figure 2.** Receiver operating characteristic curves for the contrast ratio (CR) and wall shear stress (WSS) in predicting the development of microembolic signals during exposure of the carotid arteries in patients with a vulnerable carotid plaque.

carotid plaque had MES during exposure of the carotid arteries, 44% of patients with a vulnerable carotid plaque had MES. These data corresponded to a previous finding<sup>15</sup> and verified that a nonvulnerable carotid plaque itself is a predictor of not developing MES during exposure of carotid arteries and that CFD analyses are unnecessary for such carotid plaques. Furthermore, even in patients with a vulnerable carotid plaque, a higher CR was an independent predictor of the development of MES during exposure of the carotid arteries, suggesting that a higher occupation rate of hemorrhage in carotid plaques is more likely to lead to MES. Intraplaque hemorrhages depicted on MR plaque imaging are related to a histologically disrupted plaque surface (plaque ulceration or a fissured fibrous cap) in patients with severe carotid artery stenosis (>70%).<sup>27</sup> Surgical manipulation of carotid arteries with such plaques may lead to an embolism from an intraplaque hemorrhage.

In the present study, higher WSS was another independent predictor of the development of MES during exposure of the carotid arteries, and the predictive accuracy for WSS was equal to that for plaque intensity in vulnerable carotid plaques. Furthermore, when these plaques were classified as mainly consisting of a lipid/necrotic core or intraplaque hemorrhage, the predictive accuracy for WSS was significantly greater than that for plaque intensity in the subgroup of patients with each plaque characteristic. These findings support our hypothesis that a strong frictional force because of blood flow may dislodge a solid mass from the vulnerable carotid plaque and allow transport to the intracranial arteries. In addition, although low WSS induces plaque initiation and progression in the cardiovascular system,<sup>28–31</sup> high WSS in the generated plaque with severe stenosis influences formation of plaque ulceration in the carotid artery.<sup>32</sup> Plaque ulceration is strongly associated with development of MES during exposure of the carotid arteries.<sup>33</sup>



**Figure 3.** T1-weighted magnetic resonance plaque images at the location in which the stenosis is most severe in the affected internal carotid artery (ICA; upper) and wall shear stress (WSS) images in the affected carotid artery (lower) in a 74-year-old man with microembolic signals (MES) during exposure of the carotid arteries (left) and a 71-year-old man without MES (right). Although the signal intensity of the plaque is approximately equal between these 2 patients, WSS in the stenotic portion of the ICA is considerably higher in the former patient than in the latter patient.

These findings may also explain our observation of a significant association between WSS and development of MES.

The present study also showed that a combination of plaque intensity and WSS increases the specificity and positive predictive value for predicting development of MES during exposure of the carotid arteries compared with plaque intensity alone and that a carotid plaque with a higher plaque intensity and higher WSS has the highest risk of development of MES during exposure of the carotid arteries. As practical relevance, for patients with such carotid plaques, the common and external carotid arteries should be clamped before manipulation of the carotid bulb and the ICA during carotid artery exposure in CEA.<sup>34</sup> This early clamping of the carotid arteries results in reversal of blood flow in the ipsilateral ICA and prevention of a cerebral embolism from the surgical site, although the procedure prolongs duration of carotid clamping and may lead to cerebral hemispheric ischemia.<sup>34</sup>

The present study possesses serious limitations that require discussion. First, the data processing time for each patient in the present CFD analysis was  $\approx 24$  hours, which makes clinical use of CFD analysis difficult when CEA is urgently needed. Future progress in central and graphics processing units may enable rapid CFD analysis. Second, in 30% of patients undergoing cervical angiography with gadolinium-enhanced MR, flow calculation of CFD was not accomplished because of the absence of a flow void at the mostly stenosed portion. Several investigators showed the same conditions when ICA stenosis is >90% or with near-ICA occlusion.<sup>21,35</sup> This may have affected our results because of a significant bias and may also exclude routine use of CFD analysis. Third, although the non-gated spin-echo MR plaque imaging used in the present study reportedly provides an accurate evaluation of the composition (ie, fibrous tissue, lipid/necrosis, or hemorrhage) of excised

**Table 2. Sensitivity, Specificity, and Positive and Negative Predictive Values for CR and WSS for the Development of MES During Exposure of the Carotid Arteries in Patients With a Vulnerable Carotid Plaque**

	A	B	C	Comparison of 95% CIs		
	CR	WSS	CR and WSS	A vs B	B vs C	C vs A
Sensitivity; 95% CI	88%; 74%–100%	92%; 81%–100%	79%; 63%–95%	NS	NS	NS
Specificity; 95% CI	63%; 41%–75%	87%; 75%–99%	93%; 84%–100%	NS	NS	Significant
Positive predictive value; 95% CI	66%; 45%–77%	85%; 71%–98%	90%; 78%–100%	NS	NS	Significant
Negative predictive value; 95% CI	86%; 72%–100%	93%; 83%–100%	85%; 73%–97%	NS	NS	NS
Cutoff point	1.42	52.0	1.42 and 52.0			

MES indicates microembolic signals; NS, not significant; and WSS, wall shear stress.

carotid plaques compared with histopathologic findings in patients undergoing CEA,<sup>22</sup> this finding was obtained using a 1.5-T MR scanner. Another study used a 3-T MR scanner and demonstrated that magnetization-prepared rapid acquisition of gradient echo, compared with spin echo, demonstrated higher diagnostic capability for the detection and quantification of intraplaque hemorrhage in the carotid artery.<sup>36</sup> This difference in MR scanners may cause a discrepancy in the results between the 2 studies. Fourth, the location in which the stenosis was most severe was visually determined on sagittal 2-dimensional phase-contrast MR angiography for MR plaque imaging and on time-of-flight and gadolinium-enhanced 3-dimensional MR angiography for CFD analyses. Thus, the location may not always be identical between these 2 types of imaging. Fifth, WSS was calculated in the present study assuming that carotid bifurcation was rigid. WSS in the compliant model, which produces approximately the same degree of wall motion as that occurring in vivo, was reportedly smaller by  $\approx 30\%$  than in the rigid model at most locations in the carotid bifurcation of healthy humans.<sup>37</sup> Because vulnerable plaques are soft and weak, use of a rigid model may lead to overestimation of WSS in such plaques. However, because the plaque is thick in the carotid bifurcation with severe stenosis ( $\geq 70\%$ ), pulsatile wall motion may be low, and the overestimation of WSS is presumably minimal.<sup>20</sup> Sixth, the maximum value of WSS within the most severe stenotic segment was selected for analysis in each patient. Although this value was an independent predictor of the development of MES during exposure of the carotid arteries, which value, including the mean value of WSS in the most severe stenotic segment is more appropriate for this prediction remains unknown. Seventh, of the 100 patients who were finally analyzed, only 4 patients (4%) were women. The largest sample size of studies on CEA published recently in our country was 500 patients, and women made up only 8% of the sample size.<sup>38</sup> The prevalence of smokers, heavy drinkers, and patients with hypertension is lower in women than in men in our country. Lifestyle habits or lifestyle diseases in addition to racial characteristics may cause the low percent of women among patients with atherosclerotic severe stenosis of the cervical ICA. Furthermore, according to a study on MR carotid plaque features, the presence of a lipid/necrotic core was less common in women, and a trend was observed for a lower prevalence of intraplaque hemorrhages in women.<sup>39</sup> Thus, the prevalence of vulnerable carotid plaques is lower in women than in men,<sup>39</sup> also explaining the very low percent of women in our patient population.

However, these findings imply that our data for CFD analysis may not be applicable to women. More confirmatory data are needed in women. Finally, to optimally standardize the surgical methods, the same senior neurosurgeon, who was blinded to TCD data during surgery and proceeded with surgery regardless of this information, performed all surgeries. The carotid arteries may have been exposed to different degrees of stress because of manipulation in different patients, and this may have impacted the presence or absence of MES.

## Conclusions

In addition to carotid plaque intensity on T1-weighted MR imaging, WSS preoperatively calculated using CFD analysis for the carotid arteries is associated with development of MES on TCD during exposure of the carotid arteries during CEA.

## Sources of Funding

This study was partly funded by a Grant-in-Aid for Strategic Medical Science Research from the Ministry of Education, Culture, Sports, Science, and Technology of Japan (S1491001); and Scientific Research from the Japan Society for the Promotion of Science (JP15K10313).

## Disclosures

The corresponding author (Dr Ogasawara) has received research grants from consigned research funds from Nihon Medi-Physics, Co, Ltd. The other authors report no conflicts.

## References

- Rothwell PM, Eliasziw M, Gutnikov SA, Fox AJ, Taylor DW, Mayberg MR, et al; Carotid Endarterectomy Trialists' Collaboration. Analysis of pooled data from the randomised controlled trials of endarterectomy for symptomatic carotid stenosis. *Lancet*. 2003;361:107–116. doi: 10.1016/S0140-6736(03)12228-3
- Walker MD, Marler JR, Goldstein M, Grady PA, Toole JF, Baker WH, et al; Executive Committee for the Asymptomatic Carotid Atherosclerosis Study. Endarterectomy for asymptomatic carotid artery stenosis. *JAMA*. 1995;273:1421–1428. doi:10.1001/jama.1995.03520420037035
- Barnett HJM, Taylor DW, Haynes RB, Sackett DL, Peerless SJ, Ferguson GG, et al; North American Symptomatic Carotid Endarterectomy Trial Collaborators. Beneficial effect of carotid endarterectomy in symptomatic patients with high-grade carotid stenosis. *N Engl J Med*. 1991;325:445–453. doi: 10.1056/NEJM199108153250701
- Spencer MP. Transcranial Doppler monitoring and causes of stroke from carotid endarterectomy. *Stroke*. 1997;28:685–691.
- Ackerstaff RG, Moons KG, van de Vlasakker CJ, Moll FL, Vermeulen FE, Algra A, et al. Association of intraoperative transcranial doppler monitoring variables with stroke from carotid endarterectomy. *Stroke*. 2000;31:1817–1823.
- Wolf O, Heider P, Heinz M, Poppert H, Sander D, Greil O, et al. Microembolic signals detected by transcranial Doppler

- sonography during carotid endarterectomy and correlation with serial diffusion-weighted imaging. *Stroke*. 2004;35:e373–e375. doi: 10.1161/01.STR.0000143184.69343.ec
7. Gavrilescu T, Babikian VL, Cantelmo NL, Rosales R, Pochay V, Winter M. Cerebral microembolism during carotid endarterectomy. *Am J Surg*. 1995;170:159–164.
  8. Verhoeven BA, de Vries JP, Pasterkamp G, Ackerstaff RG, Schoneveld AH, Velema E, et al. Carotid atherosclerotic plaque characteristics are associated with microembolization during carotid endarterectomy and procedural outcome. *Stroke*. 2005;36:1735–1740. doi: 10.1161/01.STR.0000173153.51295.ee
  9. Gaunt ME, Martin PJ, Smith JL, Rimmer T, Cherryman G, Ratliff DA, et al. Clinical relevance of intraoperative embolization detected by transcranial Doppler ultrasonography during carotid endarterectomy: a prospective study of 100 patients. *Br J Surg*. 1994;81:1435–1439.
  10. Jansen C, Ramos LM, van Heesewijk JP, Moll FL, van Gijn J, Ackerstaff RG. Impact of microembolism and hemodynamic changes in the brain during carotid endarterectomy. *Stroke*. 1994;25:992–997.
  11. Rosario JA, Hachinski VC, Lee DH, Fox AJ. Adverse reactions to duplex scanning. *Lancet*. 1987;330:1023.
  12. Altaf N, Beech A, Goode SD, Gladman JR, Moody AR, Auer DP, et al. Carotid intraplaque hemorrhage detected by magnetic resonance imaging predicts embolization during carotid endarterectomy. *J Vasc Surg*. 2007;46:31–36. doi: 10.1016/j.jvs.2007.02.072
  13. Sitzer M, Müller W, Siebler M, Hort W, Knemeyer HW, Jäncke L, et al. Plaque ulceration and lumen thrombus are the main sources of cerebral microemboli in high-grade internal carotid artery stenosis. *Stroke*. 1995;26:1231–1233.
  14. Hatsukami TS, Yuan C. MRI in the early identification and classification of high-risk atherosclerotic carotid plaques. *Imaging Med*. 2010;2:63–75. doi: 10.2217/iim.09.33
  15. Sato Y, Ogasawara K, Narumi S, Sasaki M, Saito A, Tsushima E, et al. Optimal MR plaque imaging for cervical carotid artery stenosis in predicting the development of microembolic signals during exposure of carotid arteries in endarterectomy: comparison of 4 T1-weighted imaging techniques. *AJNR Am J Neuroradiol*. 2016;37:1146–1154. doi: 10.3174/ajnr.A4674
  16. Davies PF. Flow-mediated endothelial mechanotransduction. *Physiol Rev*. 1995;75:519–560. doi: 10.1152/physrev.1995.75.3.519
  17. LaBarbera M. Principles of design of fluid transport systems in zoology. *Science*. 1990;249:992–1000.
  18. Dolan JM, Meng H, Sim FJ, Kolega J. Differential gene expression by endothelial cells under positive and negative streamwise gradients of high wall shear stress. *Am J Physiol Cell Physiol*. 2013;305:854–866.
  19. Hoi Y, Wasserman BA, Xie YJ, Najjar SS, Ferruci L, Lakatta EG, et al. Characterization of volumetric flow rate waveforms at the carotid bifurcations of older adults. *Physiol Meas*. 2010;31:291–302. doi: 10.1088/0967-3334/31/3/002
  20. Tuentner A, Selwaness M, Arias Lorza A, Schuurbiens JCH, Speelman L, Cibis M, et al. High shear stress relates to intraplaque haemorrhage in asymptomatic carotid plaques. *Atherosclerosis*. 2016;251:348–354. doi: 10.1016/j.atherosclerosis.2016.05.018
  21. Harloff A, Berg S, Barker AJ, Schöllhorn J, Schumacher M, Weiller C, et al. Wall shear stress distribution at the carotid bifurcation: influence of eversion carotid endarterectomy. *Eur Radiol*. 2013;23:3361–3369. doi: 10.1007/s00330-013-2953-4
  22. Birchall D, Zaman A, Hacker J, Davies G, Mendelow D. Analysis of haemodynamic disturbance in the atherosclerotic carotid artery using computational fluid dynamics. *Eur Radiol*. 2006;16:1074–1083. doi: 10.1007/s00330-005-0048-6
  23. Koga M, Kimura K, Minematsu K, Yamaguchi T. Diagnosis of internal carotid artery stenosis greater than 70% with power Doppler duplex sonography. *AJNR Am J Neuroradiol*. 2001;22:413–417.
  24. Consensus Committee of the Ninth International Cerebral Hemodynamic Symposium. Basic identification criteria of Doppler microembolic signals. *Stroke*. 1995;26:1123. doi: 10.1161/01.STR.26.6.1123
  25. Pepe MS, Longton G. Standardizing diagnostic markers to evaluate and compare their performance. *Epidemiology*. 2005;16:598–603.
  26. Saito A, Sasaki M, Ogasawara K, Kobayashi M, Hitomi J, Narumi S, et al. Carotid plaque signal differences among four kinds of T1-weighted magnetic resonance imaging techniques: a histopathological correlation study. *Neuroradiology*. 2012;54:1187–1194. doi: 10.1007/s00234-012-1025-9
  27. van Dijk AC, Hussain TB, Saiedie ZG, de Rotte AAJ, Liem MI, et al. Intraplaque hemorrhage and the plaque surface in carotid atherosclerosis: the plaque at risk study (PARISK). *AJNR Am J Neuroradiol*. 2015;36:2127–2133.
  28. Sadat U, Teng Z, Gillard JH. Biomechanical structural stresses of atherosclerotic plaques. *Expert Rev Cardiovasc Ther*. 2010;8:1469–1481. doi: 10.1586/erc.10.130
  29. Dai G, Kaazempur-Mofrad MR, Natarajan S, Zhang Y, Vaughn S, Blackman BR, et al. Distinct endothelial phenotypes evoked by arterial waveforms derived from atherosclerosis-susceptible and -resistant regions of human vasculature. *Proc Natl Acad Sci USA*. 2004;101:14871–14876. doi: 10.1073/pnas.0406073101
  30. Malek AM, Alper SL, Izumo S. Hemodynamic shear stress and its role in atherosclerosis. *JAMA*. 1999;282:2035–2042.
  31. Gimbrone MA Jr, Topper JN, Nagel T, Anderson KR, Garcia-Cardena G. Endothelial dysfunction, hemodynamic forces, and atherogenesis. *Ann N Y Acad Sci*. 2000;902:230–239; discussion 239.
  32. Groen HC, Gijzen FJ, van der Lugt A, Ferguson MS, Hatsukami TS, van der Steen AF, et al. Plaque rupture in the carotid artery is localized at the high shear stress region: a case report. *Stroke*. 2007;38:2379–2381. doi: 10.1161/STROKEAHA.107.484766
  33. Gaunt ME, Brown L, Hartshorne T, Bell PR, Naylor AR. Unstable carotid plaques: preoperative identification and association with intraoperative embolisation detected by transcranial Doppler. *Eur J Vasc Endovasc Surg*. 1996;11:78–82.
  34. Kobayashi M, Ogasawara K, Inoue T, Saito H, Komoribayashi N, Suga Y, et al. Urgent endarterectomy using pretreatment with free radical scavenger, edaravone, and early clamping of the parent arteries for cervical carotid artery stenosis with crescendo transient ischemic attacks caused by mobile thrombus and hemodynamic cerebral ischemia. Case report. *Neurol Med Chir (Tokyo)*. 2007;47:121–125.
  35. Harrison GJ, How TV, Poole RJ, Brennan JA, Naik JB, Vallabhaneni SR, et al. Closure technique after carotid endarterectomy influences local hemodynamics. *J Vasc Surg*. 2014;60:418–427. doi: 10.1016/j.jvs.2014.01.069
  36. Ota H, Yarnykh VL, Ferguson MS, Underhill HR, Demarco JK, Zhu DC, et al. Carotid intraplaque hemorrhage imaging at 3.0-T MR imaging: comparison of the diagnostic performance of three T1-weighted sequences. *Radiology*. 2010;254:551–563. doi: 10.1148/radiol.09090535
  37. Anayiotos AS, Jones SA, Giddens DP, Glagov S, Zarins CK. Shear stress at a compliant model of the human carotid bifurcation. *J Biomech Eng*. 1994;116:98–106.
  38. Oshida S, Ogasawara K, Saura H, Yoshida K, Fujiwara S, Kojima D, et al. Does preoperative measurement of cerebral blood flow with acetazolamide challenge in addition to preoperative measurement of cerebral blood flow at the resting state increase the predictive accuracy of development of cerebral hyperperfusion after carotid endarterectomy? Results from 500 cases with brain perfusion single-photon emission computed tomography study. *Neurol Med Chir (Tokyo)*. 2015;55:141–148. doi: 10.2176/nmc.0a.2014-0269
  39. Ota H, Reeves MJ, Zhu DC, Majid A, Collar A, Yuan C, et al. Sex differences in patients with asymptomatic carotid atherosclerotic plaque: in vivo 3.0-T magnetic resonance study. *Stroke*. 2010;41:1630–1635. doi: 10.1161/STROKEAHA.110.581306