



Case report

Stress fracture in acetabular roof due to motocross: case report[☆]



Alexandre de Paiva Luciano*, Nelson Franco Filho

Discipline of Orthopedics and Traumatology, School of Medicine, Universidade de Taubaté, Taubaté, SP, Brazil

ARTICLE INFO

Article history:

Received 14 May 2015

Accepted 11 June 2015

Available online 2 April 2016

Keywords:

Stress fracture

Acetabulum

Athletic injuries

Palavras-chave:

Fraturas de estresse

Acetábulo

Traumatismos em atletas

ABSTRACT

One of the first steps to be taken in order to reduce sports injuries such as stress fractures is to have in-depth knowledge of the nature and extent of these pathological conditions. We present a case report of a stress fracture of the acetabular roof caused through motocross. This type of case is considered rare in the literature. The description of the clinical case is as follows. The patient was a 27-year-old male who started to have medical follow-up because of uncharacteristic pain in his left hip, which was concentrated mainly in the inguinal region of the left hip during motocross practice. After clinical investigation and complementary tests, he was diagnosed with a stress fracture of the acetabular roof.

© 2016 Published by Elsevier Editora Ltda. on behalf of Sociedade Brasileira de Ortopedia e Traumatologia. This is an open access article under the CC BY-NC-ND license (<http://creativecommons.org/licenses/by-nc-nd/4.0/>).

Fratura de estresse no teto acetabular por motocross: relato de caso

R E S U M O

Um dos primeiros passos para se reduzirem lesões, como a fratura de estresse no esporte, é conhecermos e nos aprofundarmos no estudo da natureza e extensão dessa patologia. A seguir apresentamos um relato de caso de fratura de estresse no teto acetabular por motocross. Caso considerado raro na literatura consultada. Descrição do quadro clínico: paciente de 27 anos; masculino, iniciou seguimento médico por dores incharacterísticas no quadril esquerdo, concentradas principalmente na região inguinal do quadril esquerdo durante a prática de motocross. Após investigação clínica e por exames complementares, diagnosticou-se fratura de estresse no teto acetabular.

© 2016 Publicado por Elsevier Editora Ltda. em nome de Sociedade Brasileira de Ortopedia e Traumatologia. Este é um artigo Open Access sob uma licença CC BY-NC-ND (<http://creativecommons.org/licenses/by-nc-nd/4.0/>).

[☆] Study carried out at the Discipline of Orthopedics and Traumatology, Faculdade de Medicina, Universidade de Taubaté, Taubaté, SP, Brazil.

* Corresponding author.

E-mail: paivaortopedia@gmail.com (A. de Paiva Luciano).

<http://dx.doi.org/10.1016/j.rboe.2016.03.004>

2255-4971/© 2016 Published by Elsevier Editora Ltda. on behalf of Sociedade Brasileira de Ortopedia e Traumatologia. This is an open access article under the CC BY-NC-ND license (<http://creativecommons.org/licenses/by-nc-nd/4.0/>).

Introduction

Stress fracture is a bone injury caused by the inability of a bone to withstand chronic overload, among other reasons.^{1,2} It differs from traumatic fractures in osteoporotic bones. We can also define stress fracture as an inadequate adaptation of the bone in response to the mechanical loads.³ Microscopic fissures in bone morphology, without rest from mechanical loads and without adequate time for their repair, may result in stress fracture.³

The first clinical description of stress fractures was reported by Breithaupt, a German military surgeon in 1855, *apud* Armstrong et al.⁴ Stechow reported, in 1897, *apud* Armstrong et al.,⁴ the first radiographic confirmation of stress fractures in military recruits, the fracture of a metatarsal bone. The diagnosis remained only among the military until Pirker *apud* Armstrong et al.,⁴ Iwamoto and Takeda⁵ reported the first stress fracture diagnosis in athletes, a transverse fracture of the femoral diaphysis in 1934.

There has been an exponential growth of motocross practice throughout the world, with an increase also in the number of amateur practitioners. Due to the extreme physical and physiological demands associated to worse physical fitness, amateur riders often suffer from fatigue. A localized muscle fatigue may result in inadequate function on demands that are specific to the sports modality, thus affecting the performance and resulting in musculoskeletal injuries.⁶

Motocross competitions are usually carried out in closed tracks with distances that can reach 1500 m. These tracks incorporate natural terrain features with varying numbers of jumps and curves. People unfamiliar to the sport often assume that the pilot does nothing more than drive a motorized vehicle around a field. However, motocross places a high degree of physical stress on the upper limbs and gluteus muscles (Fig. 1).

We report a case of stress fracture of the acetabular roof due to motocross practice.



Fig. 1 – Motocross biomechanics, jumps and curves.

Clinical case description

A 27-year-old male amateur motocross rider, searched medical attention due to uncharacteristic pain in his left hip, concentrated in the inguinal region during motocross practice during a month. He denied chronic medication use, previous surgeries or previously diagnosed chronic diseases.

The patient competed in amateur closed-circuit races, with distances ranging from 1200 to 2500 m, including frequent jumps, always while wearing personal protective equipment. He had training sessions three times a week and competitions on the weekends, which lasted between 15 and 30 min.

Physical examination at admission showed weight 70 kg, height 1.75 m, BMI = 22.87, with no abnormal facies.

Physical examination of the left hip:

- *Inspection*: mild limping during gait; without atrophies.
- *Palpation*: no pain on palpation of bone and soft tissue structures of the anterior, lateral, posterior and medial regions of the left hip;
- *Specific tests*: Trendelenburg: negative; Ludloff: negative; Thomas: negative; Ober: negative.
- *Degree of mobility*: extension 0°–30°, flexion 0°–120°, lateral rotation 0°–45°, medial rotation 0°–35°, abduction 0°–50°, adduction 0°–30°.
- *Neurological strength test*: Grade V: full motion against gravity and against great resistance.

Concomitantly, imaging tests were requested: hip radiography on 03/03/2011 disclosed no signs of fracture, no abnormalities in the acetabular version angle, and no deformities. Due to the lack of relevant informations obtained by radiographies, hip MRI was requested and performed on the same day (Fig. 2).

Discussion

Publications on the physical and physiological stress observed in motocross pilots after an official competition and/or technical and tactical training are still scarce. Thus, to understand the neuromuscular and biomechanical variables of this sports modality can be one of the first steps to reduce injuries such as stress fractures.

Stress fractures have been described in many sports modalities, such as athletics, tennis, basketball, volleyball, football and baseball.^{7,8} However, we found no articles in the literature on stress fractures in the acetabular roof caused by motocross practice, which demonstrates the rarity of the reported case.

There are several factors for risk of stress fracture. They are divided into intrinsic (gender, age, ethnicity, and muscle strength), extrinsic (training regimen, footwear, training surface and type of sport), biochemical (bone mineral density and bone geometry), anatomical (foot morphology, leg length discrepancy and knee alignment), hormonal (delayed menarche, menstrual disorders and contraceptive use) and nutritional disorders (calcium and vitamin D deficiency).⁸

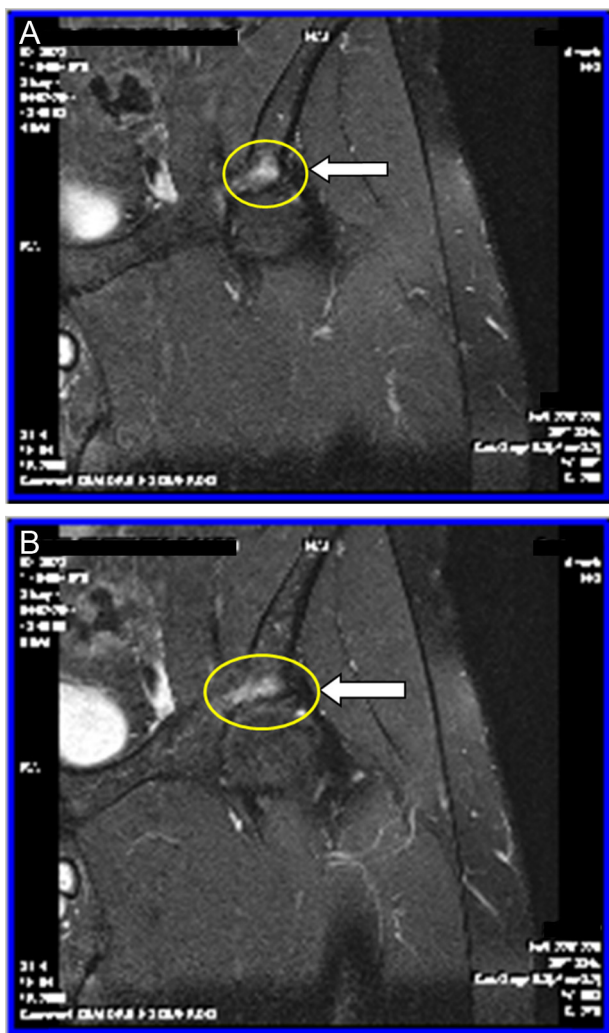


Fig. 2 – Linear hyperintense image on T2 and STIR sequences, surrounded by area of edema with poorly defined limits; acetabular roof stress fracture is suggested.

Stress fractures usually occur in groups of young individuals submitted to intense physical activities. The tibia is the most common site of involvement in athletes and accounts for 50% of the total cases. However, the fracture location varies depending on the sports modality practiced.⁸

The plain radiography is the first imaging method used in most cases and allows assessing probable abnormalities on the acetabular version angle, an important differential diagnosis for the stress fracture. However, Magnetic Resonance Imaging (MRI) is the superior diagnostic method for assessment of stress fractures, with comparable sensitivity and higher specificity than scintigraphy. It can demonstrate the presence of fracture in cases where the conventional radiography is considered normal.⁹ MRI is more specific than scintigraphy in detecting hip stress fractures, differentiating them from other causes of bone and soft tissue pain, such as avascular necrosis, bursitis and iliopsoas tendonitis.⁹⁻¹¹

Williams et al.¹² demonstrated the importance of magnetic resonance imaging and scintigraphy in the diagnosis of stress

fractures of the acetabular roof. They evaluated 178 active military personnel with a history of hip pain associated with physical activity through plain hip and pelvis radiographs, which were interpreted as normal. MRI and bone scintigraphy showed that 12 of 178 patients (6.7%) had imaging findings compatible with acetabular stress fracture. Two patterns were identified. Seven of the 12 (58%) patients had stress fractures of the acetabular roof. In this group, two cases of bilateral stress fracture of the acetabular roof were identified. And five of 12 (42%) patients had anterior column acetabular fractures, which rarely occur in isolation and almost always with a stress fracture of the lower pubic ramus.¹² This demonstrates the rarity and how difficult is the diagnosis of stress fracture of the acetabular roof.

The diagnosis of hip stress fractures must be considered in any athlete with hip and/or the proximal portion of the thigh pain, especially in sports involving joint impact. Stress fractures can also be observed in the sacrum and the ischial ramus, near the insertion of the semimembranosus, semitendinosus and biceps femoris tendons.^{10,11}

We did not find a consensus regarding the treatment of stress fractures of the acetabular roof in the assessed literature. Therefore, for this case, we adopted the treatment protocol for most of stress fractures in athletes. The fracture described in this case was considered to be of low risk, similar to most stress fractures.^{13,14} These fractures can be treated with a two-stage protocol.^{13,14} Stage 1 is characterized by pain control through the prescription of analgesics, reduction or elimination of sports gestures that cause symptoms and introduction of physical therapy modalities. If the individual is unable to walk without pain, he/she should remain immobilized, for instance, with a removable stabilizing orthosis and/or a pair of crutches.

A modified activity that can maintain the physical strength and fitness, but with reduced impact, is prescribed. Activities such as running in the swimming pool, elliptical exercises, free and stationary bicycle can maintain the physical strength and fitness, before the reintroduction of impact exercises. Exercises in water and anti-gravity ones can be used as a resource to gradually reintroduce sports gestures.^{13,14}

Phase 2 is characterized by phase 1 interventions plus a gradual return to sports practice, to be started when the athlete has no pain and normal mobility, around 10-14 days after symptom onset. The time to resume the sports movements depends on many factors, including the severity and chronicity of the injury and functional morbidity level of the athlete.^{13,14} For this patient, treatment started with pain control through analgesic prescription, discontinuation of motocross practice and any impact activity, followed by physical therapy. Reintroduction of the sports gesture began after symptoms subsided and MRI control was performed 90 days after symptom onset, with good progression. He resumed full training after 120 days and return to races 180 days after beginning treatment.

Conflicts of interest

The authors declare no conflicts of interest.

REFERENCES

1. Garrett WE Jr, Safran MR, Seaber AV, Glisson RR, Ribbeck BM. Biomechanical comparison of stimulated and nonstimulated skeletal muscle pulled to failure. *Am J Sports Med.* 1987;15(5):448-54.
2. O'Brien FJ, Taylor D, Clive Lee T. The effect of bone microstructure on the initiation and growth of microcracks. *J Orthop Res.* 2005;23(2):475-80.
3. Burr D, Migrom C. *Musculoskeletal fatigue and stress fractures.* Boca Raton, FL: CRC Press; 2001.
4. Armstrong DW 3rd, Rue JP, Wilckens JH, Frassica FJ. Stress fracture injury in young military men and women. *Bone.* 2004;35(3):806-16.
5. Iwamoto J, Takeda T. Stress fractures in athletes: review of 196 cases. *J Orthop Sci.* 2003;8(3):273-8.
6. Avela J, Kyröläinen H, Komi PV. Neuromuscular changes after long-lasting mechanically and electrically elicited fatigue. *Eur J Appl Physiol.* 2001;85(3-4):317-25.
7. Berger FH, de Jonge MC, Maas M. Stress fractures in the lower extremity. The importance of increasing awareness amongst radiologists. *Eur J Radiol.* 2007;62(1):16-26.
8. Nattiv A, Puffer JC, Casper J. Stress fracture risk factors, incidence, and distribution: a 3 year prospective study in collegiate runners. *Med Sci Sports Exerc.* 2000;32 Suppl. 5:S347.
9. Stoller DW, Maloney WT, Glick JM. The hip. In: Stoller DW, editor. *Magnetic resonance imaging in orthopaedics & sports medicine.* San Francisco: Lippincott; 1997. p. 93-202.
10. Kneeland JB. MR imaging of sports injuries of the hip. *Magn Reson Imaging Clin N Am.* 1999;7(1):105-15.
11. Resnick D, Kang HS. Pelvis and hip. In: Resnick D, Kang HS, editors. *Internal derangement of joints.* San Diego: Saunders; 1997. p. 473-554.
12. Williams TR, Puckett ML, Denison G, Shin AY, Gorman JD. Acetabular stress fractures in military endurance athletes and recruits: incidence and MRI and scintigraphic findings. *Skelet Radiol.* 2002;31(5):277-81.
13. Boden BP, Osbahr DC, Jimenez C. Low-risk stress fractures. *Am J Sports Med.* 2001;29(1):100-11.
14. Mallee WH, Weel H, van Dijk CN, van Tulder MW, Kerkhoffs GM, Lin CW. Surgical versus conservative treatment for high-risk stress fractures of the lower leg (anterior tibial cortex, navicular and fifth metatarsal base): a systematic review. *Br J Sports Med.* 2015;49(6):370-6.