



# Conservative treatment of cesarean scar pregnancy with the combination of methotrexate and mifepristone: A systematic review

Guglielmo Stabile<sup>1</sup> , Laura Vona<sup>1</sup>, Stefania Carlucci<sup>1</sup>, Francesco Zullo<sup>1</sup>, Antonio Simone Laganà<sup>2</sup> , Andrea Etrusco<sup>2</sup>, Stefano Restaino<sup>3</sup> , and Luigi Nappi<sup>1</sup>

## Abstract

**Background:** Cesarean scar pregnancy (CSP) has become more frequent as a direct consequence of the increased number of cesarean deliveries and the advances in imaging. Although some cases are characterized by spontaneous resolution, unrecognized or mishandled CSP has the potential to cause both fetal and maternal morbidity and mortality. However, due to its infrequency, there is no agreement on the best management.

**Objective:** The purpose of this study was to evaluate the safety, the risks and effectiveness of medical therapy with methotrexate and mifepristone to better understand its role in CSP therapy.

**Design:** This study is a systematic review.

**Data Sources and Methods:** The electronic databases PubMed, Medline, and Scopus were comprehensively searched until December 2023. Medical Subject Headings terms (Cesarean scar pregnancy) AND (Methotrexate) AND (Mifepristone) AND (Medical Therapy) were used to identify the relevant records. Due to the rarity of this pathology, the studies included are all case reports or case series. The methodological quality of the included studies was assessed using the JBI Critical Appraisal Checklist for case reports.

**Results:** We included in our review a total of seven cases reported in five manuscripts at the end of the screening process. Our review suggests that this type of combination treatment can be considered. The success rate is 71.4%. Treatment seems to be most effective when beta human chorionic gonadotropin (B-hCG) is below 5,000 mU/ml and when the gestational sac is less than 20 mm. The absence of fetal heartbeat seems to be a positive prognostic factor for a positive outcome.

**Conclusion:** Methotrexate and mifepristone administration can be considered as an alternative first-line effective treatment, especially in case of pregnancy with B-hCG <5,000 mU/ml and when the gestational sac is less than 20 mm. It is important to individualize the management and treatment according to the clinical condition, the patient's age, number of previous cesarean deliveries, willingness to have other children, and the physicians' experience.

## Plain language summary

**Unrecognized Cesarean Scar Pregnancy has the potential to cause both fetal and maternal morbidity and mortality. Methotrexate (MTX) and Mifepristone administration can be considered as an alternative**

<sup>1</sup>Department of Medical and Surgical Sciences, Institute of Obstetrics and Gynaecology, University of Foggia, Foggia, Italy

<sup>2</sup>Unit of Obstetrics and Gynecology, "Paolo Giaccone" Hospital, Department of Health Promotion, Mother and Child Care, Internal Medicine and Medical Specialties (PROMISE), University of Palermo, Palermo, Italy

<sup>3</sup>Department of Maternal and Child Health, Obstetrics and Gynecology Clinic, University-Hospital of Udine, Udine, Italy

### Corresponding author:

Guglielmo Stabile, Department of Medical and Surgical Sciences, Institute of Obstetrics and Gynaecology, University of Foggia, Viale Luigi Pinto 1, Foggia 71121, Italy.  
Email: [guglielmost@gmail.com](mailto:guglielmost@gmail.com)



## first-line effective treatment especially in case of pregnancy with a low BHCG and when the gestational sac is less than 20 mm

Cesarean scar pregnancy (CSP) has become more frequent as a direct consequence of the increased number of Cesarean deliveries and the advances in imaging. Unrecognized CSP has the potential to cause both fetal and maternal morbidity and mortality. However, there is no agreement on the best management. The purpose of this study was to evaluate the safety, the risks, and effectiveness of medical therapy with methotrexate and mifepristone. The electronic databases PubMed, Web of Science, and Scopus were comprehensively searched until December 2023. We included in our review a total of seven cases reported in five manuscripts at the end of the screening process. Our review suggests that this type of combination treatment can be considered. The success rate is 71.4%. Treatment seems to be most effective when B-hCG is below 5000 mU/ml and when the gestational sac is less than 20 mm. methotrexate (MTX) and mifepristone administration can be considered as an alternative first-line effective treatment.

### Keywords

scar pregnancy, ectopic pregnancy, methotrexate, mifepristone, medical treatment

Date received: 16 June 2024; revised: 12 September 2024; accepted: 23 September 2024

### Introduction

Cesarean scar pregnancy (CSP) is a rare type of ectopic pregnancy that occurs when an embryo implants in a previous cesarean scar defect on the muscular wall of the uterine isthmus. First described in 1978,<sup>1</sup> this condition has become more frequent as a direct consequence of the increased number of cesarean deliveries and the advances in imaging.<sup>2</sup> The frequency of CSP has a rate of 6.1% in women who had  $\geq 1$  prior cesarean section (CS),<sup>3</sup> in the range of 0.04%–0.05% (1/1,800 to 1/2,216) of all pregnancies and 0.15% in women who had previous CSs.<sup>4,5</sup>

In the literature, 13% CSP were misdiagnosed as intrauterine or cervical pregnancies at presentation. The prevalence is probably underestimated because some cases end in the first trimester, with miscarriage or termination, and are not reported and diagnosed.<sup>6</sup>

Although some cases are characterized by spontaneous resolution, unrecognized or mishandled CSP has the potential to cause both fetal and maternal morbidity and mortality (e.g., hemorrhage, dehiscence, or rupture of the uterus in the second or third trimester of pregnancy, preterm delivery) due to the blastocyst's deep infiltration into the scar's fibrous tissue of the lower uterine segment.<sup>4</sup> The risk of such complications increases with the number of previous CS, although other previous dilatation and curettage.<sup>7</sup>

In fact, when the scar pregnancy invades the myometrium, it can evolve into the adherent placenta spectrum disorders, such as placenta accreta, increta, and percreta. And progressive deep invasion of the placenta is life-threatening.<sup>6,8</sup>

Vial et al. described for the first time in 2000 a classification for two different types of CSPs.<sup>9</sup>

Type I or on the scar, in which the amniotic sac is implanted on a cesarean scar and progresses into the cervical-isthmic space and uterine cavity.

Type II or in the niche, when the CSP is implanted within the scar defect, resulting in deep invasion and progression to the bladder and abdominal cavity.

The first goal in the management of CSP is an accurate diagnosis and classification. Transvaginal ultrasound (TVUS) combined with color Doppler assessment is generally considered the gold standard for the diagnosis of CSP.<sup>10</sup>

The first TVUS to determine the position of pregnancy should be performed at 6–7 weeks' gestation.<sup>11</sup> The reasons are twofold:

1. The diagnosis of CSP is based on the gestational sac identification in or near the area of the cesarean scar. This relationship is best assessed in the early first trimester.
2. Early diagnosis of CSP allows successful conservative therapy selection, associated with fewer complications.

Due to its infrequency, there is no agreement on the best management. Both diagnosis and treatment of CSP are still challenging.

Patients typically present with vaginal bleeding and pain but can remain asymptomatic in up to 25% of cases at the time of ultrasound diagnosis. Vaginal bleeding usually appears at the end of the first or beginning of the second trimester and usually presents as intermittent, mild spotting but can be profuse and painless.<sup>12</sup>

Depending on the patient hemodynamic stability, embryo size, residual myometrial thickness, and desires for future fertility, CSP can be managed medically or surgically with laparoscopy, laparotomy, or a transvaginal approach or less invasively with hysteroscopy, dilatation and curettage, artery chemoembolization or ultrasound-guided injection of methotrexate (MTX) or other drugs, or a combination of these therapies.

Systematic reviews on the treatment of CSP recommend an interventional approach, single or combined, or when possible an expectant management or medical treatment, although no clear conclusion has been reached.<sup>3,13</sup>

Data from the literature are discordant with regard to medical therapy. Even if the MTX is the most widely used drug, there are no clear data on which administration is the most effective (IM or local).

The aim of our review is to analyze the safety, the risks, and effectiveness of medical therapy with MTX and mifepristone to better understand its role in the CSP therapy and to perform the best possible strategy for fertility sparing in hemodynamically stable patients.

## Materials and methods

We performed our research on MEDLINE (PubMed), Web of Science, and Scopus databases and have considered articles published until December 2023 without previous historical limits. The research strategy adopted included different combinations of the following terms: (Cesarean scar pregnancy) AND (Methotrexate) AND (Mifepristone) AND (Medical Therapy). Only article in English or with abstract in English were included in our research. Two articles written in Chinese language and with abstract in English were excluded considering the incomplete data of the abstract.

For the articles' selection, we included articles that focused on medical therapy with MTX and mifepristone for the management of CSP, without other combinations of therapies. Three case reports, one case series, one cross-sectional study meet all the review requirements. We excluded studies that do not meet our clinical study design, irrelevant studies, and duplicate records from the included studies. We examined in our review the patients' age, their obstetrical history, previous surgical procedures, symptoms, the beta human chorionic gonadotropin (B-hCG) levels, the weeks of amenorrhea, and the gestational sac dimensions. We excluded from the review studies concerned with cases of medical treatment with MTX and mifepristone combined with surgical therapy or other medical or invasive therapy. Articles not relevant to the topic were also excluded.

All studies identified were examined for year, citation, title, authors, abstract, and their full texts. Duplicates were identified through manual screening performed by two researchers (LV and GS) and then removed. PRISMA guidelines were followed.<sup>14</sup> For the eligibility process, two authors (GS and LV) independently screened the title and abstracts of all non-duplicated articles and excluded those not pertinent to the topic. The same two authors independently reviewed the articles full text that passed the first screening and identified those to be included in the review. Discrepancies were resolved by consensus.

Two researchers performed data extraction using a pre-defined form including the following data: author, month, and year.

Due to the rarity of this pathology, the studies included are all case reports or case series. For this reason, we present the data in a descriptive manner. We have analyzed for each case the age of the patient, pregnancy history, gestational age, presenting symptoms, TVUS findings, the presence of fetal heartbeat, basal B-hCG, the type of MTX administration, complications and their management, and time of B-hCG negativization. The inclusion of only case reports in this review presents a risk of bias. The methodological quality of the included studies was assessed using the JBI Critical Appraisal Checklist for case reports (Supplemental Table 1).

## Results

We identified 107 manuscripts, of these 20 records were identified on PubMed, 19 were identified on Web of Science and 68 on Scopus. Records excluded for selection criteria and duplicates were  $n=101$ . Two manuscripts were excluded because they are written in Chinese language and the information that could be recovered were limited. We included in our review, a total of seven cases reported in five manuscripts at the end of the screening process (Table 1). The PRISMA flow diagram of the selection process is provided in Table 2.

## Results

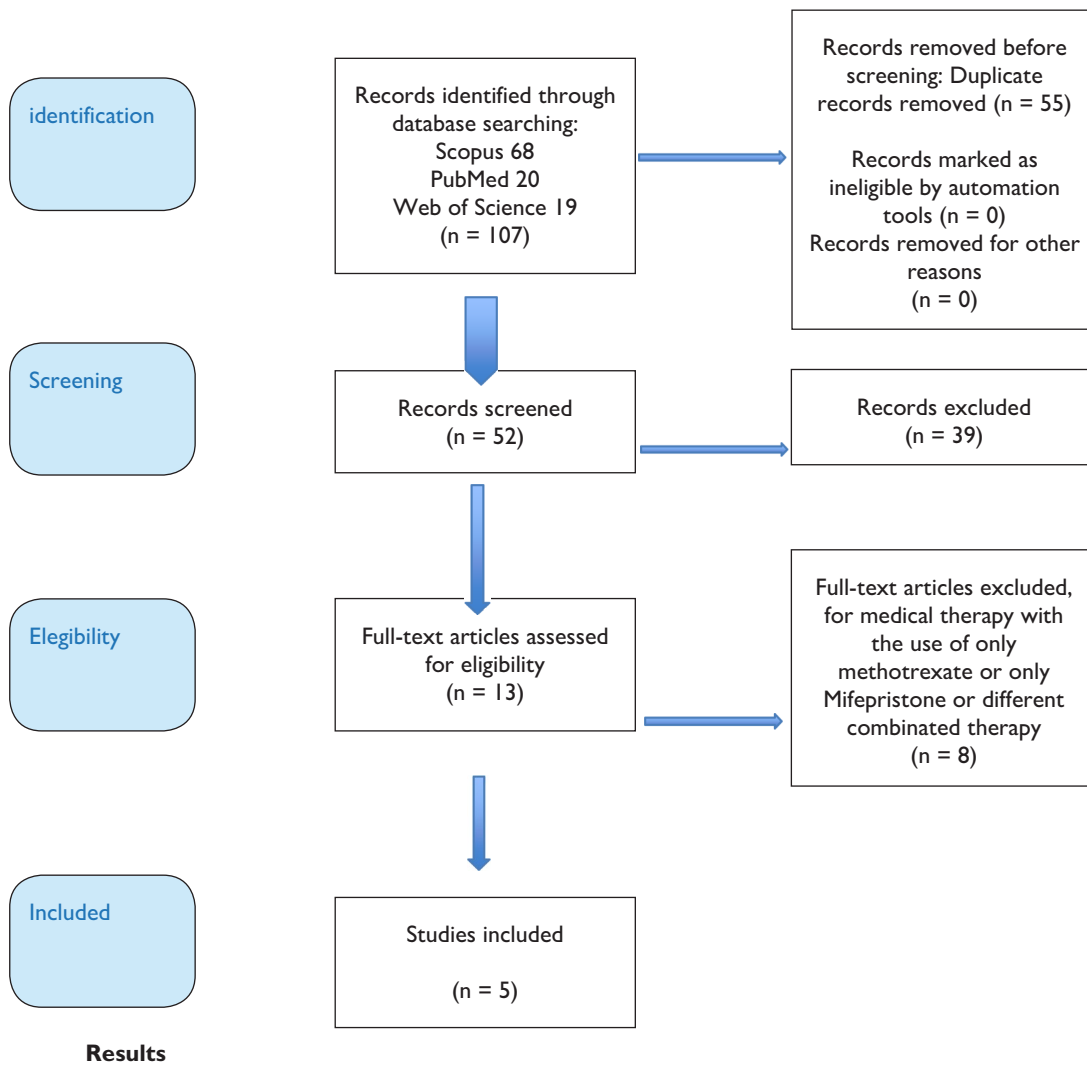
According the JBI Critical Appraisal Checklist for case reports, in four cases the information was complete, while in two cases there are insufficient data about the follow-up; in one case the take home message was missing.

In our analysis, the patients' median age was 30 years. About 71.5% had one previous CS, 28.5% had three CSs. The median gestational age was 6 weeks and 5 days. The most frequent presenting symptom was vaginal bleeding in 57% of cases, asymptomatic in 43% of cases, and tender to palpation in 14% of cases. In four on seven cases, a vital embryo was present. In only two cases, the residual myometrial thickness was measured, and the median thickness was 2.3 mm. The B-hCG median value was 82,354 mUI/ml. The most used MTX protocol was the single dose 1 (42.8%) with the administration of 600 mg of mifepristone in single dose. In 28.5% of cases a multiple dose protocol was used, with the administration of MTX on day 0, 7 or 0, 7, and 14 and mifepristone 600 mg Per oral subadministration (POS) on day 7. In 28.5% of cases a multiple dose protocol was used, with the administration of MTX on day 0, 2, 4, and 6 and mifepristone 50 mg twice a day at day 6. In two cases (28.5%), there were complications: in one case, B-hCG level increased and vaginal bleeding and successive dilatation and curettage under ultrasound guidance

Table 1. Cases in the literature.

References	Age	Pregnancy history	GA	Presenting symptoms	TVUS findings	FHB	Basal B-hCG (mIU/ml)	Management	Complications and management	hCG surveillance until negativization
Case 1 Kalampokas et al. <sup>15</sup>	31	PIG1 1 previous CS Last cesarean delivery 1 year ago	6+1	Vaginal bleeding	Gestational sac present. Embryo present	Present	1,207,213 mIU/ml	MTX 1 mg/kg IM on days 0, 7, 14+ mifepristone (600 mg) POS on day 7	/	20W
Case 2 Pristavu et al. <sup>16</sup>	32	G4P3 3 Previous CSs	12	Vaginal bleeding	Gestational sac present. No embryo seen RMT 2.6 mm	Absent	1,549 mIU/ml	MTX 1 mg/kg IM 1 dose + mifepristone (600mg) POS on day 0	/	<5 days
Case 3 Pristavu et al. <sup>16</sup>	31	G2P1 1 Previous CS	5	Vaginal bleeding Tender to palpation	Gestational sac 20.3 mm Embryo present RMT 2mm	Present	19,148 mIU/ml	MTX 1 mg/kg IM 1 dose Mifepristone (600 mg) POS on day 0	Increase hCG levels Spontaneous miscarriage with heavy vaginal bleeding D&C under US guidance hemostasis with uterine- vaginal pack	<10 days
Case 4 Gómez García et al. <sup>17</sup>	35	1 previous CS G-NA PI Recurrent miscarriage	5+3	Asymptomatic	Gestational sac 9 × 6mm Small yolk sac Embryo present	Present	1,716 mIU/ml	MTX 1 mg/kg IM 1 dose Mifepristone (600 mg) POS on day 0	/	4W
Case 5 Storgaard et al. <sup>18</sup>	28	G3P3 3 previous CS.	6+6	Asymptomatic	Gestational sac present. Embryo present	Present	13,163 mIU/ml	MTX 1 mg/kg IM on days 0, 7 Mifepristone (600 mg) POS on day 7	FHB presence. Transvaginal intrathoracic 1 mmol potassium chloride injection. After 5 months, pregnancy products still present. Laparotomy was made to suturing a cesarean defect extending just above the cervicouterine junction	NA
Case 6 Zhang et al. <sup>19</sup>	30	G4P1 1 previous CS	5+2	Asymptomatic	Gestational sac <20mm. Existence of myometrium between the gestational sac and the bladder wall	Absent	<5,000 mIU/ml	MTX 1 mg/kg IM on days 0, 2, 4, 6 Tetrahydrofolate 0.1 mg/kg IM on days 1, 3, 5, 7. Mifepristone (50 mg b.i.d.) POS on day 6	/	B-hCG level decreased over 50% in 1 week and TVUS imaged the mass in the isthmus diminish 1 week after treatment
Case 7 Zhang et al. <sup>19</sup>	24	G3P1 1 previous CS	6+2	Vaginal bleeding	Gestational sac <20mm. Existence of myometrium between the gestational sac and the bladder wall	Absent	<5,000 mIU/ml	MTX 1 mg/kg IM on days 0, 2, 4, 6 Tetrahydrofolate 0.1 mg/kg IM on days 1, 3, 5, 7. Mifepristone (50 mg b.i.d.) POS on day 6	/	B-hCG level decreased over 50% in 1 week and TVUS imaged the mass in the isthmus diminish 1 week after treatment

MTX: methotrexate; CS: cesarean section; B-hCG, beta human chorionic gonadotropin; TVUS, transvaginal ultrasound; FHB, fetal heartbeat; POS, per oral subadministration; RMT, residual myometrial tissue.

**Table 2.** Prisma flow diagram.

and hemostasis with uterine-vaginal pack were required. In the second case, no feticide effect was seen and 4 days after the last MTX injection, a transvaginal fetal intrathoracic injection of 1 mmol potassium chloride was administered, after which the cardiac action ended. Five months later, the patient was readmitted because pregnancy products were yet in the cesarean scar and a 1.5-cm defect extending all the way to the midline just above the cervical-uterine junction was present. After laparotomy, the defect was sutured.

The general success rate is 71.4%. The single-dose protocol was successful in 66.6% of cases, instead the multiple dose in 75% of cases.

The median B-hCG negativization was 46 days. The follow-up was reported until B-hCG negativization in four patients. In two cases, the follow-up was reported until 1 week after the last administration, and it was reported

only the value of B-hCG halving. The lack of these data for some studies could lead to interpretation bias.

## Discussion

In contrast to other ectopic pregnancies, for caesarean scar pregnancy, there is insufficient evidence to recommend any specific intervention over another.

Advances in TVUS and availability of quantitative B-hCG allow the diagnosis at an earlier gestational age. Management and treatment should be individualized not only according primarily to the clinical condition but also according to the patient's age, number of previous caesarean deliveries, willingness to have other children, and the experience of the providers involved in her care.<sup>20</sup>

It should be emphasized that unlike other types of ectopic pregnancies, scar pregnancy may progress to term or near to

term, questioning whether termination should be the only treatment option offered to these women. However, CSP with positive embryonic/fetal cardiac activity managed with expectant management is associated with a high burden of maternal morbidity. In Bartels et al. review, the expectant management resulted in 57% live birth rate; however, 63% of these women required hysterectomy for Placenta accreta spectrum or uterine rupture.<sup>21</sup>

In a metaanalysis including 40 cases of live CSP managed expectantly, uterine rupture occurred in 9.9% women in the first or second trimester, 15% of whom required hysterectomy. For those cases that progressed to the third trimester, 70% developed placenta percreta and 40% experienced severe bleeding.<sup>22</sup>

Uterine curettage is not generally considered a first-line treatment because it has a high rate of complications (70%–90%) and failure.<sup>23</sup>

Selective chemoembolization with MTX followed by suction and curettage is one of the treatment options for CSP that has a higher success rate than suction and curettage alone. Embolization of the uterine arteries with intra-arterial infusion of MTX is a minimally invasive technique performed endovascularly. This method allows concentrated administration of MTX directly into the arteries supplying the gestational foci, whereas occluding the vessel with occlusive agents administered through a catheter.<sup>24</sup>

Surgical approach has higher rates of pregnancy termination in literature than medical therapy, with theoretical advantages of having faster resolution of the CSP, obtaining tissue for diagnosis confirmation, and facilitating closure and healing of the uterine defect, thus reducing the risk of recurrence.

Operative resection (e.g., wedge resection) of the pregnancy can be performed laparoscopically, hysteroscopically, or (less commonly) laparotomically; laparoscopically assisted hysteroscopic operative management has also been described.<sup>25,26</sup>

However, some limitations of this approach as the need for a surgeon with advanced laparoscopic and hysteroscopic knowledge, and the possible need for general anesthesia and the risk of conversion to a laparotomy or hysterectomy if uncontrolled hemorrhage developed, make these methods challenging and applicable mainly to advanced cases.<sup>27,28</sup>

The disadvantage of medical treatment is that the product of conception remains in situ, and this could lead to a long time of follow-up until B-hCG negativization.

MTX is the most widely used chemotherapeutic agent well established as a reasonable non-surgical treatment for selected ectopic pregnancies. In CSP, it has demonstrated its effectiveness in 65.1% of cases according to Fu et al.<sup>3</sup>

The most common adverse effects are excessive flatulence and bloating due to intestinal gas formation, a mild transient elevation of liver enzymes, and stomatitis. More serious and less common adverse effects are bone marrow

suppression, nonspecific pneumonia, pulmonary fibrosis, liver cirrhosis, renal failure, and gastric ulceration. Furthermore, the major complication rate, like hysterectomy, open surgery, excessive bleeding (>500 mL), blood transfusion, pelvic infection, organ damage, recurrent active bleeding, and disseminated intravascular coagulation (13.3%).<sup>3</sup>

In case of scar pregnancy, MTX can be administered by local injection into the gestational sac under ultrasound guidance or systemically by intramuscular injection. If compared with systemic administration of MTX, intra-amniotic injection allows the achievement of a higher local concentration of MTX and higher success rate<sup>29</sup> but the mean time to normalization of B-hCG is higher with the local compared to the systemic treatment.<sup>30</sup> The local injection should be considered an invasive procedure that needs specific expertise with a higher risk of bleeding and pain.<sup>31</sup>

The similarities between the molecular structures of MTX and folic acid allow MTX to act as a potent competitive inhibitor of dihydrofolate reductase, which has a higher affinity for MTX than for folic acid. Folic acid is critical for the development of rapidly growing cells, as it is essential for DNA and RNA synthesis. In fact, MTX primarily affects actively proliferating tissues, including trophoblastic tissue (but also bone marrow, buccal and intestinal mucosa, and respiratory epithelium, and thus causes the undesirable effects mentioned above). Some authors add tetrahydrofolate to multiple-dose MTX therapy to avoid systemic adverse effects.<sup>32</sup>

The addition of mifepristone to MTX presented by some authors, is based on the effectiveness of this combination in treating other types of ectopic pregnancy.<sup>20,33</sup> Mifepristone appears to play a key role in those ectopic pregnancies in which the presence of endometrium and thus progesterone receptors is higher, so the use of an anti-progesterone can interfere with the pregnancy development enhancing the MTX effect.

MTX and mifepristone administration is considered a good medical treatment. In patients with live pregnancy, mifepristone was added to shorten the time until embryo's death and potentially reduce the dose of MTX. This is because progesterone is necessary for both the development and maintenance of pregnancy. After ovulation, the corpus luteum secretes progesterone to decidualize the endometrium and make it suitable for implantation of the embryo. Once implantation occurs, progesterone suppresses uterine contractions. Mifepristone is a steroidal antiprogesterone drug that competitively binds the progesterone receptor with a relative affinity 2–10 times that of progesterone. This combination leads to trophoblast cells dysfunction and decidua degeneration and necrosis.<sup>20</sup>

Our review suggests that this type of combination treatment can be considered, whereas the success rate is 71.4%. Treatment seems to be most effective in cases where B-hCG

is below 5,000 mU/ml and when the gestational sac is less than 20 mm. The absence of fetal heartbeat seems to be a positive prognostic factor for a positive outcome. The presence or absence of symptoms does not appear to be a negative prognostic factor. The complication rate was 28.5% but in 14% of cases resolution was easy to achieve. Future research may investigate the role of CSP location (on the scar or in the niche) as a possible predictor of success.

Limitations of this review include its retrospective nature with selection bias, as the information derive from case reports and series with few available data in which MTX and mifepristone were administered unblinded and with different protocols. It must be also considered the small number of clinical studies included in our review. It is understandable that a literature review like this may have incomplete data, such as detailed ultrasound features and rate of decline in hCG levels, but this should not affect the primary outcome. However, this is the only review in literature that examines the treatment of CSP with MTX and mifepristone alone. The articles were selected from the literature according to standard criteria and reviewed case by case. We agree that the most appropriate treatment for each woman with CSP should be individualized, choosing the least invasive approach based on the woman's symptoms and preferences

## Conclusion

CSP is an emerging health problem resulting from the steady increase in the maternal age of delivery, the rise in the number of CSs and medically assisted procreation procedures that generally raise the rate of abnormal pregnancy implantation. The management of this type of pathology is also complicated by its rarity, the absence of guidelines, and the conflicting results of the various treatments described in the literature. Further studies as clinical trials or prospective studies from multiple centers are required to establish which is the best approach for CSP management. According to our review, in clinically stable patients, a therapy with MTX and mifepristone can be offered as an alternative first-line effective treatment. However, it is important to individualize the management and treatment according to the clinical condition, CSP type, the patient's age, number of previous cesarean deliveries, willingness to have other children, and the physicians' experience.

## Declarations

### Ethics approval and consent to participate

Not applicable as the study is based exclusively on published literature/medical record.

### Consent for publication

Not applicable.

## Author contribution(s)

Conceptualization, **Guglielmo Stabile**; methodology, **Guglielmo Stabile** and **Laura Vona**; validation, **Luigi Nappi**, **Antonio Simone Laganà**, and **Stefania Carlucci**; formal analysis, **Laura Vona** and **Francesco Zullo**; investigation, **Laura Vona**, **Andrea Etrusco**; resources, **Luigi Nappi**; data curation **Guglielmo Stabile**, **Stefania Carlucci**, **Stefano Restaino**, and **Laura Vona**; writing – original draft preparation, **Laura Vona** and **Guglielmo Stabile** writing – review and editing, **Guglielmo Stabile** and **Stefania Carlucci**; visualization, **Andrea Etrusco**, **Antonio Simone Laganà**, **Stefano Restaino**, and **Luigi Nappi**; supervision, **Luigi Nappi**; project administration, **Guglielmo Stabile**; all authors have read and agreed to the published version of the manuscript.

## Acknowledgements

None.

## Funding

The authors received no financial support for the research, authorship, and/or publication of this article.

## Competing interests

The authors declared no potential conflicts of interest with respect to the research, authorship, and/or publication of this article.

## Availability of data and materials

The authors confirm that the data supporting the findings of this study are available within the article.

## ORCID iDs

Guglielmo Stabile  <https://orcid.org/0000-0001-9266-3896>

Antonio Simone Laganà  <https://orcid.org/0000-0003-1543-2802>

Stefano Restaino  <https://orcid.org/0000-0002-7848-0329>

## Supplemental material

Supplemental material for this article is available online.

## References

1. Larsen JV and Solomon MH. Pregnancy in a uterine scar sacculus—an unusual cause of postabortal haemorrhage. A case report. *S Afr Med J* 1978; 53(4): 142–143.
2. Mollo A, Alviggi C, Conforti A, et al. Intact removal of spontaneous twin ectopic Caesarean scar pregnancy by office hysteroscopy: case report and literature review. *Reprod Biomed Online* 2014; 29(5): 530–533.
3. Fu P, Sun H, Zhang L, et al. Efficacy and safety of treatment modalities for cesarean scar pregnancy: a systematic review and network meta-analysis. *Am J Obstet Gynecol* 2024; 6(8): 101328.
4. Timor-Tritsch IE, Monteagudo A, Santos R, et al. The diagnosis, treatment, and follow-up of cesarean scar pregnancy. *Am J Obstet Gynecol* 2012; 207(1): 44.e1–e13.

5. Ash A, Smith A and Maxwell D. Caesarean scar pregnancy. *BJOG* 2007; 114(3): 253–263.
6. Timor-Tritsch IE and Monteagudo A. Unforeseen consequences of the increasing rate of cesarean deliveries: early placenta accreta and cesarean scar pregnancy. A review. *Am J Obstet Gynecol* 2012; 207(1): 14–29.
7. Maymon R, Halperin R, Mendlovic S, et al. Ectopic pregnancies in a Caesarean scar: review of the medical approach to an iatrogenic complication. *Hum Reprod Update* 2004; 10(6): 515–523.
8. Timor-Tritsch IE, Monteagudo A, Cali G, et al. Cesarean scar pregnancy and early placenta accreta share common histology. *Ultrasound Obstet Gynecol* 2014; 43(4): 383–395.
9. Vial Y, Petignat P and Hohlfeld P. Pregnancy in a cesarean scar. *Ultrasound Obstet Gynecol* 2000; 16(6): 592–593.
10. Jordans IPM, Verberkt C, De Leeuw RA, et al. Definition and sonographic reporting system for Cesarean scar pregnancy in early gestation: modified Delphi method. *Ultrasound Obstet Gynecol* 2022; 59(4): 437–449.
11. Timor-Tritsch I, Buca D, Di Mascio D, et al. Outcome of cesarean scar pregnancy according to gestational age at diagnosis: a systematic review and meta-analysis. *Eur J Obstet Gynecol Reprod Biol* 2021; 258: 53–59.
12. Stabile G, Zinicola G, Romano F, et al. Management of non-tubal ectopic pregnancies: a single center experience. *Diagnostics (Basel)* 2020; 10(9): 652.
13. Knapman BL, Forgues MAS, Abbott JA, et al. Other treatments for CSP. *Best Pract Res Clin Obstet Gynaecol* 2023; 90: 102367.
14. Page MJ, McKenzie JE, Bossuyt PM, et al. The PRISMA 2020 statement: an updated guideline for reporting systematic reviews. *BMJ* 2021; 10(1): 89.
15. Kalampokas E, Boutas I, Panoulis K, et al. Novel medical therapy of cesarean scar pregnancy with a viable embryo combining multidose methotrexate and mifepristone: a case report. *Medicine (Baltimore)* 2015; 94(41): e1697.
16. Pristavu A, Vinturache A, Mihalceanu E, et al. Combination of medical and surgical management in successful treatment of caesarean scar pregnancy: a case report series. *BMC Pregnancy Childbirth* 2020; 20(1): 617.
17. Gómez García MT, Ruiz Sánchez E, Aguarón Benítez G, et al. Caesarean scar ectopic pregnancy successfully treated with methotrexate and mifepristone. *J Obstet Gynaecol* 2015; 35(1): 105–106.
18. Storgaard T, Frandsen KH and Lauszus FF. En graviditet i en sectiocikatrice—mange behandlingsmuligheder [Caesarean section scar pregnancy—various treatment alternatives]. *Ugeskr Laeger* 2006; 168(34): 2820–2821.
19. Zhang Y, Gu Y, Wang JM, et al. Analysis of cases with cesarean scar pregnancy. *J Obstet Gynaecol Res* 2013; 39(1): 195–202.
20. Stabile G, Romano F, Zinicola G, et al. Interstitial ectopic pregnancy: the role of mifepristone in the medical treatment. *Int J Environ Res Public Health* 2021; 18(18): 9781.
21. Bartels HC, Brennan DJ, Timor-Tritsch IE, et al. Global variation and outcomes of expectant management of CSP. *Best Pract Res Clin Obstet Gynaecol* 2023; 89: 102353.
22. Cali G, Timor-Tritsch IE, Palacios-Jaraquemada J, et al. Outcome of Cesarean scar pregnancy managed expectantly: systematic review and meta-analysis. *Ultrasound Obstet Gynecol* 2018; 51(2): 169–175.
23. Wang YL, Su TH and Chen HS. Operative laparoscopy for unruptured ectopic pregnancy in a caesarean scar. *BJOG* 2006; 113(9): 1035–1038.
24. Kłobuszewski B, Szmygin M, Nieoczym K, et al. Advances in treating cesarean scar pregnancy: a comprehensive review of techniques, clinical outcomes, and fertility preservation. *Med Sci Monit* 2024; 30: e943550.
25. Pickett CM, Minalt N, Higgins OM, et al. A laparoscopic approach to cesarean scar ectopic pregnancy. *Am J Obstet Gynecol* 2022; 226(3): 417–479.
26. Robinson JK, Dayal MB, Gindoff P, et al. A novel surgical treatment for cesarean scar pregnancy: laparoscopically assisted operative hysteroscopy. *Fertil Steril* 2009; 92(4): 1497.e13–1497.e16.
27. Kathopoulis N, Chatzipapas I, Samartzis K, et al. Laparoscopic management of cesarean scar pregnancy: Report of two cases with video-presentation of different operative techniques and literature review. *J Gynecol Obstet Hum Reprod* 2021; 50(8): 102066.
28. Wang G, Liu X, Bi F, et al. Evaluation of the efficacy of laparoscopic resection for the management of exogenous cesarean scar pregnancy. *Fertil Steril* 2014; 101(5): 1501–1507.
29. Wang JH, Xu KH, Lin J, et al. Methotrexate therapy for cesarean section scar pregnancy with and without suction curettage. *Fertil Steril* 2009; 92(4): 1208–1213.
30. Kim YR and Moon MJ. Ultrasound-guided local injection of methotrexate and systemic intramuscular methotrexate in the treatment of cesarean scar pregnancy. *Obstet Gynecol Sci* 2018; 61(1): 147–153.
31. Koch M, Schwab S, Meyer E, et al. Management of uterine ectopic pregnancy—local vs. systemic methotrexate. *Acta Obstet Gynecol Scand* 2018; 97(7): 824–829.
32. Revzin MV, Pellerito JS, Moshiri M, et al. Use of methotrexate in gynecologic and obstetric practice: what the radiologist needs to know. *Radiographics* 2021; 41(6): 1819–1838.
33. Stabile G, Romano F, Buonomo F, et al. Conservative treatment of interstitial ectopic pregnancy with the combination of mifepristone and methotrexate: our experience and review of the literature. *Biomed Res Int* 2020; 2020: 8703496.