



## Case report

## Mycobacterium tuberculosis concealed by enterococcal sacroiliitis

Raguraj Chandradevan, Hironobu Takeda, Tanna Lim, Nidhip Patel\*

Graduate Medical Education-Northside Hospital Gwinnett, Lawrenceville, GA, USA



## ARTICLE INFO

## Article history:

Received 18 May 2020

Received in revised form 29 May 2020

Accepted 29 May 2020

## Keywords:

Musculoskeletal tuberculosis

Diagnostic delays

Iliopsoas abscess

## ABSTRACT

A 77-year-old African American female with rheumatoid arthritis presented with fever and unsteady gait. She was started on broad-spectrum antimicrobials due to CT evidence for sacroiliitis and psoas abscess and underwent partial excision of her sacroiliac bone and drainage of the abscess. One of four blood cultures grew *Enterococcus faecalis* and the patient was sent home with intravenous ampicillin for 6 weeks. Two days after antimicrobial completion, the patient presented with night sweats and weakness. Chest x-ray revealed new right upper lobe pulmonary infiltrates, and the AFB culture sent during her prior admission returned positive for TB. RIPE therapy with moxifloxacin was initiated. Although she responded well to treatment, she retained functional immobility. We report a case of musculoskeletal TB initially misdiagnosed as enterococcus sacroiliitis, resulting in a delayed initiation of anti-tuberculous therapy. A high index of suspicion and rapid detection with TB-PCR testing should be considered to avoid delayed diagnosis.

© 2020 The Authors. Published by Elsevier Ltd. This is an open access article under the CC BY-NC-ND license (<http://creativecommons.org/licenses/by-nc-nd/4.0/>).

## Introduction

Tuberculosis is a leading cause of death worldwide [1]. Even though considerable progress has been made in reducing incidence in United States, the goal of eliminating the disease from the US remains elusive [2]. Lengthy treatment duration and delay in diagnosis are associated with multidrug-resistant and extensively drug-resistant tuberculosis. Proactive screening for tuberculosis using best available diagnostics, making accurate and early diagnoses of drug-sensitive or drug-resistant tuberculosis, and initiating appropriate treatment are crucial steps to reduce morbidity and further transmission within the community [3]. Approximately 20–30% of reported cases purely involve extrapulmonary sites. Skeletal tuberculosis is reported in 3–5% of cases [4]. The lack of suspicion, long culture period, and scant experience of providers accounts for a delay between the initial symptoms and the definite diagnosis of skeletal tuberculosis [5]. Our case represents the presence of another organism with tuberculosis, creating a diagnostic dilemma of musculoskeletal tuberculosis and explains the usefulness of rapid detection with TB-PCR to avoid the delay in diagnosis.

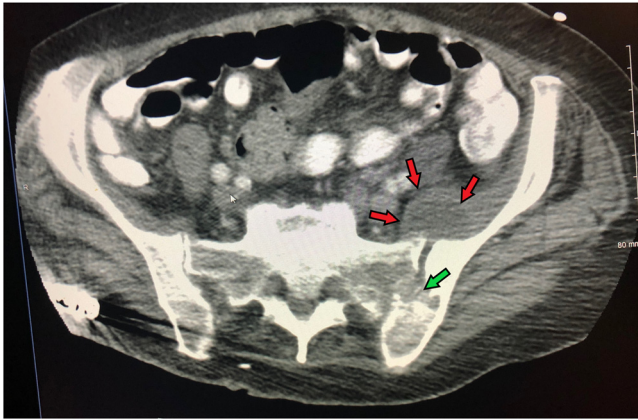
## Case report

A 77-year-old African American female with hypertension and rheumatoid arthritis on chronic prednisone therapy presented to the hospital with fever, weakness, and unsteady gait. The patient had a history of latent tuberculosis infection reportedly treated over 15 years ago, and abdominal lymphadenopathy with granulomatous histology of unknown etiology three years ago. Laboratory testing showed normal hemoglobin, elevated leukocyte count of 35,000 cells/ $\mu$ L, and normal C-reactive protein (CRP) and erythrocyte sedimentation rate (ESR). Her liver and kidney function were normal, and electrolytes were within normal limits. Physical examination revealed high fever and limited left hip mobility due to weakness and pain. Computed tomography of the hip joint revealed progressive destruction of her sacroiliac joint and a 10 × 8 × 7-centimeter (cm) fluid collection in front of her left iliopsoas muscle (Figs. 1 and 2). A presumptive diagnosis of pyogenic sacroiliitis and psoas abscess were made and the patient was placed on broad-spectrum antimicrobials.

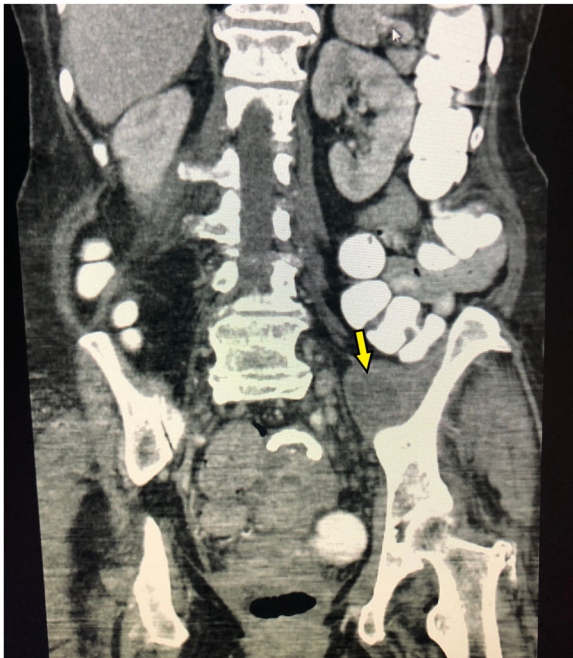
The patient underwent saucerization and partial excision of her left ilium and sacrum, surgical placement of antimicrobial beads, and drainage of the psoas abscess. Biopsy from the bone and drainage from the psoas abscess were also sent for further evaluation. The bone biopsy revealed ill-defined granulomas and the gram stain, AFB stain, GMS stain, and bacterial cultures of the psoas drainage were negative. Samples were sent for tuberculosis and fungal cultures. One out of four blood culture bottles grew *Enterococcus faecalis* sensitive to ampicillin. Given that all other

\* Corresponding author at: Internal Medicine/Graduate Medical Education, Northside Hospital Gwinnett, 1000 Medical Center Blvd, Lawrenceville, GA, 30046, USA.

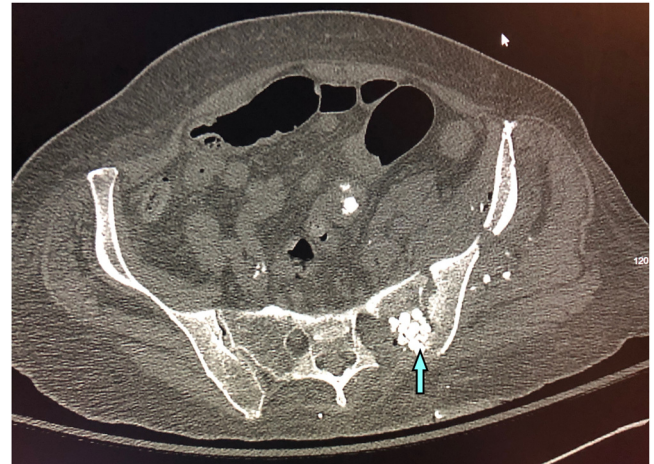E-mail address: [nidhip.patel@northside.com](mailto:nidhip.patel@northside.com) (N. Patel).



**Fig. 1.** Left psoas abscess (red arrows) and destructive sacroiliac joint (green arrow) in an axial computed tomography scan with intravenous contrast (For interpretation of the references to colour in this figure legend, the reader is referred to the web version of this article.).



**Fig. 2.** Coronal section in an abdomen and pelvis computed tomography scan with intravenous contrast showing the left psoas abscess.



**Fig. 3.** Axial computed tomography film with intravenous contrast during the second presentation showing post surgical drainage and antimicrobial beads placed (blue) (For interpretation of the references to colour in this figure legend, the reader is referred to the web version of this article.).

The patient did not present with respiratory symptoms; however, she was placed in respiratory isolation and sputum was tested for AFB. She was started on rifampin, isoniazid, pyrazinamide and ethambutol (RIPE) therapy, with the addition of moxifloxacin to also cover for multi-drug resistant tuberculosis (MDR-TB). The patient's fever subsided after one week of treatment, and after two weeks of treatment she markedly improved and had negative AFB smear and PCR on induced sputum. She was released from isolation precautions and discharged with follow up with the public health department. At the time of discharge, the patient exhibited functional decline and deconditioning due to prolonged hospital stay as well as chronic debilitating illness. She was assessed by physical therapy using Barthel Index score which is a measurement of activities of daily living and revealed a value of 45 points and partially independent. She was placed in a sub-acute rehabilitation facility after inpatient hospital discharge.

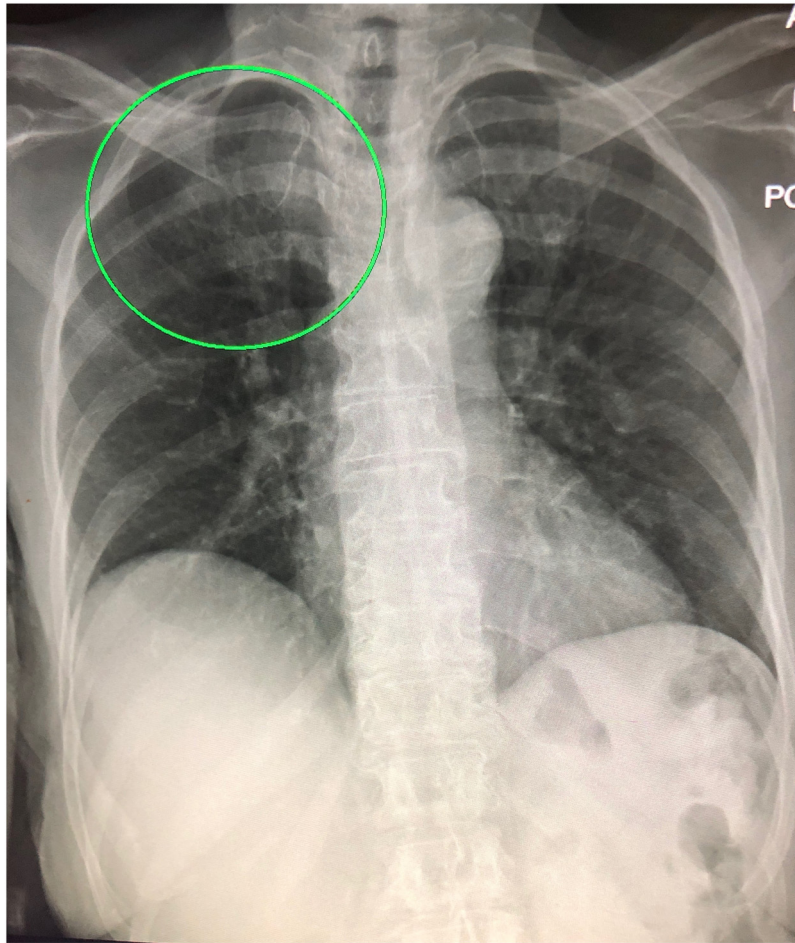
## Discussion

In skeletal tuberculosis, the onset of symptoms is generally insidious, and not accompanied by alarming general manifestations such as fever, night sweats or extreme weakness [6]. In tuberculous sacroiliitis, there is usually considerable delay between presentation and diagnosis, mainly due to its insidious onset, nonspecific clinical picture, and low clinical index of suspicion. Studies have reported a mean time from symptom onset to diagnosis of 8 months in a series of sacroiliac joint tuberculosis [7]. The diagnosis in our patient was also delayed for 6 weeks despite the recognition and drainage of psoas abscess and pathological analysis of debrided tissue. This is probably due to an atypical clinical picture of tuberculosis and presence of concomitant bacteremia.

A definitive diagnosis of skeletal tuberculosis can be made based on findings of the culture and pathological tests of infected tissues, but these cultures are only positive at a rate of 50–75 %, making bacteriologic confirmation of the disease very difficult [8]. RT-PCR assays have a high degree of sensitivity, making them a suitable test to rule out TB infection. RT-PCR assays demonstrate rapidity of detection of TB, which is an important factor in initiating early and appropriate anti-tuberculosis therapy. PCR can play an important role in rapid and accurate diagnosis of extrapulmonary tuberculosis. The percentage of specimen positive

testing was negative, the patient was sent to a nursing home with intravenous ampicillin therapy for a six-week course. Two days after completing treatment, the patient presented to the hospital again with recurrence of symptoms especially with nightly high fevers and weakness. Laboratory findings were only significant for an elevated WBC of 12,000 cells/ $\mu$ L. CT revealed healing sacroiliitis, no obvious new abscess, and post-surgical placement of antimicrobial beads (Fig. 3). Initial consideration was incomplete treatment given the timing of the symptoms after cessation of antimicrobials; however, the previous AFB culture coincidentally was found to be positive in the seventh week, and TB was confirmed by PCR from the culture positive samples. During the initial encounter, the patient underwent a CXR as a routine work up which didn't show any infiltrates; however during further work up after the AFB culture, a CXR was repeated and revealed new right upper lobe infiltrates suggestive of pulmonary tuberculosis (Fig. 4).





**Fig. 4.** Postero-anterior chest X ray film showing right upper lobe infiltrates.

by smear, culture, and PCR was 20.3%, 23.6 %, and 45.3%, respectively, for the diagnosis of extrapulmonary tuberculosis in one study [9].

The rapid results of PCR aid in early institution of anti-tuberculosis treatment and thus controlling the spread of disease. Further, in this case, it was difficult to detect the tubercle bacilli until the culture became positive. Moreover, we were hesitant to start anti-tuberculosis medications in the setting of enterococcal bacteremia. During the six weeks course of treatment patient did not have a fever and pain was markedly reduced to ease her participation in physical therapy. We believe this is due to radical debridement of the sacroiliitis and treatment response to co-existing bacterial sacroiliitis. Presence of tuberculosis with bacterial infections in immunocompetent patients has been reported in the past, and we believe our patient acquired concomitant infectious processes with enterococcal bacteremia and mycobacteria infection [10]. Negative bacterial culture and stains from the abscess, enterococcal bacteremia and treatment response with ampicillin appropriately dictated immediate antimicrobial therapy; however, it caused anchoring to a diagnosis without considering the patient's high risk for concomitant TB.

In the case of an elderly woman with known TB exposure, chronic immunosuppression secondary to prednisone therapy, pyogenic abscess to an area typical for TB, granulomatous pathology of bone biopsy, and previous biopsy with granulomatous nodules in the abdomen should have led to earlier PCR testing or empiric TB treatment on initial presentation. TB is a slow growing acid-fast bacillus and waiting for culture results can cause a delay in diagnosis and further morbidity, as in our case.

## Conclusion

Tuberculous sacroiliitis is a disabling condition and can often be overlooked. Keeping a high index of suspicion for TB in high-risk individuals and considering more rapid detection with TB-PCR testing should be considered to avoid delayed diagnosis and increased morbidity from delay in treatment.

## Author contributions

Raguraj Chandradevan helped conceptualize the paper, contributed to data acquisition, wrote the manuscript, and reviewed and approved the final manuscript.

Hironobu Takeda and Tanna Lim helped conceptualize the paper, contributed to data acquisition, and reviewed and approved the final manuscript.

Nidhip Patel is the investigator of this project and responsible for the overall conduct, results and conclusions of the paper. He conceptualized the paper, contributed to the manuscript, and reviewed and approved the final manuscript.

## Funding

There was no funding or sponsorship for this report.

## Ethical approval

This study was approved by Graduate Medical Education at Northside Hospital Gwinnett.

## Consent

We obtained the patient's consent to publish the case report. The patient accepts the publication of this case report.

## Declaration of Competing Interest

The authors have no financial relationships relevant to this article to disclose. The authors have no conflicts of interest to disclose.

## References

- [1] Glaziou P, Sismanidis C, Floyd K, Raviglione M. Global epidemiology of tuberculosis. *Cold Spring Harb Perspect Med* 2014;5(2):a017798.
- [2] Langer AJ, Navin TR, Winston CA, LoBue P. Epidemiology of tuberculosis in the United States. *Clin Chest Med* 2019;40(4):693–702.
- [3] Gilpin C, Korobitsyn A, Weyer K. Current tools available for the diagnosis of drug-resistant tuberculosis. *Ther Adv Infect Dis* 2016;3(6):145–51.
- [4] Pigrau-Serrallach C, Rodriguez-Pardo D. Bone and joint tuberculosis. *Eur Spine J* 2013;22(Suppl 4):556–66.
- [5] Broderick C, Hopkins S, Mack DJF, Aston W, Pollock R, Skinner JA, et al. Delays in the diagnosis and treatment of bone and joint tuberculosis in the United Kingdom. *Bone Joint J* 2018;100-B(1):119–24.
- [6] Garg RK, Somvanshi DS. Spinal tuberculosis: a review. *J Spinal Cord Med* 2011;34(5):440–54.
- [7] Zhu G, Jiang LY, Yi Z, Ping L, Duan CY, Yong C, et al. Sacroiliac joint tuberculosis: surgical management by posterior open-window focal debridement and joint fusion. *BMC Musculoskelet Disord* 2017;18(1):504.
- [8] Smith I. Mycobacterium tuberculosis pathogenesis and molecular determinants of virulence. *Clin Microbiol Rev* 2003;16(3):463–96.
- [9] Raveendran R, Wattal C. Utility of multiplex real-time PCR in the diagnosis of extrapulmonary tuberculosis. *Braz J Infect Dis* 2016;20(3):235–41.
- [10] Attia EF, Pho Y, Nhem S, Sok C, By B, Phann D, et al. Tuberculosis and other bacterial co-infection in Cambodia: a single center retrospective cross-sectional study. *BMC Pulm Med* 2019;19(1):60.