

## REFERENCES

1. Ockenfels HM. Therapeutic management of cutaneous and genital warts. *J Dtsch Dermatol Ges.* 2016;14:892-9.
2. Word AP, Nezafati KA, Cruz PD Jr. Treatment of Warts With Contact Allergens. *Dermatitis.* 2015;26:32-7.
3. Suh DW, Lew BL, Sim WY. Investigations of the efficacy of diphenylcyclopropenone immunotherapy for the treatment of warts. *Int J Dermatol.* 2014;53:e567-71.
4. Choi MH, Seo SH, Kim IH, Son SW. Comparative study on the sustained efficacy of diphenylcyclopropenone immunotherapy versus cryotherapy in viral warts. *Pediatr Dermatol.* 2008;25:398-9.
5. Choi Y, Kim DH, Jin SY, Lee AY, Lee SH. Topical immunotherapy with diphenylcyclopropenone is effective and preferred in the treatment of periungual warts. *Ann Dermatol.* 2013;25:434-9.

**How to cite this article:** Souza BC, Ribeiro CP, Swiczar BCC, Pires MC. Diphencyprone as a therapeutic alternative to exuberant periungual warts. *An Bras Dermatol.* 2018;93(2):305-7.



## Metastatic pleomorphic dermal sarcoma: an uncommon skin tumour\*

Georgios Kravvas<sup>1</sup>  
David Veitch<sup>1</sup>  
Ian Thomas Logan<sup>1</sup>  
Conal Martin Perrett<sup>1</sup>

DOI: <http://dx.doi.org/10.1590/abd1806-4841.20187228>

A 69-year-old Caucasian male was referred to our department with a 3-month history of an enlarging, asymptomatic nodule on his forehead. Examination revealed a 15mm, shiny, erythematous nodule with no associated lymphadenopathy. Further examination was unremarkable. Excision biopsy with a 4mm peripheral surgical margin revealed a dermal-based atypical spindle cell tumour extending from the dermo-epidermal junction to the deep subcutaneous adipose tissue. There was no evidence of tumour necrosis, lymphovascular invasion or perineural infiltration. No expression of cytokeratins, S100, desmin, or CD34 immunohistochemical markers was found, but there was positive expression of CD10. The his-

tological margins were clear by 2mm peripherally and 1.2mm deep. Histopathological and immunohistochemical findings were consistent with the diagnosis of pleomorphic dermal sarcoma (Figure 1). The patient was followed up 3-monthly in a dedicated cutaneous sarcoma clinic. Six months after excision of the primary lesion, a new 5mm papule appeared on the excision scar (Figure 2). Repeat excision revealed recurrent pleomorphic dermal sarcoma with clear margins. The multidisciplinary team consensus was to treat this further with local adjuvant radiotherapy following a staging CT scan. At 7 months, staging CT revealed a new discrete nodule in the left lower lobe of the lung. CT-guided biopsy confirmed a CD10 positive spindle cell tumour consistent with metastatic pleomorphic dermal sarcoma. The patient subsequently died from pneumonia at 11 months following diagnosis, having been too unwell for palliative chemotherapy.

Pleomorphic dermal sarcoma (PDS), previously known as superficial malignant fibrous histiocytoma, or undifferentiated pleomorphic sarcoma of skin, is a rare dermal-based spindle cell tu-

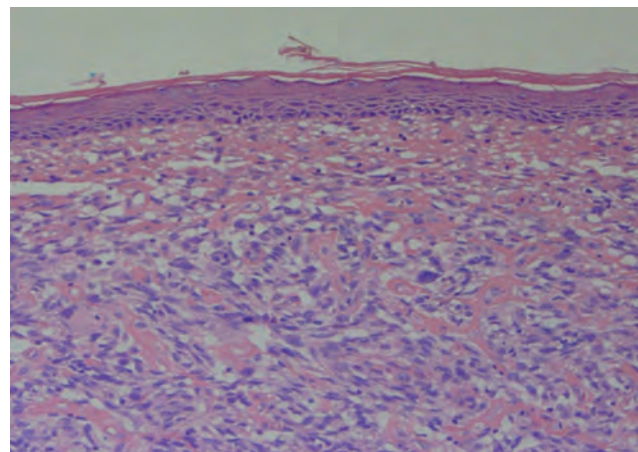


FIGURE 1: A dermal-based tumour comprised of intersecting fascicles of spindle cells with clear cytoplasm and moderate nuclear atypia (Hematoxylin & eosin, X100)

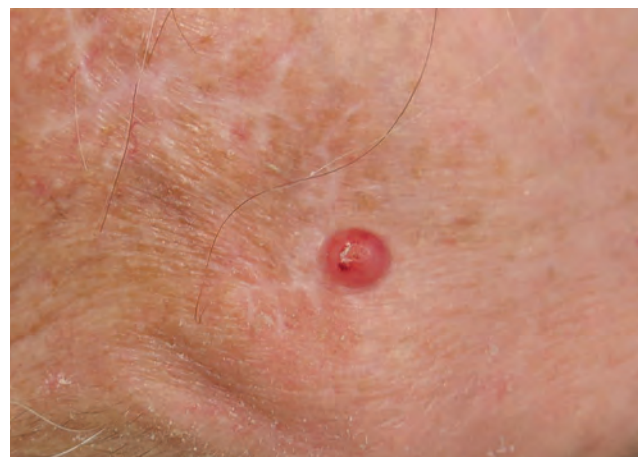

FIGURE 2: Shiny, erythematous papule with a central depression on the patient's forehead

Received on 01.05.2017.

Approved by the Advisory Board and accepted for publication on 01.10.2017.

\* Work performed at the Department of Dermatology, University College London Hospitals NHS Foundation Trust - London, United Kingdom.

Financial support: None.

Conflict of interest: None.

<sup>1</sup> Department of Dermatology, University College London Hospitals - London, United Kingdom.

MAILING ADDRESS:

Georgios Kravvas

E-mail: [kravvas@hotmail.com](mailto:kravvas@hotmail.com)

©2018 by Anais Brasileiros de Dermatologia



mour that may recur locally or metastasise.<sup>1</sup> The term pleomorphic dermal sarcoma was introduced to reclassify atypical fibroxanthoma (AFX)-like tumours that have additional high-risk features suggestive of a greater malignant potential.<sup>2</sup> Diagnostic differentiation from AFX requires the presence of one or more of: deep adipose tissue invasion, tumour necrosis, lymphovascular invasion, and/or perineural invasion.<sup>2</sup> Clinically, PDS is indistinguishable from AFX and appears to form part of a biological continuum, with PDS having a significantly higher rate of local recurrence and metastatic spread.<sup>1,3,4</sup> The first reported case series of PDS reviewed 32 cases and found tumour necrosis in 53%, lymphovascular invasion in 26%, and perineural infiltration in 29%, with CD10 expressed in all cases tested and a metastatic rate of 10%.<sup>3</sup> The second reported series of 18 patients with PDS found that tumours arose mainly on the scalp and face of elderly patients (median age 81).<sup>1</sup> Consistent histopathological features included spindle cells arranged in a fascicular pattern, and the presence of epithelioid and multinucleate giant cells with pleomorphic vesicular nuclei. Lesions in all patients demonstrated invasion to the subcutis with additional necrosis identified in 3 patients. Follow-up data revealed that 20% developed local recurrence and 20% distant metastases to the skin, lymph nodes, and/or lungs.<sup>1</sup>

Due to the predominant tumour location on the head and neck, complete histological clearance of the primary or recurrent tumour may be unachievable. Treatment with adjuvant radiotherapy may then be considered.<sup>4</sup> In large defects the initiation of adjuvant radiotherapy tends to be delayed whilst waiting for wound healing.<sup>5</sup> Müller *et al.* achieved successful graft healing without complications by treating a patient with an innovative technique where adjuvant radiotherapy was started immediately following excision and reconstruction performed subsequently.<sup>5</sup>

Our report highlights the risk of local recurrence and metastatic spread in this rare cutaneous tumour. Recognition of this greater malignant potential emphasises the need for evidence-based guidelines for the treatment of pleomorphic dermal sarcoma. □

#### REFERENCES

1. Tardío JC, Pinedo F, Aramburu JA, Suárez-Massa D, Pampín A, Requena L, et al. Pleomorphic dermal sarcoma: a more aggressive neoplasm than previously estimated. *J Cutan Pathol.* 2016;43:101-12.
2. McCalmont TH. Correction and clarification regarding AFX and pleomorphic dermal sarcoma. *J Cutan Pathol.* 2012;39:8.
3. Miller K, Goodlad JR, Brenn T. Pleomorphic dermal sarcoma: adverse histologic features predict aggressive behavior and allow distinction from atypical fibroxanthoma. *Am J Surg Pathol.* 2012;36:1317-26.
4. Davidson JS, Demsey D. Atypical Fibroxanthoma: Clinicopathological determinants for recurrence and implications for surgical management. *J Surg Oncol.* 2012;105:559-62.
5. Müller CS, Jungmann J, Pföhler C, Mohammad F, Rube C, Vogt T. Report on immediate irradiation of a rapidly growing sarcoma of the scalp prior to wound closure. *J Dtsch Dermatol Ges.* 2016;14:539-42.

**How to cite this article:** Kravvas G, Veitch D, Logan IT, Perrett CM. Metastatic pleomorphic dermal sarcoma: an uncommon skin tumour. *An Bras Dermatol.* 2018;93(2):307-8.

## Atypical aquagenic keratoderma treated with oxybutynin chloride\*

Niharika Dixit<sup>1</sup>  
Kabir Sardana<sup>1</sup>  
Sidharth Tandon<sup>1</sup>  
Yogita Singh<sup>1</sup>

DOI: <http://dx.doi.org/10.1590/abd1806-4841.20187262>

Dear Editor,

A 36-year-old male presented with a three-year history of thickened, dark coloured skin over dorsal aspect of hands, volar aspect of wrists and circumferentially around the ankles, which become whitish and wrinkled within a few minutes of sweating or immersion into water. There were no associated complaints of pruritus, burning sensation, pain or hyperhidrosis. Physical examination revealed well defined hyperpigmented, hyperkeratotic plaques over the above-mentioned sites, with sparing of palms and soles (Figure 1A and 1B). After immersing the hands in water for 5 minutes, the plaques became whitish, wrinkled and sodden (Figure 1C and 1D) and reverted back to the hyperpigmented morphology within 30 minutes. A diagnosis of aquagenic keratoderma was considered and a biopsy was done after immersion of hands in water for 5 minutes which was consistent with keratoderma.

The patient was started on oral oxybutynin chloride 2.5mg twice daily and after three weeks there was a substantial amelioration of the disorder even after exposure to water (Figure 2). The patient was continued on oxybutynin and a topical keratolytic (salicylic acid 12%) was initiated to promote a faster clinical response.

AK is a rare disorder affecting the palms and occasionally soles of adolescent females. It is an acquired disease, mostly spo-

Received on 12.06.2017.

Approved by the Advisory Board and accepted for publication on 17.09.2017.

\* Work performed at the Department of Dermatology, Venereology and Leprosy Dr. Ram Manohar Lohia Hospital and Post Graduate Institute of Medical Education and Research Baba Khark Singh Marg - New Delhi, India.

Financial support: None.

Conflict of interests: None.

<sup>1</sup> Department of Dermatology, Venereology and Leprosy Dr. Ram Manohar Lohia Hospital and Post Graduate Institute of Medical Education and Research - New Delhi, India.

MAILING ADDRESS:

Niharika Dixit

E-mail: [drniharikadixit@gmail.com](mailto:drniharikadixit@gmail.com)