

Retrospective study on the 7.5-year survival of resin-bonded dental prostheses in single missing second premolar cases

Ayça Deniz İzgi, Şebnem Eskimez¹, Ediz Kale²

Department of Prosthodontics, Faculty of Dentistry, Dicle University, Diyarbakir, ¹Private Practice, Cevatpaşa District, Velibey Street No: 16, Canakkale, ²Department of Prosthodontics, Faculty of Dentistry, Mustafa Kemal University, Hatay, Turkey

Abstract

Purpose: The purpose of this study is to report retrospectively the clinical results of cast metal slot-retained resin-bonded fixed dental prostheses (RBFDPs) used in the restoration of single missing second premolar teeth, as this kind of prostheses provides acceptable clinical outcomes in a minimally invasive and esthetic treatment for the average patient requiring cheaper and faster treatment alternative for a single missing posterior tooth. However, the data present in the literature are scarce.

Materials and Methods: Clinical follow-up was reported up to 7.5 years in nine different cast metal slot-retained RBFDPs patients of both genders between 21 and 49 years of age. Routine clinical controls were performed 6 and 12 months after treatment, followed by regular intervals every year afterward. The Kaplan–Meier survival estimation method was used to determine the overall and functional survival rates and times of the RBFDPs at the end of the observation period.

Results: At the end of the follow-up, all of the RBFDPs were still functional with a mean follow-up of 6.7 years. The Kaplan–Meier estimation for the overall survival was calculated as 89% for up to 7.5 years with one failure due to debonding. The functional survival rate was 100% with the lowest and highest observation periods being 5.8 and 7.5 years, respectively.

Conclusions: Within the limitations of this retrospective clinical study, it seems that the design and cementation regimen used for the RBFDPs presented can guarantee clinical success in the restoration of single missing second premolar teeth.

Key Words: Cast metal resin-bonded fixed dental prostheses, inlay slot cavity-retained resin-bonded fixed dental prostheses, inlay-retained resin-bonded fixed dental prostheses, posterior resin-bonded fixed dental prostheses, resin-bonded fixed dental prostheses

Address for correspondence:

Dr. Ediz Kale, Department of Prosthodontics, Faculty of Dentistry, Mustafa Kemal University, 31034 Hatay, Turkey. E-mail: dtedizkale@yahoo.com

Received: 23rd June, 2015, **Accepted:** 11th September, 2015

INTRODUCTION

Resin-bonded fixed dental prostheses (RBFDPs) have been known to the science and art of dentistry for more than three

decades. Treating patients with RBFDPs is preferred over conventional fixed dental prostheses (FDPs) with regard to the preservation of sound tooth structure and the reversibility of

Access this article online	
Quick Response Code:	Website: www.j-ips.org
	DOI: 10.4103/0972-4052.167936

This is an open access article distributed under the terms of the Creative Commons Attribution-NonCommercial-ShareAlike 3.0 License, which allows others to remix, tweak, and build upon the work non-commercially, as long as the author is credited and the new creations are licensed under the identical terms.

For reprints contact: reprints@medknow.com

How to cite this article: İzgi AD, Eskimez S, Kale E. Retrospective study on the 7.5-year survival of resin-bonded dental prostheses in single missing second premolar cases. J Indian Prosthodont Soc 2016;16:26-9.

the treatment,^[1] as well as over implant supported FDPs with regard to the reduction of stress, saving both time and money during the treatment procedure.^[2]

The concept of RBFDPs is not a new one, but the general opinion about the prognosis and functionality of these FDPs is that the existing evidence on this topic is far from clear.^[3,4] Today, it is known that significant modifications made to this treatment have contributed to the improvement of the clinical success of RBFDPs,^[5] and that the careful indication, design, preparation, and planning of this treatment are all important factors influencing the success of this kind of FDP.^[6]

Lately, one prospective study^[7] has reported the clinical results of the inlay-retained RBFDP design, utilizing inlay slot cavities to lock the prosthesis retainers into the abutment teeth, using tooth-colored restoratives after cementation. This design managed to provide acceptable clinical outcomes in a minimally invasive and esthetic treatment for the average patient requiring cheaper and faster treatment alternatives for a single missing molar.^[7] Unfortunately, this study was restricted to the absence of the first molars, and it would be interesting to determine the results if the edentulous span was shorter or the retention surface of the anterior retainer larger than those of the ones investigated.

The purpose of this study is to retrospectively report the clinical results of inlay-retained cast metal RBFDPs in tub-shaped inlay slot cavities filled with resin composite, to lock the restoration retainers into the abutments after the cementation process, in cases of single missing second premolar teeth.

MATERIALS AND METHODS

Nine patients suffering single missing second premolars, with a mean age of 28 ± 9 years, were treated with RBFDPs through the first half of 2002, in the Department of Prosthodontics, in a University Hospital [Table 1]. Ten years later, this retrospective study was conducted based on data already

available in patients’ files. Since the patients’ ID would not be revealed, approval of the Institutional Ethical Review Board was not sought. Nevertheless, informed written consents were taken from the patients prior to the treatment, which included the possibility of their data being used in the future in retrospective studies like this one.

The treatment options were discussed with each patient, and considering the low price and the reversible nature of the prosthesis, an RBFDP was decided on as the treatment of choice. The patients were periodontally healthy, maintaining good oral hygiene, with no large restorations or carious lesions. Canine guidance, with no parafunctional habits, was noted as the type of occlusion in the patients’ files. Prior to treatment in some patients, the existing restorations were removed, and the carious lesions were treated using minimally invasive techniques and adhesive restorative materials. None of the pretreated patients had proximal decay on the abutments at the potential RBFDP restoration region.

The procedures, regarding the preparation, tryout, and delivery of the prostheses, were completed by an experienced dental professional in the field of RBFDPs, exactly as described in a previously published clinical study,^[7] using the same materials and methods. The only difference was in the mesiodistal and buccolingual dimensions of the prosthesis pontics, since the missing tooth was a premolar and not a molar [Figures 1 and 2].

Nine tub-shaped slot-retained cast metal-inlay RBFDPs, with porcelain fused-to-metal pontics for the missing maxillary or mandibular second premolars in the patients, were followed-up through 6 months, and then annually after placement. This continued until a patient did not show up for more than 2 years after the last routine control, and no contact could be

Table 1: Description of patients and survival of RBFDPs

Patient number (n=9)	Gender	Age of patient	Location of prosthesis	Overall survival of prosthesis (years)	Functional survival of prosthesis (years)
1	♀	49	Maxillary right	6.6	6.6
2	♀	26	Mandibular right	7.1	7.1
3	♀	21	Maxillary right	7.0	7.0
4	♀	34	Maxillary left	0.5*	6.5
5	♀	24	Maxillary left	6.6	6.6
6	♂	23	Maxillary right	7.0	7.0
7	♂	30	Maxillary right	6.4	6.4
8	♀	26	Maxillary left	5.8	5.8
9	♀	22	Maxillary right	7.5	7.5

n: RBFDP number. *RBFDP failure. RBFDP: Resin-bonded fixed dental prostheses

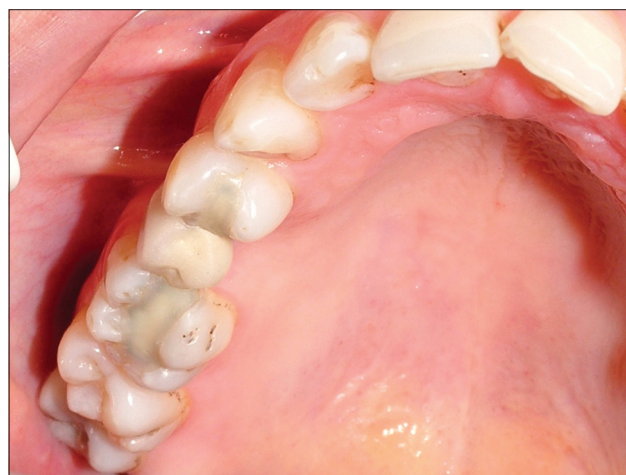

Figure 1: Occlusal view of cast metal-inlay slot cavity-retained resin-bonded fixed dental prostheses for a single missing maxillary right second premolar *in situ* (courtesy of Dr. İzgi)

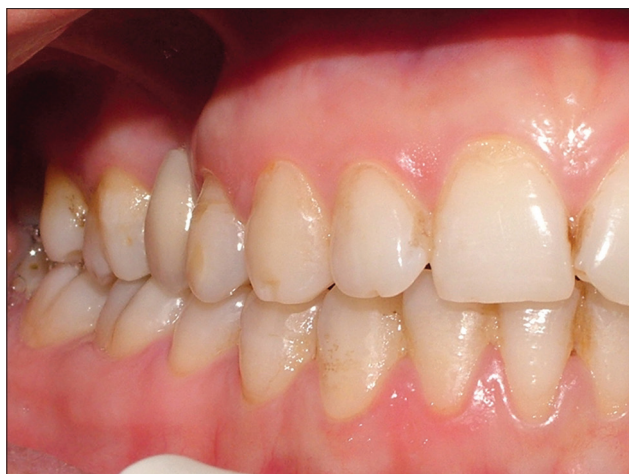

Figure 2: Buccal view of cast metal-inlay slot cavity-retained resin-bonded fixed dental prostheses for a single missing maxillary right second premolar *in situ* (courtesy of Dr. İzgi)

established via the personal telephone records present in the patient's file.

During the annual examinations, the periodontal and pulpal health was checked, secondary caries were searched, subjective complaints of the patients were noted, and emphasis on the importance of oral hygiene was made as in regular examinations. The debonding or fracture of the RBFDPs was considered to be a treatment failure. If rebonding was possible for a failed RBFDP, it was assumed to be a functional one, and the observation sequence was continued after rebonding using the same cementation regimen as at the beginning of the treatment.

The Kaplan–Meier estimation was used by means of statistical software to calculate the overall (survival time elapsed until failure) and functional (survival time, ignoring failure if rebonding was assured) survival performance of the RBFDPs after the last patient was lost to follow-up. The exact time of the “ending” of an RBFDP of a lost patient was assumed to be the last clinical check-up of the RBFDP according to the patient's records.

RESULTS

Nine RBFDPs were still functional in all patients at the end of the follow-up. Only one of the prostheses (patient #4) debonded after 6 months of service [Table I]. It was rebonded following the same sequence of cementation used during the first placement and did not debond again. The Kaplan–Meier overall survival probability was calculated to be 6.72 years (SE: 0.73, 95% CI: 5.29 and 8.16) with a survival rate of 88.9% for up to 7.5 years. Rebonding of the failed restoration increased the functional survival rate to 100% with minimum and maximum observational periods of 5.8 and 7.5 years (mean follow-up of 6.7 ± 0.5 years), respectively [Figure 3 and Table I].

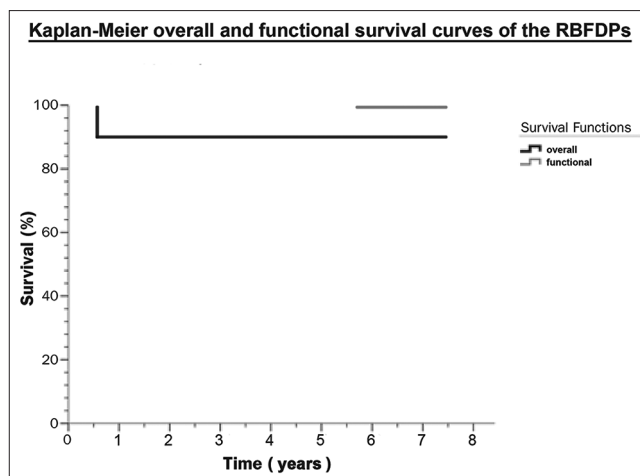


Figure 3: Overall and functional survival estimation of the resin-bonded fixed dental prostheses at the end of the follow-up

During the routine examinations, none of the patients reported subjective complaints regarding sensitivity or pain. The periodontal parameters of the abutments such as gingival bleeding, plaque accumulation, and pocket depth were all in very good condition clinically throughout the follow-up. No secondary caries were detected in any of the abutments, and the patients never expressed dissatisfaction with regard to the functionality or esthetic appearance of their prostheses.

DISCUSSION

Minimally invasive with less complicated clinical requirements and reduced chair-time and expenses, the RBFDP remains a viable alternative to short-span restoration, especially when long-term provisionalization is indicated.^[4,6,8] Nevertheless, reliable data regarding the clinical performance of the RBFDPs is still lacking.

The RBFDP design of this study has recently been described in a prospective clinical trial,^[7] and the clinical results derived have been extensively discussed with regard to the other reasonable treatment alternatives.^[7] No other data regarding this exact design is present in the literature today. The RBFDP designs reported until now in different *in vivo* studies have been presented in great variety, which makes the comparisons very difficult.

The purpose of this design was the elimination of sound tooth structure loss, with respect to the periodontal wellness, improvement of esthetics, and benefit of retention provided by the resin composite packed into inlay cavities over the prosthesis retainers.^[7] As the design proved to render these objectives under controlled clinical conditions,^[7] the results of this retrospective study completely correlated with the results of that previous publication.^[7]

The debonding of an RBFDP in the current study after only 6 months of service seems justified, considering the attribution of this phenomenon to the technique-sensitive cementation procedures of the RBFDPs,^[9] and since early debonding was also reported previously in a similar clinical study.^[7] The absence of porcelain pontic fractures and secondary marginal caries reveals the ability to maintain good periodontal health with these RBFDPs in accordance with the previously published literature.^[7,10,11]

In the current study, the Kaplan–Meier estimation of the RBFDPs for single missing second premolars yielded an 89% overall survival rate for up to 7.5 years with a mean survival time of 6.7 years. This result is much better than the 76% rate of the RBFDPs for single missing first molars followed for up to 7.7 years with a mean survival time of 6.8 years.^[7] The functional survival rate of the current study presented a 100% success rate with no failures, whereas the functional survival rate for the missing first molars according to the Kaplan–Meier estimation showed an 83% survival rate.^[7] In fact, these findings corroborate the results for the missing molars if it is assumed that the present study has less than 1/3 of the sample size of the molar study,^[7] and that this is only a noncontrolled retrospective clinical observation.

Among the main limitations of the present study, the small sample size and noncontrolled nature of the follow-ups can be mentioned as having a great importance for not being able to draw strongly objective conclusions at the end of the observation period. However, studies reporting survival estimations for RBFDPs with even smaller sample sizes also exist.^[12] Not having performed regular radiographic controls on the annual recalls in order to check for deep caries formation may give speculative results mentioning the absence of secondary caries, yet the conclusion was drawn only as a result of clinical examination and taking into account the patients' complaints, and no radiological involvement was ever sought unless a symptom was present to justify for the exposure of the patients to ionizing radiation. More well-designed prospective controlled clinical studies are needed in the future to enlighten the inside of the clinical success of these specially designed RBFDPs. However, it seems that cast metal slot-retained RBFDP treatment anyway guarantees a high potential for clinical success, being a minimally invasive, reversible, time and cost-effective treatment alternative at least for the long-term provisionalization of single missing second premolars.

CONCLUSION

Considering the limitations of the present clinical study, the following conclusions can be made; (1) The design and cementation procedure used for these RBFDPs can guarantee even higher clinical success, when utilized in shorter edentulous spans, (2) debonding remains as the major failure type for this kind of RBFDPs, although not being frequent nevertheless with potential of occurring early attributed to the complexity of the cementation regimen. These RBFDPs can reliably serve as long-term temporary restorations for single missing second premolar teeth.

Financial support and sponsorship

Nil.

Conflicts of interest

There are no conflicts of interest.

REFERENCES

1. Ketabi AR, Kaus T, Herdach F, Groten M, Axmann-Krcmar D, Pröbster L, et al. Thirteen-year follow-up study of resin-bonded fixed partial dentures. *Quintessence Int* 2004;35:407-10.
2. Pröbster B, Henrich GM. 11-year follow-up study of resin-bonded fixed partial dentures. *Int J Prosthodont* 1997;10:259-68.
3. Creugers NH, De Kanter RJ, Verzijden CW, Van't Hof MA. Risk factors and multiple failures in posterior resin-bonded bridges in a 5-year multi-practice clinical trial. *J Dent* 1998;26:397-402.
4. Zalkind M, Ever-Hadani P, Hochman N. Resin-bonded fixed partial denture retention: A retrospective 13-year follow-up. *J Oral Rehabil* 2003;30:971-7.
5. Wyatt CC. Resin-bonded fixed partial dentures: What's new? *J Can Dent Assoc* 2007;73:933-8.
6. el-Mowafy O, Rubo MH. Resin-bonded fixed partial dentures – A literature review with presentation of a novel approach. *Int J Prosthodont* 2000;13:460-7.
7. Izgi AD, Kale E, Eskimez S. A prospective cohort study on cast-metal slot-retained resin-bonded fixed dental prostheses in single missing first molar cases: Results after up to 7.5 years. *J Adhes Dent* 2013;15:73-84.
8. Pjetursson BE, Tan K, Lang NP, Brägger U, Egger M, Zwahlen M. A systematic review of the survival and complication rates of fixed partial dentures (FPDs) after an observation period of at least 5 years. *Clin Oral Implants Res* 2004;15:625-42.
9. Göhring TN, Roos M. Inlay-fixed partial dentures adhesively retained and reinforced by glass fibers: Clinical and scanning electron microscopy analysis after five years. *Eur J Oral Sci* 2005;113:60-9.
10. Kiliçarslan MA, Kedici PS, Küçükmesmen HC, Uludag BC. *In vitro* fracture resistance of posterior metal-ceramic and all-ceramic inlay-retained resin-bonded fixed partial dentures. *J Prosthet Dent* 2004;92:365-70.
11. Stokholm R, Isidor F. Resin-bonded inlay retainer prostheses for posterior teeth. A 5-year clinical study. *Int J Prosthodont* 1996;9:161-6.
12. Izgi AD, Eskimez S, Kale E, Deger Y. Directly fabricated inlay-retained glass- and polyethylene fiber-reinforced composite fixed dental prostheses in posterior single missing teeth: A short-term clinical observation. *J Adhes Dent* 2011;13:383-91.