

Nickel allergic contact dermatitis

Mingang Zhu MD, Angela Vinturache MD PhD, Guodong Ding MD PhD

■ Cite as: *CMAJ* 2022 August 29;194:E1136. doi: 10.1503/cmaj.220260

A 41-year-old man presented to the dermatology clinic with a 1-month history of erythematous, pruritic papules on the abdomen. The periumbilical skin had 2 symmetric erythematous plaques with overlying scaly, hyperkeratotic tissue and eczematous papules (Figure 1A). The lesions were confined to the skin in contact with a metallic belt buckle purchased 3 months before. Positive patch test (++) for nickel sulfate (5.0%) in petroleum confirmed contact dermatitis to nickel (Appendix 1, available at www.cmaj.ca/lookup/doi/10.1503/cmaj.220260/tab-related-content). We prescribed a 7-day course of mometasone furoate (0.1%) cream, which led to a substantial improvement (Figure 1B). We recommended that the patient avoid future contact with nickel-containing accessories and use brass or plastic fasteners, belts and buckles instead.

A meta-analysis of 20 000 people from the general population who were patch tested confirmed a 20% prevalence of contact allergy, with nickel being the most common allergen (11.4%).¹ Prevalence is higher in women and people with atopic disorders.² Nickel allergic contact dermatitis results from a type IV cutaneous hypersensitivity reaction, although symptoms can occur within the first 30 minutes of exposure.³ Prolonged contact with the skin, sweat and friction can induce subclinical maceration and release of nickel into the skin.

Differential diagnoses include scabies, impetigo, psoriasis, inflammatory dermatoses, mycosis fungoides, tinea corporis, atopic dermatitis and fixed drug eruptions.⁴ Presentation varies from mild dermatitis with pruritus, deep erythema with oozing and papulation, to a systemic reaction with generalized idiopathic hypersensitivity. Patch testing can confirm the etiologic agent, and skin biopsy may help if the diagnosis is uncertain. Standard treatment is to remove the source object and prescribe topical corticosteroids.⁵ Calcineurin inhibitors (i.e., tacrolimus) can be considered for steroid-resistant cases, and oral steroids or antihistamines to aid in symptom resolution.

References

1. Alinaghi F, Bennike NH, Egeberg A, et al. Prevalence of contact allergy in the general population: a systematic review and meta-analysis. *Contact Dermatitis* 2019;80:77-85.
2. Warsaw EM, Zhang AJ, DeKoven JG, et al. Epidemiology of nickel sensitivity: retrospective cross-sectional analysis of North American Contact Dermatitis Group data 1994-2014. *J Am Acad Dermatol* 2019;80:701-13.

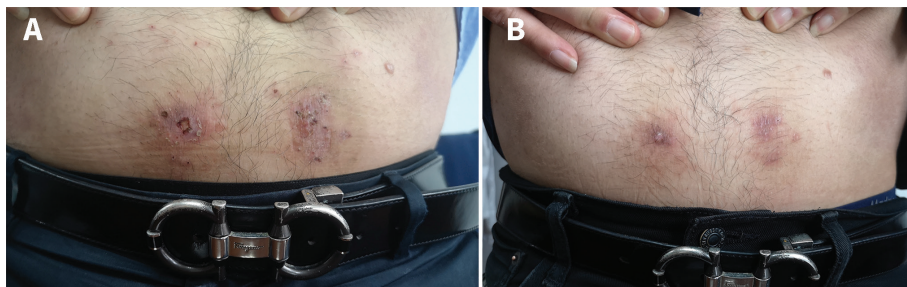


Figure 1: Nickel allergic contact dermatitis: (A) Periumbilical skin of a 41-year-old man with 2 erythematous plaques with overlying pruritic and eczematous papules. (B) A marked improvement was observed after 1 week of using a topical corticosteroid.

3. Saito M, Arakaki R, Yamada A, et al. Molecular mechanisms of nickel allergy. *Int J Mol Sci* 2016;17:202.
4. Tuchman M, Silverberg JI, Jacob SE, et al. Nickel contact dermatitis in children. *Clin Dermatol* 2015;33:320-6.
5. Silverberg NB, Pelletier JL, Jacob SE, et al; Section on Dermatology, Section on Allergy and Immunology. Nickel allergic contact dermatitis: identification, treatment, and prevention. *Pediatrics* 2020;145:e20200628.

Competing interests: None declared.

This article has been peer reviewed.

The authors have obtained patient consent.

Affiliations: Department of Dermatology (Zhu), the First People's Hospital of Jiashan, Jiashan, Zhejiang, China; Department of Obstetrics & Gynecology (Vinturache), Grande Prairie General Hospital, Grande Prairie, Alta.; Department of Neuroscience (Vinturache), University of Lethbridge, Lethbridge, Alta.; Department of Respiratory Medicine (Ding), Shanghai Children's Hospital, Shanghai Jiao Tong University School of Medicine, Shanghai, China

Content licence: This is an Open Access article distributed in accordance with the terms of the Creative Commons Attribution (CC BY-NC-ND 4.0) licence, which permits use, distribution and reproduction in any medium, provided that the original publication is properly cited, the use is noncommercial (i.e., research or educational use), and no modifications or adaptations are made. See: <https://creativecommons.org/licenses/by-nc-nd/4.0/>

Correspondence to: Guodong Ding, dingguodong@shchildren.com.cn

Clinical images are chosen because they are particularly intriguing, classic or dramatic. Submissions of clear, appropriately labelled high-resolution images must be accompanied by a figure caption. A brief explanation (300 words maximum) of the educational importance of the images with minimal references is required. The patient's written consent for publication must be obtained before submission.