



Contents lists available at ScienceDirect

## International Journal of Surgery Case Reports

journal homepage: [www.casereports.com](http://www.casereports.com)

## Laparostomy during pregnancy: A case report

Ana Logrado\*, Júlio Constantino, Jorge Pereira, Carlos Casimiro

Serviço de Cirurgia Geral do Centro Hospitalar Tondela-Viseu, Avenida Rei D. Duarte, 3504-509, Viseu, Portugal

## ARTICLE INFO

## Article history:

Received 6 July 2018

Received in revised form 12 August 2018

Accepted 15 August 2018

Available online 20 August 2018

## Keywords:

Acute appendicitis

Pregnancy

Laparostomy

Case report

## ABSTRACT

**INTRODUCTION:** Acute appendicitis is the main indication for surgery during pregnancy. Physiologic changes during pregnancy and fear of using ionising radiation exams are some of the reasons to delayed diagnosis and consequently to higher morbidity and mortality rates for mother and fetus.

**PRESENTATION OF CASE:** We present the case of a 38-year-old woman that resorted to the emergency room on the 13th week of pregnancy with abdominal discomfort, nausea and vomiting that lasted for 7 days. She had been in the Obstetric Emergency Department 6 days prior with the same complaints. She had no fever and she was discharged home following normal obstetric ultrasound. On this second visit, after surgical consultation, septic shock with abdominal source was recognised and patient was taken for emergency exploratory laparotomy. Intraoperatively we found generalised purulent peritonitis secondary to perforated acute appendicitis. Appendectomy, thorough abdominal washing and laparostomy were performed. Patient was admitted on the Intensive Care Unit with septic shock, need for vasopressor therapy and dialysis. Four days after the first intervention the abdominal cavity was closed. She was discharged home on the 14th post-operative day and maintained obstetric follow-up for the remaining uncomplicated pregnancy.

**DISCUSSION:** In the presented clinical case, diagnostic delay evolves to abdominal sepsis that demanded a damage control approach. Laparostomy constitutes a damage control gesture, limiting abdominal contamination, preventing abdominal compartment syndrome and allowing subsequent surgical revisions.

**CONCLUSION:** Acute abdominal approach using laparostomy allowed for a good outcome, maintaining ongoing pregnancy and with incisional hernia as the only observed morbidity.

© 2018 The Author(s). Published by Elsevier Ltd on behalf of IJS Publishing Group Ltd. This is an open access article under the CC BY-NC-ND license (<http://creativecommons.org/licenses/by-nc-nd/4.0/>).

## 1. Introduction

Acute appendicitis is the main indication for surgery during pregnancy. It is estimated that acute appendicitis occurs between 0.06% and 0.28% [1] in the pregnant woman, 40% of cases taking place on the second trimester [2]. Although pregnancy is not a risk factor for acute appendicitis, appendix rupture is higher amongst pregnant women [2]. Physiologic changes during pregnancy and fear of using ionising radiation exams are some of the reasons that contribute to delayed diagnosis and consequently later surgical intervention and higher morbidity and mortality rates for mother and fetus.

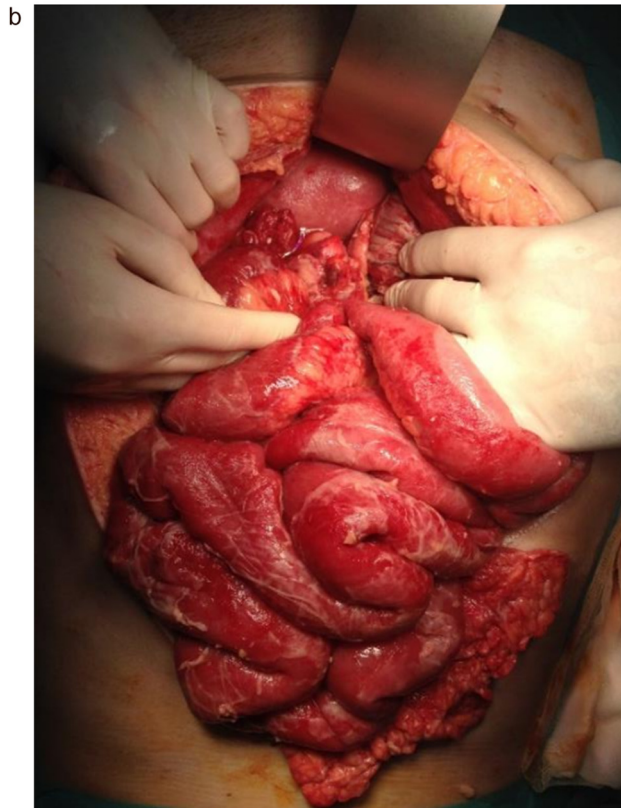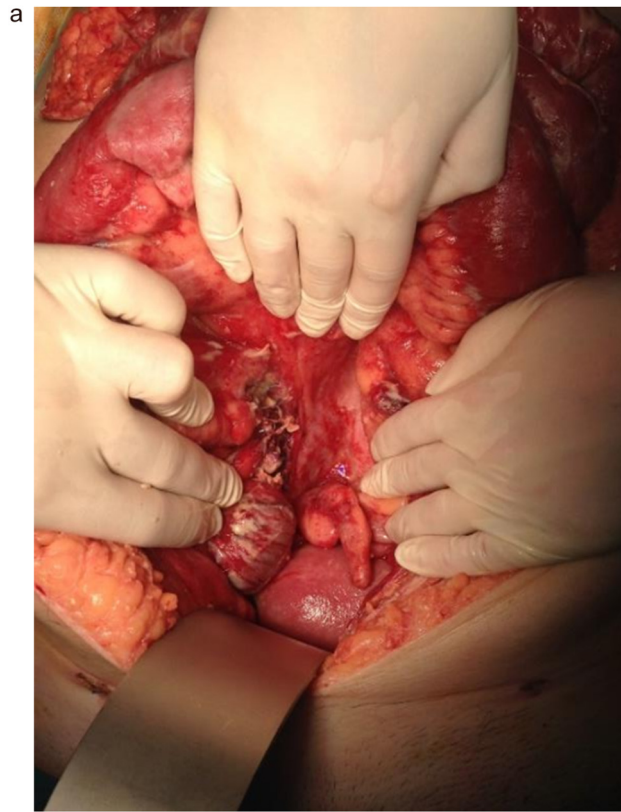
The present work has been reported in line with the SCARE criteria [3].

## 2. Case report

We present the case of a 38-year-old woman that presented to the emergency room (ER) on the 13th week of pregnancy with abdominal discomfort, nausea and vomiting that lasted for 24 h. She had no fever nor vaginal discharge. She was initially evaluated in the Obstetric Emergency Department and was discharged home following normal obstetric ultrasound. Six days after the beginning of symptoms, the patient returns to the ER with persistent abdominal pain associated with nausea and vomiting. On physical examination she was tachycardic with diffuse abdominal pain and guarding on the right quadrants. Blood work showed signs of systemic infection namely neutrophilia, low prothrombinemia, acute renal failure and high procalcitonin (180 ng/ml [normal range 0.01–0.64]) and c-reactive protein (17 mg/dl [normal range <0.5]). Abdominal ultrasound showed moderate fluid in all quadrants as well as good foetal vitality. Because of worsening general condition, surgical

\* Corresponding author.

E-mail addresses: [anacristina.logrado@gmail.com](mailto:anacristina.logrado@gmail.com) (A. Logrado), [constantino.julio@gmail.com](mailto:constantino.julio@gmail.com) (J. Constantino), [doctorjota@me.com](mailto:doctorjota@me.com) (J. Pereira), [docoliveira@hotmail.com](mailto:docoliveira@hotmail.com) (C. Casimiro).



**Fig. 1.** First laparostomy review.

A. Appendix A's base and gravid uterus.

B. Distention and thickening of small bowel.

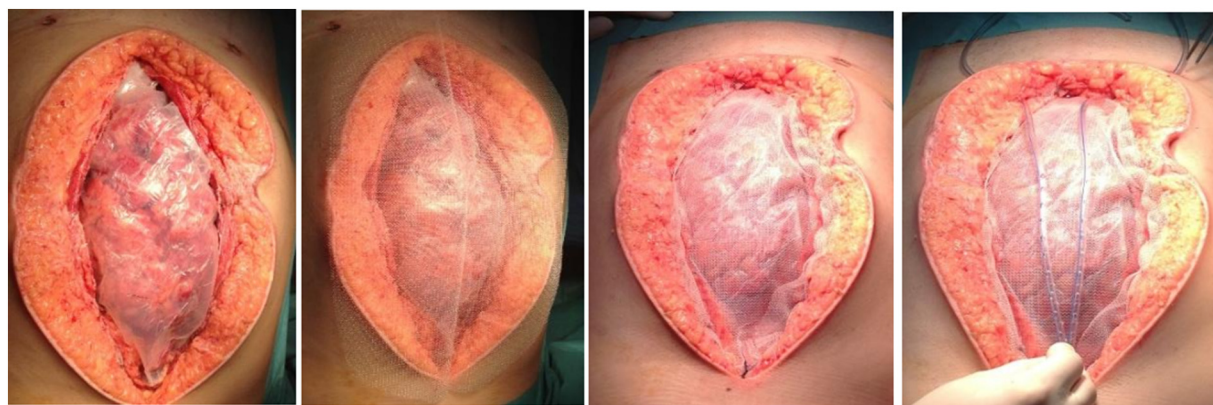


Fig. 2. Laparostomy with progressive closure technique.

consultation was obtained finding hypotension, general abdominal guarding, hyperlacticaemia (5.87 mmol/l [normal range <0.8]), hypokalaemia of 2 mmol/l and hyperglycaemia of 320 mg/dl. Septic shock with an abdominal source was acknowledged and the patient was taken for emergency exploratory laparotomy. Intraoperatively it was found generalised purulent peritonitis secondary to perforated acute appendicitis. One thousand three hundred millilitres of pus was aspirated, and multiple interloop, retrosplenic, subfrenic, pelvic and retrouterine abscesses were drained. Appendicectomy and thorough abdominal washing were performed. Due to generalised intraabdominal infection with exuberant bowel distention, and the possibility of abdominal compartment syndrome, we chose to perform a laparostomy. The patient was admitted to the Intensive Care Unit (ICU) with septic shock, need for vasopressor therapy and dialysis. Intravenous piperacillin-tazobactam antibiotherapy was initially prescribed. Forty-eighth hours later laparostomy revision was undertaken finding marked bowel oedema and distention with mild intraabdominal soiling. (Fig. 1) Further peritoneal lavage was undertaken and new laparostomy with progressive closure technique was performed. (Fig. 2) The patient recovered progressively. Four days after the first intervention she was again taken to the Operating Room for surgical revision, and the abdominal cavity was primarily closed, without the need of prosthesis. (Figs. 3 and 4) On the sixth postoperative day antibiotherapy was adjusted according to microbiological culture which isolated an *Escherichia coli* and *Streptococcus orallis*. In this context piperacillin-tazobactam was suspended and the patient started amoxicillin with clavulanic acid. The remaining ICU stay was uneventful and she was transferred to the obstetrics ward on 12th day. During all hospital stay she was daily evaluated by obstetrics physicians and good foetal viability was observed. She was discharged home on the 14th postoperative day and kept obstetric follow-up of the remaining uncomplicated pregnancy. At forty-one weeks she was admitted for an elective caesarean section giving birth to a healthy child. On 3 months post-partum follow-up consultation, the patient was clinically well presenting a ventral hernia needing correction. To this date the child remains thriving without neurological or other impairments.

### 3. Discussion

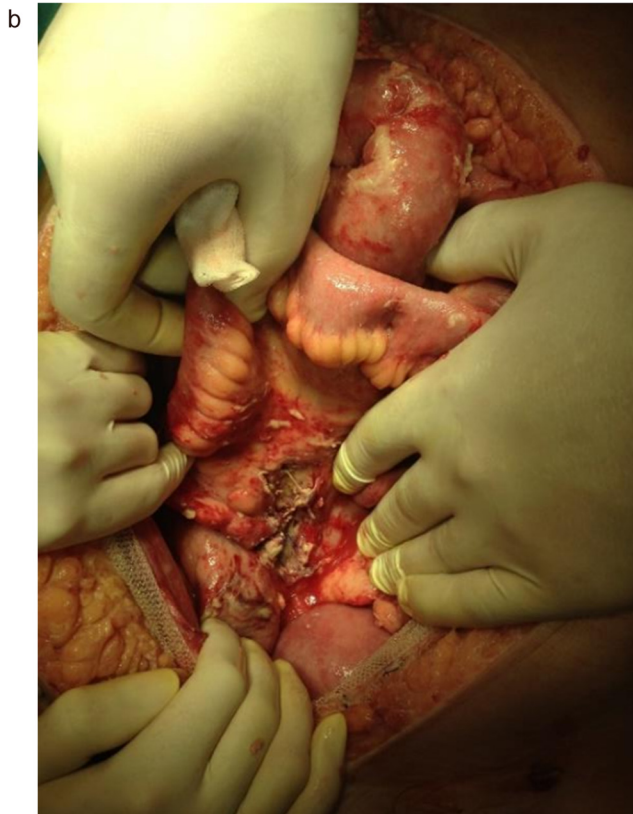
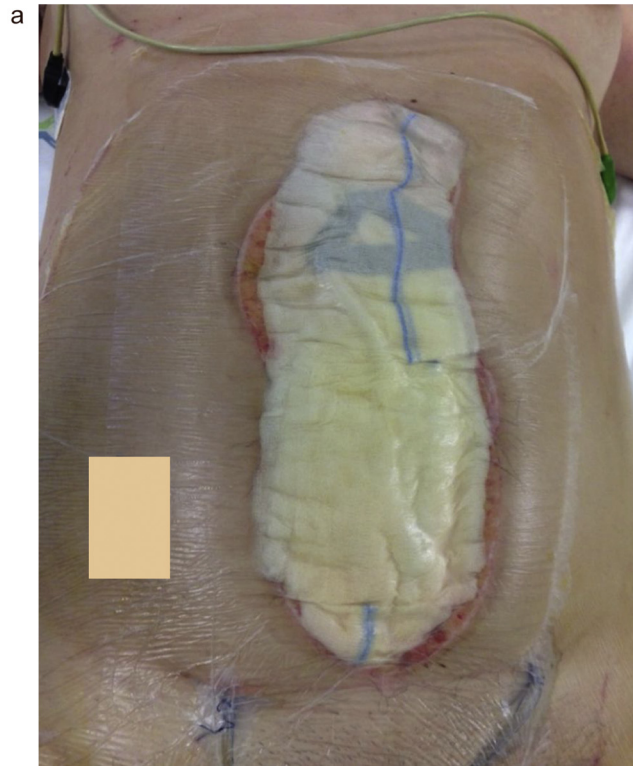
Pregnancy particularities make acute appendicitis diagnosis a clinical challenge. Abdominal organ displacement, physiological leucocytosis and similarities between initial presentation and most symptoms presented by pregnant women are some of the reasons

implicated in diagnostic delay. Furthermore, fear of ionising radiation exams impairs differential diagnosis [4,5]. When ultrasound fails to visualize the appendix, Magnetic Resonance Imaging (MRI) provides a safe and effective method of evaluating the pregnant patient [6]. However in our Hospital, emergency MRI is not an available exam. Delayed diagnosis is the primary factor for poor prognosis as it allows for disease progression and a higher rate of appendix perforation. It is estimated that foetal death rate occurs in 3–5% of cases when there is no appendix perforation and raises to 20–35% when perforation exists [7,8]. Maternal mortality raises from 0 to 4% depending on perforation presence. Surgical intervention should take place as soon as possible, as a 24-h diagnostic delay implies an appendiceal perforation rate of 66% [2]. In the present clinical case, diagnostic delay presumably evolved to a situation of abdominal sepsis that demanded a damage control approach with open abdomen management.

Published cases of laparostomy during pregnancy are rare, and the main indications are trauma, abdominal sepsis and severe acute pancreatitis. These situations may lead to abdominal hypertension, and laparostomy is used for prevention and treatment of acute abdominal compartment syndrome [9]. When used for abdominal sepsis, laparostomy is a damage control procedure, limiting abdominal contamination, preventing abdominal compartment syndrome and allowing subsequent abdominal reviews. In the presented case, generalised bowel oedema and impossibility of tension free fascial closure were the main reasons for laparostomy. Additionally, the possibility of abdominal abscess formation and predicted need of further peritoneal lavage lead to this option. The main issue with open abdominal techniques remains the progressive fascial retraction that can hamper definitive closure [10]. During pregnancy, this issue is worsened due to progressive and constant raise of intraabdominal pressure motivated by uterine growth [11]. In this clinical case, Barker's negative pressure technique and fascial prosthesis prevented excessive retraction and allowed direct fascial closure 4 days after the first procedure.

### 4. Conclusion

The emergency abdominal approach using laparostomy allowed for a good outcome, maintaining ongoing pregnancy, with an incisional hernia as ultimate morbidity. The present case shows that the principles of abdominal sepsis and damage control approach are reproducible in the pregnant woman, and pregnancy should not delay any procedure necessary for the best outcome.



**Fig. 3.** Last surgical revision.

A. Before Intervention.

B. Intraoperative: Improved bowel distention and local contamination.

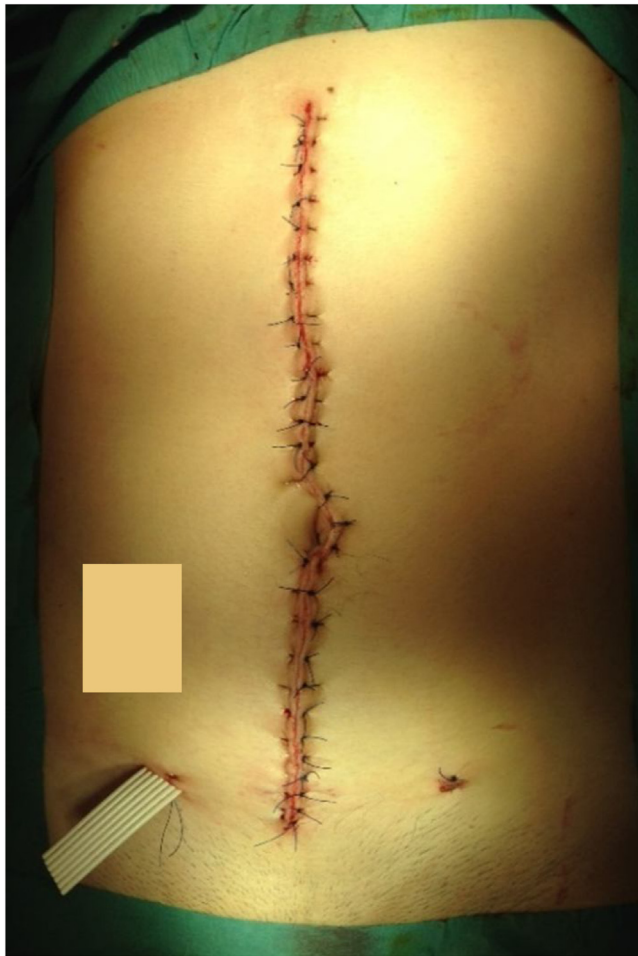

Fig. 4. Abdominal wall closed without the need of prosthesis material.

#### Author contribution

Ana Logrado–data collection, data analysis and interpretation, writing the paper.

Júlio Constantino – operated the patient, data analysis and interpretation, writing the paper.

Jorge Pereira – data analysis, manuscript review.

Carlos Casimiro – manuscript review.

#### Registration of research studies

Clinical case report, not formal research project.

#### Guarantor

Júlio Constantino.

#### References

- [1] Tika Ram Bhandari, Sudha Shahi, Sarita Acharya, Acute appendicitis in pregnancy and the developing world, *Int. Sch. Res. Notices* 2017 (2017), 2636759, 5 pages.
- [2] Sebastián Barber-Millet, José Bueno Lledó, Pablo Granero Castro, Immaculada Gómez Gavara, Neus Ballester Pla, Rafael García Domínguez, Update on the management of non-obstetric acute abdomen in pregnant patients, *Cirurgia Espanhola* 94 (5) (2016) 257–265.
- [3] R.A. Agha, A.J. Fowler, A. Saetta, I. Barai, S. Rajmohan, D.P. Orgill, for the SCARE Group, The SCARE statement: consensus-based surgical case report guidelines, *Int. J. Surg.* 34 (2016) 180–186.
- [4] Ronald Squires, Steven N. Carter, Russell G. Postier, Sabiston Textbook of Surgery, 20th ed., 2016 (Chapter 45, Acute Abdomen) p. 1131–1132.
- [5] Svati Singla Long, Christopher Long, Hong Lai, Katarzyna J. Macura, Imaging strategies for right lower quadrant pain in pregnancy, *AJR* 196 (2011) 4–12.
- [6] I.H. Shambe, N. Dikkol, K.N. Ozoilo, Pregnancy outcome following non-obstetric abdominal surgery in Jos University Teaching Hospital: a 5-year retrospective study, *Niger. J. Clin. Pract.* 19 (2016) 591–594.
- [7] Charlie C. Kilpatrick, Manju Monga, Approach to the acute abdomen in pregnancy, *Obstet. Gynecol. Clin. N. Am.* 34 (2007) 389–402.
- [8] İlkerMurat Arer, Songül Alemdaroğlu, Hasan Yeşilağaç, Hakan Yabanoğlu, Acute appendicitis during pregnancy: case series of 20 pregnant women, *Ulus Travma Acil Cerrahi Derg.* 22 (November (6)) (2016).
- [9] Federico Coccolini, Walter Biffi, Fausto Catena, Marco Ceresoli, Osvaldo Chiara, Stefania Cimbanassi, Luca Fattori, Ari Leppaniemi, Roberto Manfredi, Giulia Montori, Giovanni Pesentis, Michael Sugrue, Luca Ansaloni, The open abdomen, indications, management and definitive closure, *World J. Emerg. Surg.* 13 (7) (2018).
- [10] Adam R. Turnock, Brian P. Fleischer, Martin J. Carney, Wesley B. Vanderlan, Perforated second trimester appendicitis with abdominal compartment syndrome managed with negative pressure wound therapy and open abdomen, *J. Surg. Case Rep.* 6 (2016) 1–2.
- [11] Wojciech Staszewicz, Michel Christodoulou, François Marty, Vincent Bettschart, Damage control surgery by keeping the abdomen open during pregnancy: favorable outcome, a case report, *World J. Emerg. Surg.* 4 (33) (2009).

#### Conflicts of interest

Nothing to declare.

#### Funding source

No funding.

#### Ethical approval

Clinical case exempt from ethical approval in my institution.

#### Consent

Written informed consent was obtained from the patient for publication of this case report and accompanying images. A copy of the written consent is available for review by the Editor-in-Chief of this journal on request.

#### Open Access

This article is published Open Access at [sciencedirect.com](https://www.sciencedirect.com). It is distributed under the [IJSCR Supplemental terms and conditions](#), which permits unrestricted non commercial use, distribution, and reproduction in any medium, provided the original authors and source are credited.