

A Rare Case of Mosaic Ring Turner Syndrome with Horseshoe Kidney

Kumari Pritti, Vineet Mishra, Hetvi Patel

Department of Obstetrics and Gynecology, G. R. Doshi and K.M. Mehta Institute of Kidney Diseases and Research Centre and Dr. H.L. Trivedi Institute of Transplantation Sciences, Ahmedabad, Gujarat, India

ABSTRACT

Rearranged X chromosomes in Turner syndrome (TS) generally present with a mild phenotype, but in cases of ring X chromosomes, the incidence of intellectual disability and other congenital abnormalities can be significantly higher depending on the size of the ring and the involvement of X-inactive specific transcript (XIST) region. Here, we report a 17-year-old female who was referred for a cytogenetic analysis because of primary amenorrhoea. The patient, of normal intelligence, had been found to have traits of TS, especially short stature and some rare findings such as horseshoe kidney and short fourth toe. Cytogenetic analysis showed a mosaic 45, X/46, X and r(X) karyotype. Fluorescence *in situ* hybridisation analysis using sex chromosome probes permitted us to identify the marker as a ring X chromosome, detected in 30% of cells. The r(X) might include the XIST locus, which would have caused X-inactivation of this abnormal ring chromosome leading to mild phenotype in our patient but with atypical features present in the form of horseshoe kidney and short fourth toe.

KEYWORDS: Mosaicism and Turner syndrome, primary amenorrhoea, ring chromosome

INTRODUCTION

Turner syndrome (TS) is a common, but little-known chromosomal aneuploidy characterised by complete or partial absence of an X chromosome; with a characteristic mild phenotype with some degree of variability.^[1] The majority of the patients have short stature and primary amenorrhoea and do not develop secondary sexual characteristics. Less consistent abnormalities include webbed neck, renal malformations (>50%) and cardiac defects (10%), while intelligence is considered normal. Approximately three-quarters of TS females inherit their X chromosome maternally.^[2]

TS mosaics are also well documented and can be subcategorised according to whether the second cell line contains a whole or part of a sex chromosome. Jacobs *et al.* showed that out of 211 patients clinically diagnosed of TS, 97 patients to have a 45, X constitution, 15 to be 45, X/46, XX or 45, X/47, XXX mosaics, 86 to have a structurally abnormal X, out of which

13 were mosaic, with a second cell line containing a ring X chromosome (45, X/46, X and r[X]).^[3] The phenotypic variability of these mosaics largely depends on the size of the ring and the presence of a functioning X-inactive specific transcript (XIST).^[4] Here, we report a case which, from a cytogenetic viewpoint, appears to represent a relatively straightforward example of a TS variant mosaic karyotype, with a small marker chromosome of X chromosome origin. However, from a clinical perspective, this case study has rather phenotype similar to a case of non-mosaic TS or mosaic TS with one normal X chromosome but with atypical findings of horseshoe kidney and short fourth toe. The final karyotype was based on a combination of fluorescence *in situ* hybridisation (FISH) analysis, as well as conventional (G-banded) karyotyping.

Address for correspondence: Dr. Kumari Pritti, Genetics Division, Department of Obstetrics and Gynecology, G. R. Doshi and K. M. Mehta Institute of Kidney Diseases and Research Centre and Dr. H.L. Trivedi Institute of Transplantation Sciences, Ahmedabad - 380 016, Gujarat, India.
E-mail: preeti.ikdrc@gmail.com

Received: 08-08-2022

Revised: 25-08-2022

Accepted: 14-09-2022

Published: 30-09-2022

Access this article online

Quick Response Code:



Website:
www.jhrsonline.org

DOI:
10.4103/jhrs.jhrs_110_22

This is an open access journal, and articles are distributed under the terms of the Creative Commons Attribution-NonCommercial-ShareAlike 4.0 License, which allows others to remix, tweak, and build upon the work non-commercially, as long as appropriate credit is given and the new creations are licensed under the identical terms.

For reprints contact: WKHLRPMedknow_reprints@wolterskluwer.com

How to cite this article: Pritti K, Mishra V, Patel H. A rare case of mosaic ring turner syndrome with horseshoe kidney. *J Hum Reprod Sci* 2022;15:318-20.

CASE REPORT

A 17-year-old girl presented with short stature and primary amenorrhoea. Her height was 136 cm and her weight was 37 kg (<5th percentile). She was born to an unrelated couple. Physical examination revealed a female phenotype with short stature and cubitus valgus with an overlapping fourth toe in the left foot and a short fourth toe in both feet; on X-ray, both fourth metatarsals were shorter than the fifth metatarsal bone [Figure 1a and b]. Her breast and hair development were Tanner's Stage 1. Examination of cardiovascular, respiratory and neurological systems was normal. Gynaecological examination revealed a normal cervix and vagina. Transabdominal sonography showed a hypoplastic uterus with definite ovaries. In magnetic resonance imaging, the uterus was 37 mm × 22 mm × 12 mm in size. The left ovary was seen but the right ovary was not visible. A horseshoe kidney was noted.

Laboratory investigations revealed normal haematological and biochemical parameters. Her hormonal profile was done showing high follicle-stimulating hormone (69.7 mIU/ml) and luteinising hormone (15.29 mIU/ml) levels favouring premature ovarian failure. Her thyroid-stimulating hormone – 1.2 UIU/ml, oestrogen (E2) – 14 pg/ml and prolactin – 16.7 ng/ml were in the normal range. Her karyotype revealed a mosaic pattern having two cell lines, where 70% of the cells showed 45 chromosomes with a single X chromosome and 30% of the cells were noted to have a ring chromosome. This was confirmed to be of X origin by FISH with a centromeric X probe [Figure 2a and b]. Her final karyotype was mos 45, X[70]/46, X, r(X).[30].ish r (X)(DXZ1+).

DISCUSSION

Most of the females with a ring chromosome X that is r(X) have an appearance of somatic signs of TS, including short stature, peripheral oedema, characteristic

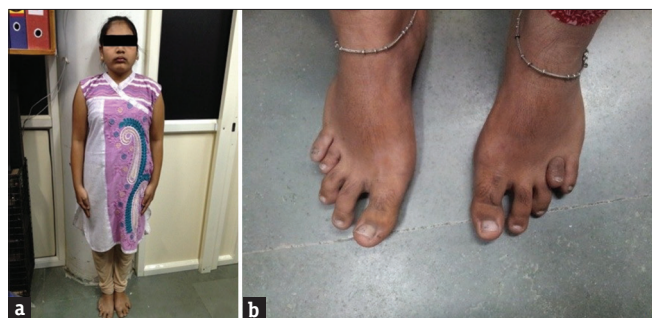

Figure 1: (a) Turner syndrome patient with short stature, (b) Turner syndrome patient having overlapping fourth toe in left and short fourth toe in both foot

facial features, low posterior hairline, ovarian dysgenesis, and also endocrine disorders and autoimmune conditions.^[5] The patients with r(X) are at higher risk of mental retardation, learning difficulties, autistic spectrum disorders and structural brain abnormalities.^[6] These abnormal phenotypes can be attributed to failed or partial X inactivation and/or incomplete selection in favour of cells with a normal balance of gene expression. However, such abnormalities are generally well tolerated because of the preferential inactivation of the abnormal X, which can restore, at least in part, a balanced genetic makeup. This beneficial effect of X inactivation results in a mild phenotype in most patients with structural abnormalities of the X, similar to that found in TS patients with a 45, X karyotype. In our case, the patient presented with a milder phenotype such as short stature, poorly developed secondary sexual characteristics, hypoplastic uterus and normal left ovary and a horseshoe kidney. Her intellectual level was normal. This could be explained by the possibility of the presence of XIST region in the ring chromosome leading to inactivation of the ring chromosome and thus preventing the overdosage effect of the genes present in the ring chromosome.

TS variants include female individuals with partial deletions in the 'p' and/or 'q' arms of one X chromosome. Deletions of certain X chromosome regions/genes can lead to specific phenotypic features which are characteristic of 'full' or 'classic' TS. Deletions of the SHOX gene, located in the pseudoautosomal region at Xp22.33, are associated with short stature. Primary ovarian failure (POF) has been associated with deletions of the FMR1 gene (POF1) at Xq26–q28^[7] and the DIAPH 2 gene (POF2A) at Xq21.33.^[8] Type I diabetes has also been linked to the TS phenotype.^[9] Chromosomal microarray could have exactly mapped the breakpoints and delineated the extent of deletion in Xp and Xq regions of the ring chromosome, which could have provided better phenotype–genotype correlation. Unfortunately, the microarray study could not be done in our case.

Here, the female is having some of the classic phenotypes of TS but at the same time has been spared

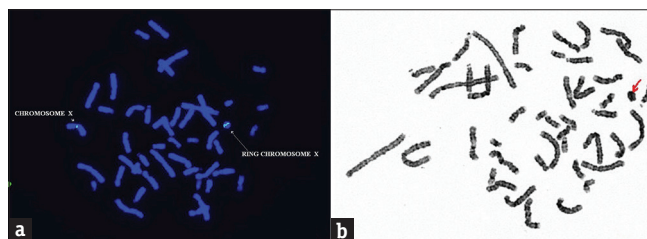


Figure 2: (a) Partial karyotype of the patient showing ring (marker) chromosome, (b) Fluorescence *in situ* hybridisation showing ring (marker) chromosome positive for centromeric X probe

by not having cardiac anomalies and thyroid-related disorders. This phenotypic variation may have at least two causes: the size of the deleted portion at each end of the X chromosome and the relative frequency and distribution of 45, X and 46, X, r(X) cell lines in various body tissues.^[10]

Most of TS cases are diagnosed in pubertal years due to stunted growth; hence, it is essential to diagnose these cases during the neonatal period to develop appropriate hormonal therapy for development, growth and pubertal induction. It is also important to diagnose TS early so that screening for congenital heart disease, horseshoe kidney and hypothyroidism associated with TS can be detected before the presentation of symptoms and timely intervention could be possible. The presence of short fourth toe can be used as a marker for early cytogenetic study. Early hormone therapy, especially in girls, will lead to the proper development of secondary sexual characteristics and female reproductive organs. With early treatment in such cases, normal uterine size could be achieved which will enable them to bear the child naturally or through assisted reproductive techniques in case of ovarian failure.

CONCLUSION

We strongly emphasise the importance of cytogenetic study complemented with molecular cytogenetic study and karyotype–phenotype correlations in patients with TS to obtain information regarding the genotype–phenotype correlations related to the X chromosome. Early diagnosis through genetic evaluation is very crucial for the timely management of such patients in terms of reproductive and fertility care.

Declaration of patient consent

The authors certify that they have obtained all appropriate patient consent forms. In the form the patient(s) has/have given his/her/their consent for his/her/their images and other clinical information to be

reported in the journal. The patients understand that their names and initials will not be published and due efforts will be made to conceal their identity, but anonymity cannot be guaranteed.

Financial support and sponsorship

Nil.

Conflicts of interest

There are no conflicts of interest.

REFERENCES

- Gardner RJ, Sutherland GR, Shaffer LG. Chromosome Abnormalities and Genetic Counseling. 4th ed. New York, NY, USA: Oxford University Press; 2011.
- Schinzel A. Catalogue of Unbalanced Chromosome Aberrations in Man. 2nd ed. Berlin, NY, USA: De Gruyter; 2001.
- Jacobs P, Dalton P, James R, Mosse K, Power M, Robinson D, *et al.* Turner syndrome: A cytogenetic and molecular study. *Ann Hum Genet* 1997;61:471-83.
- Mazzaschi RL, Taylor J, Robertson SP, Love DR, George AM. A turner syndrome patient carrying a mosaic distal X chromosome marker. *Case Rep Genet* 2014;2014:597314.
- Dennis N, Coppin B, Turner C, Skuse D, Jacobs P. A clinical, cytogenetic and molecular study of 47 females with r(X) chromosomes. *Ann Hum Genet* 2000;64:277-93.
- Kuntsi J, Skuse D, Elgar K, Morris E, Turner C. Ring-X chromosomes: Their cognitive and behavioural phenotype. *Ann Hum Genet* 2000;64:295-305.
- Eggermann T, Meschede D, Schüler H, Palm S, Glaser D, Horsthemke B, *et al.* Premature ovarian failure associated with a small terminal Xq deletion: Narrowing the POF1 region down to Xq27.2/Xq27.3-qter. *Clin Genet* 2005;67:434-7.
- Marozzi A, Manfredini E, Tibiletti MG, Furlan D, Villa N, Vegetti W, *et al.* Molecular definition of Xq common-deleted region in patients affected by premature ovarian failure. *Hum Genet* 2000;107:304-11.
- Callea M, Radovich F, Cappa M, Clarich G. Turner's syndrome with mental retardation, microcephaly and Type 1 diabetes in a 6-year-old child. Case report and literature review. *Minerva Pediatr* 2013;65:251-2.
- Chauhan P, Jaiswal SK, Lakhotia AR, Rai AK. Molecular cytogenetic characterization of two turner syndrome patients with mosaic ring X chromosome. *J Assist Reprod Genet* 2016;33:1161-8.