



Contents lists available at ScienceDirect

Journal of Hand Surgery Global Online

journal homepage: [www.JHSGO.org](http://www.JHSGO.org)

## Case Report

# Volar Metacarpophalangeal Dislocation of Fingers: Review of the Literature



Khaled T. Kabbani, MD, \* Konstantinos Dimos, MD, † Dimitris Kosmas, MD, † Nadia Kampani, MS, ‡ Georgios Papathanasiou, PhD, § Evridiki Tsiomita, MD, † Mouammer Chouskoglou, MD †

\* Orthopaedic Department, University Hospital of Ioannina, Ioannina, Greece

† Department of Orthopaedics, University of Ioannina, Ioannina, Greece

‡ Department of Pharmacy, University of Strathclyde, Glasgow, Scotland

§ Department of Physics, Democritus University of Thrakis, Xanthi, Greece

## ARTICLE INFO

## Article history:

Received for publication January 6, 2021

Accepted in revised form April 1, 2021

Available online May 2, 2021

## Key words:

Palmar metacarpophalangeal

Volar dislocation

Volar plate

Isolated volar metacarpophalangeal dislocations of fingers are extremely rare. There are few cases published in English and French literature. In this article, we aim to review the literature and present a case of isolated open volar dislocation of a finger. We treated this dislocation first by a dorsal approach alone and later, after recurrence, using a combined dorsal and volar approach. This report emphasizes the pathology of such injuries, clarifies the mechanisms, and outlines the treatment options of the dislocations. Close reduction can be achieved and maintained if done early. It must be attempted first for all cases. In irreducible or reducible but unstable dislocations, we recommend surgical restoration. During an open reduction, the major torn or avulsed soft tissue joint stabilizers must be repaired. A combined dorsal and volar approach, starting dorsally, is useful.

Copyright © 2021, THE AUTHORS. Published by Elsevier Inc. on behalf of The American Society for Surgery of the Hand. This is an open access article under the CC BY-NC-ND license (<http://creativecommons.org/licenses/by-nc-nd/4.0/>).

McLaughlin<sup>1</sup> reported the first isolated metacarpophalangeal (MCP) volar dislocation of a finger in 1965. Since then, to our knowledge, only 21 cases have been reported (Table). This type of dislocation can easily be missed and may present late. Little is known about the mechanisms, pathology, and outcomes of isolated volar MCP dislocations. Previous studies<sup>1–10</sup> have mentioned different treatment methods. Nevertheless, there is not enough evidence to support the use of one treatment over another. In this study, we have attempted to comprehensively address these issues by discussing the challenges we faced in treating a case and by reviewing previous reports.

## Case Report

We searched MEDLINE, EMBASE, PubMed, and Google Scholar from 1948 to 2020 for isolated MCP volar dislocations of fingers.

**Declaration of interests:** No benefits in any form have been received or will be received related directly or indirectly to the subject of this article.

**Corresponding author:** Khaled T. Kabbani, MD, Orthopaedic Department, University Hospital of Ioannina, Stavros Niarchos Avenue 6, 45500, Ioannina, Greece.

E-mail address: [kabbakha@gmail.com](mailto:kabbakha@gmail.com) (K.T. Kabbani).

The following key words were used: volar and/or palmar, MCP dislocation, and finger. We excluded thumb dislocations and volar MCP dislocations concomitant with fractures to the involved metacarpal or proximal phalange. We found 18 related articles, which reported 21 isolated volar MCP dislocations. We reviewed the articles for the mechanism of injury, the pathologic anatomy, the time between the injury and treatment, the methods of treatment, the structures repaired in surgically treated cases, rehabilitation, and outcomes (Table).

A 37-year-old right-handed male bodybuilder athlete presented to the emergency department of our hospital 9 days after a motorcycle accident. At presentation, he had an edematous left hand with a 1.8-cm-long sutured wound, radial to the dorsal surface of the MCP joint of the left ring finger. He was unable to move the left ring finger, and the head of the fourth metacarpal was prominent dorsally. The x-rays showed a volar dislocation of the left ring finger (Fig. 1), an oblique fracture to the base of the left fifth metacarpal, and multiple fractures/dislocations to the left foot. An attempt to reduce the MCP dislocation in the emergency department was unsuccessful. Two days postadmission, he underwent surgery under general anesthesia. We used the same puncture wound to approach the joint. The head of the fourth metacarpal emerged through the wound. The dorsal insertion of the joint

<https://doi.org/10.1016/j.jhsg.2021.04.001>

2589-5141/Copyright © 2021, THE AUTHORS. Published by Elsevier Inc. on behalf of The American Society for Surgery of the Hand. This is an open access article under the CC BY-NC-ND license (<http://creativecommons.org/licenses/by-nc-nd/4.0/>).

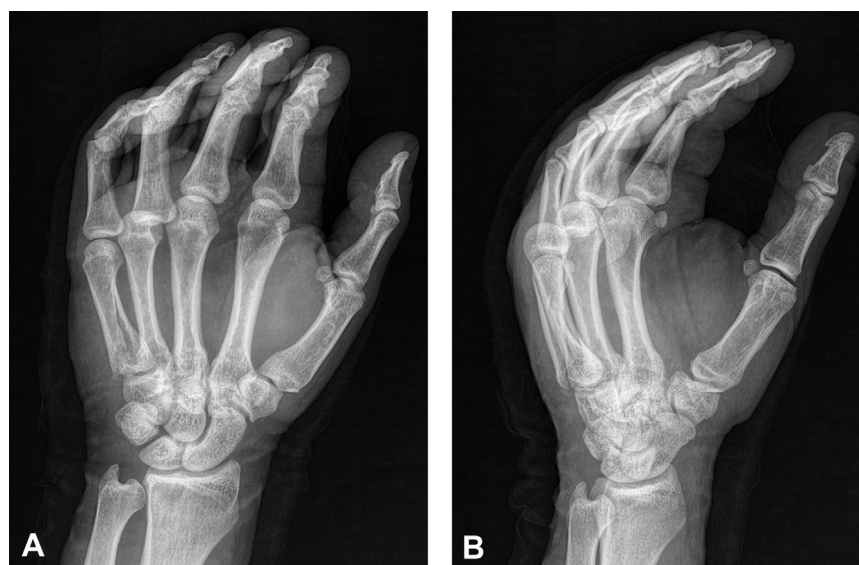**Table**

All Reported Isolated Volar Metacarpophalangeal Dislocations, Including the Present Case\*

Author/Year	Finger/Injury	Age/ Gender	Mechanism	Treatment/ Restored Structures	Time to Surgery/ Approach	Interposed Structure	Results
McLaughlin, 1965 <sup>1</sup>	Left middle/closed	-	-	OR	-	DC	-
Renshaw and Lewis, 1973 <sup>2</sup>	Left little/closed	48 M	HE +AF	OR	2 wk	PP	60°
Wood and Dobyns, 1981 <sup>3</sup>	Left index/closed	17 F	HF	OR/Arthrodesis	9 mo	DC	0°
	Right middle/closed	20 M	HF	OR/TAF	2 wk	DC	60°
	Right middle/closed	61 F	HF	OR/Arthrodesis	5 mo	DC	0°
Betz et al, 1982	Left ring/closed	70 F	HE	OR/UCL, PP	-	PP, UCL	Full
Moneim, 1983 <sup>4</sup>	Right little/closed	59 M	HF	OR/RCL, UCL, PP, DC/TAF	7 wk	PP	70°
Boland, 1984 <sup>5</sup>	Left ring/closed	65 F	HF	CR	0	-	-20°
Khuri and Fay, 1986	Left ring/closed	31 M	HF	CR	0	-	Full
Hargarten and Hanel, 1992 <sup>6</sup>	Right little/closed	66 M	HF	OR	4 wk	-	65°
Qui, 1992	Right index/closed	20 M	HF	OR/TAF	3 wk	PP	20°
MLSna et al, 1993	Right little/closed	68 M	-	OR/RCL	3 wk	DC	65°
Paul et al, 1995	Right ring/closed	22 M	HE + TF	OR/PP	0	PP	Full
Takami et al, 1999 <sup>9</sup>	Right ring/closed	20 M	-	CR	0	-	Full
	Right ring/closed	60 F	-	CR	0	-	75°
Lam et al, 2000 <sup>8</sup>	Left ring/closed	44 M	HF	OR/TAF	0	PP	80°
Patel and Bassini, 2000	Little/closed	-	-	-	-	Juncturae tendinum	-
Murase et al, 2004 <sup>7</sup>	Left ring/closed	52 F	HE + rotation	OR/DC, UCL, RCL, PP	6 d	DC, PP	70°
Zrig et al, 2009	Ring/closed	-	HE+ AF+ TF	CR	0	-	Full
Panchal and Bamberger, 2010 <sup>10</sup>	Left middle/closed	45 M	HE	CR	0	-	90°
Lai and Leung, 2017	Right ring/closed	49 F	-	OR/ RCL,UCL	0	PP	10
Present case	Left ring/open	37 M	AF+ TF	OR/DC, PP, RCL SB/EF	14 wk	DC, PP	65°

AF, active flexion; CR, closed reduction; DC, dorsal capsule; EF, external fixator ; HE, hyperextension; HF, hyperflexion; OR, open reduction; PP, palmar plate; RCL, radial lateral collateral ligament; SB, sagittal band; TAF, transarticular fixation with Kirschner wire; TF, transmitting force; UCL, ulnar collateral ligament.

\* Uncited references are provided in [Appendix 1](#) (available on the *Journal's* website at [www.jhsgo.org](http://www.jhsgo.org)).

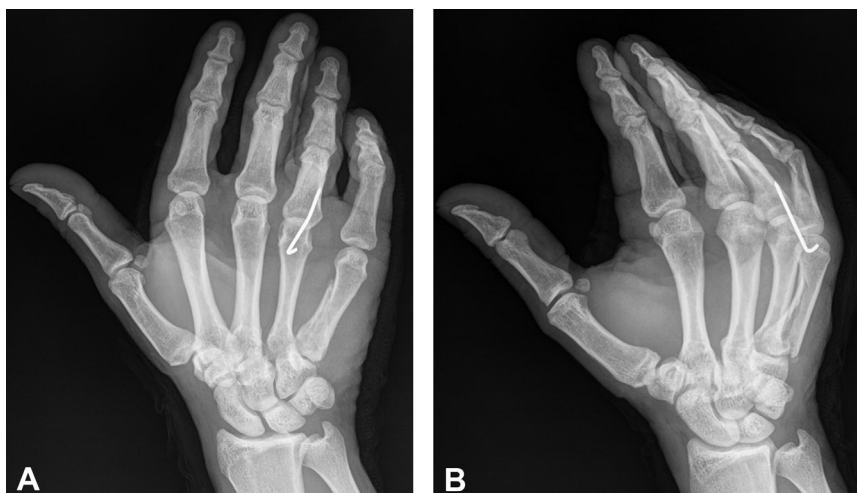

**Figure 1.** **A** Anteroposterior x-ray of the patient's left hand at presentation. Notice the dislocation of the fourth MCP, as indicated by the overlapping metacarpal head over the base of the proximal phalanx and by the oblique fracture of the fifth metacarpal. **B** Oblique x-ray at presentation. Notice the dislocation of the base of the proximal phalanx of the ring finger and the oblique fracture of the fifth metacarpal.

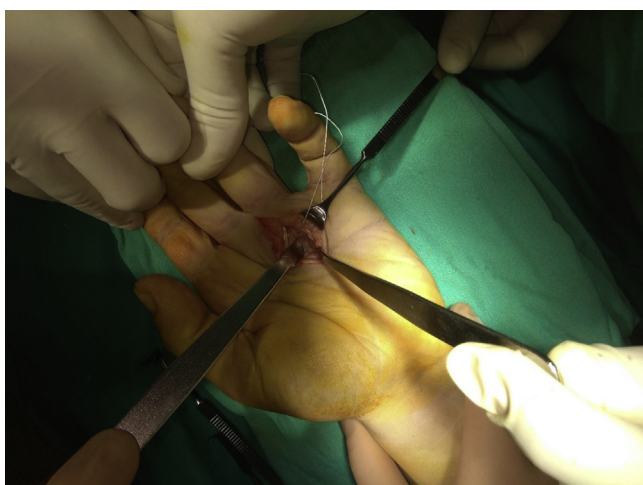capsule, extensor hood, radial sagittal band, radial lateral collateral ligament, and radial deep transverse ligament were torn. The central slip of the extensor tendon was dislocated palmarly and trapped between the head of the metacarpal and the base of the proximal phalanx. The reduction was difficult because of the entrapment of the ruptured volar plate and dorsal joint capsule within the joint. They were disengaged using a MacDonald-like instrument. It was not possible to maintain the reduction due to the gross instability. After the reduction, the extensor tendon was dislocated ulnarly. To repair the soft tissues, we had to first stabilize the joint with one Kirschner wire through the joint at 70° of flexion

([Fig. 2](#)). The radial deep transverse ligament, radial lateral collateral ligament midsubstance tear, and sagittal band were repaired with a 4-0 nylon suture. Gross instability after reduction forced us to immobilize the joint for a prolonged period. Five weeks after surgery, we removed the Kirschner wire and started hand therapy with active and passive range of motion exercises. Two weeks later, the patient presented with a recurrence of the deformity.

We waited for 14 weeks after the initial injury, until the patient had improved from his severe lower limb trauma. We then reoperated by a combined dorsal and volar approach. Starting palmarly, after removing the scar tissue, we examined the insertion of the

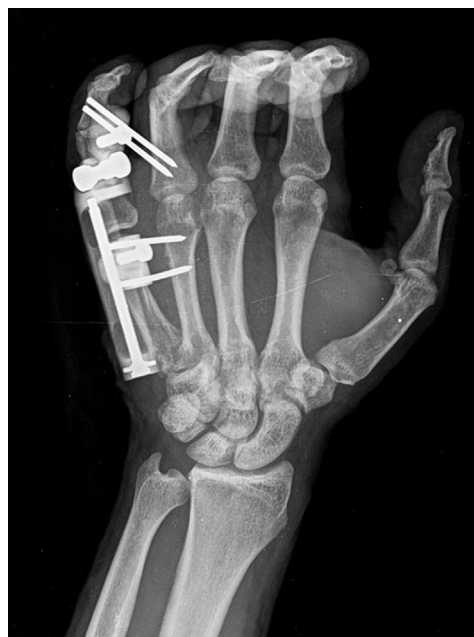

**Figure 2.** A Anteroposterior view of the patient's left hand after the first reduction with a dorsal approach. B Oblique views of the patient's left hand after the first reduction with a dorsal approach and stabilization with Kirschner wire in 70° flexion.



**Figure 3.** Intraoperative view showing the palmar approach.

volar plate. It was torn distally and loose proximally. We stabilized it using 2-mm suture mini anchors. First, 2 anchors were inserted at the base of the proximal phalanx. The proximal insertion continued to be loose; thus, additional 2 anchors were inserted at the neck of the metacarpal (Fig. 3). Dorsally, we inspected the joint, cleared the fibrous tissues, and centralized the ulnarly dislocated extensor. We raised a strip from the radial side of the extensor tendon, preserving its distal continuity with the tendon, passed it as a loop underneath the tendon, and sutured it to the radial deep transverse ligament. Before closing the wound and after suturing the joint capsule, reinforcing the sagittal band and the extensor hood with duplicating 4-0 nylon sutures, we assessed the joint stability by passive flexion and extension of the wrist and the joint. To secure our reduction, we used an external fixator with 3 mm of joint distraction (Fig. 4). To avoid tension at the repaired dorsal structures, especially the radial sagittal band repair, the joint was stabilized at 45° rather than at 70°. Feeling confident about the joint stability, we chose a shorter immobilization period. Three weeks later, we removed the external fixator and started gentle active flexion and extension as tolerated. At 8 weeks, the patient achieved 90° flexion and -30° extension. Six months after surgery, his motion was unchanged. We noticed a deviation of the finger during extension,

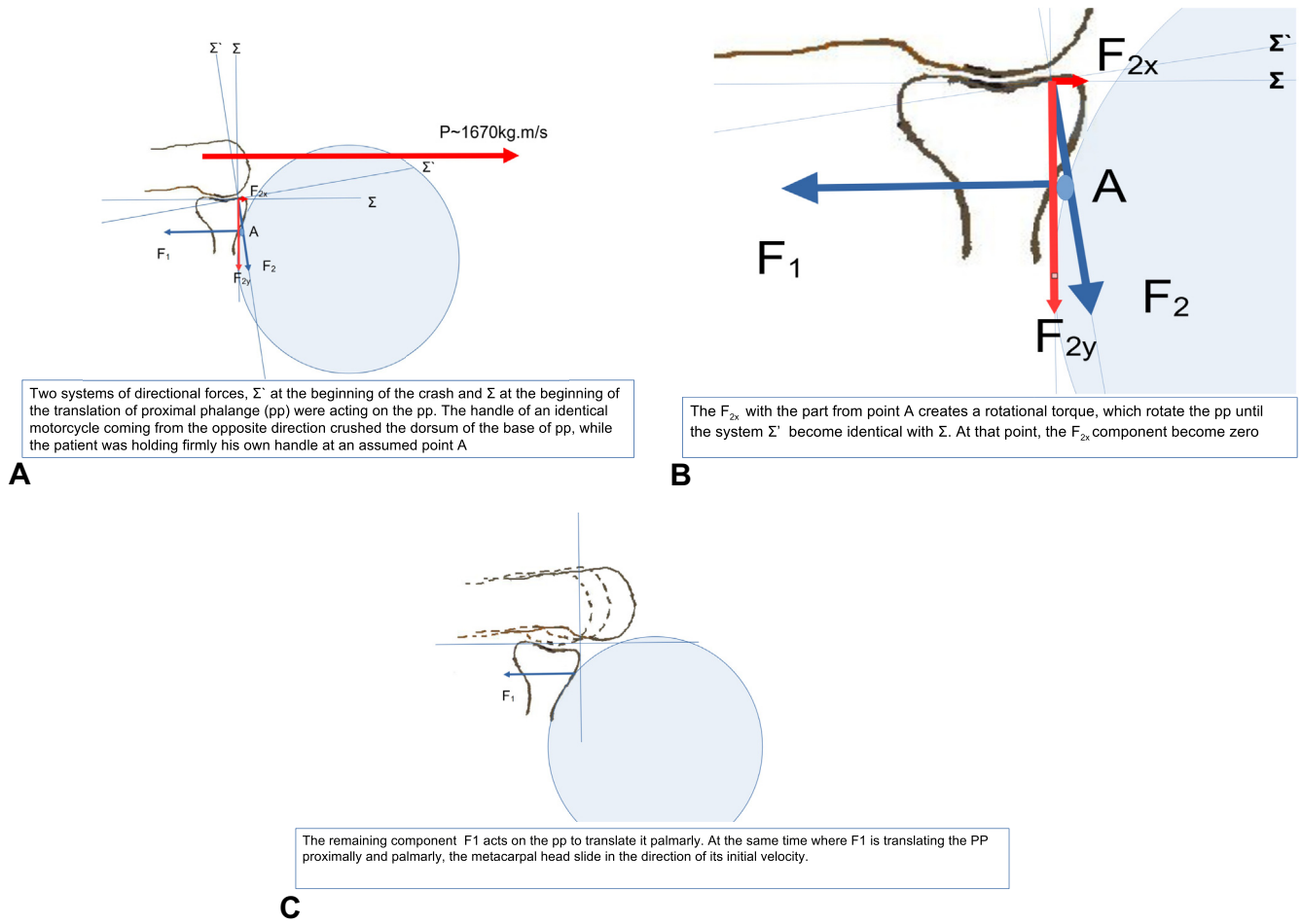


**Figure 4.** Stabilization of the MCP joint with external fixator after combined dorsal and palmar approach.

which was likely due to laxity of the repaired radial side of the extensor mechanism, especially the radial sagittal band (Video 1). His last follow-up was 14 months after surgery, with painless 90° of flexion and -25° of extension, normal grip, and grasp function.

## Discussion

Isolated palmar MCP dislocation of a finger is an extremely rare injury. We reviewed all 21 cases that have been reported previously (Table). The present case is the first reported open, isolated volar MCP dislocation of a finger. The rarity of this injury could be related to the MCP structural anatomy. Different mechanisms have been described. Renshaw and Lewis<sup>2</sup> reported extreme hyperextension as the mechanism of injury, and the avulsed distally volar plate as the main pathology. They experimented on 16 cadaveric digits but were unable to produce neither volar dislocation nor the avulsion



**Figure 5.** **A** Two systems of directional forces,  $\Sigma'$  at the beginning of the crash and  $\Sigma$  at the beginning of the translation of proximal phalange, were acting on the proximal phalange. The handle of an identical motorcycle coming from the opposite direction crushed the dorsum of the base of proximal phalange while the patient was holding his own handle firmly at an assumed point "A." **B** The  $F_{2x}$  with the part from point A created a rotational torque, which rotated the proximal phalange until the system  $\Sigma'$  became identical to  $\Sigma$ . At that point, the  $F_{2x}$  component became 0. **C** The remaining component,  $F_1$ , acted on the proximal phalange to translate it palmarly. At the same time when  $F_1$  was translating the proximal phalange proximally and palmarly, the metacarpal head slid in the direction of its initial velocity.

of the volar plate from the base of the proximal phalanx. Wood et al<sup>3</sup> reported 3 cases of MCP volar dislocations caused by hyperflexion, with palmarly directed translational force acting on the proximal phalanx and the avulsed joint capsule proximally as the main intra-articular trapped structure. They also succeeded in reproducing the isolated dislocation in 5 of 10 cadaver digits. Betz et al and Murase et al<sup>7</sup> reported forceful hyperextension during powerful flexion as the mechanism of dislocation and stated that torsion forces can cause collateral avulsions. The mechanism in 9 of 21 reported cases was forceful hyperflexion (Table). In our case, the mechanism, according to the patient's history, was by a direct blow on the dorsal surface of the base of the proximal phalange during forceful active flexion. Analyzing the acting forces in our case resulted in a moment that translated the proximal phalanx palmarly (Fig. 5). In the 15 surgically treated cases, the entrapped structures were the dorsal capsule in 5, palmar plate in 6, both dorsal capsule and palmar plate in 3, and juncturae tendinum in 1. Also, some studies have reported avulsed collaterals and/or dislocated tendons entrapped in the joint. In our case, the volar plate, dorsal capsule, and dislocated extensor central slip were the entrapped structures that prevented reduction. Takami et al<sup>9</sup> emphasized the importance of early reduction attempts. They noticed that most of the surgically treated reported cases were treated after a delay.<sup>9</sup> We also found that the 6 cases that

presented early were treated conservatively, with favorable results (Table).

Isolated palmar MCP finger dislocation is an extremely rare injury. This easily missed injury can be reduced conservatively if detected early, with excellent functional outcomes. When closed reduction is impossible because of the entrapment of soft tissue structures between the joint surfaces, open reduction is indicated. Mlsna et al used magnetic resonance imaging to identify the torn MCP stabilizers. If available, magnetic resonance imaging can be helpful in preoperative planning. Starting dorsally, after repairing all the important stabilizing structures, if the reduction is still unstable or difficult to maintain, volar instability may also be present, and a combined volar approach may be beneficial. It is crucial to repair the lateral collaterals, volar plate, and joint capsule. The 2 mm (0.08 in) suture mini anchors seem to be an easy and reliable way to stabilize the avulsed volar plate. An external fixator is useful for the stabilization of the joint and enables joint distraction, which may prevent secondary joint stiffness.

**Acknowledgments**

Dr Khaled Kabbani thanks Dr Papathanasiou from the Department of Physics at Democritus University of Thrakis for his brilliant analysis on the mechanics of forces that directed the dislocation and for his work on Figure 5 and thanks Nadia Kampani from the

University of Strathclyde for her contribution in reviewing and designing this study. We thank Rontis-Hellas for funding the publishing expenses of this research.

## References

1. McLaughlin HL. Complex “locked” dislocation of the metacarpophalangeal joints. *J Trauma*. 1965;5(6):683–688.
2. Renshaw TS, Louis DS. Complex volar dislocation of the metacarpophalangeal joint: a case report. *J Trauma*. 1973;13(12):1086–1088.
3. Wood MB, Dobyns JH. Chronic, complex volar dislocation of the metacarpophalangeal joint. *J Hand Surg Am*. 1981;6(1):73–76.
4. Moneim MS. Volar dislocation of the metacarpophalangeal joint. Pathologic anatomy and report of two cases. *Clin Orthop Relat Res*. 1983;176:186–189.
5. Boland D. Volar dislocation of the ring finger metacarpophalangeal joint. *Orthop Rev*. 1984;13:520–523.
6. Hargarten SW, Hanel DP. Volar metacarpal phalangeal joint dislocation: a rare and often missed injury. *Ann Emerg Med*. 1992;21(9):1157–1159.
7. Murase T, Moritomo H, Yoshikawa H. Palmar dislocation of the metacarpophalangeal joint of the finger. *J Hand Surg Br*. 2004;29(1):90–93.
8. Lam WL, Fitzgerald AM, Hooper G. Volar metacarpophalangeal joint dislocation. *J Accid Emerg Med*. 2000;17(3):226–228.
9. Takami H, Takahashi S, Ando M. Volar dislocation of the metacarpophalangeal joint of the ring finger. Report of two cases. *Clin Orthop Relat Res*. 1999;363:116–120.
10. Panchal AP, Bamberger HB. Dorsal dislocation of the distal interphalangeal joint and volar dislocation of the metacarpophalangeal joint in the same finger: a case report. *Hand (NY)*. 2010;5(2):200–202.