

# Safety and Efficacy of Nano-Pulse Stimulation Treatment of Non-Genital, Cutaneous Warts (Verrucae)

Richard Nuccitelli, PhD <sup>1\*</sup>, Brenda M. LaTowsky, MD,<sup>2</sup> Edward Lain, MD,<sup>3</sup> Girish Munavalli, MD,<sup>4</sup> Lesley Loss, MD,<sup>5</sup> E. Victor Ross, MD <sup>6</sup>, Lauren Jauregui, BS,<sup>1</sup> and William A. Knappe, BS<sup>1</sup>

<sup>1</sup>Pulse Biosciences, 3957 Point Eden Way, Hayward, California 94545

<sup>2</sup>Clear Dermatology and Aesthetics Center, 20201N. Scottsdale Healthcare Dr. #260, Scottsdale, Arizona 85255

<sup>3</sup>Sanova Dermatology, 1601 E Pflugerville Pkwy, Bldg 1 Ste 1102, Pflugerville, Texas 78660

<sup>4</sup>Dermatology, Laser & Vein Specialists, 1918 Randolph Rd., Charlotte, North Carolina 28207

<sup>5</sup>Dermatology Associates, 100 White Spruce Blvd, Rochester, New York 14623

<sup>6</sup>Scripps Clinic, 3811 Valley Centre Dr., San Diego, California 92130

**Background and Objectives:** This study describes the effects of nano-pulse stimulation (NPS) technology on the common verruca with the objectives of demonstrating efficacy and safety. NPS technology applies nanosecond pulses of non-thermal electrical energy to induce highly localized regulated cell death in the cellular structures of the targeted zone with negligible effects on surrounding non-cellular structures. Previous clinical studies applying NPS to common, benign skin lesions have demonstrated safety and efficacy in clearing seborrheic keratoses and sebaceous hyperplasia.

**Study Design/Materials and Methods:** Sixty-two subjects were enrolled at a total of five sites. One hundred and ninety-five study verrucae up to 10 mm wide were treated with NPS delivered by a console-based handheld applicator (CellFX<sup>®</sup> System; Pulse Biosciences) and follow-ups occurred every 30 days with the option to retreat at 30, 60, and 90 days. There were 62 untreated controls and 46% of the treated verrucae were recalcitrant.

**Results:** Overall, 75.3% (70/93) of the common verrucae, 72.7% (8/11) of the flat verrucae, and 43.8% (14/32) of the plantar verrucae treated with NPS were completely clear by 60 days following the last treatment and did not recur within the 120-day observation period. The majority (54%) of verrucae cleared with a single NPS procedure. The most common treatment site reactions were erythema (50.5%) and eschar formation (23.4%) on Day 30 and on Day 120 mild erythema was present in 14% of the cases and hyperpigmentation in 18.5%. No serious adverse events were reported. A particle counter was used during 11 NPS procedures on verrucae and no significant plume generation was detected during these procedures.

**Conclusions:** NPS is a safe and effective procedure for removing non-genital, cutaneous verrucae. *Lasers Surg. Med.* © 2021 The Authors. *Lasers in Surgery and Medicine* published by Wiley Periodicals LLC.

**Key words:** cutaneous verrucae; warts; nanosecond; pulsed electric fields; nano-pulse stimulation

## INTRODUCTION

Non-genital verrucae (verruca vulgaris) are common benign lesions resulting from the infection of epidermal cells with the human papillomavirus (HPV). They appear as thickened, round, raised papules on the skin. Common verrucae are most often seen on the hands and present as skin-colored papules with a rough “verrucous” surface. Flat verrucae are most often seen on the backs of the hands and on the legs and appear as slightly elevated, small plaques that are skin-colored or light brown. Plantar verrucae occur on the soles of the feet and look like very thick callouses.

Current treatments for common and flat verrucae involve the destruction of the infected cells. Chemical approaches include daily topical salicylic acid [1], topical cantharidin [2], or intralesional injections of agents with immune activity [3] or cell-killing activity [4]. Physical destruction modalities include freezing the verrucae with liquid nitrogen cryotherapy [5] and burning them off with electrodesiccation [6] or laser treatment [7].

The clinical management of verrucae is challenging, and no treatment strategy has proven to be singularly effective, especially against verrucae that are recalcitrant.

---

This is an open access article under the terms of the Creative Commons Attribution-NonCommercial-NoDerivs License, which permits use and distribution in any medium, provided the original work is properly cited, the use is non-commercial and no modifications or adaptations are made.

**Conflict of Interest Disclosures:** All authors have completed and submitted the ICMJE Form for Disclosure of Potential Conflicts of Interest and have disclosed the following: RN, LJ, and WK are employed by Pulse Biosciences, the manufacturer of one of the medical devices used in this study. EVR and GM are on the advisory board for Pulse Biosciences. The other authors have stated explicitly that they have no conflicts of interest in connection with this article.

\*Correspondence to: Richard Nuccitelli, PhD, Pulse Biosciences, 3957 Point Eden Way, Hayward, CA 94545.

E-mail: rnuccitelli@pulsebiosciences.com

Received 5 January 2021; revised 18 April 2021; Accepted 9 May 2021

Published online 19 May 2021 in Wiley Online Library (wileyonlinelibrary.com).

DOI 10.1002/lsm.23423

We introduce a new, non-thermal energy modality for clearing verrucae called nano-pulse stimulation (NPS). This technology applies ultra-short electrical pulses to cells in a targeted zone and triggers regulated cell death in a highly localized manner. This relatively new cell-focused energy modality has been used in clinical studies with published results demonstrating high safety and efficacy for the skin on the abdomen [8] and face [9] as well as clearing seborrheic keratoses [10] and sebaceous hyperplasia [11].

Much is known about the mechanism by which NPS initiates regulated cell death [12]. The main targets of NPS are the lipid bilayer membranes surrounding the verruca's cells and organelles. The electrical pulses are strong enough to force water molecules into those membranes to form thousands of small, transient nanopores which allow small molecules, such as ions, to cross the membrane barriers. When a sufficient number of these nanopulses are applied to the target area, the cells are stressed by the subsequent increase in intracellular calcium [13] as well as the disruption of ATP production due to loss of mitochondrial membrane potential [14,15] which then initiates a process common to all cells, often called regulated cell death, including apoptosis. This is a slow cell death that may recruit the immune system to phagocytize dead cells and initiate an immune response if any foreign antigens are present. One previous study treating HPV16-transformed tumor cells with NPS demonstrated the initiation of an adaptive immune response [16].

## MATERIALS AND METHODS

### Study Design

This study was designed to determine if NPS energy is safe and effective for the clearance of cutaneous non-genital verrucae. This was a multicenter, unblinded, non-significant risk study under the supervision of the Advarra Institutional Review Board (Protocol #: NP-WP-010) and registered under ClinicalTrials.gov (NCT04554394). It conforms with the US Federal Policy for the Protection of Human Subjects. Verrucae were treated with an applicator that best matched the size of the verruca and delivered the energy listed in Table 1. Follow-up visits were at 7, 30, 60, 90, and 120 days after the initial session for measurements and photography. Four additional sessions were allowed at 30-day intervals if evidence of the verrucae remained.

### Subjects

A total of 62 subjects with a mean age of 47 years participated in this study. A total of 257 study verrucae (195 treated and 62 untreated controls) with an average of 4.1 verrucae per subject were enrolled and evaluated at 60-days post last treatment. Nine subjects discontinued prematurely, and one study center closed after the Day 30 visit due to the restrictions imposed by the COVID-19 pandemic. Data were available from 58 subjects at Day 30, 53 at Day 60, 50 subjects on Day 90, and 53 subjects at Day 120. Of the 257 verrucae, 73% were common, 20.6%

**TABLE 1. Energy Applied With Each Applicator**

Tip Size (mm)	Energy (mJ/mm <sup>3</sup> )
1.5 × 1.5	575
2.5 × 2.5	345
5 × 5	155
7.5 × 7.5	85
10 × 10	85

were plantar and 6.4% were flat verrucae, and the predominant locations were the hand (49.1%) and foot (29.6%). 63.5% of these verrucae were considered recalcitrant (Table 2).

### NPS Technology

Applicator tips were composed of two parallel rows of 2-mm-long microneedles for the three smaller sizes and three rows for the two larger sizes (Fig. 1). The microneedles deliver the energy specified in Table 2 using 200 nanosecond-long, bipolar pulses between the rows as generated by the CellFX System (Pulse Biosciences, Hayward, CA). All verrucae received an injection of lidocaine prior to the procedure. One verruca in each subject was designated as a control and was untreated.

In order to detect any presence and density of plume resulting from the procedure, a condensation particle counter (Model 3007; TSI Inc., Shoreview, MN) was used to measure the average particles per cubic centimeter once per second during 11 verruca procedures.

## RESULTS

Two-thirds of the treatments (65.6%, 128/195) were performed with a 5 mm tip and very few had concomitant curettage (95.4%, 186/195). Overall, 75.3% (70/93) of the common verrucae, 72.7% (8/11) of the flat verrucae, and 43.8% (14/32) of the plantar verrucae treated with NPS were completely clear by 60 days following the last procedure and did not recur within the 120-day observation period. Moreover, 71% (50/70)

**TABLE 2. History of Treated Warts**

Treatment type	N (%)
Cryotherapy	49 (25.1%)
Over-the-counter	40 (20.5%)
Laser	10 (5.1%)
Laser and over-the-counter	8 (4.1%)
Electrocautery	7 (3.6%)
Cantharone and cryotherapy	4 (2.1%)
Investigational product	2 (1%)
Aldara and cryotherapy	1 (0.5%)
Cantharone	1 (0.5%)
Cryotherapy and laser	1 (0.5%)
Yeast injection	1 (0.5%)
No previous treatment	71 (36.4%)




Fig. 1. Five types of applicator tips used in these treatments.

of those completely cleared common verrucae were cleared with only a single procedure session and 94% (66/70) were cleared after two procedure sessions. 76.6% (49/64) of previously untreated verrucae were completely clear by 60 days after the last session as compared with 59.7% (43/72) of the treated recalcitrant verrucae (Fig. 2). This contrasts with only 24.5% of the control verrucae clearing by 120 days.

**Treatment Site Reactions**

Immediately after the procedure, mild erythema and mild edema were observed regardless of location.

The edema subsided over a few days and by Day 30, the most common site reactions were erythema (50.5%) and eschar formation (23.4%) (Table 3). By 60 days post last procedure, most treated regions reverted to normal appearance, but some still exhibited mild erythema (14%) and mild hyperpigmentation (22.8%). Examples of these transient skin reactions can be seen in the photographs illustrating five verruca treatments (Figs. 3–6). By 120 days post-treatment, the treated regions appeared normal and scar-free (Figs. 3E, 4F).

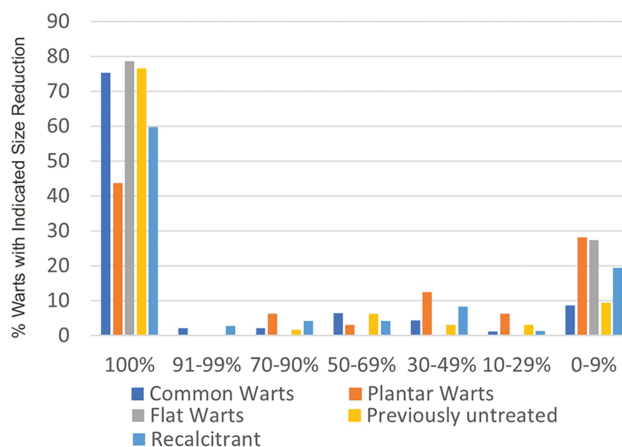


Fig. 2. Percentage of reduction in verruca size measured 60 days after the last nano-pulse stimulation treatment.

Approximately half of the treated verrucae were located on the hand and a typical photographic montage is shown in Figure 3. An example of a pair of knee verrucae that were treated is in Figure 4. Plantar verrucae are

**TABLE 3. Treatment Site Reactions**

Reaction	30 days	60 days post last treatment
Erythema	50.5% (93/184)	14% (19/136)
Hyperpigmentation	15.8% (29/184)	22.8% (31/136)
Hypopigmentation	3.3% (5/164)	5.9% (8/136)
eschar	9.2% (17/184)	10.3% (14/136)
edema	4.4% (8/184)	2.9% (4/136)
crust	23.4% (43/184)	4.4% (6/136)

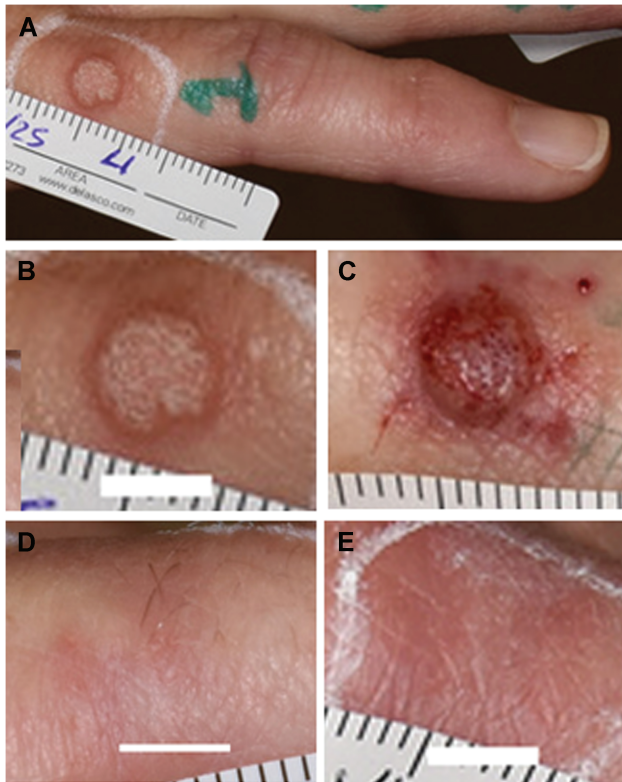

Fig. 3. Recalcitrant finger verruca on a 51-year-old female with Fitzpatrick Class III skin type previously treated with an investigational product. (A–C) Day 0 before and after treatment; (D) Day 60; (E) Day 120. Moderate erythema, crust, and eschar formation were evident on Day 7 and retreatment with nano-pulse stimulation occurred on Day 30. The white scale bar in each image indicates 5 mm.

particularly difficult to eliminate with most common treatments but 43% of those treated with NPS were cleared (Figs. 5 and 6).

#### Adverse Events (AEs)

Eight subjects reported nine treatment-related AEs: transient numbness which improved by Day 7 and was gone by Day 62 [3], suspected infection [3], pain during the procedure [2], and numbness and edema [1]. None of the AEs were severe and all had resolved by study

end. No medical intervention was required for any of these.

#### Procedural Pain

Each subject was asked to score their pain during the treatment on an 11-point scale in which 0 indicates no pain and 10 the worst imaginable pain. Two-thirds of verruca treatments were rated as 0–4, indicating minimal to tolerable pain and only 15% of the treatments were rated above 6. Treatment location was also a factor with the hand exhibiting higher average pain scores than any of the other treatment regions. Differences in pain scores were most likely attributed to differences in the 2% lidocaine injection volumes and the depth of injection.

#### Absence of Plume Generation

Eleven verruca procedures were monitored with a condensation particle counter located within 18 inches of the treated area. No significant plume could be detected during these procedures, which both minimizes the likelihood of airborne viral DNA and differentiates NPS from verruca treatment methods [8] currently used.

#### DISCUSSION

This multicenter study represents the first controlled clinical trial to evaluate the efficacy of NPS technology in the treatment of cutaneous non-genital verrucae. Previous studies treating other skin lesions have demonstrated that NPS induces regulated cell death to cellular components in the epidermis and dermis while sparing the acellular dermal matrix [9–11,17]. The clinical results from this study indicate that the HPV-infected epidermal cells of all three major types of non-genital verrucae were effectively cleared. The 75.3% NPS clearance rate for common verrucae compares quite favorably with the 49% clearance rate reported in the literature for cryotherapy [1,18]. More importantly, this clearance rate required only one or two procedure sessions for 72% of the verrucae whereas cryotherapy often requires more treatments. Moreover, NPS had a 63.5% clearance rate when treating recalcitrant verrucae. The clearance rate for plantar verrucae was only 43.8% and this lower clearance rate is most likely due to the much thicker stratum corneum on the bottom of the foot preventing the short (2 mm) microneedles from reaching the entire verruca. Ongoing studies using 3-mm-long microneedles are in support of this hypothesis thus far.

Another common challenge with verrucae is their high recurrence rate when treated with cryotherapy. None of the 195 verrucae treated with NPS recurred over the 120-day observation period, suggesting that the NPS-cleared verrucae may exhibit a lower rate of recurrence than that observed with other treatment methods.

#### Control Verrucae

The clearance rate for control verrucae was at a level of 24.5%. This suggests that NPS directed to neighboring

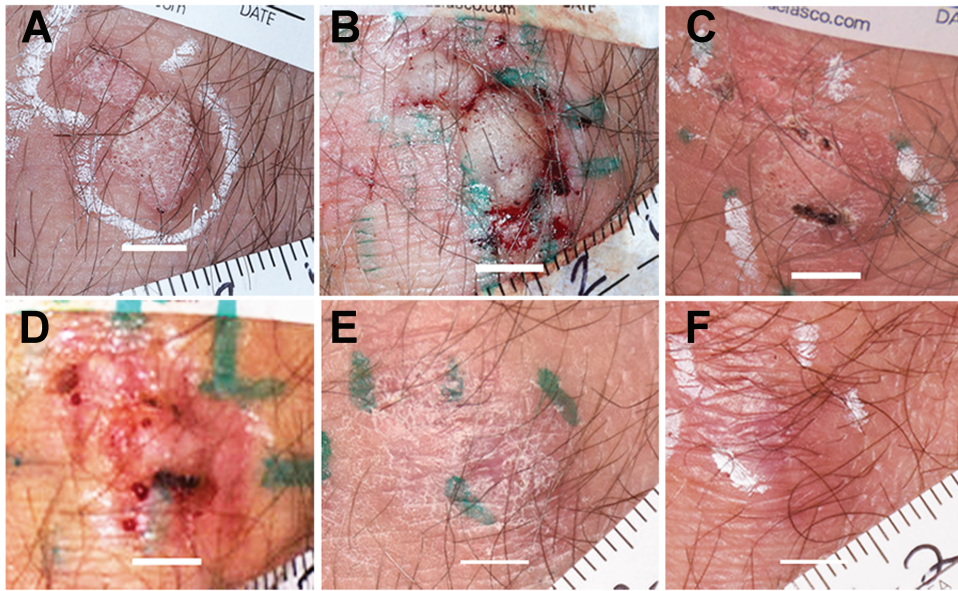


Fig. 4. Knee verrucae on a 53-year-old female with Fitzpatrick Class II skin with no previous treatments. (A and B) Day 0 before and after 1st procedure session; (C and D) Day 30 before and after 2nd session; (E) Day 60; (F) Day 120. Eschar formation and erythema present on Day 30, mild flaking and hyperpigmentation on Day 60, and mild hyperpigmentation and erythema observed on Day 120. White scale bars indicate 5 mm.

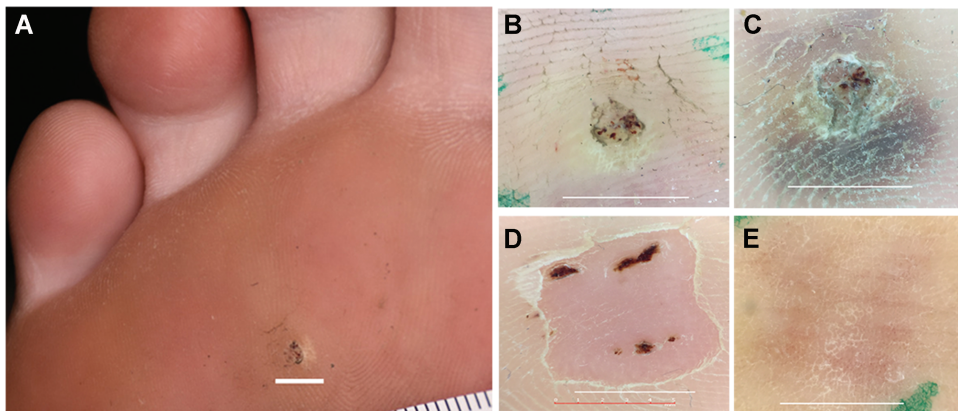


Fig. 5. Recalcitrant plantar verruca on a 21-year-old female with Fitzpatrick Class II skin type previously treated with cryotherapy. (A) Pre-treatment photo and (B) Pre-treatment dermoscope photo, (C) Post-treatment dermoscope photo Day 0 before the only procedure session; (D) Day 30 dermoscope photo; (E) Day 90. Mild hyperpigmentation and eschar formation were present on Day 7 and a crust was present on Day 30. Cleared by Day 90. All white scale bars indicate 5 mm.

verrucae may produce a “bystander” effect or immune system activation to eliminate some of the controls as has been described in previous studies treating verrucae with intralesional injections [19,20]. Complete distant verruca clearance rates ranged from 25% [20] to 64% [21] for these intralesional injection studies.

Further evidence for the stimulation of the immune system by NPS treatments of virus-containing cells came from the treatment of HPV16-transformed

tumors in mice [16]. In that study, a single NPS treatment of the HPV16-transformed tumor initiated an adaptive immune response in 25% of the treated mice causing inhibition of rechallenge tumor growth in a CD8<sup>+</sup>-T-cell-dependent manner. In this study, NPS treatment of HPV-1, -2-containing verrucae may be initiating a similar immune response to viral antigens that supports clearance of some of the control verrucae.

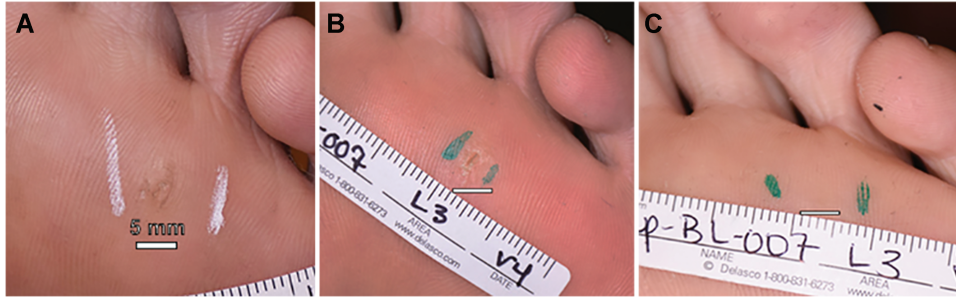


Fig. 6. Recalcitrant plantar verruca treated previously with cryotherapy on a 22-year-old female with Fitzpatrick class II skin type. (A) Before procedure; (B) Day 60; (C) Day 90. Mild flaking was observed on Day 60. All white scale bars indicate 5 mm.

## CONCLUSIONS

The new, non-thermal, cell-focused modality of NPS exhibits a 75.3% clearance rate of common verrucae, 72.7% of flat verrucae, and 43.8% of plantar verrucae, with the majority clearing in one NPS session. Additionally, none of these cleared verrucae recurred within the 120-day observation period. Most were cleared with only one or two procedure sessions in which the delivery of NPS pulses was less than a minute long. There were no serious adverse reactions and the result of all the NPS procedures was scar-free, re-epithelialized skin.

## ACKNOWLEDGMENT

This work was funded entirely by Pulse Biosciences, Inc.

## REFERENCES

- Dall'oglio F, D'Amico V, Nasca MR, Micali G. Treatment of cutaneous warts: An evidence-based review. *Am J Clin Dermatol* 2012;13(2):73–96.
- Vakharia PP, Chopra R, Silverberg NB, Silverberg JI. Efficacy and Safety of topical cantharidin treatment for molluscum contagiosum and warts: A systematic review. *Am J Clin Dermatol* 2018;19(6):791–803.
- Muse ME, Stiff KM, Glines KR, Cline A, Feldman SR. A review of intralesional wart therapy. *Dermatol Online J* 2020;26(3). Retrieved from <https://escholarship.org/uc/item/3md9z8gj>.
- Bik L, Sangers T, Greveling K, Prens E, Haedersdal M, van Doorn M. Efficacy and tolerability of intralesional bleomycin in dermatology: A systematic review. *J Am Acad Dermatol* 2020;83(3):888–903.
- Bruggink SC, Gussekloo J, Berger MY, et al. Cryotherapy with liquid nitrogen versus topical salicylic acid application for cutaneous warts in primary care: Randomized controlled trial. *CMAJ* 2010;182(15):1624–1630.
- Singh S, Neema S. Comparison of electrosurgery by electrodesiccation versus cryotherapy by liquid nitrogen spray technique in the treatment of plantar warts. *Med J Armed Forces India* 2020;76(2):156–160.
- Nguyen J, Korta DZ, Chapman LW, Kelly KM. Laser treatment of nongenital verrucae: A systematic review. *JAMA Dermatol* 2016;152(9):1025–1034.
- Sawchuk WS, Weber PJ, Lowy DR, Dzubow LM. Infectious papillomavirus in the vapor of warts treated with carbon dioxide laser or electrocoagulation: Detection and protection. *J Am Acad Dermatol* 1989;21(1):41–49.
- Kaufman D, Martinez M, Jauregui L, et al. A dose-response study of a novel method of selective tissue modification of cellular structures in the skin with nanosecond pulsed electric fields. *Lasers Surg Med* 2020;52(1):315–3322.
- Hruza GJ, Zelickson BD, Selim MM, et al. Safety and efficacy of nanosecond pulsed electric field treatment of seborrheic keratoses. *Dermatol Surg* 2019;46:1183–1189.
- Munavalli GS, Zelickson BD, Selim MM, et al. Safety and efficacy of nanosecond pulsed electric field treatment of sebaceous gland hyperplasia. *Dermatol Surg* 2019;46 (Oct 4):803–809.
- Nuccitelli R. Nano-pulse stimulation therapy for the treatment of skin lesions. *Bioelectricity* 2019;1:235–239.
- Vernier PT, Sun Y, Marcu L, Salemi S, Craft CM, Gundersen MA. Calcium bursts induced by nanosecond electric pulses. *Biochem Biophys Res Commun* 2003;310(2):286–295.
- Nuccitelli R, McDaniel A, Connolly R, Zelickson B, Hartman H. Nano-pulse stimulation induces changes in the intracellular organelles in rat liver tumors treated in situ. *Lasers Surg Med* 2020;52(4):882–889.
- Vernier PT. Mitochondrial membrane permeabilization with nanosecond electric pulses. *Conf Proc IEEE Eng Med Biol Soc* 2011;2011(743-5):743–745.
- Skeate JG, Da Silva DM, Chavez-Juan E, Anand S, Nuccitelli R, Kast WM. Nano-pulse stimulation induces immunogenic cell death in human papillomavirus-transformed tumors and initiates an adaptive immune response. *PLOS One* 2018;13(1):e0191311.
- Newman J, Jauregui L, Knappe WA, et al. A dose-response study of nanosecond electric energy pulses on facial skin. *J Cosmet Laser Ther* 2020;22(4-5):195–199.
- Kwok CS, Holland R, Gibbs S. Efficacy of topical treatments for cutaneous warts: A meta-analysis and pooled analysis of randomized controlled trials. *Br J Dermatol* 2011;165(2):233–246.
- Gonçalves MA, Donadi EA. Immune cellular response to HPV: Current concepts. *Braz J Infect Dis* 2004;8(1):1–9.
- Abd-Elazeim FM, Mohammed GF, Fathy A, Mohamed RW. Evaluation of IL-12 serum level in patients with recalcitrant multiple common warts, treated by intralesional tuberculin antigen. *J Dermatolog Treat* 2014;25(3):264–267.
- Clifton MM, Johnson SM, Roberson PK, Kincannon J, Horn TD. Immunotherapy for recalcitrant warts in children using intralesional mumps or Candida antigens. *Pediatr Dermatol* 2003;20(3):268–271.