

CORRECTION

Open Access

Correction to: Drusen characteristics of type 2 macular neovascularization in age-related macular degeneration



Daniel Ahmed^{1,2†}, Martin Stattin^{1,2†}, Anna-Maria Haas^{1,2}, Alexandra Graf³, Katharina Krepler^{1,2} and Siamak Ansari-Shahrezaei^{1,2,4*}

Correction to: BMC Ophthalmol (2020) 20:381

<http://orcid.org/10.1186/s12886-020-01651-2>

Following publication of the original article [1], we were notified that Fig. 1 was incorrect. Figure 1 was meant to picture Drusen $\geq 63 \mu\text{m}$ and SDD, however a duplicate of Fig. 3 was published. The correct Fig. 1 with its respective legend is displayed below.

Author details

¹Karl Landsteiner Institute for Retinal Research and Imaging, Vienna, Austria.

²Department of Ophthalmology, Rudolf Foundation Hospital, Juchgasse 25, 1030 Vienna, Austria. ³Center for Medical Statistic, Informatics, and Intelligent Systems, Medical University of Vienna, Spitalgasse 23, 1090 Vienna, Austria.

⁴Department of Ophthalmology, Medical University of Graz, Auenbruggerplatz 1, 8036 Graz, Austria.

Published online: 27 October 2020

Reference

1. Ahmed D, et al. Drusen characteristics of type 2 macular neovascularization in age-related macular degeneration. *BMC Ophthalmol.* 2020;20:381. <https://doi.org/10.1186/s12886-020-01651-2>.

The original article can be found online at <https://doi.org/10.1186/s12886-020-01651-2>.

* Correspondence: siamak.ansari-shahrezaei@wienkav.at; siamak.ansarishahrezaei@wienkav.at

[†]Daniel Ahmed and Martin Stattin contributed equally to this work.

¹Karl Landsteiner Institute for Retinal Research and Imaging, Vienna, Austria

²Department of Ophthalmology, Rudolf Foundation Hospital, Juchgasse 25, 1030 Vienna, Austria

Full list of author information is available at the end of the article



© The Author(s). 2020 **Open Access** This article is licensed under a Creative Commons Attribution 4.0 International License, which permits use, sharing, adaptation, distribution and reproduction in any medium or format, as long as you give appropriate credit to the original author(s) and the source, provide a link to the Creative Commons licence, and indicate if changes were made. The images or other third party material in this article are included in the article's Creative Commons licence, unless indicated otherwise in a credit line to the material. If material is not included in the article's Creative Commons licence and your intended use is not permitted by statutory regulation or exceeds the permitted use, you will need to obtain permission directly from the copyright holder. To view a copy of this licence, visit <http://creativecommons.org/licenses/by/4.0/>. The Creative Commons Public Domain Dedication waiver (<http://creativecommons.org/publicdomain/zero/1.0/>) applies to the data made available in this article, unless otherwise stated in a credit line to the data.

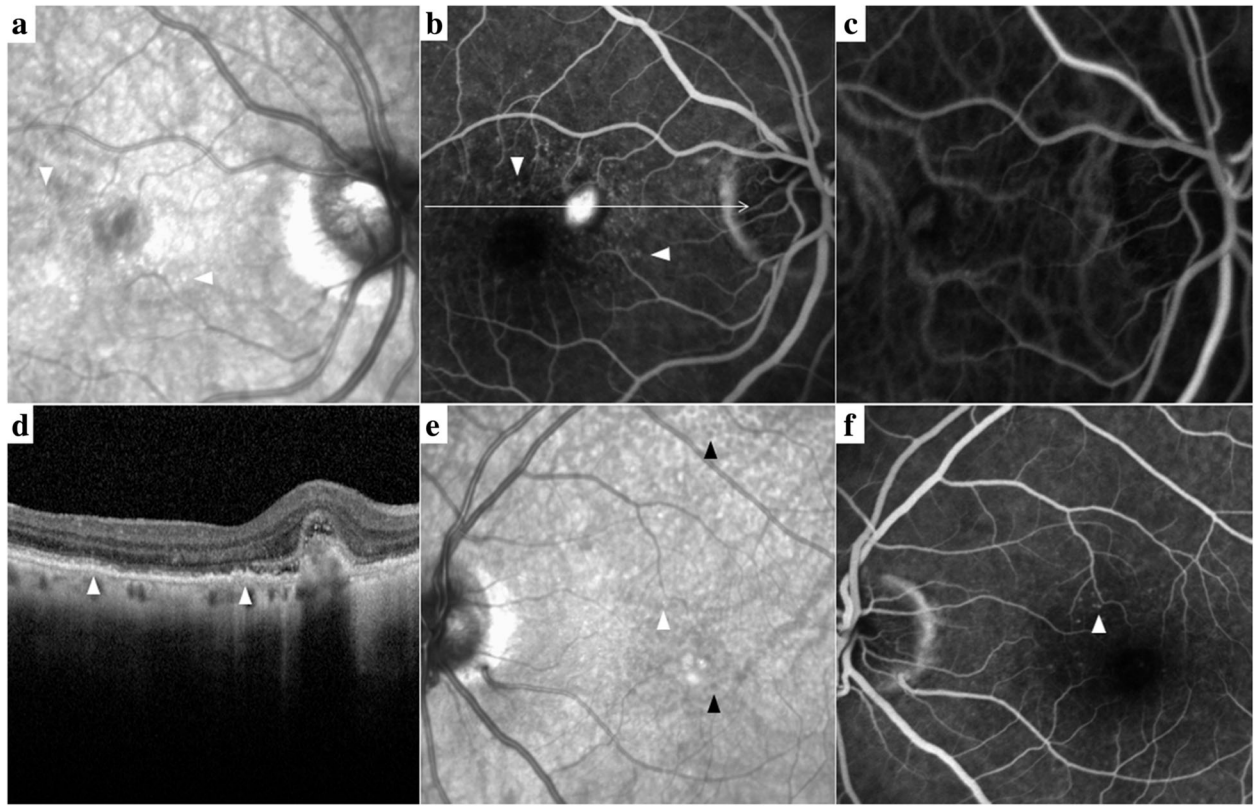


Fig. 1 Multimodal imaging of type 2 MNV, Drusen $\geq 63 \mu\text{m}$ and SDD. **a** Drusen $\geq 63 \mu\text{m}$ (arrowheads) displayed in IR. **b** FA with early MNV leakage and drusen staining (scan line). **c** ICGA revealed a circumscribed MNV besides choroidal vessels under speckled hypocyancence. **d** SD-OCT B-scan section through the lesion illustrated soft drusen (arrowheads) and a thin SFCT ($109 \mu\text{m}$). **e** Drusen > 63 (white arrowhead) and SDD (black arrowheads) visualized in the patient's fellow eye as demonstrated in IR and **f** soft drusen staining in late FA