

PD-1/PD-L1 immune checkpoint in bone and soft tissue tumors (Review)

KAZUHIKO HASHIMOTO, SHUNJI NISHIMURA and KOJI GOTO

Department of Orthopedic Surgery, Kindai University Hospital, Osaka-Sayama, Osaka 589-8511, Japan

Received December 8, 2024; Accepted January 22, 2025

DOI: 10.3892/mco.2025.2826

Abstract. Anti-programmed cell death 1 (PD-1)/PD-1 ligand-1 (PD-L1) drugs have been used clinically, including those for skin cancer, with reasonable efficacy. Despite extensive ongoing research on bone and soft tissue sarcomas, there is a paucity of reviews that present a coherent picture. The present article is a comprehensive narrative review on the role of the PD-1/PD-L1 immune checkpoint in bone and soft tissue tumors. The review outlines the biological functions and mechanisms of action of PD-1/PD-L1 and its expression and clinical significance in various tumor types, including osteosarcoma and soft tissue sarcoma. Clinical trial results of immune checkpoint inhibitors, their association with prognosis, mechanisms of resistance to therapy, immune-related adverse events, and their potential in combination therapies, were also discussed.

Contents

1. Introduction
2. Biological role and mechanism of PD-1/PD-L1
3. PD-1/PD-L1 expression in bone and soft tissue tumors
4. Clinical trials of ICIs
5. PD-1/PD-L1 expression and prognosis
6. Mechanisms of resistance to PD-1/PD-L1 blockade
7. Clinical and preclinical studies (2009-2014)
8. Immune-related adverse events (iRAEs)
9. Combination therapy of PD-1/PD-L1 ICIs and other treatments
10. Future directions
11. Conclusions

Correspondence to: Dr Kazuhiko Hashimoto, Department of Orthopedic Surgery, Kindai University Hospital, Ohnohigashi 377-2, Osaka-Sayama, Osaka 589-8511, Japan
Email: hazzhiko@med.kindai.ac.jp

Abbreviations: PD-1, programmed cell death 1; PD-L1, programmed cell death ligand-1

Key words: PD-1/PD-L1, bone and soft tissue tumors, review

1. Introduction

Programmed cell death protein 1 (PD-1) and its ligand PD-L1 are crucial immune checkpoint molecules which regulate the immune response. PD-1 is a receptor protein present on the surface of T cells and other immune cells. It plays a role in suppressing T-cell activity for appropriate immune response control (1). PD-1 was discovered in 1992 as a gene associated with programmed cell death (2). However, subsequent research revealed that PD-1 primarily functions as an immune checkpoint (3). PD-L1 protein is present mainly on the surface of tumor cells and some normal cells (3). PD-L1 is expressed in numerous tissues, but is relatively more abundant on tumor cells (4). When PD-L1 binds to PD-1, it suppresses T-cell attack and weakens the immune response (3), allowing tumor cells to evade the immune system. The PD-1/PD-L1 pathway is an important target in cancer immunotherapy (4). Drugs that block PD-1 and PD-L1 (immune checkpoint inhibitors; ICIs) have enabled great progress in cancer treatment (5). Their effectiveness has been confirmed in numerous types of cancer, including melanoma, non-small cell lung cancer and renal cell carcinoma (6). Recently, systematic reviews have addressed the relationship between PD-1/PD-L1 immune checkpoint mechanisms and bone and soft tissue tumors; however, limited comprehensive reviews have summarized the long-term outcomes of ICIs, including their side effects. This gap highlights the need for more robust evidence regarding the efficacy and safety of these therapies in the context of sarcomas (7-9). The present review examines PD-1/PD-L1 expression in bone and soft tissue tumors, focusing on their clinical significance, based on studies conducted between 2009-2024.

2. Biological role and mechanism of PD-1/PD-L1

PD-1 is an inhibitory receptor expressed on activated T cells, B cells, and myeloid cells. Its ligand, PD-L1, is expressed on cells, including tumor cells within the tumor microenvironment (Figs. 1 and 2). The interaction between PD-1 and PD-L1 inhibits T-cell function, allowing tumors to evade immune surveillance. This mechanism is central to the development of ICIs which block PD-1/PD-L1 interaction, restoring T-cell activity and enhancing antitumor immunity (10,11).

3. PD-1/PD-L1 expression in bone and soft tissue tumors

Osteosarcoma. Osteosarcoma is the most common primary malignant bone tumor and predominantly affects adolescents and young adults. PD-L1 expression in osteosarcoma is associated with poor prognosis, indicating its potential as a prognostic marker (11). Previously, the authors evaluated preoperative needle biopsy specimens from 16 patients with osteosarcoma, performing immunostaining for CD4, CD8, PD-1 and PD-L1 (11). The findings revealed that 75% of specimens were positive for both CD4 and CD8, while PD-1 and PD-L1 positivity rates were 18.7 and 62.5%, respectively. Notably, the tumors were larger in PD-L1-negative cases than those in PD-L1-positive cases. Furthermore, high PD-L1 expression correlates with increased tumor invasiveness and metastatic potential, suggesting that PD-1/PD-L1 blockade may be a suitable therapeutic strategy (11). Other studies have supported that PD-L1 expression in osteosarcoma cells may contribute to immune evasion and tumor progression (Fig. 3). Paydas *et al* (12) found that PD-L1 expression is significantly higher in metastatic osteosarcoma than that in non-metastatic cases and correlates with shorter overall and disease-free survival.

Soft tissue sarcomas (STSs). STSs are a heterogeneous group of malignancies arising from mesenchymal tissues. PD-L1 expression varies among STS subtypes. The expression rate of PD-1 is in the range of 12.2-28.3% and that of PD-L1 is 10.7-31.7% (13-16). In addition, dedifferentiated liposarcoma exhibits higher expression levels of PD-1, PD-L1 and PD-L2 than those in other sarcoma subtypes. These elevated expression levels suggest a potential immunosuppressive environment which may contribute to the tumor's ability to evade immune detection and response. Investigating these expression patterns is crucial for developing targeted therapies that leverage ICIs in treating dedifferentiated liposarcoma (15). It was previously demonstrated that PD-L1 is more frequently expressed in high-grade sarcomas (17), which are associated with poor clinical outcomes, suggesting that PD-1/PD-L1 inhibitors may benefit patients harboring tumors with high PD-L1 expression. Studies by Kim *et al* (18) and Anastasiou *et al* (9) revealed that PD-L1 expression is prevalent in certain STS subtypes, such as undifferentiated pleomorphic sarcoma and leiomyosarcoma, suggesting a potential role of ICIs in these subtypes, particularly when conventional therapies fail. They found that PD-L1 is expressed in significant number of cases and is associated with relatively poor overall survival (OS) rates (11 and 19 months for patients positive and negative for PD-L1, respectively). In addition, Anastasiou *et al* (9) reviewed the role of ICIs in sarcomas, highlighting their potential and limitations. They reported that monotherapies with ICIs exhibit inadequate responses in sarcomas, while combinations with targeted therapies, such as TKIs and anti-CTLA-4, have demonstrated promising results, particularly in alveolar soft part sarcomas. The aforementioned study emphasized that although certain sarcoma subtypes, such as undifferentiated pleomorphic sarcoma, exhibit the prevalence of tertiary lymphoid structures and may have improved response to ICIs, further research is necessary to identify predictive biomarkers for treatment efficacy.

In high-grade STSs, PD-L1 expression is associated with increased tumor aggressiveness and poor prognosis. Despite multidisciplinary treatments, including extensive resection, high-grade STSs have a high recurrence rate and poor prognosis (19). It was found that PD-1 and PD-L1 expression levels in these sarcomas can serve as biomarkers for identifying patients who may benefit from immune checkpoint blockade therapy (20,21). These findings are supported by those of D'Angelo *et al* (22), who demonstrated the clinical activity of pembrolizumab, an anti-PD-1 antibody, in patients with PD-L1-expressing advanced sarcomas.

Desmoid tumors. Desmoid tumors, also known as aggressive fibromatosis, are benign but locally invasive soft tissue tumors. The PD-1/PD-L1 immune checkpoint mechanism is reportedly active in desmoid tumors (23). This research included biopsy and resection samples from patients diagnosed with desmoid tumors, focusing on the immunohistochemical assessment of PD-L1 expression. The findings revealed that while PD-L1 was expressed in the tumor microenvironment, all patients were negative for PD-1. However, low PD-L1 expression was found in desmoid tumors, which may reflect their benign nature (24); some desmoid tumors exhibit PD-1/PD-L1 expression, indicating a possible, albeit limited, role for immunotherapy in selected patients.

Angiosarcoma. Angiosarcoma is a rare and aggressive malignancy of endothelial cell origin (25). The importance of the PD-1/PD-L1 pathway in angiosarcoma (26). In particular, high PD-L1 expression may be a target for immunotherapy (26). The aforementioned study discussed the role of the PD-1/PD-L1 pathway in cancer, further emphasizing its significance in immune regulation and tumor progression. PD-L1 serves as a critical immune checkpoint which inhibits T cell activation when it binds to PD-1, thus promoting immune evasion by tumors. The authors have explored the following dual functions of PD-L1: its role in suppressing antitumor immunity and its pro-oncogenic signaling which enhances cancer cell survival and resistance to apoptosis. The research also highlights the therapeutic potential of targeting this pathway with ICIs, which have demonstrated promising potential in treating various cancers. High PD-L1 expression has been confirmed in some patients with angiosarcoma (27), suggesting that immunotherapy (for example, PD-1/PD-L1 inhibitors) may be effective. A previous study reported that ~40% of tumor samples from patients with angiosarcoma are PD-L1-positive. In this patient population, the use of PD-1 inhibitors resulted in tumor shrinkage and disease stabilization (28). Significant tumor shrinkage was observed in some patients with advanced angiosarcoma in a clinical trial using PD-1/PD-L1 inhibitors (29). It was found that PD-1, PD-L1 and other immunogenic markers such as NY-ESO-1 and MAGE-A4 are expressed in cutaneous angiosarcoma, suggesting that multitargeted immunotherapy may be a promising approach for this aggressive cancer (20,21).

4. Clinical trials of ICIs

Several clinical trials have investigated the efficacy of PD-1/PD-L1 inhibitors in bone and soft tissue tumors. The

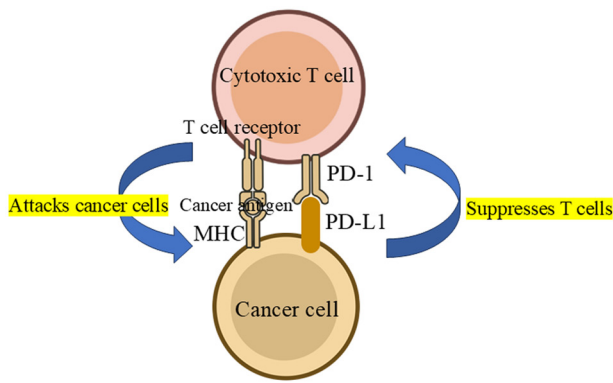


Figure 1. PD-1/PD-L1 immune checkpoint mechanism. The PD-1/PD-L1 immune checkpoint mechanism involves the interaction between the PD-1 receptor on T cells and the PD-L1 ligand on cancer cells. When PD-1 binds to PD-L1, it inhibits T cell activation, allowing cancer cells to evade the immune response. Immune checkpoint inhibitors, such as pembrolizumab, block this interaction, thereby enhancing T cell activity and promoting an effective antitumor immune response. This mechanism is crucial in cancer immunotherapy, particularly for certain types of sarcomas and other malignancies. PD-1, programmed cell death 1; PD-L1, programmed cell death ligand-1; MHC, major histocompatibility complex.

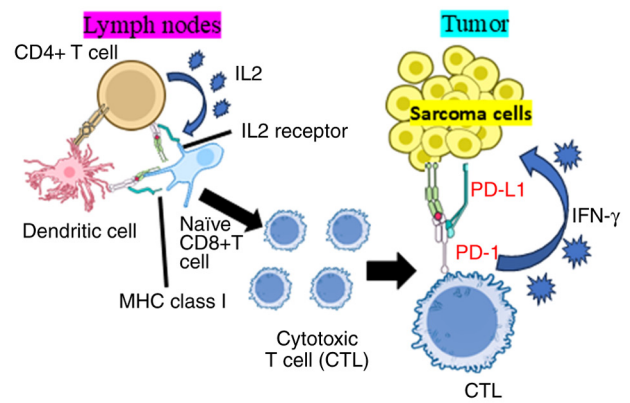


Figure 3. Potential PD-1/PD-L1 immune checkpoint mechanism in the bone and soft tissue tumor microenvironment. The PD-1/PD-L1 immune checkpoint mechanism involves both CD4⁺ and CD8⁺ T cells in regulating immune responses against tumors. CD8⁺ T cells, which are crucial for directly eliminating cancer cells, express PD-1 which binds to PD-L1 on tumor cells, inhibiting their function. Similarly, activated CD4⁺ T cells can also express PD-1, further contributing to immune suppression. Tumors often exploit this pathway by upregulating PD-L1, allowing them to evade immune detection. Immune checkpoint inhibitors targeting PD-1 or PD-L1 can block this interaction, restoring the activity of both T cell populations and enhancing antitumor immunity. PD-1, programmed cell death 1; PD-L1, programmed cell death ligand-1; MHC, major histocompatibility complex; IFN, interferon.

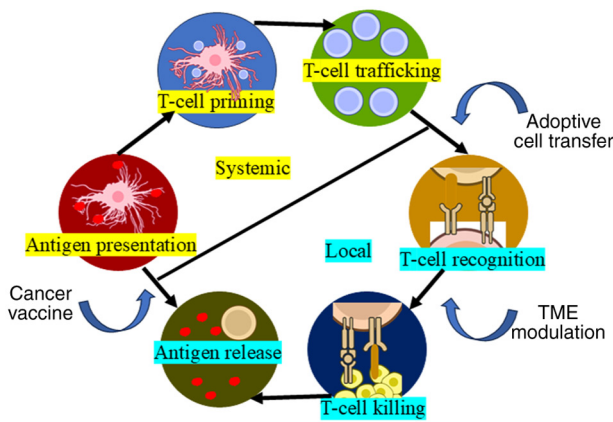


Figure 2. PD-1/PD-L1 immune checkpoint mechanism involving both systemic and local cycles. Systemically, activated T cells express PD-1, which binds to PD-L1 on cancer cells, inhibiting T cell activation and allowing tumors to evade the immune response. Locally, within the tumor microenvironment, cancer cells and surrounding support cells also express PD-L1, further suppressing T cell function. Immune checkpoint inhibitors block this interaction, enhancing T cell activity and promoting a stronger anti-tumor immune response. PD-1, programmed cell death 1; PD-L1, programmed cell death ligand-1.

PD-1 inhibitors pembrolizumab and nivolumab have been evaluated in various sarcoma subtypes. The SARCO28 trial demonstrated significant activity of pembrolizumab in undifferentiated pleomorphic sarcoma and liposarcoma, leading to ongoing investigations into combination therapies and in other sarcoma subtypes (30). This trial included two cohorts and enrolled 86 patients, with 84 receiving pembrolizumab. The overall objective response rate was 18%, with notable responses observed in undifferentiated pleomorphic sarcoma (40% response) and dedifferentiated liposarcoma. Despite the promising results in specific subtypes, the primary endpoint of overall response was not met for either cohort. The study also reported various grade 3 or higher adverse

events, highlighting the need for further investigating the efficacy of pembrolizumab in these sarcomas. Nivolumab in combination with the a CTLA-4 inhibitor ipilimumab showed promising results in heavily pretreated patients with sarcoma, high-lighting the potential for synergistic effects in enhancing antitumor immunity (22). A total of 85 eligible patients were randomized to receive either nivolumab monotherapy or a combination of nivolumab and ipilimumab. The results showed an objective response rate of 5% in the nivolumab group and 16% in the combination group. Serious but manageable treatment-related adverse events occurred in both the groups. The findings suggest that while nivolumab alone may not warrant further investigation in unselected sarcoma populations, the combination with ipilimumab demonstrated promising efficacy, particularly in certain sarcoma subtypes, indicating the need for further randomized studies to validate these results.

5. PD-1/PD-L1 expression and prognosis

PD-1/PD-L1 expression is associated with prognosis in various bone and soft tissue tumors. High PD-L1 expression generally correlates with poor outcomes, including low OS and high recurrence rates. For example, patients with osteosarcoma and high PD-L1 expression tend to have worse survival rates than those with low PD-L1 expression. Similarly, in STSs, high PD-L1 expression is often associated with more aggressive disease and lower survival rates. Additionally, higher PD-1 expression levels in synovial sarcoma are associated with shorter progression-free survival (PFS) rates. This correlation suggests that increased PD-1 expression may contribute to a more immunosuppressive tumor microenvironment, negatively impacting the efficacy of the immune response and leading to poorer clinical outcomes (31). These findings underscore the

potential of PD-1/PD-L1 as both a prognostic marker and a therapeutic target in such malignancies (11,12).

However, it remains controversial whether high or low expression of PD-1/PD-L1 immune molecules correlates with prognosis. One reason for this is the exhaustion of T cells in the tumor microenvironment (32).

T cells that are definitively induced may no longer be able to function in the tumor microenvironment, even when they have colonized it. Miyake *et al* (15) reported that the expression rates of PD-1, PD-L1 and PD-L2 are not associated with prognosis; however, high Ki67 expression was identified as a significant factor for poor prognosis. This finding highlights the importance of Ki67 as a marker for tumor proliferation and its potential role in predicting clinical outcomes in patients (15).

6. Mechanisms of resistance to PD-1/PD-L1 blockade

Despite the promising results of PD-1/PD-L1 inhibitors, resistance to these therapies remains a significant challenge. Mechanisms of resistance include adaptive immune resistance, in which tumors upregulate PD-L1 in response to immune pressure, and intrinsic resistance, involving genetic and epigenetic changes within the tumor cells. A study by Martin *et al* (33) highlighted the role of the tumor microenvironment in mediating therapy resistance. Factors such as tumor-associated macrophages, regulatory T cells, and myeloid-derived suppressor cells can inhibit the antitumor immune response, even in the presence of PD-1/PD-L1 blockade (33). Combining PD-1/PD-L1 inhibitors with other therapeutic modalities, such as chemotherapy, radiotherapy, or other immunotherapies, may help overcome resistance. Studies are in progress to identify the most effective combination strategies to enhance the efficacy of ICIs in bone and soft tissue tumors (22).

7. Clinical and preclinical studies (2009-2014)

Between 2009 and 2014, foundational studies laid the groundwork for elucidating the role of PD-1/PD-L1 in various cancers, including bone and soft tissue tumors. The role of PD-1/PD-L1 in immune evasion was first characterized in melanoma and lung cancer, providing a rationale for exploring these pathways in other cancers types.

Preclinical studies. Preclinical studies have demonstrated that PD-L1 is upregulated in response to immune attack, suggesting that targeting this pathway may enhance antitumor immunity. In this regard, Dong *et al* (10) established that PD-L1 on tumor cells inhibits T-cell function, which is pivotal in understanding the tumor immune escape mechanism. In sarcomas, initial studies focused on assessing PD-L1 expression and its impact on the tumor microenvironment. These studies provided evidence that, similar to other solid tumors, sarcomas can evade the immune system via PD-1/PD-L1 interaction. Chen and Han (34) found that PD-L1 expression in sarcoma cell lines was associated with resistance to T cell-mediated cytotoxicity, supporting the potential for PD-1/PD-L1 blockade in these tumors.

Clinical studies. Clinical studies conducted between 2009-2014 focused primarily on the safety and preliminary

efficacy of PD-1/PD-L1 inhibitors. Early-phase trials in melanoma and lung cancer demonstrated durable responses and manageable toxicity, paving the way for trials in other cancers, including sarcomas. Topalian *et al* (35) conducted a land-mark phase I trial of nivolumab in patients with various cancers, including melanoma, demonstrating promising antitumor activity and durable responses. Brahmer *et al* (36) evaluated PD-1 blockade with pembrolizumab in solid tumors, including a small cohort of patients with sarcoma. Although the response rate was lower in sarcomas than that in melanoma and lung cancer, the aforementioned study highlighted the potential for PD-1/PD-L1 blockade in sarcomas and provided a platform for more focused trials.

Clinical studies (2014-2024). Italiano *et al* (37) performed a combined analysis of data from multiple phase II trials to assess the efficacy of PD-1/PD-L1-targeted therapy in advanced soft tissue sarcoma. This analysis included 384 patients, 153 of whom received PD-1/PD-L1 inhibitor monotherapy. The overall response rate for monotherapy was 15.1%, and the non-progression rate was 58.5%. Based on histology, focal soft-tissue sarcomas and anaplastic pleomorphic sarcomas had the highest response rates, while leiomyosarcomas had the lowest response rates. PD-L1 expression rates were generally low and not consistently associated with objective response. The investigators concluded that PD-1/PD-L1 inhibitors demonstrate only limited efficacy in the unselected soft-tissue sarcoma patient population and recommended stratification for sarcoma heterogeneity and longitudinal blood and tissue sampling in future studies.

Somaiah *et al* (38) evaluated the efficacy and safety of the dervalumab and tremelimumab combination in a single-center phase II trial in patients with advanced or metastatic soft tissue and osteosarcoma. Among the 62 enrolled patients, 57 were treated, with 37.2 months of follow-up and a 12-week point-of-care. The PFS rate was 49%, and the median OS (mOS) was 17.4 months. The most common adverse events were lipase elevation, colitis and pneumonia, with one patient experiencing a grade 5 adverse event. The investigators concluded that the combination was active against advanced or metastatic sarcoma and warrants further evaluation in specific subsets.

Gordon *et al* (39) conducted a phase I/II trial evaluating the safety and efficacy of the combination of ipilimumab, nivolumab and trabectedin (SAINT regimen) as primary therapy for advanced soft tissue sarcoma. In Phase I, the maximum tolerated dose of trabectedin was 1.2 mg/m² in nine previously treated patients. In Phase II, 79 untreated patients were evaluated; the results showed six complete responses, 14 partial responses and 49 stable responses, with a best response rate of 25.3% and a disease control rate of 87.3%. The median PFS (mPFS) was 6.7 months and the mOS was 24.6 months. In terms of safety, the most common Grade 3/4 treatment-related adverse events reported were alanine aminotransferase elevation (25%), fatigue (8.7%), aspartate aminotransferase elevation (8.7%), neutropenia (5.4%) and anemia (4.6%). The researchers concluded that the SAINT regimen is a safe and effective first-line treatment for advanced soft-tissue sarcoma. The aforementioned study represents a new therapeutic approach combining ICIs and conventional chemotherapy

and provides important implications for treatment strategies against soft-tissue sarcoma.

The SU2C-SARC032 trial is a Phase II randomized study focusing on 127 patients with high-risk extremity soft tissue sarcoma, primarily including undifferentiated pleomorphic sarcoma and dedifferentiated/mixed-type liposarcoma across 20 medical institutions (40). The trial assessed the efficacy of pembrolizumab administered preoperatively for three cycles and postoperatively for up to 14 cycles, with the primary endpoint being the two-year disease-free survival rate. Results indicated that pembrolizumab administration reduced the risk of cancer recurrence by 43% after two years, highlighting its effectiveness in treating soft tissue sarcoma.

Liao *et al* (41) conducted a two-center study evaluating the efficacy and safety of PD-1 inhibitor-based immunotherapy in patients with sarcoma, including both monotherapy and combination therapy. Among 37 patients with advanced or unresectable tumors, the mPFS was 5 months and mOS was 13 months. mPFS and mOS were not significantly different between PD-1 inhibitors in combination with targeted therapy and in combination with chemotherapy. There were no significant differences in mPFS and mOS between PD-1 inhibitors plus targeted therapy and chemotherapy. The six patients who received adjuvant therapy demonstrated a longer mPFS of 15 months. The investigators concluded that this immunotherapy is effective against sarcoma and has a manageable safety profile.

Babatunde *et al* (42) performed a retrospective single-center study which evaluated the efficacy of ICI-based therapy in 60 patients with leiomyosarcoma. The findings revealed an mPFS of 8.43 weeks and an overall response rate of 6.67% (four patients). Of note, two of the four patients demonstrating partial responses had BRCA1 or BRCA2 mutations. Thus, while the aforementioned study suggested that the overall effect of ICI treatment for leiomyosarcoma is limited, patients with LMS and specific molecular profiles (such as BRCA1/2 mutations) may benefit from ICI.

8. Immune-related adverse events (iRAEs)

PD-1/PD-L1 inhibitors are widely used as part of cancer immunotherapy, but they can cause side effects called iRAEs (43). While PD-1/PD-L1 inhibitors enhance the antitumor activity of T cells and prevent the immune escape of tumor cells, they can over-activate autoimmune responses, causing iRAEs (44).

Main iRAEs. iRAEs can affect various organs of the body, and the following symptoms have been reported (45): Skin disorders, including rash, itching and psoriasis-like dermatitis. Gastrointestinal disorders such as diarrhea, colitis and hepatitis have also been identified. Endocrine disorders comprise thyroid dysfunction, diabetes and adrenal insufficiency. Reported lung disorders include pneumonia and interstitial pneumonia, and neuropathies include peripheral neuropathy and central nervous system disorders (for example, encephalitis and meningitis).

Frequency and severity of iRAEs. The frequency of iRAEs varies depending on the type of treatment and the patient's condition, but it is generally considered that 10-30% of patients

develop some form of iRAE (46). In total, ~3.5% of iRAE cases are severe and require hospitalization for treatment (46). In most cases, symptoms are mild to moderate and can be managed with steroid treatment; however, in severe cases, treatment may need to be interrupted or immunosuppressants may be used (47).

Management of iRAEs. Early detection and prompt treatment are important for managing iRAEs (48). Regular monitoring and patient education are recommended, and patients are required to immediately visit a medical institution if symptoms appear. For treating mild cases, local treatment and low-dose steroids are used, and for moderate to severe cases, systemic steroids and immunosuppressants (such as methotrexate and azathioprine) are used (46,47,49).

9. Combination therapy of PD-1/PD-L1 ICIs and other treatments

PD-1/PD-L1 ICIs may be not sufficiently effective, and several combination therapies have recently been evaluated (50).

PD-1/PD-L1 inhibitors combined with chemotherapy. Gandhi *et al* (51) reported that the combination of chemotherapy and a PD-1 inhibitor (pembrolizumab) is more effective than conventional treatment in patients with metastatic non-small cell lung cancer. Lynch *et al* (52) treated 30 patients with advanced sarcoma using a combination of doxorubicin and pembrolizumab, and 36.7% (11/30) of the patients responded to the treatment. However, PFS and OS were relatively short, at 5.7 and 17 months, respectively.

PD-1/PD-L1 inhibitors in combination with radiotherapy. Dovedi *et al* (53) demonstrated that a combination of radiotherapy and PD-1 inhibitors improved the tumor immune environment and enhances the therapeutic effect. Patel *et al* (54) reported that preoperative radiation increases the tumor-associated macrophage expression of PD-L1 in STSs. Katsuki *et al* (55) reported that radiotherapy is necessary both pre- and post-operatively when anti-PD-L1 therapy is used.

Combining PD-1/PD-L1 inhibitors with other immunotherapies. The combination of PD-1/PD-L1 inhibitors with CTLA-4 inhibitors (for example, ipilimumab) improves the therapeutic effect on refractory cancers such as advanced melanoma (56). A recent systematic review and meta-analysis evaluated the efficacy and safety of a combination of PD-1/PD-L1 inhibitors and CTLA-4 inhibitors as a novel therapy for solid tumors (57). This combination showed no significant effect on the overall response rate, major pathological response, pathological complete response, surgical resection, radical resection, OS, PFS, recurrence-free survival, grade 3-4 adverse events, all-cause mortality, and treatment completion. New ICIs which suppress both PD-1 and CTLA-4 signals have been developed (58).

Combination of PD-1/PD-L1 Inhibitors and targeted therapy. The combination of a PD-L1 inhibitor (atezolizumab) and an angiogenesis inhibitor (bevacizumab) improves survival in patients with unresectable hepatocellular carcinoma (59).

Rousset *et al* (60) assessed the safety of a combination of a PD-1/PD-L1 inhibitor and anti-angiogenesis therapy in the first-line treatment of unresectable hepatocellular carcinoma by monitoring patients' conditions during and after treatment and documenting the frequency and severity of adverse reactions; they found the regimen to be generally safe and efficacious. They used the Common Terminology Criteria for Adverse Events to assess the adverse reactions. iRAEs such as skin rash, diarrhea, liver dysfunction and endocrine disorders, and radiation-related adverse reactions such as dermatitis at the irradiated site, fatigue, and effects on organs at the irradiated site (for example, pneumonia due to irradiation of the lungs) were reported as the most common adverse reactions. Mild to moderate side effects were observed in numerous patients, but these were within the normal range and did not require intervention. Serious side effects were reported in some patients but were infrequent and manageable with prompt therapeutic intervention (60). A phase III randomized study demonstrated the efficacy of atezolizumab and bevacizumab plus chemotherapy in patients with non-small cell lung cancer (61). A phase I study reported the efficacy of a combination of atezolizumab and bevacizumab in patients with advanced malignancies (62). These combination therapies are promising strategies to maximize the efficacy of PD-1/PD-L1 inhibitors in cancer treatment.

10. Future directions

Future research should focus on several key areas. Reliable response biomarkers, such as tumor mutation burden and microsatellite instability, should be identified to predict which patients will benefit most from PD-1/PD-L1 inhibitors. Combinations of PD-1/PD-L1 inhibitors with other therapies can be explored to overcome resistance and enhance efficacy (22). To improve therapeutic strategies, the contributions of the tumor microenvironment and genetic alterations to resistance and the underlying mechanisms should be elucidated (33). Finally, additional immune checkpoints and pathways that may synergize with PD-1/PD-L1 blockade should be identified (20,21).

11. Conclusions

The PD-1/PD-L1 immune checkpoint plays a critical role in the immune evasion of bone and soft tissue tumors. While significant progress has been made in elucidating and targeting this pathway, challenges remain in identifying target patient populations and in overcoming resistance mechanisms. Ongoing research and clinical trials continue to explore the potential of PD-1/PD-L1 inhibitors, alone and in combination with other therapies, to improve outcomes for patients with these challenging malignancies.

Acknowledgements

Not applicable.

Funding

No funding was received.

Availability of data and materials

The data generated in the present study may be requested from the corresponding author.

Authors' contributions

KH, SN and KG conceptualized the study, contributed to the study methodology, wrote the original draft, and reviewed and edited the manuscript. All authors read and approved the final version of the manuscript. Data authentication is not applicable.

Ethics approval and consent to participate

Not applicable.

Patient consent for publication

Not applicable.

Competing interests

The authors declare that they have no competing interests.

References

- Lin X, Kang K, Chen P, Zheng Z, Li G, Xiong W, Yi M and Xiang B: Regulatory mechanisms of PD-1/PD-L1 in cancers. *Mol Cancer* 23: 108, 2024.
- Pipitone RM, Lupo G, Zito R, Javed A, Petta S, Pennisi G and Grimaudo S: The PD-1/PD-L1 axis in the biology of MASLD. *Int J Mol Sci* 25: 3671, 2024.
- Liu J, Chen Z, Li Y, Zhao W, Wu J and Zhang Z: PD-1/PD-L1 checkpoint inhibitors in tumor immunotherapy. *Front Pharmacol* 12: 731798, 2021.
- Yi M, Li T, Niu M, Mei Q, Zhao B, Chu Q, Dai Z and Wu K: Exploiting innate immunity for cancer immunotherapy. *Mol Cancer* 22: 187, 2023.
- Tang Q, Chen Y, Li X, Long S, Shi Y, Yu Y, Wu W, Han L and Wang S: The role of PD-1/PD-L1 and application of immune-checkpoint inhibitors in human cancers. *Front Immunol* 13: 964442, 2022.
- Gao W, Liu S, Wu Y, Wei W, Yang Q, Li W, Chen H, Luo A, Wang Y and Liu Z: Enhancer demethylation-regulated gene score identified molecular subtypes, inspiring immunotherapy or CDK4/6 inhibitor therapy in oesophageal squamous cell carcinoma. *EBioMedicine* 105: 105177, 2024.
- Wood GE, Meyer C, Petitprez F and D'Angelo SP: Immunotherapy in sarcoma: Current data and promising strategies. *Am Soc Clin Oncol Educ Book* 44: e432234, 2024.
- Martin-Broto J, Hindi N and Moura DS: Combination treatment with PD1/PDL-1 inhibitors for sarcomas: State of the art, next questions. *Curr Opin Oncol* 36: 269-275, 2024
- Anastasiou M, Kyriazoglou A, Kotsantis I, Economopoulou P, Kyrkasiadou M, Giannopoulou A, Kosmidou A, Smerdi D, Moutafi M, Gavrielatou N and Psyrris A: Immune checkpoint inhibitors in sarcomas: A systematic review. *Immuno-oncol Technol* 20: 100407, 2023
- Dong H, Strome SE, Salomao DR, Tamura H, Hirano F, Flies DB, Roche PC, Lu J, Zhu G, Tamada K, *et al*: Tumor-associated B7-H1 promotes T-cell apoptosis: A potential mechanism of immune evasion. *Nat Med* 8: 793-800, 2002.
- Hashimoto K, Nishimura S and Akagi M: Characterization of PD-1/PD-L1 immune checkpoint expression in osteosarcoma. *Diagnostics (Basel)* 10: 528, 2020.
- Paydas S, Bagir EK, Deveci MA and Gonluses G: Clinical and prognostic significance of PD-1 and PD-L1 expression in sarcomas. *Med Oncol* 33: 93, 2016.
- Torabi A, Amaya CN, Wians FH Jr and Bryan BA: PD-1 and PD-L1 expression in bone and soft tissue sarcomas. *Pathology* 49: 506-513, 2017.

14. Orth MF, Buecklein VL, Kampmann E, Subklewe M, Noessner E, Cidre-Aranaz F, Romero-Pérez L, Wehweck FS, Lindner L, Issels R, *et al*: A comparative view on the expression patterns of PD-L1 and PD-1 in soft tissue sarcomas. *Cancer Immunol Immunother* 69: 1353-1362, 2020.
15. Miyake M, Oda Y, Nishimura N, Morizawa Y, Ohnishi S, Hatakeyama K, Fujii T, Hori S, Gotoh D, Nakai Y, *et al*: Integrative assessment of clinicopathological parameters and the expression of PD L1, PD L2 and PD 1 in tumor cells of retroperitoneal sarcoma. *Oncol Lett* 20: 190, 2020.
16. Boxberg M, Steiger K, Lenze U, Rechl H, von Eisenhart-Rothe R, Wörtler K, Weichert W, Langer R and Specht K: PD-L1 and PD-1 and characterization of tumor-infiltrating lymphocytes in high grade sarcomas of soft tissue—prognostic implications and rationale for immunotherapy. *Oncoimmunology* 7: e1389366, 2018.
17. Hashimoto K, Nishimura S, Ito T and Akagi M: Characterization of PD-1/PD-L1 immune checkpoint expression in soft tissue sarcomas. *Eur J Histochem* 65: 3203, 2021.
18. Kim C, Kim EK, Jung H, Chon HJ, Han JW, Shin KH, Hu H, Kim KS, Choi YD, Kim S, *et al*: Prognostic implications of PD-L1 expression in patients with soft tissue sarcoma. *BMC Cancer* 18: 1-9, 2018.
19. Guo J, Li YM, Guo H, Hao DP, Xu JX, Huang CC, Han HW, Hou F, Yang SF, Cui JL and Wang HX: Parallel CNN-deep learning clinical-imaging signature for assessing pathological grade and prognosis of soft tissue sarcoma patients. *J Magn Reson Imaging* 61: 807-819, 2024.
20. Hashimoto K, Nishimura S, Shinyashiki Y, Ito T, Tanaka H, Ohtani K, Kakinoki R and Akagi M: PD-1, PD-L1, NY-ESO-1, and MAGE-A4 expression in cutaneous angiosarcoma: A case report. *Medicine (Baltimore)* 101: e29621, 2022.
21. Hashimoto K, Nishimura S, Ito T, Kakinoki R and Akagi M: Immunohistochemical expression and clinicopathological assessment of PD-1, PD-L1, NY-ESO-1, and MAGE-A4 expression in highly aggressive soft tissue sarcomas. *Eur J Histochem* 66: 3393, 2022.
22. D'Angelo SP, Mahoney MR, Van Tine BA, Atkins J, Milhem MM, Jahagirdar BN, Antonescu CR, Horvath E, Tap WD, Schwartz GK and Streicher H: Nivolumab with or without ipilimumab treatment for metastatic sarcoma (Alliance A091401): Two open-label, non-comparative, randomized, phase 2 trials. *Lancet Oncol* 19: 416-426, 2018.
23. Yildirim AN, Akyurek M, Okay E, Zenginkinet T, Iyeten Y and Ozkan K: Programmed cell death ligand-1 (PD-L1) expression in desmoid tumors: A retrospective study. *Eur Rev Med Pharmacol Sci* 27: 5223-5229, 2023.
24. Hashimoto K, Nishimura S, Shinyashiki Y, Ito T, Kakinoki R and Akagi M: Clinicopathological assessment of PD-1-comp/PD-L1 immune checkpoint expression in desmoid tumors. *Eur J Histochem* 67: 3688, 2023.
25. Young RJ, Brown NJ, Reed MW, Hughes D and Woll PJ: Angiosarcoma. *Lancet Oncol* 11: 983-991, 2010.
26. Ai L, Xu A and Xu J: Roles of PD-1/PD-L1 pathway: Signaling, cancer, and beyond. *Adv Exp Med Biol* 1248: 33-59, 2020.
27. Lee JB, Ahn BC, Kim SH, Lee YH, Han JW, Jeon MK, Kim SH and Kim HS: Prognostic implications of PD-L1 expression in patients with angiosarcoma. *Future Sci OA* 7: FSO691, 2021.
28. Shimizu A, Kaira K, Okubo Y, Utsumi D, Yasuda M, Asao T, Nishiyama M, Takahashi K and Ishikawa O: Positive PD-L1 expression predicts worse outcome in cutaneous angiosarcoma. *J Glob Oncol* 3: 360-369, 2016.
29. Wen W, Zhang Y, Zhang H and Chen Y: Clinical outcomes of PD-1/PD-L1 inhibitors in patients with advanced hepatocellular carcinoma: A systematic review and meta-analysis. *J Cancer Res Clin Oncol* 149: 969-978, 2023.
30. Tawbi HA, Burgess M, Bolejack V, Van Tine BA, Schuetz SM, Hu J, D'Angelo S, Attia S, Riedel RF, Priebat DA, *et al*: Pembrolizumab in advanced soft-tissue sarcoma and bone sarcoma (SARC028): A multicentre, two-cohort, single-arm, open-label, phase 2 trial. *Lancet Oncol* 18: 1493-1501, 2017.
31. Nowicki TS, Akiyama R, Huang RR, Shintaku IP, Wang X, Tumeq PC, Singh A, Chmielowski B, Denny C, Federman N and Ribas A: Infiltration of CD8 T cells and expression of PD-1 and PD-L1 in synovial sarcoma. *Cancer Immunol Res* 5: 118-126, 2017.
32. Huang Q, Wu X, Wang Z, Chen X, Wang L, Lu Y, Xiong D, Liu Q, Tian Y, Lin H, *et al*: The primordial differentiation of tumor-specific memory CD8+ T cells as bona fide responders to PD-1/PD-L1 blockade in draining lymph nodes. *Cell* 185: 4049-4066.e25, 2022.
33. Martin AM, Nirschl TR, Nirschl CJ, Francica BJ, Kochel CM, van Bokhoven A, Meeker AK, Lucia MS, Anders RA, Demarzo AM and Drake CG: Paucity of PD-L1 expression in prostate cancer: Innate and adaptive immune resistance. *Prostate Cancer Prostatic Dis* 18: 325-332, 2015.
34. Chen L and Han X: Anti-PD-1/PD-L1 therapy of human cancer: Past, present, and future. *J Clin Invest* 125: 3384-3391, 2015.
35. Topalian SL, Hodi FS, Brahmer JR, Gettinger SN, Smith DC, McDermott DF, Powderly JD, Carvajal RD, Sosman JA, Atkins MB, *et al*: Safety, activity, and immune correlates of anti-PD-1 antibody in cancer. *N Engl J Med* 366: 2443-2454, 2012.
36. Brahmer JR, Tykodi SS, Chow LQ, Hwu WJ, Topalian SL, Hwu P, Drake CG, Camacho LH, Kauh J, Odunsi K, *et al*: Safety and activity of anti-PD-L1 antibody in patients with advanced cancer. *N Engl J Med* 366: 2455-2465, 2012.
37. Italiano A, Bellera C and D'Angelo S: PD1/PD-L1 targeting in advanced soft-tissue sarcomas: A pooled analysis of phase II trials. *J Hematol Oncol* 13: 55, 2020.
38. Somaiah N, Conley AP, Parra ER, Lin H, Amini B, Soto LS, Salazar R, Barreto C, Chen H, Gite S, *et al*: Durvalumab plus tremelimumab in advanced or metastatic soft tissue and bone sarcomas: A single-centre phase 2 trial. *Lancet Oncol* 23: 1156-1166, 2022.
39. Gordon EM, Chawla SP, Tellez WA, Younesi E, Thomas S, Chua-Alcala VS, Chomoyan H, Valencia C, Brigham DA, Moradkhani A, *et al*: SAINTE: A phase I/Expanded phase II study using safe amounts of ipilimumab, nivolumab and trabectedin as first-line treatment of advanced soft tissue sarcoma. *Cancers (Basel)* 15: 906, 2023.
40. Saif A, Verbus EA, Sarvestani AL, Teke ME, Lambdin J, Hernandez JM and Kirsch DG: A randomized trial of pembrolizumab & radiotherapy versus radiotherapy in high-risk soft tissue sarcoma of the extremity (SU2C-SARC032). *Ann Surg Oncol* 30: 683-685, 2023.
41. Liao Z, Teng J, Li T, Liu H, Li T, Zhang C, Xing R, Teng S, Yang Y, Zhao J, *et al*: Evaluation of the efficacy and safety of immunotherapy in sarcoma: A two-center study. *Front Immunol* 15: 1292325, 2024.
42. Babatunde O, Rosenbaum E, Kelly CM, Desir-Camille R, Keohan ML, Banks L, Avutu V, Chan J, Reed D, Gounder M, *et al*: 1752P A retrospective single-center study of outcomes to immune checkpoint blockade-based therapy in leiomyosarcoma. *Ann Oncol* 35: S1045, 2024.
43. Sonpavde GP, Grivas P, Lin Y, Hennessy D and Hunt JD: Immune-related adverse events with PD-1 versus PD-L1 inhibitors: A meta-analysis of 8730 patients from clinical trials. *Future Oncol* 17: 2545-2558, 2021.
44. Baxi S, Yang A, Gennarelli RL, Khan N, Wang Z, Boyce L and Korenstein D: Immune-related adverse events for anti-PD-1 and anti-PD-L1 drugs: Systematic review and meta-analysis. *BMJ* 360: k793, 2018.
45. Liu X, Shi Y, Zhang D, Zhou Q, Liu J, Chen M, Xu Y, Zhao J, Zhong W and Wang M: Risk factors for immune-related adverse events: What have we learned and what lies ahead? *Biomark Res* 9: 79, 2021.
46. Kalinich M, Murphy W, Wongvibulsin S, Pahalyants V, Yu KH, Lu C, Wang F, Zubiri L, Naranbhai V, Gusev A, *et al*: Prediction of severe immune-related adverse events requiring hospital admission in patients on immune checkpoint inhibitors: Study of a population level insurance claims database from the USA. *J Immunother Cancer* 9: e001935, 2021.
47. Schneider BJ, Naidoo J, Santomasso BD, Lacchetti C, Adkins S, Anadkat M, Atkins MB, Brassil KJ, Caterino JM, Chau J, *et al*: Management of immune-related adverse events in patients treated with immune checkpoint inhibitor therapy: ASCO guideline update. *J Clin Oncol* 39: 4073-4126, 2021.
48. Postow MA, Sidlow R and Hellmann MD: Immune-related adverse events associated with immune checkpoint blockade. *N Engl J Med* 378: 158-168, 2018.
49. Wang DY, Salem JE, Cohen JV, Chandra S, Menzer C, Ye F, Zhao S, Das S, Beckermann KE, Ha L, *et al*: Fatal toxic effects associated with immune checkpoint inhibitors: A systematic review and meta-analysis. *JAMA Oncol* 4: 1721-1728, 2018.
50. Yi M, Zheng X, Niu M, Zhu S, Ge H and Wu K: Combination strategies with PD-1/PD-L1 blockade: Current advances and future directions. *Mol Cancer* 21: 28, 2022.
51. Gandhi L, Rodríguez-Abreu D, Gadgeel S, Esteban E, Felip E, De Angelis F, Domine M, Clingan P, Hochmair MJ, Powell SF, *et al*: Pembrolizumab plus chemotherapy in metastatic non-small-cell lung cancer. *N Engl J Med* 378: 2078-2092, 2018.

52. Lynch MM, Alexiev BA, Schroeder BA and Pollack SM: Combinations of chemotherapy and PD-1/PD-L1 inhibitors in sarcoma. *Curr Treat Options Oncol* 23: 1861-1876, 2022.
53. Dovedi SJ, Adlard AL, Lipowska-Bhalla G, McKenna C, Jones S, Cheadle EJ, Stratford IJ, Poon E, Morrow M, Steward R, *et al*: Acquired resistance to fractionated radiotherapy can be overcome by concurrent PD-L1 blockade. *Cancer Res* 74: 5458-5468, 2014.
54. Patel KR, Martinez A, Stahl JM, Logan SJ, Perricone AJ, Ferris MJ, Buchwald ZS, Chowdhary M, Delman KA, Monson DK, *et al*: Increase in PD-L1 expression after pre-operative radiotherapy for soft tissue sarcoma. *Oncoimmunology* 7: e1442168, 2018.
55. Katsuki S, Takahashi Y, Tamari K, Minami K, Takenaka W, Ibuki Y, Yamamoto J, Tatekawa S, Hayashi K, Seo Y, *et al*: Radiation therapy enhances systemic antitumor efficacy in PD-L1 therapy regardless of sequence of radiation in murine osteosarcoma. *PLoS One* 17: e0271205, 2022.
56. Wolchok JD, Kluger H, Callahan MK, Postow MA, Rizvi NJ, Lesokhin AM, Segal NH, Ariyan CE, Gordon RA, Reed K, *et al*: Nivolumab plus ipilimumab in advanced melanoma. *N Engl J Med* 369: 122-133, 2013.
57. Huang S, Zheng G and Yang K: Neoadjuvant PD-1/PD-L1 combined with CTLA-4 inhibitors for solid malignancies: A systematic review and meta-analysis. *World J Surg Oncol* 21: 349, 2023.
58. Willmore ZN, Coumbe BGT, Crescioli S, Reci S, Gupta A, Harris RJ, Chenoweth A, Chauhan J, Bax HJ, McCraw A, *et al*: Combined anti-PD-1 and anti-CTLA-4 checkpoint blockade: treatment of melanoma and immune mechanisms of action. *Eur J Immunol* 51: 544-556, 2021.
59. Finn RS, Qin S, Ikeda M, Galle PR, Ducreux M, Kim TY, Kudo M, Breder V, Merle P, Kaseb AO, *et al*: Atezolizumab plus bevacizumab in unresectable hepatocellular carcinoma. *N Engl J Med* 382: 1894-1905, 2020.
60. Roussot N, Fumet JD, Limagne E, Thibaudin M, Hervieu A, Hennequin A, Zanetta S, Dalens L, Fourrier T, Galland L, *et al*: A phase I study of the combination of atezolizumab, tiragolumab, and stereotactic body radiation therapy in patients with metastatic multiorgan cancer. *BMC Cancer* 23: 1080, 2023.
61. Huang D, Ke L, Cui H and Li S: Efficacy and safety of PD-1/PD-L1 inhibitors combined with anti-angiogenic therapy for the unresectable hepatocellular carcinoma and the benefit for hepatitis B virus etiology subgroup: A systematic review and meta-analysis of randomized controlled trials. *BMC Cancer* 23: 474, 2023.
62. Park S, Kim TM, Han JY, Lee GW, Shim BY, Lee YG, Kim SW, Kim IH, Lee S, Kim YJ, *et al*: Phase III, randomized study of atezolizumab plus bevacizumab and chemotherapy in patients with EGFR- or ALK-mutated non-small-cell lung cancer. *J Clin Oncol* 42: 1241-1251, 2024.



Copyright © 2025 Hashimoto et al. This work is licensed under a Creative Commons Attribution-NonCommercial-NoDerivatives 4.0 International (CC BY-NC-ND 4.0) License.