

Ciliated nasal epithelial cells damage and human rhinovirus infection: cytological findings

Rafael Martínez-Girón¹, Hugo Cornelis van Woerden², Cristina Martínez-Torre³

¹INCLÍNICA Foundation for Clinical, Pneumological and Carcinogenic Research, Oviedo, Spain; ²University of the Highlands and Islands, Centre for Health Science, Inverness, United Kingdom; ³Faculty of Pharmacy, University of Modena-Reggio Emilia, Modena, Italy

To the Editor:

We read with great interest the article by Gelardi et al. regarding ciliocytophthoria (CCT) of nasal cells in 20 patients infected with type A influenza virus, demonstrating three distinct characteristic phases of CCT (1). In another article by the same authors, 12 patients with serologically confirmed type A influenza infection of the upper airways had morphological alterations to the nuclei of their nasal cells in nasal scrapings, when stained with the May-Grünwald Giemsa preparation (2). The nuclear changes consisted primarily of coalescence of chromatin, forming a compact mass surrounded by a peripheral halo.

Viruses such as adenovirus, influenza virus and respiratory syncytial virus, are known to cause cellular damage and morphological alterations: the cytopathic effect (3).

Although in vitro and in vivo studies have shown that human rhinoviruses disrupts tight junctions complexes, with consequent loss of epithelial barrier integrity and extrusion of ciliated nasal epithelial cells (4), human rhinovirus infection has so far not been shown to demonstrate similar cellular damage (5).

Rhinovirus, coronavirus, adenovirus, respiratory syncytial virus, parainfluenza virus type 1, 2 and 3, and influenza virus type A and B can all infect ciliated nasal epithelial cells and cause the common cold, but human rhinovirus infection has been identified as the commonest cause (52.5% of cases) and is therefore particularly important from a population perspective (6). We were therefore interested in cytological assess-

ment of nasal cells from patients with human rhinovirus infection.

Cytological examination was undertaken of nasal smears from a group of 7 patients, 4 females and 3 males; aged between 27 and 14 years-old (average = 17.5), who had longstanding perennial rhinitis (in all cases 7 years or more). They had all been treated with oral H1 antihistamines and nasal corticosteroid sprays during the preceding two years. Two patients, (27 and 21 years-old male respectively) also had nasal polyposis, and one (18 years-old female) had bronchial asthma. None of the patients were smokers. They presented at our research unit showing clinical symptoms of a common cold, including sore throat, nasal congestion, sneezing, and watery rhinorrhea. Serology and DNA real-time PCR demonstrated human rhinoviruses type A (5 cases) and C (two cases) as the cause of the infection. Nasopharyngeal swabs were taken, fixed with 96% ethanol and stained using the Papanicolaou method and Giemsa stain. The research was undertaken with full consent, and in line with obligations of research practice as outlined in the Declaration of Helsinki.

Under light microscopy the Pap smears showed the presence of numerous detached ciliated nasal epithelial cells, with approximately one third of the cells showed destruction and irregular attachment of cilia, microvacuolated cytoplasm, and large red round intranuclear bodies, similar to inclusions, surrounded by clear halos, where the nuclear borders were visible (Figure 1A). Eosinophils were very scarce (MGG

stain). Ultrastructural examination of the cells indicated disappearance of cilia, or shortened, fragmented and disordered cilia. Large intranuclear bodies appeared as a compact mass similar, similar to the condensed chromatin, and separated from the nuclear membrane by a clear space (Figure 1B). No viral particles were observed in the cytoplasm or nucleus.

Our results confirm that human rhinovirus can alter the morphology of the ciliated nasal epithelial cells,

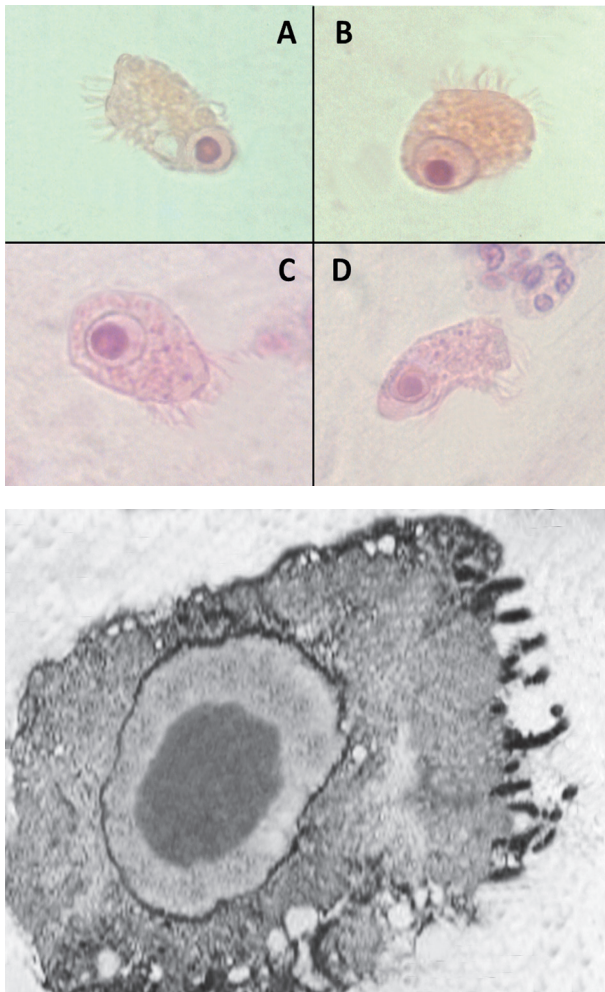


Figure 1. A: Cytopathic effect showing destruction and irregular attachment of cilia, microvacuolated cytoplasm, and large red round intranuclear bodies, surrounded by clear halos (Papanicolaou stain x 400). B: Ultrastructural findings of an infected ciliated nasal epithelial cell.

principally causing alterations to the cilia and provoking nuclear changes.

Although we had a small sample size ($n=7$), we think that the results are of interest. A larger sample, assessing any interplay with demographic factors such as gender, age, smoking, and presence or absence of other pathological conditions would be helpful in confirming and expanding on these findings.

Conflict of interest: Each author declares that he or she has no commercial associations (e.g. consultancies, stock ownership, equity interest, patent/licensing arrangement etc.) that might pose a conflict of interest in connection with the submitted article

References

1. Gelardi M, Ciprandi G. Ciliocytophthoria of nasal epithelial cells after viral infection: a sign of suffering cell. *Acta Biomed* 2019; 90 (2-S). doi: 10.23750/abm.v90i2-S.8103.
2. Gelardi M, Iannuzzi L, Seccia V, Quaranta N. Ciliocytophthoria: Cytomorphologic Modifications in Viral Infections of the Nasal Mucosa. *J Cytol Histol* 2016; S5:005. Doi: 10.4172/2157-7099.S5-005.
3. Mäkelä MJ, Puhakka T, Ruuskanen O et al. Viruses and bacteria in the etiology of the common cold. *J Clin Microbiol* 1998; 36: 539-542.
4. Winther B, Gwaltney JM, Hendley JO. Respiratory virus infection of monolayer cultures of human nasal epithelial cells. *Am Rev Respir Dis* 1990; 141: 839-845.
5. Kennedy JL, Turner RB, Braciale T, Heymann PW, Borish L. Pathogenesis of rhinovirus infection. *Curr Opin Virol* 2012; 2: 287-293.
6. Yeo NK, Jang YJ. Rhinovirus infection-induced alteration of tight junction and adherens junction components in human nasal epithelial cells. *Laryngoscope* 2010; 120: 346-352.

Received: 11 October 2019

Accepted: 20 January 2020

Correspondence:

Prof. Rafael Martínez-Girón, M.D.; Ph.D.

INCLÍNICA Foundation

Calvo Sotelo, 167. 33007-Oviedo (Spain)

Tel. +34 985532306

Fax +34 985507192

E-mail: rmartinezgiron@hotmail.com