



Revision Anterior Cruciate Ligament, Lateral Collateral Ligament Reconstruction, and Osteochondral Allograft Transplantation for Complex Knee Instability

Annalise M. Peebles, B.A., Phob Ganokroj, M.D., Reed L. Macey, M.Phil.,
Brendan M. Lilley, B.A., and
CAPT. Matthew T. Provencher, M.D., M.B.A., M.C., U.S.N.R. (Ret.)

Abstract: Anterior cruciate ligament (ACL) injuries rarely occur as an isolated event and often include associated meniscal, subchondral bone, and collateral ligament injuries. Concomitant pathology frequently complicates primary and revision ACL reconstruction and must be addressed to ensure comprehensive diagnosis and treatment. In this Technical Note, we describe our method for treatment of complex knee instability following multiple failed ACL reconstruction using a multiligament reconstruction technique with an osteochondral allograft transplantation to the lateral femoral condyle. This comprehensive repair technique restores the anatomic load bearing forces of the cruciate and collateral ligaments and promotes biological repair through incorporation of cartilage resurfacing to ultimately achieve optimal kinematics of the knee joint.

Failed anterior cruciate ligament reconstruction (ACLR) remains a challenging problem. Several factors, such as tunnel misplacement, inappropriate graft selection, and missed concomitant injuries, have been identified to contribute to failure after ACLR.^{1,2} Notwithstanding, localized anterior cruciate ligament (ACL) damage also can have serious biomechanical implications for neighboring knee ligaments that further contribute to ACLR failure.³ While the ACL is primarily responsible for inhibiting anterior tibial translation, it substantially supports the collateral ligaments during varus and valgus motion. Severe ACL

damage has been observed to more than triple maximum lateral collateral ligament (LCL) stress (2.93 MPa vs 9.04 MPa, at N = 300) and double medial collateral ligament stress (1.98 MPa vs 5.46 MPa, at N = 100) during anterior shear force loading of the knee.³ In the event of long-term chronic knee instability, alterations to load-carrying such as this can cause repetitive subluxations and subsequent damage to the associated articular cartilage and meniscus.⁴

Cruciate and collateral ligamentous injuries are not mutually exclusive and warrant thorough examination while formulating an optimal treatment plan for failed

From the Steadman Philippon Research Institute, Vail, Colorado, U.S.A. (A.M.P., P.G., M.T.P.); Faculty of Medicine Siriraj Hospital, Mahidol University, Bangkok, Thailand (P.G.); Dartmouth Geisel School of Medicine, Hanover, New Hampshire, U.S.A. (R.L.M.); Frank H. Netter School of Medicine, New Haven, Connecticut, U.S.A. (B.M.L.); and the Steadman Clinic, Vail, Colorado, U.S.A. (M.T.P.).

The authors report the following potential conflicts of interest or sources of funding: M.T.P. reports personal fees from Arthrex, Joint Surface Foundation, SLACK, Inc, and ArthroSurface, during the conduct of the study; is an editorial and governing board member of Arthroscopy, Knee, Orthopedics, and SLACK, Inc; and is a board or committee member for AANA, American Academy of Orthopaedic Surgeons, American Orthopaedic Society for Sports Medicine, American Shoulder and Elbow Surgeons, International Society of Arthroscopy, Knee Surgery and Orthopaedic Sports Medicine, the San Diego Shoulder Institute, and the Society of Military Orthopaedic Surgeons. Full

ICMJE author disclosure forms are available for this article online, as supplementary material.

Received May 6, 2022; accepted August 10, 2022.

Address correspondence to CAPT. Matthew T. Provencher, M.D., M.B.A., M.C., U.S.N.R. (Ret.), Steadman Philippon Research Institute, The Steadman Clinic, 181 W Meadow Dr., Ste 400, Vail, CO 81657. E-mail: mprovencher@thesteadmanclinic.com

© 2022 THE AUTHORS. Published by Elsevier Inc. on behalf of the Arthroscopy Association of North America. This is an open access article under the CC BY-NC-ND license (<http://creativecommons.org/licenses/by-nc-nd/4.0/>).

2212-6287/22618

<https://doi.org/10.1016/j.eats.2022.08.016>

ACLR. In fact, approximately 95% and 57% of all medial collateral ligament and LCL grade III injuries, respectively, occur with a concomitant ACL tear.^{5,6} Although current methods for ACLR have evolved, such techniques address ACL pathology in isolation while associated ligamentous and cartilaginous injuries remain either unrecognized or untreated. Recent advancements in imaging, grafting options, and chondral-resurfacing techniques have become valuable tools for improving comprehensive diagnosis and treatment of ACLR failure in the setting of complex knee instability.^{3,7}

The purpose of this Technical Note is to describe our method for treatment of complex knee instability following multiple failed ACLRs using a multiligament reconstruction technique with an osteochondral allograft (OCA) transplantation to the lateral femoral condyle (LFC). This comprehensive repair technique restores the anatomic load-bearing forces of the cruciate and collateral ligaments and promotes biological repair through incorporation of cartilage resurfacing to ultimately achieve optimal kinematics of the knee joint.

Surgical Technique (With Video Illustration)

The surgical technique can be reviewed in [Video 1](#).

Preoperative Planning

Preoperative planning includes anteroposterior, lateral knee radiographs, and magnetic resonance imaging of the knee to obtain the ACLR tunnels' condition, the position of the previous implants, overall knee alignment, and to determine associated pathology such as meniscal injury, associated ligaments (medial or lateral complex knee structures), and cartilage loss.

Patient Positioning

Following an induction of general anesthesia, an examination under anesthesia (EUA) is performed to

evaluate knee range of motion compared with the contralateral side. Degree of knee instability in each direction is also confirmed during EUA. The patient is then placed in a supine position. All bony prominences are well padded to prevent pressure ulcers. After completion of patient positioning and EUA, the knee is prepared and draped in a sterile fashion. A well-padded tourniquet is used and insufflated to 200 mm Hg during the case.

Diagnostic Arthroscopy and Arthroscopic Procedures

A diagnostic knee arthroscopy is performed using 2 inferior portals through the central incision. Synovitis tissue and the ACL footprint are debrided and prepared. The lateral and medial meniscus structures, including its roots, are probed and checked. In this example case, a lateral meniscal posterior root tear, a 15-mm diameter LFC cartilage defect, LCL deficiency, and ACL re-rupture are detected.

Lateral Meniscal Root Repair

The lateral meniscal root repair is first addressed. The attachment site of the lateral meniscal root is identified and debrided using a combination of curette, shaver and high-speed bone cutting bur. This allows for a good bleeding bone bed at the root attachment site. The root tear is cleaned and prepared with a rasp. Two high-strength meniscal sutures (FiberLinks sutures; Arthrex, Naples, FL) are passed with a meniscal suture passer (Scorpion suture passers; Arthrex) within the posterior root of lateral meniscus in a luggage-tag fashion ([Fig 1A](#)). The drill guide (Arthrex root repair set) is set at 60° and placed just medial to the expected ACL tibial tunnel and next to the anatomic posterior root of the lateral meniscus. The transtibial tunnel is placed using a canulated drill, which is passed from the

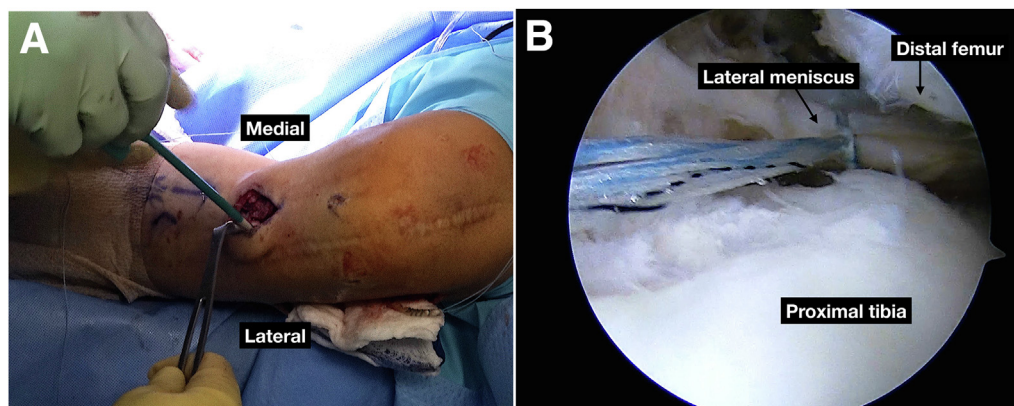


Fig 1. Arthroscopic and intraoperative images of the left knee (supine position), respectively. (A) Two high-strength meniscal sutures (FiberLinks sutures; Arthrex) are passed with a meniscal suture passer (Scorpion Suture Passers; Arthrex) within the posterior root of lateral meniscus in a luggage-tag fashion. (B) The meniscal root sutures are secured with one 4.75 knotless anchor (SwiveLock anchors; Arthrex) on the tibia under arthroscopic visualization.

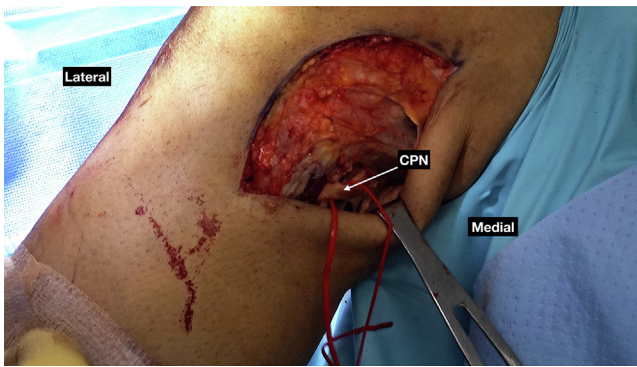


Fig 2. Intraoperative image of the left knee (supine position). The common peroneal nerve neurolysis is performed to minimize the risk of footdrop due to swelling after surgery.

anteromedial tibia to the anatomic root footprint. Next, a passing suture is placed through the cannulated drill to shuttle and secure the meniscal sutures at its footprint. The meniscal root sutures are then secured with one 4.75 knotless anchor (SwiveLock anchors) on the tibia under arthroscopic visualization (Fig 1B). Final suture passage through the tibial tunnel and suture fixation is performed after LCL reconstruction is completed.

Lateral Collateral Ligament Reconstruction

The knee is then positioned at 90° of flexion (an assistant can manually hold the foot) and an incision is made from the lateral epicondyle of the femur down to the trajectory that intersects between Gerdy's tubercle and the fibular head. Skin flaps are elevated anteriorly, posteriorly, superiorly and inferiorly from the fascia, along with the superior layer of the iliotibial band (ITB), using a combination of Metzenbaum scissors and sharp dissection. The common peroneal nerve (CPN) is carefully identified as it crosses the fibular neck. A CPN neurolysis is performed to minimize risk of footdrop after surgery due to swelling (Fig 2). The peroneus longus fascia is released over the CPN and dissected at approximately 6 cm proximal to the CPN, taking care to protect the CPN. A vessel loop is loosely placed around the CPN without any instrument.

Next, the native lateral collateral ligament (LCL) is identified in the interval anterior to the biceps femoris insertion and posterior to the ITB. It is tagged with a #2 nonabsorbable suture (FiberWire; Arthrex). The LCL femoral footprint can be identified by pulling and releasing the LCL traction stitch to determine whether the LCL has been strained (Fig 3). A 5-cm split incision is then made at the ITB next to where the anticipated LCL femoral footprint will be. The LCL femoral footprint is marked, and a Beath pin is passed. The Beath pin is oriented from a lateral to anteromedial trajectory out of the medial femoral skin to avoid the ACL femoral tunnel (Fig 4). A 6-mm reamer is used over the pin and drilled to a depth of 30 mm. A passing suture is then

shuttled through the femoral tunnel with the Beath pin and set aside. Next, the LCL fibular footprint is identified by palpation at an anatomic bony ridge (the anterolateral aspect of the fibular head) and guided by pulling the LCL traction stitch. The lateral head of gastrocnemius is elevated from the posterolateral aspect of the fibular head. A threaded 2.4-mm guide pin is drilled from the anterolateral to the posteromedial direction at the LCL fibular footprint marked site. A 6-mm reamer is used over the pin through the femoral head, and a wire suture passing device is used to shuttle a passing stitch through the fibular head. Care should be taken to avoid injury to the nearby neurovascular structures by using a finger at the posterior aspect of the fibular head.

The semitendinosus allograft is then prepared on the back table. The graft is passed into the femoral tunnel and secured with a 7-mm × 23-mm interference screw (FastThread PEEK Interference Screws; Arthrex). The channel for passing the LCL graft is created under the superficial layer of the ITB and the lateral aponeurosis of the biceps femoris. Next, the passing suture is used to shuttle the graft from anterior to posterior through the fibular head. The graft will not be secured on the fibula until after ACLR is completed. Next, the knee is positioned in neutral rotation, at 20° of flexion with a slightly valgus stress. The 7-mm × 23-mm interference screw (FastThread PEEK Interference Screws) is placed from anterior to posterior, securing the graft in the fibular tunnel.

Revision ACLR With Hamstring Autograft

The hamstring autograft harvest is first performed. A skin incision is made along the anteromedial tibia, and the sartorial fascia is carefully dissected and identified. The gracilis and semitendinosus tendon are gently isolated and harvested using a tendon stripper. We make sure to protect the saphenous nerve throughout the harvesting. Both the gracilis and semitendinosus autograft are prepared on the back table with nonabsorbable

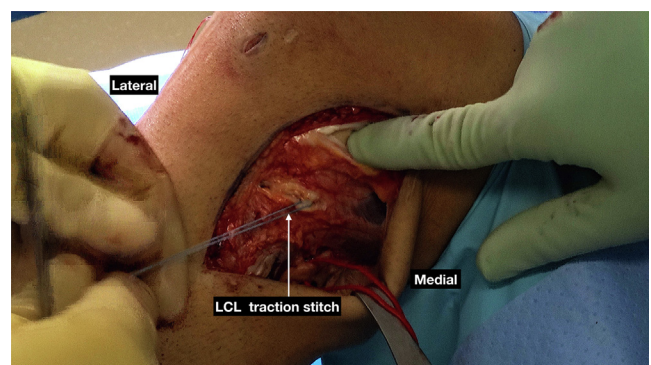


Fig 3. Intraoperative image of the left knee (supine position). Pulling and releasing the lateral collateral ligament (LCL) traction stitch will show that the LCL has been stretched and the LCL femoral footprint area can be identified.

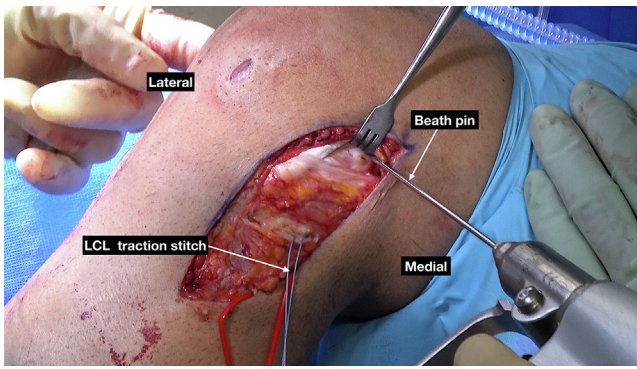


Fig 4. Intraoperative image of the left knee (supine position). The lateral collateral ligament (LCL) femoral footprint is marked and a Beath pin is passed, which is oriented from lateral to anteromedial trajectory, out the medial femoral skin to avoid the anterior cruciate ligament (ACL) femoral tunnel.

#2 high-strength Krakow suture (FiberWire; Arthrex) in each end.

Attention is then drawn to the lateral femoral notch. The arthroscope is reinserted, and the femoral footprint tunnel is prepared to expose the notch and the over-the-top position on the lateral femoral condyle. The anatomic femoral footprint is then marked with a Bovie, and a posterior notchplasty is performed with a combination of a basket, high-speed bone cutting shaver, curette, and the radiofrequency wand. The 9-mm Flip-Cutter device guide (Arthrex) that is the same size of the graft is placed at the previously marked anatomic femoral footprint. We then drill the femur with the FlipCutter in a retrograde fashion to create a femoral tunnel (Fig 5). Next, the tibial tunnel is drilled using the 9-mm acorn drill bit with an anatomic tibial guide. A stay suture is passed through both the femoral and the tibial tunnels. Following this, the ACL autograft is passed in a retrograde fashion and the femoral tunnel is fixed with a suspension ENDOBUTTON device (TightRope ABS; Arthrex). The ENDOBUTTON is flipped on the lateral femoral cortex, and its position is confirmed with visual inspection to ensure there is no soft tissue between the button and the femoral cortex. Next, the knee is cycled over the tibial side and the isometry is tested. The tibial tunnel is fixed with a 12 × 30-mm interference screw (BioComposite FastThread; Arthrex) while the knee is in full-extension and with full manual maximum tension on the graft. The tibia is also augmented with one 4.75 knotless anchor (SwiveLock anchors; Arthrex) for an enhanced fixation construct. After completing fixation, the Lachman test and varus-valgus tests, as well as full knee range of motion, are performed to confirm adequate knee stability.

Osteochondral Allograft Transplantation

A peripatellar incision is made to access the LFC defect using a peripatellar arthrotomy approach. The

full area of the LFC defect is then identified and is sized to be 16 mm. The appropriate cannulated guide (Cannulated Allograft OATS sizers; Arthrex) is selected (16 mm) and placed over the defect, staying perpendicular to the condyle surface (Fig 6A). A drill-tip guide pin is advanced through the guide and the bone defect. The appropriate recipient site reamer is then selected (16 mm) and advanced to its desired depth (approximately 6 mm total). Next, we identify and measure the depth of the created bone socket from 4 quadrants (12-, 3-, 6-, and 9-o'clock positions) (Fig 6B). The patellar defect is prepared with 0.045 Kirschner wire using 10 drill areas to fenestrate the area of bone defect for bleeding purposes and integration (Fig 7A). A premade 16-mm OCA plug (JRF Ortho, Centennial, CO) is used for the bone defect. Correct positioning is achieved to the edges of the graft once finalized on the clock face position. The 10-mm fine sagittal saw is used to prepare the allograft at the desired depth and is pulse lavaged with normal saline. The graft is then soaked in a combination of autologous conditioned plasma and platelet-rich-plasma using a Double Syringe System (Greyledge Technologies, Vail, CO) (Fig 7B). The graft is then gently bulletized by 0.5 mm around the edges with a rongeur to assist with insertion. Before fixation, the graft is manually pressed to the desired anatomic fit by matching it to the 12-o'clock position of the defect. Once the graft is positioned appropriately, it is gently tamped into position using a soft lap in between the tamper and advanced until it assumes perfect fit. The graft is then flush and fit with the surrounding cartilage (Fig 8). At this point, the knee was checked for adequate fixation through full range of motion. All wounds were copiously irrigated and closed in a layered fashion.

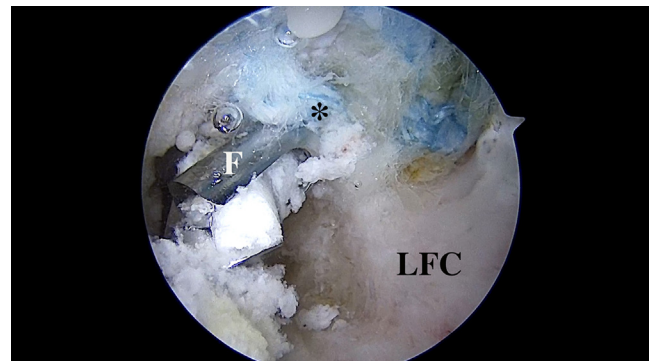


Fig 5. An arthroscopic image of the left knee (supine position). Creating the anterior cruciate ligament (ACL) femoral tunnel in a retrograde fashion provides a more anatomic footprint, especially in the case of an ACL revision. *ACL femoral footprint. (F, FlipCutter; LFC, lateral femoral condyle.)

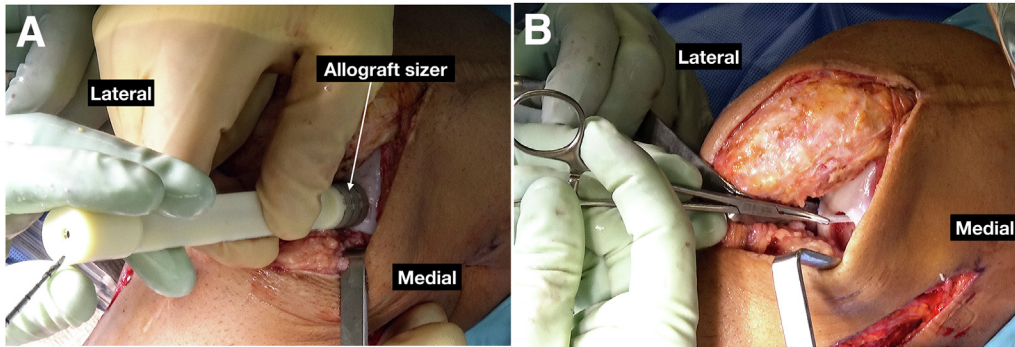


Fig 6. Intraoperative image of the left knee (supine position). (A) The appropriate (16 mm) cannulated guide (Cannulated Allograft OATS sizers; Arthrex) is selected and placed over the defect, staying perpendicular to the condyle surface; (B) The depth of the created bone socket is measured from 4 quadrants (12-, 3-, 6-, and 9-o'clock positions).

Postoperative Rehabilitation

The patient is initially placed in a hinged brace locked in extension at the initial post operation and then transitions to a functional brace. Full range of motion exercise is permitted as tolerated. The patient will be 10-pound touch down weight-bearing with crutches for 4 to 6 weeks. The pearls and pitfalls of the described technique are listed in [Table 1](#).

Discussion

This Technical Note describes our method for treatment of complex knee instability following multiple failed ACLRs using a multiligament reconstruction technique and an OCA transplantation to the LFC. This comprehensive repair technique restores the anatomic load-bearing forces of the cruciate and collateral ligaments and promotes biological repair through incorporation of cartilage resurfacing to ultimately achieve optimal kinematics of the knee joint.

The ACL is a robust ligament paramount to proper knee functioning, resisting both anterior tibial translation and internal rotation to give stability against

rotation and subluxation.⁸ Once integrity of this ligament is compromised, care must be taken during reconstruction to recreate the vectors along which the ACL is naturally tensioned to restore stability, regardless of technique. However, failure of these reconstructions is commonplace, with more than 13,000 revision ACL repairs performed annually in the United States.⁹ It is well documented that the more times the ACL is repaired, the more likely it is to fail and the less likely the patient is to return to the same level of sport.^{10,11} Such results are illustrated by Wegrzyn et al.¹² in their retrospective case series that observed only 20% (N = 10) of patients who underwent revision surgery after multiple ACLR failures achieved the same sporting ability after their second revision, compared to 70% after index repair. Similar outcomes were observed by Griffith et al.,¹³ who reported only a 27% return-to-play rate following revision ACLR in 15 patients. While ACL tears can occur at any age and under various activity thresholds, these findings highlight particular risk factors, such as younger patients with high-functional demands and history of failed ACLRs

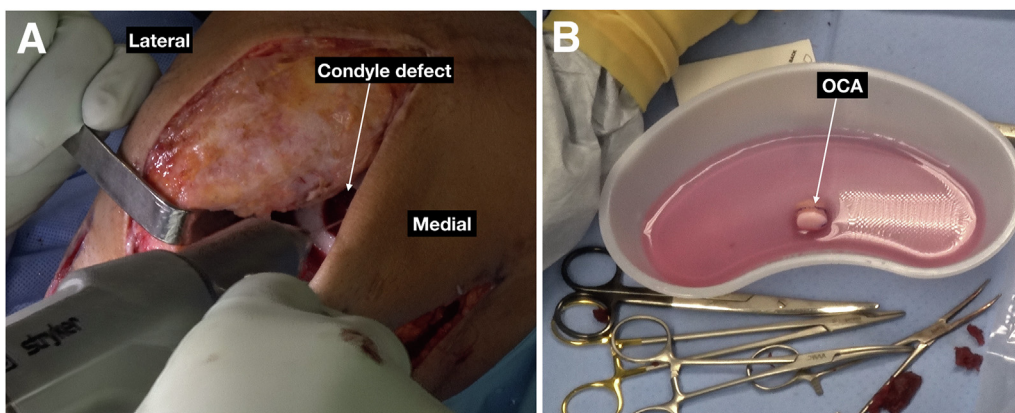


Fig 7. Intraoperative image of the left knee (supine position). (A) The 0.045 Kirschner wire is used throughout 10 drill areas to fenestrate the area of bone defect for bleeding purposes and integration; (B) The graft is then soaked in a combination of autologous conditioned plasma and platelet-rich-plasma using a Double Syringe System (Greyledge Technologies, Vail, CO).

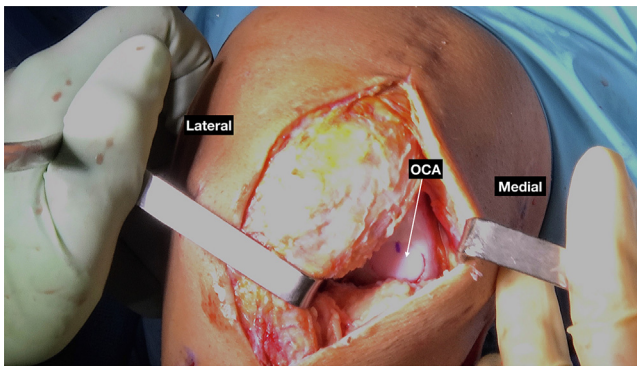


Fig 8. Intraoperative image of the left knee (supine position). Once the graft is positioned appropriately, it is gently tamped into position using a soft lap in between the tamper, and the graft is advanced until it is perfectly flush and fit within the surrounding cartilage. (OCA, osteochondral allograft.)

that may warrant a more comprehensive, robust treatment alternative to current revision ACLR techniques.

In the setting of perpetual ACL graft failure with concomitant collateral ligament deficiency, careful consideration of graft type and tunnel drilling are essential to ensure proper restoration of load bearing forces. Our choice of an autologous semitendinosus graft and gracilis tendon graft has several advantages. First, hamstring grafts possess up to 3 times more tensile strength than native ACLs and have been reported to allow approximately 70% of patients to return to their preoperative level of sport.¹⁴ In their systematic review, Conte et al.¹⁴ reported that hamstring grafts 8 mm or larger in diameter had decreased failure rates in all patients, including those younger than 20 years of age,

who have the greatest risk of failure. Additional benefits are gained from using an autograft versus an allograft, such as lower incidence of failure and lower risk of infection.¹⁵⁻¹⁷ Possibly more important than graft selection is graft tunnel placement. We elected to drill both tunnels independently to achieve anatomical position of the graft rather than through a transtibial approach. The latter technique often results in anterior positioning of the femoral tunnel which subsequently results in worse outcomes compared to more central tunnels achieved with independent drilling of the femur.^{10,18,19} Tunnels that are too anterior or medial create a vector through the graft which is predominantly vertical and poorly resists rotation. Existing tunnels should be carefully evaluated before reuse as vertical graft positioning is a leading cause of failure.²⁰⁻²²

Clinicians should be aware that most patients with multiple revision failures have reached this stage by engaging in high risk/demand sporting activity and are unlikely to regain their native level of function. Concomitant injuries frequently complicate revisions and must be addressed to give patients the best chance to return to preoperative level of activity.^{22,23} In their retrospective cohort study, Wright et al.²³ report that of 47 patients who underwent revision ACLR, 22 had medial meniscal tears, 24 had lateral tears, and 21 had lateral femoral condyle and tibial plateau lesions grades I through IV. Postrevision, patients still had a 15% chance of reoperation. Griffith et al.¹³ further illustrates the implications of concomitant chondral injuries in the setting of revision ACLR, reporting that presence of high-grade chondral lesions was associated with “poor” or “fair” outcomes as defined by Lysholm Knee Scoring

Table 1. Pearls and Pitfalls for Revision Complex Knee Instability

Pearls	Pitfalls
Preoperative radiograph and magnetic resonance imaging are essential to address all pathologies in revision complex knee instability cases	There is increased risk of peroneal nerve injury during the procedure
Exam under anesthesia is important to determine knee instability in each direction	Avoid injury to the posterior neurovascular structures and soft tissue of the knee
Identify and neurolysis of the peroneal nerve to prevent injury after the procedure	Crossover of the femoral tunnel between lateral collateral ligament (LCL) and anterior cruciate ligament (ACL) reconstruction
Identify and use LCL traction stitch to help identify both femoral and fibular LCL footprint	Potential of saw injury during osteochondral allograft (OCA) graft preparation
When creating the femoral tunnel in LCL reconstruction, the tunnel should be oriented from lateral to anteromedial trajectory out the medial femoral skin to avoid the ACL femoral tunnel	Mismatch or incorrect placement of the OCA
Creating ACL femoral tunnel in a retrograde fashion provides a more anatomic footprint, especially in the case of a revision procedure	Increased operative time and risk of knee stiffness
Reassess the graft alignment for the perfectly match to the 12-o'clock position of the defect and recipient area	
Use K-wire to fenestrate the area of bone defect and a biologic treatment such as autologous conditioned plasma and platelet-rich plasma is encouraged	

System. While degree of concomitant pathology in the reconstructed knee does not definitively correlate with graft failure, it does indirectly reflect the intensity of force the knee experiences and should therefore be included as a component in patients' treatment algorithm.

Treatment algorithm for multiple failed ACLRs is highly dependent on patients' auxiliary pathology, activity profile, and anticipation for return to play. Reconstruction of the ACL using a robust hamstring graft source with newly drilled femoral and tibial tunnels, in addition to treatment of concomitant collateral ligament and chondral pathology through LCL reconstruction and chondral resurfacing, offers a comprehensive repair technique that restores the anatomic load bearing forces and promotes biological repair of cartilaginous structures to achieve optimal kinematics of the knee joint.

References

- Southam BR, Colosimo AJ, Grawe B. Underappreciated factors to consider in revision anterior cruciate ligament reconstruction: A current concepts review. *Orthop J Sports Med* 2018;6:2325967117751689.
- Mitchell JJ, Cinque ME, Dornan GJ, et al. Primary versus revision anterior cruciate ligament reconstruction: Patient demographics, radiographic findings, and associated lesions. *Arthroscopy* 2018;34:695-703.
- Knapp A, Williams LN. Predicting the effect of localized ACL damage on neighbor ligament mechanics via finite element modeling. *Bioengineering (Basel)* 2022;9:54.
- Lee RJ, Margalit A, Nduaguba A, Gunderson MA, Ganley TJ. Risk factors for concomitant collateral ligament injuries in children and adolescents with anterior cruciate ligament tears. *Orthop J Sports Med* 2018;6:2325967118810389.
- Fetto JF, Marshall JL. Medial collateral ligament injuries of the knee: A rationale for treatment. *Clin Orthop Relat Res* 1978;132:206-218.
- Geeslin AG, LaPrade RF. Location of bone bruises and other osseous injuries associated with acute grade III isolated and combined posterolateral knee injuries. *Am J Sports Med* 2010;38:2502-2508.
- Mehl J, Diermeier T, Herbst E, et al. Evidence-based concepts for prevention of knee and ACL injuries. 2017 guidelines of the ligament committee of the German Knee Society (DKG). *Arch Orthop Trauma Surg* 2018;138:51-61.
- Noyes FR. The function of the human anterior cruciate ligament and analysis of single- and double-bundle graft reconstructions. *Sports Health* 2009;1:66-75.
- Grassi A, Ardern CL, Marcheggiani Muccioli GM, Neri MP, Marcacci M, Zaffagnini S. Does revision ACL reconstruction measure up to primary surgery? A meta-analysis comparing patient-reported and clinician-reported outcomes, and radiographic results. *Br J Sports Med* 2016;50:716-724.
- Kamath GV, Redfern JC, Greis PE, Burks RT. Revision anterior cruciate ligament reconstruction. *Am J Sports Med* 2011;39:199-217.
- Wright RW, Gill CS, Chen L, et al. Outcome of revision anterior cruciate ligament reconstruction: A systematic review. *J Bone Joint Surg Am* 2012;94:531-536.
- Wegrzyn J, Chouteau J, Philippot R, Fessy MH, Moyon B. Repeat revision of anterior cruciate ligament reconstruction: A retrospective review of management and outcome of 10 patients with an average 3-year follow-up. *Am J Sports Med* 2009;37:776-785.
- Griffith TB, Allen BJ, Levy BA, Stuart MJ, Dahm DL. Outcomes of repeat revision anterior cruciate ligament reconstruction. *Am J Sports Med* 2013;41:1296-1301.
- Conte EJ, Hyatt AE, Gatt CJ Jr, Dhawan A. Hamstring autograft size can be predicted and is a potential risk factor for anterior cruciate ligament reconstruction failure. *Arthroscopy* 2014;30:882-890.
- Kaeding CC, Aros B, Pedroza A, et al. Allograft versus autograft anterior cruciate ligament reconstruction: Predictors of failure from a MOON Prospective Longitudinal Cohort. *Sports Health* 2011;3:73-81.
- Effect of graft choice on the outcome of revision anterior cruciate ligament reconstruction in the Multicenter ACL Revision Study (MARS) Cohort. *Am J Sports Med* 2014;42:2301-2310.
- Ho B, Edmonds EW, Chambers HG, Bastrom TP, Pennock AT. Risk factors for early ACL reconstruction failure in pediatric and adolescent patients: A review of 561 cases. *J Pediatr Orthop* 2018;38:388-392.
- Kopf S, Forsythe B, Wong AK, Tashman S, Irrgang JJ, Fu FH. Transtibial ACL reconstruction technique fails to position drill tunnels anatomically in vivo 3D CT study. *Knee Surg Sports Traumatol Arthrosc* 2012;20:2200-2207.
- Markatos K, Kasetta MK, Lallios SN, Korres DS, Efstathopoulos N. The anatomy of the ACL and its importance in ACL reconstruction. *Eur J Orthop Surg Traumatol* 2013;23:747-752.
- Morgan JA, Dahm D, Levy B, Stuart MJ. Femoral tunnel malposition in ACL revision reconstruction. *J Knee Surg* 2012;25:361-368.
- Taggart TF, Kumar A, Bickerstaff DR. Revision anterior cruciate ligament reconstruction: A midterm patient assessment. *Knee* 2004;11:29-36.
- Chen JL, Allen CR, Stephens TE, et al. Differences in mechanisms of failure, intraoperative findings, and surgical characteristics between single- and multiple-revision ACL reconstructions: a MARS cohort study. *Am J Sports Med* 2013;41:1571-1578.
- Wright RW, Dunn WR, Amendola A, et al. Anterior cruciate ligament revision reconstruction: Two-year results from the MOON cohort. *J Knee Surg* 2007;20:308-311.