

Successful Surgical Treatment for Congenital Vaginal Agenesis Accompanied by Functional Uterus: A Report of Two Cases

Chihiro Minami¹, Ryosuke Tsunematsu^{1*}, Kana Hiasa², Katsuko Egashira², Kiyoko Kato³

¹Department of Obstetrics and Gynecology, National Hospital Organization Kyushu Medical Center, ²Department of Obstetrics and Gynecology, Kyushu University Hospital, ³Department of Obstetrics and Gynecology, Graduate School of Medical Sciences, Kyushu University, Fukuoka, Japan

Abstract

We present two cases of congenital vaginal agenesis with functional uterine corpus, manifesting with periodic lower abdominal pain and hematometra in adolescence. Both patients were successfully treated with the creation of neovagina and neocanal structures to discharge menstrual blood; this may also facilitate the preservation of fertility. Both cases were characterized by degrees of congenital vaginal agenesis, whether short or completely absent, with no communication between the uterine cavity and external genitalia, as confirmed by physical examination and imaging. We surgically reconstructed a neovagina with the modified McIndoe's procedure, using an artificial skin graft, and canalized to the caudal portion of the uterine cavity. Although redilatation of the neocanal was required, no patient suffered severe infection in postoperative course and both now exhibit regular menstruation. Although hysterectomy has classically been the preferred treatment for such cases, recent technical progression enables treatment of such diseases with conservative and minimally invasive surgery, in a safe manner.

Keywords: Cervical atresia, cervicovaginal agenesis, laparoscopic, McIndoe vaginoplasty, vaginal agenesis

INTRODUCTION

Congenital vaginal agenesis occurs in 1 in 4000–10,500 live female births, among which normal development of the uterine corpus is observed in <10% of patients.^[1] In such cases, surgical intervention should be performed in adolescence for drainage of menstrual blood, to relieve pelvic pain and to avoid retrograde menstruation, which may result in endometriosis and infertility in the future. Historically, hysterectomy has been the chosen procedure to relieve symptoms through obstruction of menstrual blood flow and to avoid severe postoperative complications such as pelvic inflammatory disease.^[2-4] However, recent progressions in surgical techniques and devices have made it possible to not only treat symptoms but also to provide an avenue to preserve

fertility.^[1,3,5] Here, we present two cases of congenital vaginal agenesis with functional uterine corpus, successfully treated without hysterectomy.

CASE REPORTS

Case 1

A 14-year-old virgin girl was referred to our hospital with primary amenorrhea and a 1-year history of cyclic lower abdominal pain. A 1-cm blind vagina was present on physical examination. The transrectal ultrasonography revealed a 4.7 cm × 3.5 cm-sized central fluid pooling in the uterus.

Address for correspondence: Dr. Ryosuke Tsunematsu, Department of Obstetrics and Gynecology, National Hospital Organization Kyushu Medical Center, 1-8-1, Jigyo-Hama, Chuo-Ku, Fukuoka 810-8563, Japan. E-mail: 20101205@gmail.com

Article History:

Received 21 July 2018

Received in revised form 17 November 2018

Accepted 6 December 2018

Available online 29 April 2019

Access this article online

Quick Response Code:



Website:
www.e-gmit.com

DOI:
10.4103/GMIT.GMIT_124_18

This is an open access journal, and articles are distributed under the terms of the Creative Commons Attribution-NonCommercial-ShareAlike 4.0 License, which allows others to remix, tweak, and build upon the work non-commercially, as long as appropriate credit is given and the new creations are licensed under the identical terms.

For reprints contact: reprints@medknow.com

How to cite this article: Minami C, Tsunematsu R, Hiasa K, Egashira K, Kato K. Successful surgical treatment for congenital vaginal agenesis accompanied by functional uterus: A report of two cases. *Gynecol Minim Invasive Ther* 2019;8:76-9.

A 1.5 cm-sized hypoechoic mass in the left ovary was also noted. The drip infusion pyelography (DIP) was normal. The pelvic magnetic resonance imaging (MRI) revealed clotted blood filling the uterine cavity and a 1.5 cm-sized chocolate cyst in the left ovary. However, the uterine cervix was absent [Figure 1a and b].

A diagnosis of congenital cervicovaginal agenesis was established, with the first operation performed to drain fluid pooled in the uterine cavity as a means of relieving the lower abdominal pain. After monthly intramuscular administration of 1.88-mg depot leuprolide acetate, the second vaginoplasty operation, involving canalization from the uterine body to the vagina, and cystectomy of the left ovary, were performed. In laparotomy, we observed a normal uterine corpus; however, the uterine cervix was not apparent. The neovagina was created with the modified McIndoe's procedure, using an artificial skin graft (Terudermis®). A reverse T incision was made in the inferior part of the uterine body, and canalization between the lower part of the uterus and the upper vault of the neovagina was performed using forceps. A balloon catheter was inserted to maintain patency [Figure 1c].

Postoperative course

The patient ran a fever 5 days after the operation. On the 7th postoperative day (POD), the balloon catheter and prosthesis were removed in an attempt to mitigate a fever that had not settled in spite of antibiotics administration. After the body temperature had normalized, a Nelaton catheter (22 Fr) was reintroduced to the neocanal. On the 20th POD, the Nelaton catheter spontaneously fell off and the canal was obstructed. Recanalization under ultrasound guidance

was performed, and a urethral catheter (14 Fr) was inserted. Following catheter removal, cervical dilatation with Hegars cervical dilator was performed to avoid reobstruction, on every visit to the outpatient clinic. At the time of writing, 6 years after surgery, menstruation is normal, without cervical dilation or recurrent hematometra.

Case 2

A 14-year-old virgin girl was referred to our hospital with a 2-year history of cyclic lower abdominal pain, loss of consciousness, and primary amenorrhea. During the physical examination, we observed an absent vagina. Transrectal ultrasound scan showed that the uterus was 7.4 cm in length with a small amount of central fluid at the uterine cervical portion. A hypoechoic mass of 8 cm in diameter was found in the left ovary. The right ovary was normal. DIP exhibited incomplete duplication of the right ureter. The pelvic MRI revealed clotted blood filling the uterine cervical portion and an 8 cm-sized chocolate cyst in the left ovary [Figure 2a and b]. On the other hand, the uterine corpus was not filled with the clotted blood. It seemed that it was pooling in the upper part of the vagina and that the overt uterine cervical structure was absent. She was diagnosed with high vaginal atresia with cervical hypoplasia.

Laparoscope-assisted surgery was performed. During the operation, we found a small, hen egg-sized uterine body and an enlarged uterine cervical portion/upper vagina. An

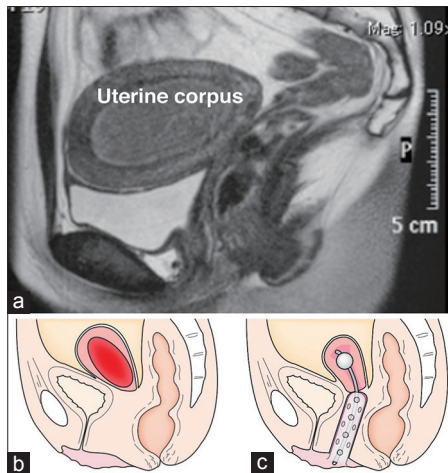


Figure 1: Magnetic resonance imaging image and operative procedure of Case 1. (a) Magnetic resonance imaging reveals a cystic mass consistent with clotted blood filling the uterine cavity, without uterine cervix. Arrowhead indicates the absence of the uterine cervix and vagina. (b) Schematic representation of Case 1. (c) A balloon catheter was inserted to keep the neocanal patent. Prosthesis with a skin graft was inserted into the neovagina

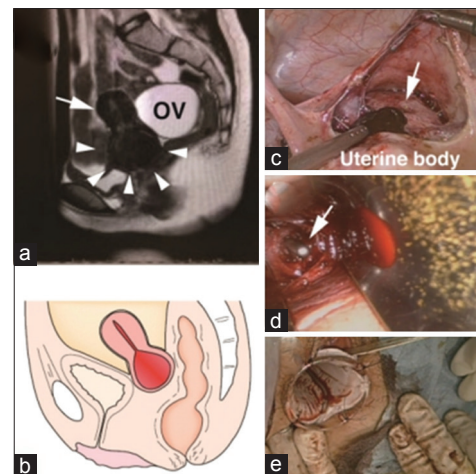


Figure 2: Magnetic resonance imaging image and operative procedure of Case 2. (a) Magnetic resonance imaging image reveals a cystic mass consistent with clotted blood filling the uterine cervical portion/upper vagina (arrowhead). The uterine corpus exhibits a normal appearance (arrow). An 80 mm-sized chocolate cyst in the left ovary was also noted (OV). (b) Schematic representation of Case 2. (c-e) Operative findings and steps. (c) A vertical incision was made in the enlarged uterine cervical portion/upper vagina (arrow). Chocolate-like fluid was evacuated. (d) Canalization between the uterus and the upper vault of the neovagina. Arrow indicates the tip of forceps penetrating from the uterine cavity. (e) A prosthesis and artificial skin graft were inserted into the neovagina

8cm-sized chocolate cyst and hematosalpinx were also observed in the left adnexa. The right ovary was normal. Left ovarian cystectomy and left salpingectomy were performed. The peritoneum of the vesicouterine pouch was opened and the uterine cervical portion/upper vagina was incised vertically. Chocolate-like fluid was extracted [Figure 2c]. A horizontal incision was made on the vaginal vestibule. A neovagina was constructed with the same procedure as used in Case 1 [Figure 2e]. The functional uterus and the upper vault of the neovagina were penetrated using forceps, inserted through the incision in the uterine cervical portion/upper vagina [Figure 2d]. The canal was then dilated to insert a 10-Fr Nelaton catheter to maintain patency.

Postoperative course

The neovagina was washed daily to prevent infection. On the 9th POD, the Nelaton catheter and prosthesis were removed. The patient was able to put on and take off a prosthesis by herself, every day. On the 60th POD, the neovagina was restenosed. We performed vaginal expansion with a cusco-type speculum, involving recanalization under transabdominal ultrasound guidance, and balloon catheter replacement. Current menstrual status is normal; however, a balloon catheter and prosthesis are still required.

DISCUSSION

The prevalence of Müllerian anomalies is ~4% in the general population.^[4] Among them, congenital vaginal agenesis with functional uterus is a rare disease entity. The Müllerian malformation manifests with various phenotypes due to the variance of developmental defects in the female genitourinary tract.^[6] Both cervicovaginal agenesis and vaginal agenesis/cervical atresia are thought to originate with developmental defects of the Müllerian tubercle.^[6] According to the Müllerian development anomaly classification of the American Fertility Society (AFS), both our cases are classified as Class 1A (Class 1 includes all cases of vaginal agenesis/hypoplasia)^[7] because the AFS classification fails to distinguish between cervicovaginal agenesis and vaginal agenesis/cervical atresia. Recently, newly designed classifications have been proposed. The European Society of Human Reproduction and Embryology and the European Society for Gynecological Endoscopy have presented a new classification based on the anatomy of the uterus, cervix, and vagina.^[8] According to this, both our cases are classified as a class U0/C4/V4.

The major postoperative complication in vaginal agenesis/cervical atresia is infection and stenosis of the neocanal,^[1] with both of our patients exhibiting some degree of infection. Many of these cases required catheters to maintain patency of the neocanal;^[1,3,4,9-11] however, long-term use of

a foreign body is associated with development of infectious disease. Some patients, following uterovaginal canalization, required hysterectomy for pelvic inflammatory disease in the literature and even death by sepsis has been reported.^[4] Therefore, one of the key points in postoperative management is the judgment of an adequate indwelling period for a neocanal catheter to maintain patency while simultaneously protecting patients from infection. In our cases, canalization between the uterus and the neovagina was made by blunt penetration using forceps. Acien *et al.* recommends anastomosing the uterine body into the created neovagina after resecting the cervical fibrous tract.^[1,5] Although their reported case needed reoperation for recanalization because of stenosis, the patency of the neocanal maintained, resulting in spontaneous gestation after the third operation.^[1] Deffarges *et al.* also reported that uterovaginal anastomosis appears to be an adequate treatment of uterine cervical atresia with good functional results, by analyzing their experienced cases.^[3]

We performed vaginoplasty through the modified McIndoe's procedure using an artificial skin graft. Our results suggest that this methodology limits postoperative scarring and vaginal stricture, while simultaneously being a relatively straightforward technique. The skin,^[1,11] bladder mucosa,^[12] or amniotic membrane^[13] were used as graft media in the literature. On the other hand, Ghafarnejad *et al.* observed effective results in vaginoplasty using no graft, with good postoperative results.^[10]

With the spread of laparoscopic techniques, reports describing laparoscope-assisted surgery in cases of vaginal agenesis/cervical atresia are increasing.^[9,11,14] Laparoscope-assisted surgery is less invasive and is considered especially suitable for young women, due to reduced likelihood for intraperitoneal adhesions following surgery, which may contribute to fertility potential in the future.

We present two cases of congenital agenesis of vagina with functional uterine corpus. We successfully treated these cases with vaginoplasty and the canalization between the neovagina and the uterine corpus, making it possible to discharge menstrual blood and hopefully facilitating preservation of fertility. While the patients did exhibit some complications in postoperative course, such as infection and restenosis, conservative surgery could be achieved with comparable safety.

Declaration of patient consent

The authors certify that they have obtained all appropriate patient consent forms. In the form, the patient (s) has/have given his/her/their consent for his/her/their images and other clinical information to be reported in the journal. The patients understand that their names and initials will not be published and due efforts will be made to conceal their identity, but anonymity cannot be guaranteed.

Financial support and sponsorship

Nil.

Conflicts of interest

There are no conflicts of interest.

REFERENCES

1. Acien P, Acien MI, Quereda F, Santoyo T. Cervicovaginal agenesis: Spontaneous gestation at term after previous reimplantation of the uterine corpus in a neovagina: Case report. *Hum Reprod* 2008;23:548-53.
2. Fujimoto VY, Miller JH, Klein NA, Soules MR. Congenital cervical atresia: Report of seven cases and review of the literature. *Am J Obstet Gynecol* 1997;177:1419-25.
3. Deffarges JV, Haddad B, Musset R, Paniel BJ. Utero-vaginal anastomosis in women with uterine cervix atresia: Long-term follow-up and reproductive performance. A study of 18 cases. *Hum Reprod* 2001;16:1722-5.
4. Grimbizis GF, Tsalikis T, Mikos T, Papadopoulos N, Tarlatzis BC, Bontis JN, *et al.* Successful end-to-end cervico-cervical anastomosis in a patient with congenital cervical fragmentation: Case report. *Hum Reprod* 2004;19:1204-10.
5. Acien P, Acien M. The presentation and management of complex female genital malformations. *Hum Reprod Update* 2016;22:48-69.
6. Acien P, Acien MI. The history of female genital tract malformation classifications and proposal of an updated system. *Hum Reprod Update* 2011;17:693-705.
7. Grimbizis GF, Campo R. Congenital malformations of the female genital tract: The need for a new classification system. *Fertil Steril* 2010;94:401-7.
8. Grimbizis GF, Gordts S, Di Spiezio Sardo A, Brucker S, De Angelis C, Gergolet M, *et al.* The ESHRE/ESGE consensus on the classification of female genital tract congenital anomalies. *Hum Reprod* 2013;28:2032-44.
9. El Saman AM. Endoscopically monitored canalization for treatment of congenital cervical atresia: The least invasive approach. *Fertil Steril* 2010;94:313-6.
10. Ghafarnejad M, Adabi K, Moosavi SA. Uteroneovaginal cannulation using pezzet catheter in patients with vaginal agenesis and functional uterus. *J Obstet Gynaecol Res* 2013;39:210-6.
11. Zhang X, Han T, Ding J, Hua K. Combined laparoscopic and vaginal cervicovaginal reconstruction using split thickness skin graft in patients with congenital atresia of cervix. *Int J Clin Exp Med* 2015;8:10081-5.
12. Bugmann P, Amaudruz M, Hanquinet S, La Scala G, Birraux J, Le Coultre C, *et al.* Uterocervicoplasty with a bladder mucosa layer for the treatment of complete cervical agenesis. *Fertil Steril* 2002;77:831-5.
13. Mhaskar R. Amniotic membrane for cervical reconstruction. *Int J Gynaecol Obstet* 2005;90:123-7.
14. Fedele L, Bianchi S, Frontino G, Berlanda N, Montefusco S, Borruto F, *et al.* Laparoscopically assisted uterovestibular anastomosis in patients with uterine cervix atresia and vaginal aplasia. *Fertil Steril* 2008;89:212-6.