



Original Article

Efficacy and Safety of Peroral Endoscopic Myotomy (POEM) in Achalasia: An Updated Meta-analysis

Afshin Khaizer¹, Muhammad Baig^{1*}, David Forcione², Matthew Bechtold³, Srinivas R. Puli¹¹Department of Gastroenterology and Hepatology, University of Illinois College of Medicine at Peoria, Peoria, IL, USA²Department of Gastroenterology and Hepatology, Boca Raton Regional Hospital, Boca Raton, FL, USA³Department of Gastroenterology and Hepatology, University of Missouri-Columbia, Columbia, MO, USA**Abstract**

Background: Heller myotomy has been considered the standard surgical treatment for patients with achalasia. Since the initiation of peroral endoscopic myotomy (POEM), it has represented an alternative for treating patients with achalasia. Over the years, numerous prospective and retrospective studies with POEM use for achalasia have been published. We performed a systematic review and meta-analysis to evaluate the efficacy and safety of POEM in patients with achalasia.

Methods: Publications investigating the safety and efficacy of POEM in patients with achalasia were searched in Medline, Ovid Journals, Medline non-indexed citations, and Cochrane Central Register of Controlled Trials and Database of Systematic Reviews. Pooling was conducted by both fixed and random effects models.

Results: The initial search identified 328 reference articles; of these, 34 relevant articles were selected and reviewed. Data was extracted from 20 studies (n=1753) which met the inclusion criteria. In pooled analysis, the clinical success of POEM at 3 months was 94% (95% CI=93–95). The pooled clinical success of POEM at 12 months was 91% (95% CI=90–92). The pooled rate of gastroesophageal reflux disease (GERD) was 21% (95% CI=19–23), esophagitis was reported in 16% (95% CI=15–18), pneumomediastinum in 4% (95% CI=3–6), cervical emphysema in 12% (95% CI=10–13), pneumoperitoneum in 8% (95% CI=7–10), pneumothorax in 5% (95% CI=4–6), pleural effusion in 3% (95% CI=2–3), post-operative bleeding in 4.29% (95% CI=1.91–7.61) and aspiration pneumonia in 3.08% (95% CI=1.13–5.97) of the patients after POEM.

Conclusion: This meta-analysis suggests that POEM is a highly effective and safe endoscopic treatment for patients with achalasia and a reasonable alternative to Heller myotomy.

Keywords: Achalasia, Peroral endoscopic myotomy, Dysphagia

Cite this article as: Khaizer A, Baig M, Forcione D, Bechtold M, R. Puli S. Efficacy and safety of peroral endoscopic myotomy (POEM) in achalasia: an updated meta-analysis. *Middle East J Dig Dis* 2023;15(4):235-241. doi: 10.34172/mejdd.2023.352.

Received: December 20, 2022, **Accepted:** July 6, 2023, **ePublished:** October 30, 2023

Introduction

Achalasia is an uncommon primary motor disorder of the esophagus that is characterized by insufficient relaxation of the lower esophageal sphincter (LES) as well as disorganized peristalsis of the LES. Symptoms include dysphagia, regurgitation, and chest pain.¹ The annual incidence rate of 1.6 cases per 100 000 individuals and the prevalence of 10 cases per 100 000 appears to be rising.² While the disease can occur at any age, the onset before adolescence is rare, and it is usually diagnosed between 25 and 60 years of age.³

Achalasia results from inflammation and degeneration of neurons in the esophageal wall.^{4,5} Histological examination typically reveals decreased numbers of ganglion cells in the myenteric plexus with an increased number of lymphocytes surrounding the remaining cells.⁶ The primary loss of inhibitory neurons within the wall of the esophagus leads to an increase in the basal LES pressure and affects its normal relaxation. This leads to progressive dilation of the esophagus, tortuosity, angulation, and even mega-esophagus. Patients with achalasia are also at

an increased risk of developing esophageal cancer. Both squamous cell carcinoma and adenocarcinoma have been implicated, with squamous cell carcinoma typically having an increased prevalence.⁷

Treatment goals aim to improve the progression of the ingested contents into the stomach and alleviate dysphagia. Currently, the three main discussed therapeutic options are pneumatic dilatation (PD), laparoscopic Heller myotomy (LHM), and peroral endoscopic myotomy (POEM). The choice of treatment modality depends on many factors, including the type of achalasia, prior treatments, and the functional status of the patient.

Currently, the most common treatment modality employed by gastroenterologists is PD. It involves the passage of a dilating balloon across the LES attempting to disrupt the sphincter muscles. LHM is an alternative modality involving a laparoscopic approach to the LES myotomy. To prevent gastroesophageal reflux disease (GERD), concomitant partial fundoplication is performed. For patients who are not surgical candidates, Botox injections at LES can be offered for short-term



*Corresponding Author: Muhammad Baig, Email: Muhammad.baig@osfhealthcare.org

© 2023 The Author(s). This work is published by Middle East Journal of Digestive Diseases as an open access article distributed under the terms of the Creative Commons Attribution License (<http://creativecommons.org/licenses/by/4.0/>), which permits unrestricted use, distribution, and reproduction in any medium, provided the original work is properly cited.

symptom relief.

POEM is a novel endoscopic procedure that incorporates concepts of natural orifice transluminal endoscopic surgery and expands upon techniques used in endoscopic submucosal dissection in order to achieve a division of the esophageal circular muscle fibers across the gastroesophageal junction. As a result, POEM incorporates the advantages of both endoscopic dilation and LHM.⁸ Previous literature and major society guidelines support it as a safe and effective treatment option, mainly for type 2 and type 3 achalasia.⁹ When performed by an experienced operator, there is a low incidence of intra and post-procedure complications.¹⁰

Ortega et al in 1980, first described a technique for dissecting the LES using a needle-knife to cut the muscular fibers from the luminal side.¹¹ Later, Pasricha et al described the feasibility of an endoscopic mucosal esophageal myotomy in animal models.¹² Thereafter, in 2010 Inoue et al successfully performed the first POEM in humans. Inoue is also known for coining the term peroral endoscopic esophageal myotomy.¹³ Since then, there have been a number of prospective and retrospective data in terms of outcomes and adverse events. The aim of this meta-analysis was to pool the results of previously published literature on the efficacy and safety of this novel technique.

Materials and Methods

Search Methodology

A literature search was conducted using the electronic database engines MEDLINE through PubMed, Ovid, Cochrane Library (Cochrane Central Register of Controlled Trials and Cochrane Database of Systematic Reviews), EMBASE, Cumulative Index for Nursing & Allied Health Literature, ACP Journal Club, Database of Abstracts of Reviews of Effects (DARE), International Pharmaceutical Abstracts, OVID HealthStar, and Google Scholar from January 1974 to July 2021 to identify published articles and reports addressing the use of POEM in patients with achalasia. The combinations of keywords used were “Peroral Endoscopic Myotomy” or “POEM” and “Achalasia”. The reference list of all eligible studies was reviewed to identify additional studies. The retrieved studies were carefully examined to exclude potential duplicates or overlapping data. Titles and abstracts selected from the initial search were first scanned, and the full papers of potentially eligible studies were reviewed.

Study Eligibility

Published studies were eligible for inclusion if they reported the use of POEM for the management of achalasia. Articles were excluded if they were not available in English, no outcomes were reported, or they represented review articles or studies published as abstracts only. In studies using multiple modalities for the management of achalasia, data from the cohort of patients who underwent POEM were collected and analyzed. Two

reviewers (AK, MB) independently performed study selections according to eligibility criteria. Disagreements were resolved by discussion or a third reviewer.

Data Extraction and Quality Assessment

The following data was independently abstracted onto a standardized form: study characteristics (primary author, time period of study, year of publication, and country of the population studied), study design, baseline characteristics of the study population (the numbers of patients enrolled, participant demographics, pre-procedure dysphagia score), the intervention details and outcomes (clinical success at 3 months, efficacy at 1-year, post-procedure dysphagia score and complications). Risk of bias was rated for each study by two authors independently, using the Cochrane criteria for RCTs.¹⁴

Outcome Definition

The primary outcome of interest was efficacy assessment 3 and 12 months after the procedure. This was defined as a post-POEM Eckardt score ≤ 3 or clinically relevant improvement of dysphagia. The secondary outcome of interest was safety assessment, including immediate and late complications. GERD was defined as symptomatic gastroesophageal reflux or abnormal acid exposure noted in a 24-hour pH monitoring study. Esophagitis was defined by the presence of erosions or ulcerations in the distal esophagus noted on upper gastrointestinal (GI) endoscopy.

Statistical Analysis

This meta-analysis was performed by calculating pooled proportions. First, the individual study proportions were transformed into a quantity using Freeman-Tukey variant of the arcsine square root transformed proportion. The pooled proportion is calculated as the back-transform of the weighted mean of the transformed proportions, using inverse arcsine variance weights for the fixed effects model and DerSimonian-Laird weights for the random effects model. Forest plots were drawn to show the point estimates in each study in relation to the summary pooled estimate. The width of the point estimates in the Forest plots indicates the assigned weight to that study. The heterogeneity among studies was tested using I^2 statistic and Cochran Q test based upon inverse variance weights. I^2 of 0% to 39% was considered as nonsignificant heterogeneity, 40% to 75% as moderate heterogeneity, and 76% to 100% as considerable heterogeneity. If P value is > 0.10 , it rejects the null hypothesis that the studies are heterogeneous. The effect of publication and selection bias on the summary estimates was tested by the Egger bias indicator.¹⁵

Results

The initial search identified 328 reference articles; of these, 34 relevant articles were selected and reviewed. Data was extracted from 20 studies which met the inclusion criteria.

A Preferred Reporting Items for Systematic Reviews and Meta-Analyses (PRISMA) flow diagram for details of the review process is shown in Figure 1. All the studies are published as full-text articles. All the pooled estimates given are estimates calculated by the fixed effects model.

The total number of patients included in this meta-analysis was 1753. Table 1 shows the baseline characteristics of the studies.

Primary Outcome

In pooled analysis, the clinical success of POEM at 3 months was 94% (95% CI=93–95). A forest plot diagram of the pooled analysis is shown in Figure 2. Publication bias calculated using the Harbord-Egger bias indicator gave a value of -0.26 (95% CI=-2.14–1.62, $P=0.79$), indicating no publication bias. Figure 3 is a funnel plot assessing the publication bias for the same variable.

Secondary Outcomes

Clinical Success at 12 Months

In the pooled analysis, the pooled clinical success of POEM at 12 months was 91% (95% CI=90–92). A forest plot diagram of the pooled analysis is shown in Figure 4. Publication bias calculated using the Harbord-Egger bias indicator gave a value of -3.29 (95% CI=-9.59–3.01, $P=0.30$), indicating no publication bias. Figure 5 is a funnel plot assessing the publication bias for the same

Table 1. Basic characteristics of the included studies

| Study | Year | Type of study | Country | N |
|---|------|---------------|---------------|-----|
| Shiwaku et al ¹⁶ | 2020 | PCT | Japan | 233 |
| Kahaleh et al ¹⁷ | 2020 | PCT | Latin America | 69 |
| Hernández-Mondragón et al ¹⁸ | 2018 | PCT | Mexico | 50 |
| Martinek et al ¹⁹ | 2018 | PCT | USA | 132 |
| Li et al ²⁰ | 2018 | PCT | China | 564 |
| Nabi et al ²¹ | 2017 | PCT | India | 408 |
| Minami e al ²² | 2014 | RCT | Japan | 28 |
| Khashab et al ²³ | 2014 | RCT | USA | 9 |
| Hungness et al ²⁴ | 2013 | RCT | USA | 18 |
| Verlaan at al ²⁵ | 2013 | PCT | Netherlands | 10 |
| Kurian et al ²⁶ | 2013 | PCT | USA | 40 |
| Rieder et al ²⁷ | 2013 | RCT | USA | 4 |
| Chiu et al ²⁸ | 2013 | PCT | China | 16 |
| Meireles et al ²⁹ | 2013 | PCT | USA | 7 |
| Lee et al ³⁰ | 2013 | RCT | Korea | 13 |
| Ujiki et al ³¹ | 2013 | RCT | USA | 18 |
| Von Renteln et al ³² | 2013 | PCT | International | 70 |
| Teitelbaum et al ³³ | 2013 | PCT | USA | 36 |
| Costamagna et al ^{16,34} | 2012 | RCT | Italy | 11 |
| Inoue et al ¹³ | 2010 | PCT | Japan | 17 |

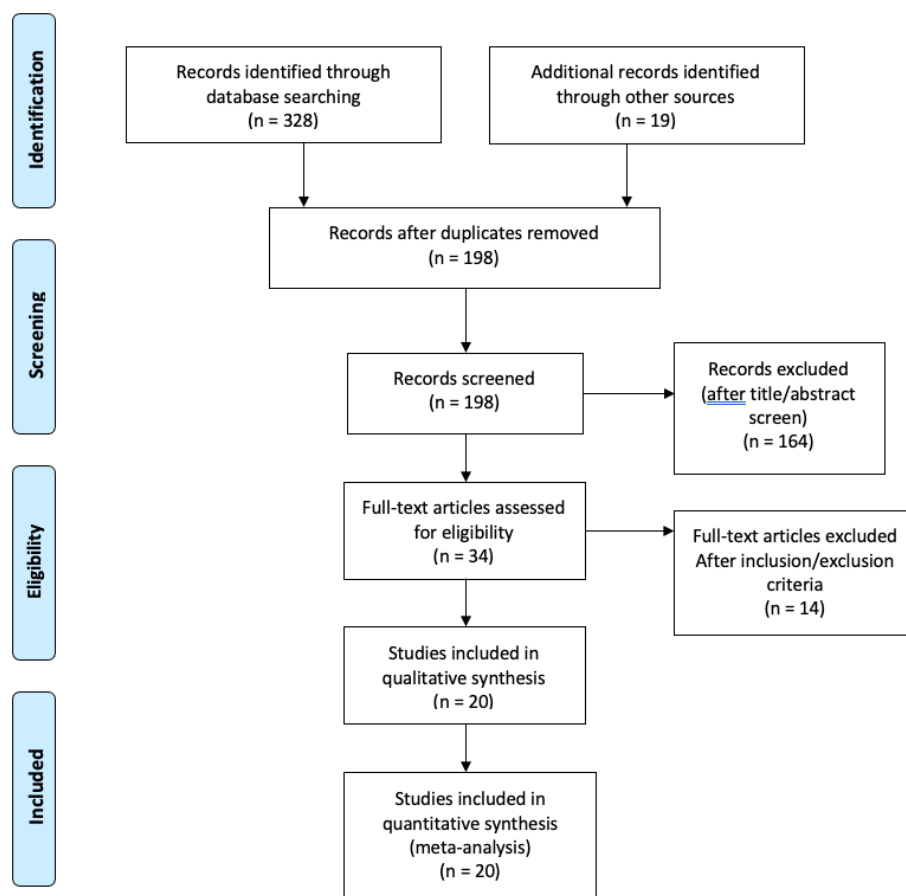


Figure 1. Preferred Reporting Items for Systematic Reviews and Meta-Analyses flow diagram detailing the review process

Proportion meta-analysis plot [fixed effects]

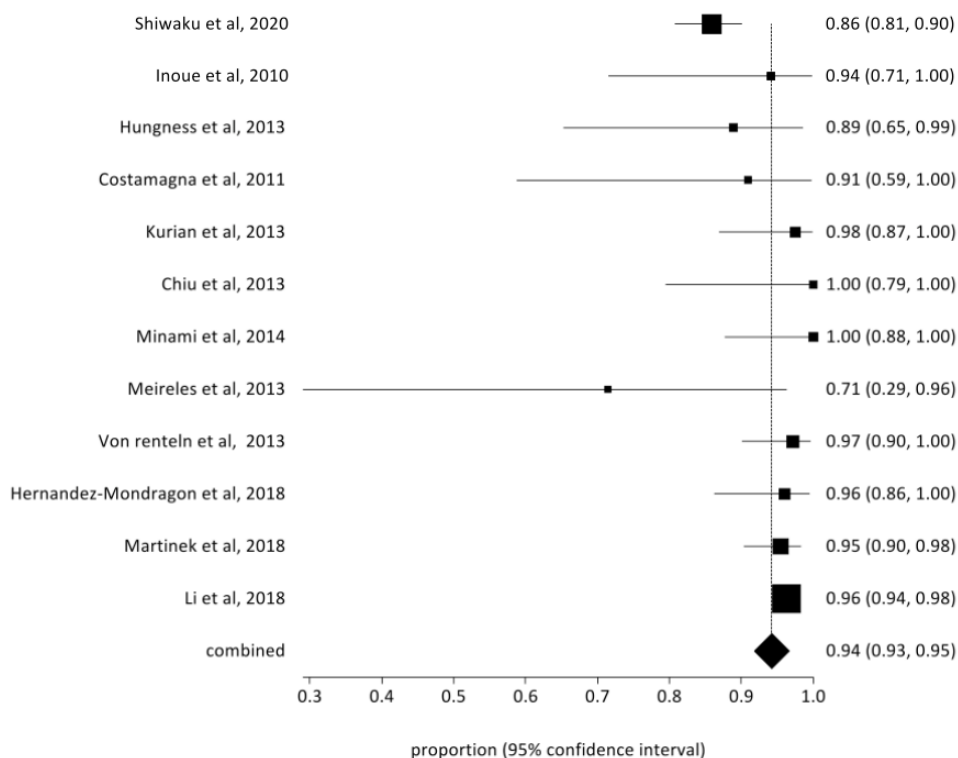


Figure 2. Forrest plot showing the pooled estimate of clinical success at 3 months with peroral endoscopic myotomy (POEM) in patients with achalasia

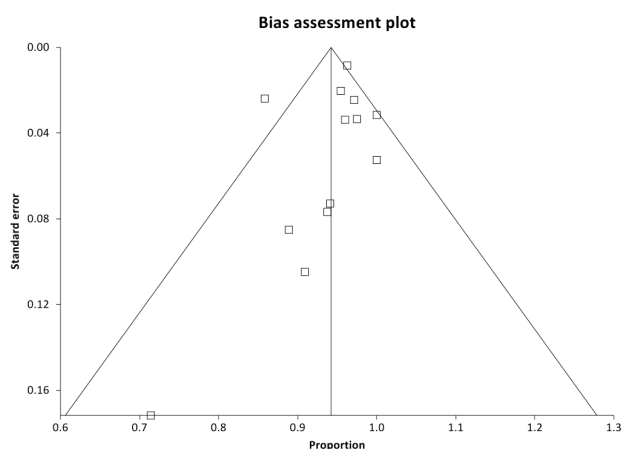


Figure 3. Bias assessment plot of publication bias in reporting clinical success at 3 months with peroral endoscopic myotomy (POEM) in patients with achalasia

variable.

Pooled change in Eckardt score at 12 months was noted to be -3.95 (95% CI = -4.10 – -3.80).

Rate of Immediate Complications

Pooled rate of pneumomediastinum was 4% (95% CI = 3–6), cervical emphysema was reported in 12% (95% CI = 10–13), pneumoperitoneum in 8% (95% CI = 7–10), pneumothorax in 5% (95% CI = 4–6), pleural effusion in 3% (95% CI = 2–3), post-operative bleeding in 4.29% (95% CI = 1.91–7.61) and aspiration pneumonia in 3.08% (95% CI = 1.13–5.97) of the patients after POEM.

Rate of Late Complications

The pooled rate of GERD was 21% (95% CI = 19–23), and esophagitis was reported in 16% (95% CI = 15–18) of the patients.

Discussion

POEM is a relatively novel, minimally invasive technique that entails the creation of a submucosal tunnel, followed by myotomy of the muscular layer, reducing LES resting pressure.³⁵ The major alternatives to POEM for the treatment of achalasia are Heller myotomy and endoscopic pneumatic dilation. Since 2008, POEM has proven its efficacy in the treatment of patients with achalasia. POEM can be offered for different esophageal diseases, is cost-saving, and provides a longer myotomy with similar long-term benefits as compared to LHM, all while reducing post-procedural complications.¹⁸ In addition, endoscopic myotomy has proven to be a promising technique for other esophageal conditions, such as Jackhammer esophagus, and as a “salvation technique” for patients with recurrent symptoms after LHM. Prior studies have demonstrated similar results comparing POEM and LHM and found that patients in the POEM group had lower Eckardt scores after the procedure compared with the LHM group.³⁵ Similarly, Schlottmann et al conducted a meta-analysis of LHM versus POEM for achalasia, confirming that overall, POEM is more effective than the Heller procedure based on short-term results.³⁶ Endoscopic pneumatic dilation is associated with a 4% risk of perforation, although it

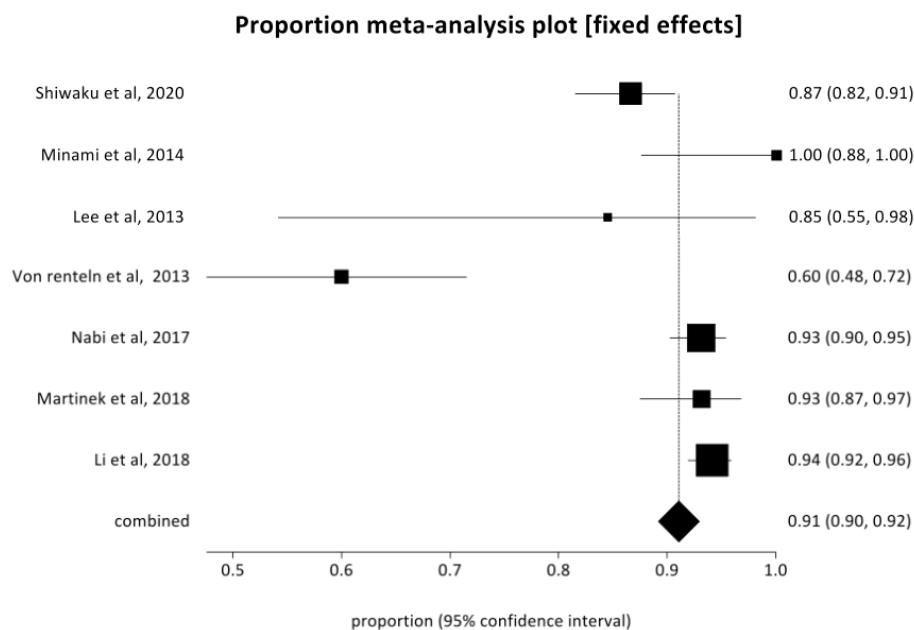


Figure 4. Forrest plot showing the pooled estimate of clinical success at 12 months with peroral endoscopic myotomy (POEM) in patients with achalasia

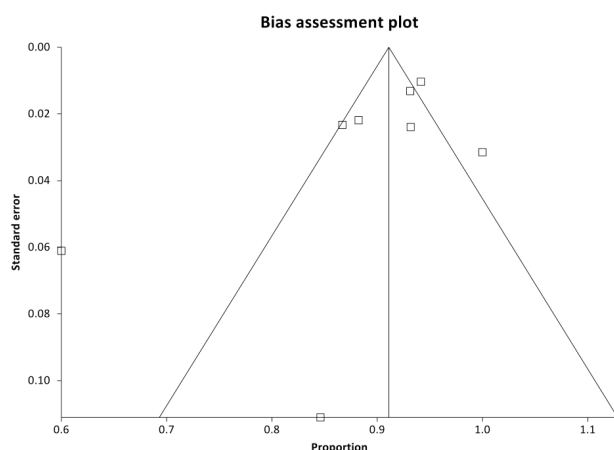


Figure 5. Bias assessment plot of publication bias in reporting clinical success at 12 months with peroral endoscopic myotomy (POEM) in patients with achalasia

appears to be as effective as Heller myotomy for at least 2–3 years.

In order to summarize the literature and assess for potential sources of heterogeneity, we conducted a systematic review and meta-analysis of available literature on the safety and efficacy of POEM.

This study further adds to the available evidence that POEM is an effective treatment for performing an endoscopic myotomy in patients with achalasia. In a pooled population of 1753, our meta-analysis demonstrated a pooled clinical success of 93% at 3 months and 91% at 1 year. Moreover, the risk of adverse events requiring surgical intervention was minimal and only observed in one patient.²⁴ Most of the adverse-related events were successfully managed conservatively.

As no anti-reflux procedure is performed in POEM, the development of GERD post-operatively has been a concern since its introduction. In our meta-analysis, post-

POEM GERD was noted in 21% of the patients, which is higher than a rate of 11.5% with LHM noted in a large meta-analysis.³⁶ While the aim of POEM is to leave the layer of longitudinal muscle fibers intact, adverse events of pneumomediastinum, pneumoperitoneum and/or subcutaneous emphysema were noted in less than 10% of the patients.

This study has several limitations. The absence of individual patient data limited our ability to stratify patients according to the manometric subtype and previous treatments. Long-term follow-up was unavailable in most studies as POEM is a novel technique.

Conclusion

In conclusion, our study adds to the current evidence that POEM is a safe and efficacious procedure for patients with achalasia. As a short-term follow-up, POEM resulted in a significant decrease in Eckardt score with minimal adverse events. At this time, further data would be beneficial in discussing the long-term outcomes of POEM.

Competing Interests

The authors declare no conflict of interest related to this work.

Funding

No financial support/declaration.

References

- Eckardt VF, Stauf B, Bernhard G. Chest pain in achalasia: patient characteristics and clinical course. *Gastroenterology* 1999;116(6):1300-4. doi: [10.1016/s0016-5085\(99\)70493-2](https://doi.org/10.1016/s0016-5085(99)70493-2)
- Samo S, Carlson DA, Gregory DL, Gawel SH, Pandolfino JE, Kahrilas PJ. Incidence and prevalence of achalasia in Central Chicago, 2004-2014, since the widespread use of high-resolution manometry. *Clin Gastroenterol Hepatol* 2017;15(3):366-73. doi: [10.1016/j.cgh.2016.08.030](https://doi.org/10.1016/j.cgh.2016.08.030)
- Allgrove J, Clayden GS, Grant DB, Macaulay JC. Familial

- glucocorticoid deficiency with achalasia of the cardia and deficient tear production. *Lancet* 1978;1(8077):1284-6. doi: [10.1016/s0140-6736\(78\)91268-0](https://doi.org/10.1016/s0140-6736(78)91268-0)
4. Wong RK, Maydonovitch CL, Metz SJ, Baker JR Jr. Significant DQw1 association in achalasia. *Dig Dis Sci* 1989;34(3):349-52. doi: [10.1007/bf01536254](https://doi.org/10.1007/bf01536254)
 5. Verne GN, Sallustio JE, Eaker EY. Anti-myenteric neuronal antibodies in patients with achalasia. A prospective study. *Dig Dis Sci* 1997;42(2):307-13. doi: [10.1023/a:1018857617115](https://doi.org/10.1023/a:1018857617115)
 6. Goldblum JR, Rice TW, Richter JE. Histopathologic features in esophagomyotomy specimens from patients with achalasia. *Gastroenterology* 1996;111(3):648-54. doi: [10.1053/gast.1996.v111.pm8780569](https://doi.org/10.1053/gast.1996.v111.pm8780569)
 7. Sandler RS, Nyrén O, Ekbom A, Eisen GM, Yuen J, Josefsson S. The risk of esophageal cancer in patients with achalasia. A population-based study. *JAMA* 1995;274(17):1359-62.
 8. Khashab MA, Pasricha PJ. Conquering the third space: challenges and opportunities for diagnostic and therapeutic endoscopy. *Gastrointest Endosc* 2013;77(1):146-8. doi: [10.1016/j.gie.2012.09.022](https://doi.org/10.1016/j.gie.2012.09.022)
 9. Kahrilas PJ, Katzka D, Richter JE. Clinical practice update: the use of per-oral endoscopic myotomy in achalasia: expert review and best practice advice from the AGA Institute. *Gastroenterology* 2017;153(5):1205-11. doi: [10.1053/j.gastro.2017.10.001](https://doi.org/10.1053/j.gastro.2017.10.001)
 10. Werner YB, von Renteln D, Noder T, Schachschal G, Denzer UW, Groth S, et al. Early adverse events of per-oral endoscopic myotomy. *Gastrointest Endosc* 2017;85(4):708-18.e2. doi: [10.1016/j.gie.2016.08.033](https://doi.org/10.1016/j.gie.2016.08.033)
 11. Ortega JA, Madureri V, Perez L. Endoscopic myotomy in the treatment of achalasia. *Gastrointest Endosc* 1980;26(1):8-10. doi: [10.1016/s0016-5107\(80\)73249-2](https://doi.org/10.1016/s0016-5107(80)73249-2)
 12. Pasricha PJ, Hawari R, Ahmed I, Chen J, Cotton PB, Hawes RH, et al. Submucosal endoscopic esophageal myotomy: a novel experimental approach for the treatment of achalasia. *Endoscopy* 2007;39(9):761-4. doi: [10.1055/s-2007-966764](https://doi.org/10.1055/s-2007-966764)
 13. Inoue H, Minami H, Kobayashi Y, Sato Y, Kaga M, Suzuki M, et al. Peroral endoscopic myotomy (POEM) for esophageal achalasia. *Endoscopy* 2010;42(4):265-71. doi: [10.1055/s-0029-1244080](https://doi.org/10.1055/s-0029-1244080)
 14. Higgins J, Green S. *Cochrane Handbook for Systematic Reviews of Interventions*. John Wiley & Sons; 2008.
 15. Harbord RM, Egger M, Sterne JA. A modified test for small-study effects in meta-analyses of controlled trials with binary endpoints. *Stat Med* 2006;25(20):3443-57. doi: [10.1002/sim.2380](https://doi.org/10.1002/sim.2380)
 16. Shiwaku H, Inoue H, Sato H, Onimaru M, Minami H, Tanaka S, et al. Peroral endoscopic myotomy for achalasia: a prospective multicenter study in Japan. *Gastrointest Endosc* 2020;91(5):1037-44.e2. doi: [10.1016/j.gie.2019.11.020](https://doi.org/10.1016/j.gie.2019.11.020)
 17. Kahaleh M, Tyberg A, Suresh S, Lambroza A, Gaidhane M, Zamarripa F, et al. How does per-oral endoscopic myotomy compare to Heller myotomy? The Latin American perspective. *Endosc Int Open* 2020;8(10):E1392-E7. doi: [10.1055/a-1223-1521](https://doi.org/10.1055/a-1223-1521)
 18. Hernández-Mondragón OV, Solórzano-Pineda OM, González-Martínez MA, Blancas-Valencia JM, Caballero-Luengas C. Peroral endoscopic myotomy for the treatment of achalasia and other esophageal motor disorders: short-term and medium-term results at a Mexican tertiary care center. *Rev Gastroenterol Mex (Engl Ed)* 2019;84(1):1-10. doi: [10.1016/j.rgm.2017.09.001](https://doi.org/10.1016/j.rgm.2017.09.001)
 19. Martinek J, Svecova H, Vackova Z, Dolezel R, Ngo O, Krajcivova J, et al. Per-oral endoscopic myotomy (POEM): mid-term efficacy and safety. *Surg Endosc* 2018;32(3):1293-302. doi: [10.1007/s00464-017-5807-3](https://doi.org/10.1007/s00464-017-5807-3)
 20. Li QL, Wu QN, Zhang XC, Xu MD, Zhang W, Chen SY, et al. Outcomes of per-oral endoscopic myotomy for treatment of esophageal achalasia with a median follow-up of 49 months. *Gastrointest Endosc* 2018;87(6):1405-12.e3. doi: [10.1016/j.gie.2017.10.031](https://doi.org/10.1016/j.gie.2017.10.031)
 21. Nabi Z, Ramchandani M, Chavan R, Kalapala R, Darisetty S, Rao GV, et al. Per-oral endoscopic myotomy for achalasia cardia: outcomes in over 400 consecutive patients. *Endosc Int Open* 2017;5(5):E331-E9. doi: [10.1055/s-0043-105517](https://doi.org/10.1055/s-0043-105517)
 22. Minami H, Isomoto H, Yamaguchi N, Matsushima K, Akazawa Y, Ohnita K, et al. Peroral endoscopic myotomy for esophageal achalasia: clinical impact of 28 cases. *Dig Endosc* 2014;26(1):43-51. doi: [10.1111/den.12086](https://doi.org/10.1111/den.12086)
 23. Khashab MA, Messallam AA, Saxena P, Kumbhari V, Ricourt E, Aguila G, et al. Jet injection of dyed saline facilitates efficient peroral endoscopic myotomy. *Endoscopy* 2014;46(4):298-301. doi: [10.1055/s-0033-1359024](https://doi.org/10.1055/s-0033-1359024)
 24. Hungness ES, Teitelbaum EN, Santos BF, Arafat FO, Pandolfino JE, Kahrilas PJ, et al. Comparison of perioperative outcomes between peroral esophageal myotomy (POEM) and laparoscopic Heller myotomy. *J Gastrointest Surg* 2013;17(2):228-35. doi: [10.1007/s11605-012-2030-3](https://doi.org/10.1007/s11605-012-2030-3)
 25. Verlaan T, Rohof WO, Bredenoord AJ, Eberl S, Rösch T, Fockens P. Effect of peroral endoscopic myotomy on esophagogastric junction physiology in patients with achalasia. *Gastrointest Endosc* 2013;78(1):39-44. doi: [10.1016/j.gie.2013.01.006](https://doi.org/10.1016/j.gie.2013.01.006)
 26. Kurian AA, Dunst CM, Sharata A, Bhayani NH, Reavis KM, Swanström LL. Peroral endoscopic esophageal myotomy: defining the learning curve. *Gastrointest Endosc* 2013;77(5):719-25. doi: [10.1016/j.gie.2012.12.006](https://doi.org/10.1016/j.gie.2012.12.006)
 27. Rieder E, Swanström LL, Perretta S, Lenglinger J, Riegler M, Dunst CM. Intraoperative assessment of esophagogastric junction distensibility during per oral endoscopic myotomy (POEM) for esophageal motility disorders. *Surg Endosc* 2013;27(2):400-5. doi: [10.1007/s00464-012-2484-0](https://doi.org/10.1007/s00464-012-2484-0)
 28. Chiu PW, Wu JC, Teoh AY, Chan Y, Wong SK, Liu SY, et al. Peroral endoscopic myotomy for treatment of achalasia: from bench to bedside (with video). *Gastrointest Endosc* 2013;77(1):29-38. doi: [10.1016/j.gie.2012.08.018](https://doi.org/10.1016/j.gie.2012.08.018)
 29. Meireles OR, Horgan S, Jacobsen GR, Katagiri T, Mathew A, Sedrak M, et al. Transesophageal endoscopic myotomy (TEEM) for the treatment of achalasia: the United States human experience. *Surg Endosc* 2013;27(5):1803-9. doi: [10.1007/s00464-012-2666-9](https://doi.org/10.1007/s00464-012-2666-9)
 30. Lee BH, Shim KY, Hong SJ, Bok GH, Cho JH, Lee TH, et al. Peroral endoscopic myotomy for treatment of achalasia: initial results of a Korean study. *Clin Endosc* 2013;46(2):161-7. doi: [10.5946/ce.2013.46.2.161](https://doi.org/10.5946/ce.2013.46.2.161)
 31. Ujiki MB, Yetasook AK, Zapf M, Linn JG, Carbray JM, Denham W. Peroral endoscopic myotomy: a short-term comparison with the standard laparoscopic approach. *Surgery* 2013;154(4):893-900. doi: [10.1016/j.surg.2013.04.042](https://doi.org/10.1016/j.surg.2013.04.042)
 32. Von Renteln D, Fuchs KH, Fockens P, Bauerfeind P, Vassiliou MC, Werner YB, et al. Peroral endoscopic myotomy for the treatment of achalasia: an international prospective multicenter study. *Gastroenterology* 2013;145(2):309-11.e3. doi: [10.1053/j.gastro.2013.04.057](https://doi.org/10.1053/j.gastro.2013.04.057)
 33. Teitelbaum EN, Soper NJ, Arafat FO, Santos BF, Kahrilas PJ, Pandolfino JE, et al. Analysis of a learning curve and predictors of intraoperative difficulty for peroral esophageal myotomy (POEM). *J Gastrointest Surg* 2014;18(1):92-9. doi: [10.1007/s11605-013-2332-0](https://doi.org/10.1007/s11605-013-2332-0)
 34. Costamagna G, Marchese M, Familiari P, Tringali A, Inoue H, Perri V. Peroral endoscopic myotomy (POEM) for oesophageal

- achalasia: preliminary results in humans. *Dig Liver Dis* 2012;44(10):827-32. doi: [10.1016/j.dld.2012.04.003](https://doi.org/10.1016/j.dld.2012.04.003)
35. Kumbhari V, Tieu AH, Onimaru M, El Zein MH, Teitelbaum EN, Ujiki MB, et al. Peroral endoscopic myotomy (POEM) vs laparoscopic Heller myotomy (LHM) for the treatment of type III achalasia in 75 patients: a multicenter comparative study. *Endosc Int Open* 2015;3(3):E195-201. doi: [10.1055/s-0034-1391668](https://doi.org/10.1055/s-0034-1391668)
36. Schlottmann F, Luckett DJ, Fine J, Shaheen NJ, Patti MG. Laparoscopic Heller myotomy versus peroral endoscopic myotomy (POEM) for achalasia: a systematic review and meta-analysis. *Ann Surg* 2018;267(3):451-60. doi: [10.1097/sla.0000000000002311](https://doi.org/10.1097/sla.0000000000002311)