

Case
Report

Extended Bronchoplasty Anastomosed between the Left Main and the Superior Segmental Bronchi for Locally Advanced Left Upper Lobe Lung Cancer with Invasion of the Basal Segment

Keisuke Yokota, MD, PhD,¹ Katsuhiko Okuda, MD, PhD,¹ Ichiro Fukai, MD, PhD,²
and Ryoichi Nakanishi, MD, PhD¹

We report a case of extended bronchoplasty in which anastomosis between the left main and the superior segmental bronchi with resection of the left upper lobe and basal segment was required to avoid pneumonectomy for locally advanced lung cancer. The main tumor located at the left upper lobe invaded the basal segment, and involved both the basal pulmonary artery and left secondary carina. Regarding anastomosis, the bronchi were cut in a deep wedge shape and a wall flap was made by part of the lower lobar bronchus. The patient's postoperative course was uneventful and he has been alive without recurrence for more than 3 years after surgery.

Keywords: extended bronchoplasty, lung cancer, surgery

Introduction

Pneumonectomy is generally indicated in cases of left hilar lung cancer with invasion to another lobe.¹⁾ On the other hand, there are some cases in which pneumonectomy can be avoided by extended bronchoplasty.¹⁻⁵⁾ We herein report a case of extended wedge bronchoplasty with the removal of the left upper lobe and the basal segment. Preserving even with only the superior segment

may lead to a reduction in pulmonary impairment and the prevention of postpneumonectomy syndrome and dysphagia. Our unique extended bronchoplasty procedure enabled us to avoid pneumonectomy for locally advanced left upper lobe lung cancer that invaded the basal segment and involved the basal pulmonary artery and bronchus.

Case Report

A 72-year-old man was admitted to our hospital because of hemoptysis. Chest computed tomography (CT) showed a left hilar lung tumor of 45 mm in diameter that was diagnosed as squamous cell carcinoma by transbronchial lung biopsy. Preoperative spirometry showed that the vital capacity (VC) was 3950 ml and the forced expiratory volume in one second (FEV1) was 2720 mL. The predicted postoperative (ppo) respiratory function, which was evaluated based on preoperative spirometry and the number of subsegments was as follows: the ppoVC and ppoFEV1 of the left pneumonectomy were 2069 and 1424 mL, respectively, while those when the superior segment was preserved were 2351 and 1619 mL. Contrast-enhanced CT showed no

¹Department of Oncology, Immunology and Surgery, Nagoya City University Graduate School of Medical Sciences, Nagoya, Aichi, Japan

²Department of Thoracic Surgery, Suzuka Chuo General Hospital, Suzuka, Mie, Japan

Received: July 8, 2020; Accepted: August 23, 2020

Corresponding author: Katsuhiko Okuda, MD, PhD. Department of Oncology, Immunology and Surgery, Nagoya City University Graduate School of Medical Sciences, 1 Kawasumi, Mizuhocho, Mizuho-ku, Nagoya, Aichi 467-8601, Japan
Email: kokuda@med.nagoya-cu.ac.jp



This work is licensed under a Creative Commons Attribution-NonCommercial-NoDerivatives International License.

©2022 The Editorial Committee of *Annals of Thoracic and Cardiovascular Surgery*

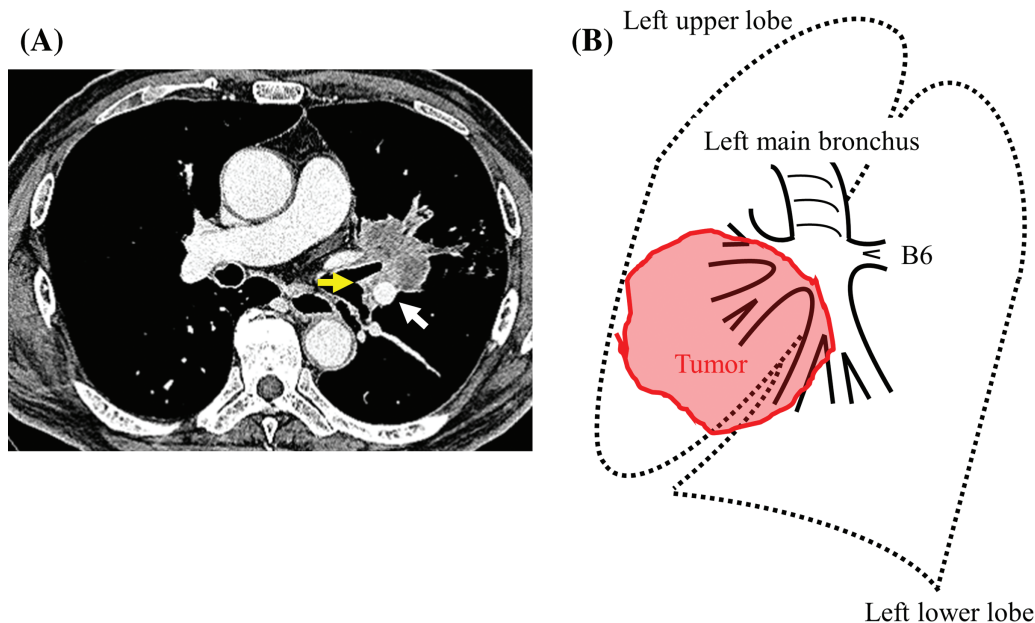


Fig. 1 (A) Contrast-enhanced CT of the chest showing a hilar lung tumor of 45 mm in diameter. The tumor of the left upper lobe involved the basal pulmonary artery (white arrow) and the left secondary carina (yellow arrow). (B) A schematic illustration showing the tumor located in the left upper lobe, which invaded the basal segment of the lower lobe.

enlargement of the hilar or mediastinal lymph nodes, and head magnetic resonance imaging and ^{18}F -fluorodeoxyglucose positron emission tomography showed no distant metastasis. The clinical stage was diagnosed as stage IIA (cT2bN0M0, TNM classification, 7th edition), and surgical resection was planned. CT showed that the tumor of the left upper lobe invaded the basal segment and involved the basal pulmonary artery and left secondary carina (**Fig. 1A**). Our preoperative plan was as follows: if the tumor invasion limited to the basal pulmonary artery, the left upper lobectomy and the arterioplasty with patch procedure was planned because of relatively large vascular defect. If the tumor also invaded to the lower bronchus, pneumonectomy was planned.

Left posterolateral thoracotomy via the fifth intercostal space was performed. Because the tumor invaded the superior pulmonary vein close to the pericardium, intrapericardial vessel management was needed. After encircling the left main pulmonary artery and superior pulmonary vein in the pericardium, the extent of tumor invasion was confirmed from the interlobar surface. The tumor in the lingular segment invaded the basal pulmonary artery and the left secondary carina (**Fig. 1B**). Because the superior segment of the lower lobe was intact from tumor invasion, we changed our plan to perform extended wedge bronchoplasty with the removal of upper lobe, including the basal segment of the lower

lobe, which combined anastomosis between the left main and the superior segmental bronchi to preserve the superior segment. Then, the pulmonary arteries and veins of the upper lobe and the basal segment were dissected sequentially. After separating the basal segment from the superior segment using a stapling device, the left main and superior segmental bronchi were cut in a deep wedge shape and a bronchial wall flap was made with part of the lower lobar bronchus to match the aperture of the main bronchus with the caliber of the superior segmental bronchi (**Fig. 2A**). The cut ends of the bronchi were confirmed to be negative for cancer based on a frozen section examination during the operation. A deep one-third circle was sewn with a running suture using 4-0 monofilament absorbable suture, and the remaining circle was sewn with interrupted sutures (**Fig. 2B**). The anastomotic site was wrapped with the pericardial free fat pad. To prevent torsion, the superior segment was sutured to the intercostal muscle at the site of the thoracotomy wound (**Fig. 2C**). Regarding the lymphadenectomy, systematic mediastinal lymph node dissection (ND2a-2) was performed. The tumor was pathologically diagnosed as squamous cell carcinoma and the stage was confirmed to be T2bN0M0 in accordance with the seventh edition of the TNM classification. The patient's postoperative course was uneventful. The postoperative chest X-ray showed that the superior segment of the left

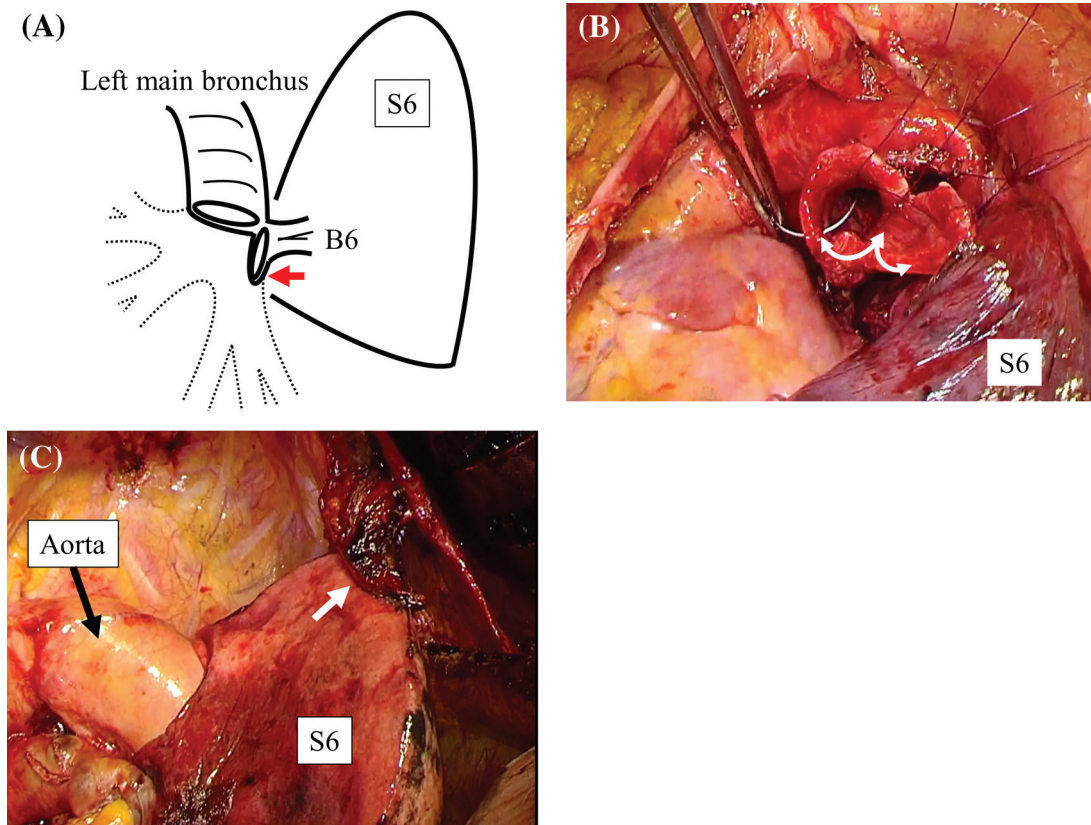


Fig. 2 The operative procedure. B6, the superior segmental bronchus. S6, the superior segment. (A) The left main and the superior segmental bronchi were cut in a deep wedge shape and a bronchial wall flap was made from part of the lower lobar bronchus to match the aperture of the main bronchus with the caliber of the superior segmental bronchi (red arrow). (B) A deep one-third circle was sewn with a running suture using 4-0 monofilament absorbable suture (white arrow), and the remaining circle was sewn with interrupted sutures. (C) To prevent torsion, the superior segment was sutured to the intercostal muscle at the site of the thoracotomy wound (white arrow).

lung was appropriately located and that it expanded properly (**Fig. 3A**) and the patency of anastomosis between the left main and the superior segmental bronchi was checked by bronchoscopy (**Fig. 3B**). Adjuvant chemotherapy was not performed because of comorbidity. Spirometry at one and a half years after surgery showed that the VC was 2430 mL and the FEV1 was 1740 mL. At the time of writing this report, the patient has been alive without recurrence for more than 3 years after surgery.

Comment

Extended bronchoplasty for locally advanced lung cancer is a challenging procedure that requires a removal of more than a pulmonary lobe and the adjustment of different bronchial calibers.²⁻⁵ As Okada et al. reported, pneumonectomy should be avoided at all costs because the risk of perioperative morbidity and mortality is

greater in pneumonectomy than in lobectomy and there are complications peculiar to pneumonectomy that worsen the quality of life for a long time, such as the so-called postpneumonectomy syndrome.^{2,6} Okada et al. classified 15 patients who underwent extended bronchoplasty into three groups according to the surgical procedure. However, the present type of anastomosis between the left main and the superior segmental bronchi was not classified in the article and has not previously been reported. Regarding anastomosis between the left main and the superior segmental bronchi, the bronchi were cut in a deep wedge shape and were trimmed to match the calibers. The reason why the deep wedge cut was performed is that the superior segmental bronchus immediately diverged into the three subsegmental bronchi and sleeve resection was thought to be difficult for anatomical reasons. Another reason is that wedge resection was thought to be superior to sleeve resection from the point of view of blood flow at the superior segmental

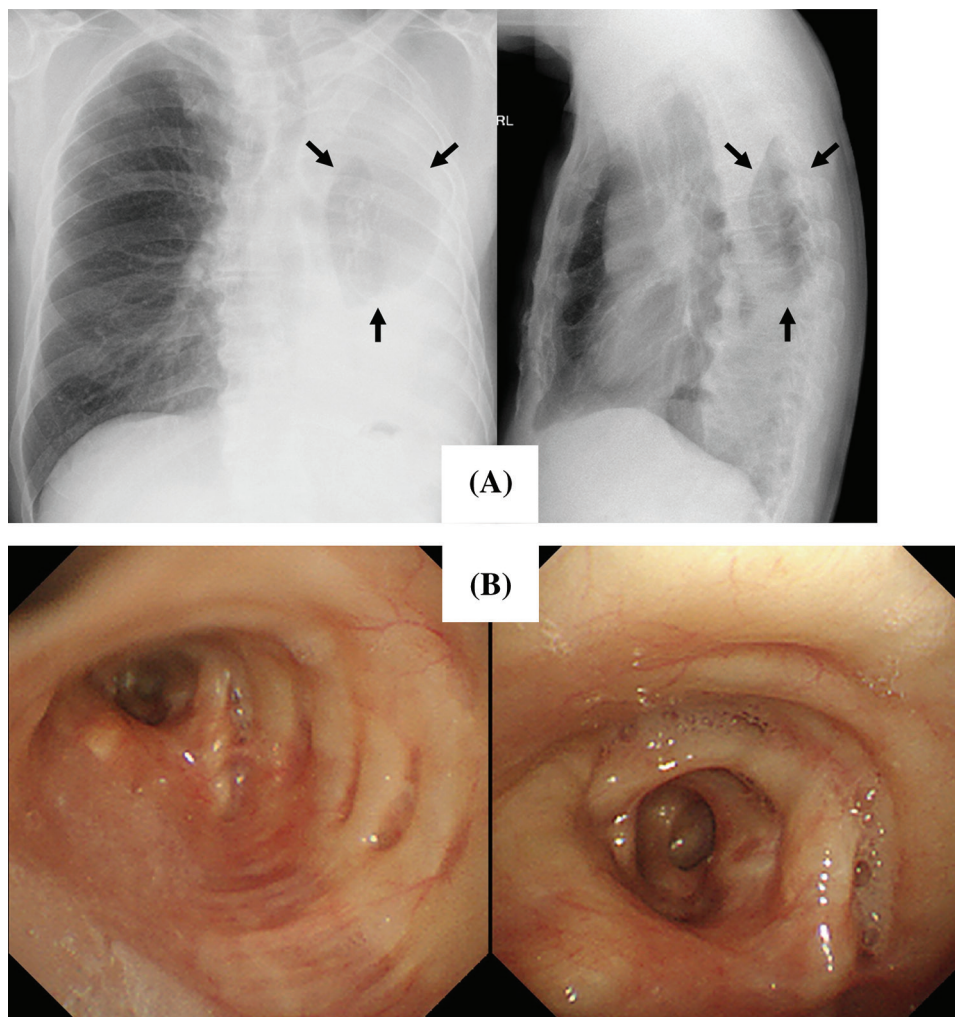


Fig. 3 (A) Postoperative chest X-ray demonstrated that the superior segment was located at a suitable position and expanded properly. (B) Bronchoscopy showed patent anastomosis between the left main and the superior segmental bronchi.

side, where the bronchial wall flap was made. The adjustment of the caliber difference between the two bronchi is quite important to successful anastomosis. Therefore, the bronchial wall flap was made at the superior segmental side in the present case. Regarding the respiratory function, the better postoperative VC and FEV1 values demonstrate that even just one segment of the lung is worthy of preservation. Furthermore, only the superior segment prevented a rapid mediastinal shift and did not cause serious complications, such as postpneumonectomy syndrome or dysphagia.⁷⁾ This unique technique that avoids pneumonectomy is quite useful for preserving the patient's long-term quality of life after surgery.

Disclosure Statement

All authors have no conflicts of interest.

References

- 1) Deslauriers J, Grégoire J, Jacques LF, et al. Sleeve lobectomy versus pneumonectomy for lung cancer: a comparative analysis of survival and sites or recurrences. *Ann Thorac Surg* 2004; **77**: 1152–6; discussion 1156.
- 2) Okada M, Tsubota N, Yoshimura M, et al. Extended sleeve lobectomy for lung cancer: the avoidance of pneumonectomy. *J Thorac Cardiovasc Surg* 1999; **118**: 710–4.
- 3) Berthet JP, Paradela M, Jimenez MJ, et al. Extended sleeve lobectomy: one more step toward avoiding pneumonectomy in centrally located lung cancer. *Ann Thorac Surg* 2013; **96**: 1988–97.
- 4) Miyoshi S, Tamura M, Araki O, et al. Telescoping bronchial anastomosis for extended sleeve lobectomy. *J Thorac Cardiovasc Surg* 2006; **132**: 978–80.

- 5) Hishida T, Aokage K, Yoshida J, et al. Extended bronchoplasty for locally advanced left lower lobe lung cancer: surgical technique and outcomes. *Interact Cardiovasc Thorac Surg* 2018; **27**: 602–5.
- 6) Schulte T, Schniewind B, Dohrmann P, et al. The extent of lung parenchyma resection significantly impacts long-term quality of life in patients with non-small cell lung cancer. *Chest* 2009; **135**: 322–9.
- 7) Fiorelli A, Vicidomini G, Milione R, et al. The effects of lung resection on physiological motor activity of the oesophagus. *Eur J Cardiothorac Surg* 2013; **44**: 250–6;discussion 257.