J Orthop Sci (2015) 20:1–11
DOI 10.1007/s00776-014-0653-9

REVIEW ARTICLE

Clinical pathways for fragility fractures of the pelvic ring: personal experience and review of the literature

Pol M. Rommens · Christian Ossendorf · Philip Pairon · Sven-Oliver Dietz · Daniel Wagner · Alexander Hofmann

Received: 28 April 2014 / Accepted: 8 September 2014 / Published online: 17 October 2014
© The Japanese Orthopaedic Association 2014

Abstract Fragility fractures of the pelvic ring (FFP) are increasing in frequency and require challenging treatment. A new comprehensive classification considers both fracture morphology and degree of instability. The classification system also provides recommendations for type and invasiveness of treatment. In this article, a literature review of treatment alternatives is presented and compared with our own experiences. Whereas FFP Type I lesions can be treated conservatively, FFP Types III and IV require surgical treatment. For FFP Type II lessions, percutaneous fixation techniques should be considered after a trial of conservative treatment. FFP Type III lesions need open reduction and internal fixation, whereas FFP Type IV lesions require bilateral fixation. The respective advantages and limitations of dorsal (sacroiliac screw fixation, sacroplasty, bridging plate fixation, transsacral positioning bar placement, angular stable plate) and anterior (external fixation, angular stable plate fixation, retrograde transpubic screw fixation) pelvic fixations are described.

Introduction

With rising life expectancy, the number of elderly persons in developed communities increases. According to the World Factbook, life expectancy for those born in 2013 is 84.19 years for the Japanese and 80.32 years for the German population [1]. Diseases and injuries of the musculoskeletal system specific to the aging population will become even more frequent [2, 3]. Particularly in elderly females, osteoporosis represents a very common medical condition and a significant health care problem [4] with a growing incidence of osteoporotic fractures most typically occurring in the hip and spine. Clinical pathways characterized by multidisciplinarity have been recently reworked to cope with problems specific to these patients and to secure their best possible outcome [5]. A constantly-rising number of fragility pelvic fractures has also been reported [6]. Their clinical picture, radiological morphology and intrinsic instability range widely from nearly stable to completely unstable conditions. Although the number of case studies and publications on this topic in the current literature is incremental, there is no consensus about the optimal treatment strategy for these lesions. In this paper, we review literature data on the management of fragility pelvic fractures and compare them with our recommendations that are based on a previously published classification [7].

Materials and methods

We reviewed 245 patients with fragility fractures of the pelvic ring who received in-patient treatment in our department between 2007 and 2012 [7]. Included were only patients older than 65 years of age without any history of cancer. Patients with acetabular fractures were also excluded. The average age of the patients was 79.2 years. There were 198 females and 47 males, wherin the gender distribution was 4.2:1. Medical history revealed a low energy trauma in all patients. Sometimes the trauma event wasn't even remembered. Most patients had a fall on their side or backwards at home. In a few immobilized patients, even patient transfer from a bed to a chair was sufficient

P. M. Rommens (✉) · C. Ossendorf · P. Pairon · S.-O. Dietz · D. Wagner · A. Hofmann
Department of Orthopaedics and Traumatology, University Medical Center, Johannes Gutenberg-University, Langenbeckstrasse 1, 55131 Mainz, Germany
e-mail: pol.rommens@unimedizin-mainz.de

to cause a fragility fracture. At admission, the patients suffered from severe, immobilizing pain in the groin or at the pubic region. Some of these patients also suffered from deep pain in the lower back or in the sacral region. Other patients only suffered from isolated low dorsal pain and had no anterior complaints.

Diagnostic work-up

All patients received three conventional pelvic radiographs (Fig. 1a–c): an anteroposterior (ap); the pelvic inlet view; and the pelvic outlet view. On the ap view of the pelvis, fractures of the superior and inferior pubic rami or the pubic bone near the symphysis are often visible. In case of lateral impact, the fracture line at the superior pubic ramus runs horizontally and there is a slight overriding of the fracture fragments; the lateral fracture fragment is displaced medially. In case of an ap or posteroanterior impact, the fracture lines run vertically through the pubic bone or through the obturator foramen. There is no overriding, sometimes even a slight diastasis. The pelvic inlet view gives a good impression of the amount and direction of the fracture fragment displacement in the anterior pelvic ring. In this projection, the inner curve of the innominate bone and the anterior cortex of the sacrum are also well visible. Fractures or changes in the morphology of these lines can easily be detected. The pelvic outlet view, especially, gives information about the dorsal pelvis, the shape and symmetry of the sacrum, the neuroforamina and the sacroiliac joints. Assessment of the dorsal pelvic ring on conventional pelvic overviews is difficult in these patients because of disturbing bowel and bladder content. Further, interruptions within the bony structures of the dorsal pelvis are less clearly visible due to fragile bones with rarefaction of spongious and cortical structures. In case of an anterior pelvic fracture, we therefore recommend to always perform a computed tomography (CT)-scan of the whole pelvis. This precludes lesions of the dorsal pelvic ring being overlooked and the degree of instability consequently underestimated [8]. Multiplanar reconstructions of the CT data help us to fully appreciate the fracture configuration of the dorsal pelvis. In the coronal reconstructions, a complete fracture of the lateral mass of the sacrum is sometimes better visible than in transverse sections. A horizontal component of sacral fractures, if present, even with a slight angulation, can be recognized best in sagittal reconstructions.

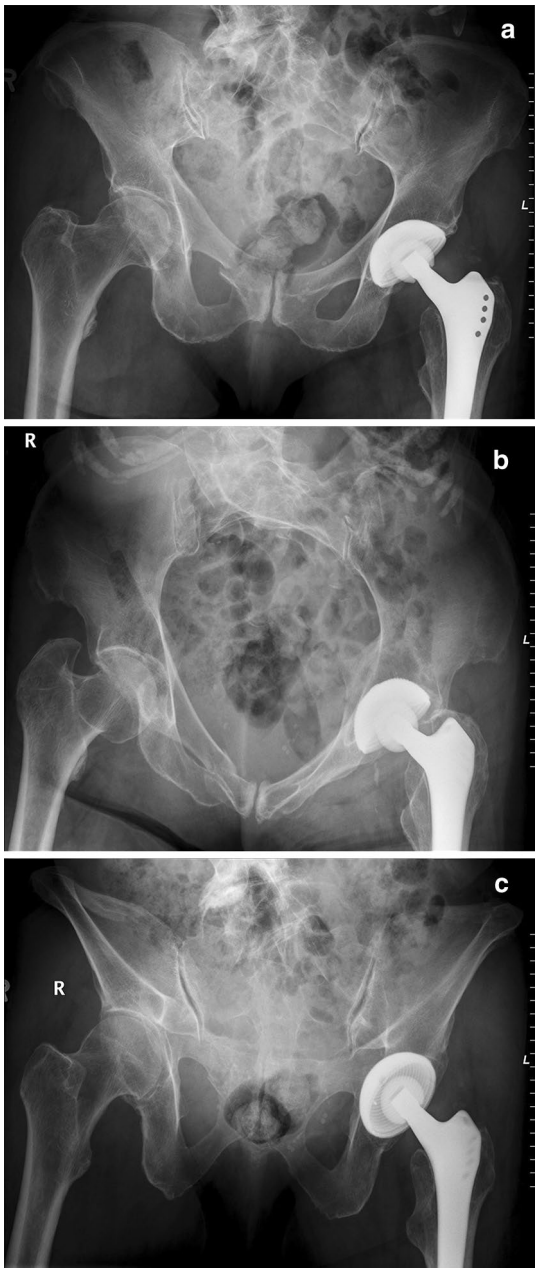

Fig. 1 **a** Pelvic ap overview of Type Ia FFP in an 82-year old woman. There is slight overriding of the fracture fragments at the right superior pubic ramus; **b** Pelvic inlet overview. A slight internal rotation of the right hemipelvis at the fracture of the right anterior pelvic ring is visible; **c** Pelvic outlet overview. The fracture of the right anterior pubic ramus is hardly visible. There is no lesion of the posterior pelvic ring

Comprehensive FFP classification

When analyzing the conventional radiographs and the CT-data of 245 patients, we detected a spectrum of different fracture morphologies. The fractures may involve the anterior pelvic ring only, the posterior pelvic ring only or a combination of both. Anteriorly, the fractures run through the superior and inferior pubic rami, the pubic bone in the proximity of the symphysis or more seldom there is a disruption of the symphysis itself. In the dorsal pelvis, the instability may run through the ilium, through the lateral mass of the sacrum or through the sacroiliac joint. A new,

comprehensive classification system was established, distinguishing the fracture morphology and degree of instability (Fig. 2a–k) [7]. The absolute number of these lesions in our series is presented in brackets ($n =$) after each fracture type.

FFP Type I lesions include anterior pelvic ring fractures only; FFP Type Ia is a unilateral anterior lesion and FFP Type Ib is a bilateral anterior lesion. Bilateral isolated anterior lesions were very rare in our series ($n = 1$); unilateral lesions are much more common ($n = 43$), but they were far from comprising the majority of all FFP (43/245 = 17.5%). This data supports the need for CT-evaluation of all low-energy pelvic ring lesions with pubic rami fractures; whenever an anterior pelvic ring lesion is present, there is a high risk of a concomitant posterior ring lesion often missed on conventional radiographs [8].

FFP Type II lesions are non-displaced posterior lesions; FFP Type IIa is a non-displaced posterior lesion only ($n = 3$); FFP Type IIb is a sacral crush with anterior disruption ($n = 59$); and FFP Type IIc is a non-displaced sacral, sacroiliac or iliac fracture with anterior disruption ($n = 65$). Together, FFP Type IIb and FFP Type IIc lesions formed half of all FFP lesions in our series (124/245 = 50.6%).

FFP Type III lesions are characterized by a displaced unilateral posterior injury combined with an anterior pelvic ring lesion. FFP Type IIIa involves a displaced unilateral ilium fracture ($n = 20$), FFP Type IIIb is a displaced unilateral sacroiliac disruption ($n = 4$) and FFP Type IIIc is a displaced unilateral sacral fracture ($n = 3$). Non-displaced unilateral posterior lesions (all FFP Types II, $n = 127$) were much more common in our series than displaced unilateral ones (all FFP Types III, $n = 27$), the FFP Type II versus FFP Type III ratio being 4.7:1.

FFP Type IV lesions are characterized by displaced bilateral posterior injuries. FFP Type IVa have bilateral iliac fractures or bilateral sacroiliac disruptions ($n = 2$). FFP Type IVb is characterized by a spinopelvic dissociation containing a bilateral vertical fracture through the lateral mass of the sacrum with a horizontal component connecting them ($n = 37$). FFP Type IVc is a combination of different posterior instabilities ($n = 8$). The frequency of spinopelvic dissociations in this series was striking, although not always visible on the conventional radiographs (37/245 = 15.1 %). This underlines the importance of two-dimensional CT-reconstructions; only in the sagittal reconstruction of the sacrum can the horizontal component of an H-type sacrum fracture be identified. Linstrom et al. [9] described typical anatomical patterns in insufficiency sacrum fractures and empasised that the H-type fracture

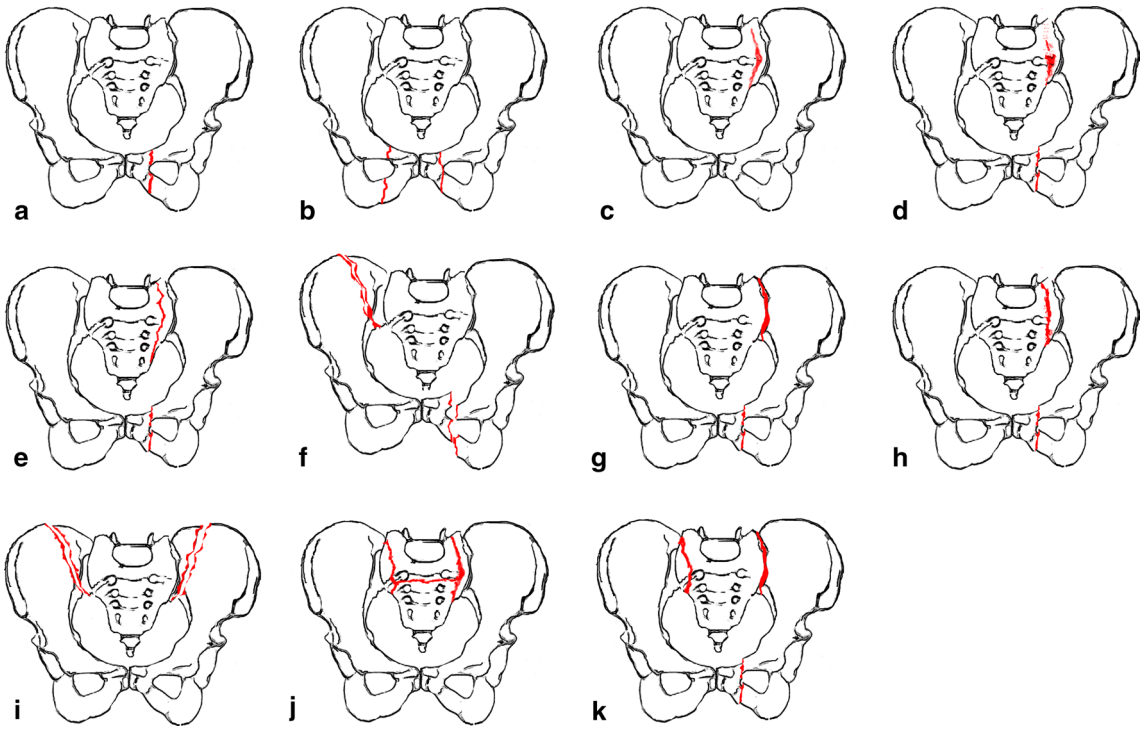

Fig. 2 Classification of fragility fractures of the pelvis. **a** FFP Type Ia: unilateral anterior pelvic ring disruption. **b** FFP Type Ib: bilateral anterior pelvic ring disruption. **c** FFP Type IIa: dorsal non-displaced posterior injury only. **d** FFP Type IIb: sacral crush with anterior disruption. **e** FFP Type IIc: non-displaced sacral, sacroiliac or iliac fracture with anterior disruption. **f** FFP Type IIIa: displaced unilateral ilium fracture and anterior disruption. **g** FFP Type IIIb: displaced unilateral sacroiliac disruption and anterior disruption. **h** FFP Type IIIc: displaced unilateral sacral fracture together with anterior disruption. **i** FFP Type IVa: bilateral iliac fractures or bilateral sacroiliac disruptions together with anterior disruption. **j** FFP Type IVb: spinopelvic dissociation with anterior disruption. **k** FFP Type IVc: combination of different posterior instabilities together with anterior disruption

pattern is not uncommon, with 61% of isolated sacral insufficiency fractures.

This comprehensive classification describes all different fracture morphologies and also categorizes the lesions into different degrees of instability. Isolated anterior lesions (FFP Type I) are more stable than non-displaced posterior lesions (FFP Type II). Displaced posterior lesions are less stable than non-displaced ones, and bilateral posterior lesions (FFP Type IV) are less stable than unilateral ones (FFP Type III).

Treatment options - clinical pathways

Depending on the clinical presentation of the patient at initial presentation and his or her fracture type, different treatment strategies will have to be chosen. All patients immediately require bed rest and painkillers. Depending on the healthcare system, diagnosis and treatment of anti-osteoporosis medication is started or continued. Studies have shown low rates of follow-up for osteoporosis diagnostics after fragility fractures [10]. The orthopedic trauma surgeon treating the pelvic fragility fracture plays an important role in initiating anti-osteoporotic management [11]. Diagnostic work-up on the state of bone metabolism should follow after fracture treatment. Management consists of life style changes, fall prevention, Vitamin D, calcium supplementation and antiresorptive drugs [12]. Biphosphonates are the drugs of choice. Promising results of enhanced fracture healing in FFP via administering the anabolic agent parathyroid hormone were published recently [13, 14]. The latter will not contribute to fracture healing in the acute setting, but they may avoid recurrent fragility fractures in the same or other skeletal regions.

In FFP Type I lesions, initial treatment is conservative. After a few days or a week of bed rest and with significant pain relief, careful mobilization is started [15]. Full-weight bearing as tolerated by the patient is allowed. However, forced mobilization must be avoided until radiographic evidence of fracture healing. We hypothesize that inadequate, premature and aggressive mobilization may lead to additional trauma of the weak bony structures with more complex and more unstable fracture types as a consequence [7]. Mobilization is done in the presence of physiotherapists. In the meantime, a high index of suspicion for the appearance of additional, secondary lesions must be present. In case pain intensity and pain frequency do not decrease, or even increase, after days or weeks, we recommended repeating the CT-scan evaluation in order to rule out fracture types of higher instability, or performing magnetic resonance imaging (MRI) to rule out occult sacral fractures [16]. The patient should be seen regularly on an outpatient basis until (radiographic) evidence of fracture healing and relief from complaints.

Fig. 3 Transverse CT cut through dorsal pelvis of 83-year old female. Zones of low bone density in both sacral alae and a fracture of the left sacral ala are visible

FFP Type II lesions are non-displaced injuries of the dorsal pelvic ring. Distinct fracture patterns of the sacrum were identified [9]. Here, a vertical fracture line is consistently a part of sacral insufficiency fractures. The fracture is situated in the lateral mass, lateral to the neuroforamina and medial to the sacroiliac joint. In an osteoporotic anatomical specimen, an “alar void” was shown in the lateral mass of the sacrum [17] (Fig. 3). Patients with FFP Type II lesions present with pain in the dorsal pelvis and also experience pain in the groin in cases of pubic rami fractures. Due to acute and intense pain, the patients can hardly be mobilized within the first days after admission. If no pain relief is observed within days with adequate pain medication and mobilization remains impossible, surgical stabilization of the dorsal fracture should be considered. In FFP Type II lesions, the bony structures are not displaced. Therefore, a percutaneous procedure for internal fixation is possible [18]. Alternatives for invasive treatment are sacroiliac screw osteosynthesis, sacroplasty, bridging plate osteosynthesis or insertion of a transsacral positioning bar.

Sacroiliac screw osteosynthesis is a well-known procedure in dorsal sacral instabilities after high-velocity trauma. Two large fragment screws are inserted into the body of S1 or one screw into the body of S1 and S2 each (Fig. 4a–f). This can be done with the patient either supine or in prone position. The elderly have a significantly lower bone mass density than adults. Consequently, there is a higher risk of screw loosening because of a lower pull-out force of these screws [19]. Cement augmentation of such screws may provide a higher pull-out force. However, there is little experience using these techniques and information regarding clinical outcome is limited. Adequate instruments and implants are scarcely available [20].

Sacroplasty has been recommended as an alternative treatment option for sacral insufficiency fractures in osteoporotic bone [21–23]. Here, a small portion of bone cement is injected into the fracture area through a long needle. The cement is distributed in the sacral ala adjacent to the

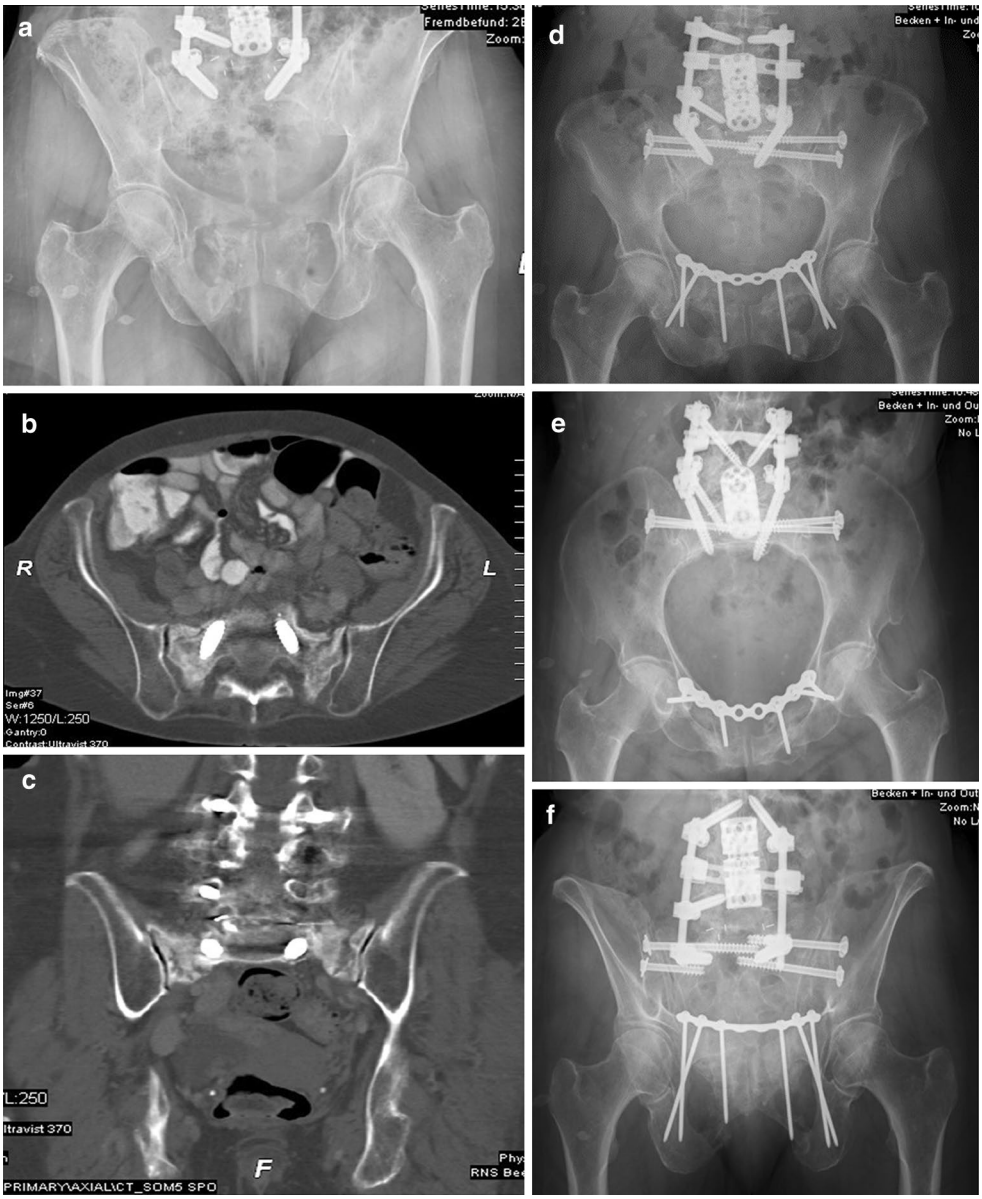

Fig. 4 **a** Pelvic ap overview of 72-year old female with anterior and posterior intervertebral fusion between L4 and S1. The patient had a history of more than three months of severe pain after a fall at home. A bilateral fracture of the pubic rami is visible with sclerotic margins, demonstrating a non-union. A fracture of the dorsal pelvic ring is not clear; **b** Axial CT reconstruction shows a bilateral fracture of the sacral ala at the S1 level; **c** Coronal reconstruction gives another view of the bilateral sacral ala lesions. This is an unstable lesion of the pelvic ring classified as FFP Type IVb; **d** Pelvic ap overview five months after operative reconstruction. Two sacroliliac screws have been inserted in the S1 body bilaterally. Insertion of a transsacral bar was not possible due to the pedicular screws in S1. The bilateral anterior instability was bridged with a long plate and screws construct; **e** Pelvic inlet overview; **f** Pelvic outlet overview. Note the long screws into the posterior column providing stability in this osteoporotic bone. The patient is free of complaints in the pelvic region and able to walk without crutches

fractured area. Similar to kyphoplasty, this technique provides quick pain relief and early mobilization is possible. Cement leakage is a described complication with possible neurological damage [24]. Biomechanically, there are important differences between vertebral kyphoplasty and sacroplasty. In osteoporotic vertebral fractures, the plane of the fracture is horizontal, whereas in sacral fragility fractures, it is vertical. In standing position, axial loading is perpendicular to the fracture plane of a vertebral fracture, but parallel to the plane of the sacral fracture. After sacroplasty, shearing forces will load the cement-augmented area. Due to cement interposition, the sacral fracture will never heal. Thus, on the longer term, these patients will be prone to treatment failure due to the high likelihood of fracture displacement. In cases

of recurrent fractures and consecutive revision surgery, internal fixation of the sacrum may become more demanding or even impossible. Therefore, the authors cannot recommend sacroplasty for the treatment of FFP.

For bridging plate osteosynthesis, the patient must be placed in the prone position. A pre-contoured long plate connects both dorsal iliac crests and is curved around the posterior inferior iliac spines. Several angular stable screws are inserted into the dorsal ilium through the plate holes on each side. The plate construct does not give absolute stability; it only bridges the fracture area, but does not realize any compression in the fracture side. We consider this technique of osteosynthesis less suitable for the stabilization of insufficiency fractures of the sacrum.

In contrast, placement of a transsacral positioning bar combines several advantages. Here, a solid bar with a diameter of 6 mm is placed horizontally in a coronal plane through the body of S1, alternatively through S2, from one ilium to the opposite. Washers and nuts are placed over the ends of the bar on each side. The procedure can be performed percutaneously. Implants are the same as in sacral bar osteosynthesis dorsally to the sacrum. It is obvious that this procedure requires thorough preoperative planning. The procedure bears the same risks as sacroiliac screw placement, such as perforation of the anterior cortex of the sacrum and damage to the cauda equine, nerve roots and vessels. The morphology of the sacrum is highly variable and, in some patients, there is no safe transsacral corridor through S1. In contrast, although smaller, the transsacral corridor in S2 seems to be constantly available [25]. The correct entry portal for the insertion of the bar is determined in a perfect lateral view of the sacrum at the level of S1 and S2. By tightening the nuts, a compressive force, which is perpendicular to the plane of the sacral fracture, is created. The amount of compression is not dependent

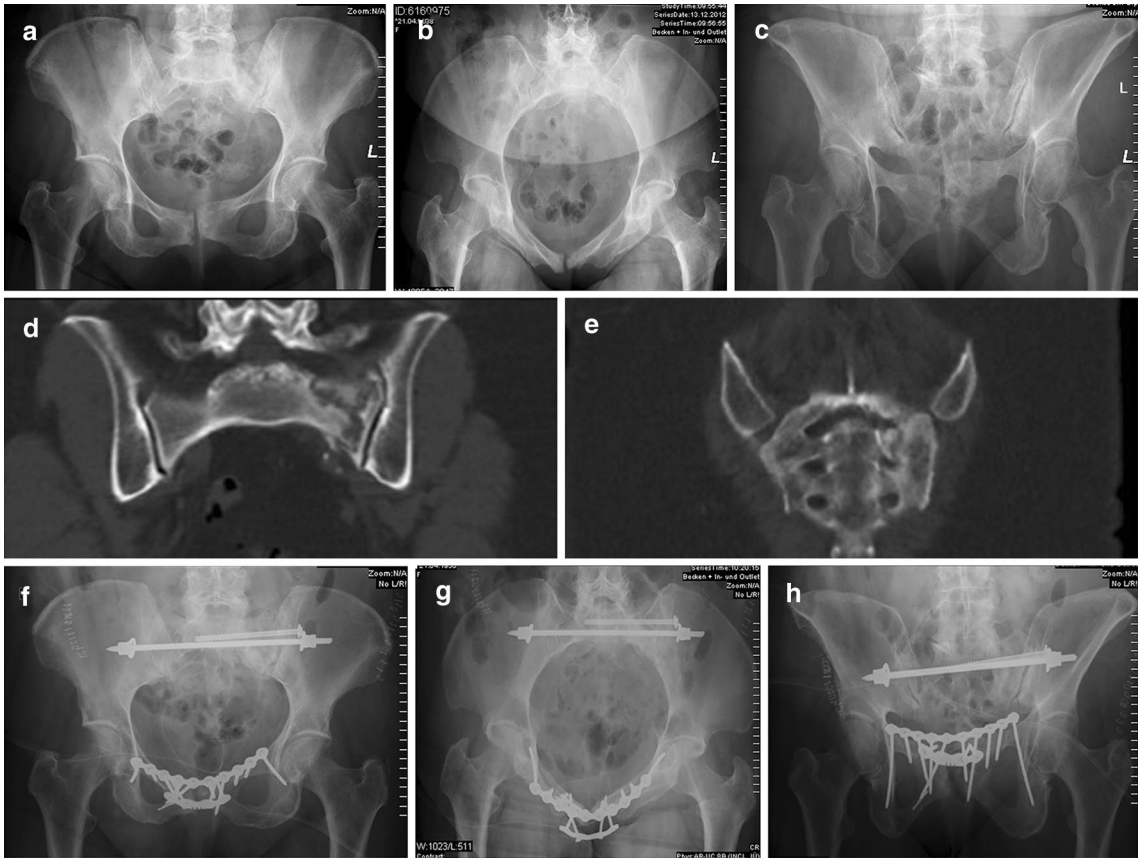

Fig. 5 Seventy-two-year old female with an FFP IIc lesion. **a** Pelvic ap overview. There are irregularities and a slight displacement at the symphysis pubis. A clear lesion of the dorsal pelvis is not visible; **b** Pelvic inlet view; **c** Pelvic outlet view. Instability of the symphysis pubis is visible as a step-off; **d** Coronal CT reconstruction of the dorsal pelvis. There is an undisplaced, yet complete, fracture of the left massa lateralis of the sacrum; **e** The fracture of the left lateral mass of the sacrum runs down through the neuroforamina S1 and S2; **f** Postoperative pelvic ap view. A sacral bar has been placed through the body of S1. On the left side, an additional sacroiliac screw has been placed. The instability of the symphysis pubis has been fixed with a double plate osteosynthesis and long screws into the posterior column, the anterior plate being angular stable; **g** Postoperative pelvic inlet view; **h** Postoperative pelvic outlet view. Three months after surgery, the patient was walking independently without complaints at the pelvis

on the strength of the spongious bone in the body of S1, as is the case in sacroiliac screw osteosynthesis, but on the strength of the cortical bone at the dorsal ilium. The cortical bone at the dorsal ilium of osteoporotic pelvis is sometimes very fragile. When the nut and washer threatens to perforate through the very weak dorsal ilium cortex while tightening, we replace the usual washer by a larger one (e.g., a small conventional plate). By using a larger washer, we distribute the contact pressure between the washer and the cortex over a larger surface. An additional S1 screw can be inserted at the unstable side to minimize rotational instability in the dorsal pelvis (Fig. 5a–h). A small series of 11 patients treated with this technique has been published with excellent to good results by Mehling et al. [26]. There was one case of reversible S1 nerve palsy. Loosening, pull-out or cut-out of the transsacral positioning bar was not observed in this case series.

Non-displaced superior pubic rami fractures are splinted in a retrograde manner with a large fragment screw inserted through a small skin incision from the pubic bone near to the symphysis (Fig. 6d–f). In case of a displaced superior pubic ramus fracture, reduction can be achieved through a small suprapubic midline incision prior to screw insertion. In case of symphysis pubis instability or a fracture very near to the joint, a bridging angular stable plate osteosynthesis has to be considered (Fig. 4a–h). In most patients with long history of pain in the pubic region, a very unstable condition with osteoporotic bone was found intraoperatively in our case series [7]. Therefore, a long bridging plate with long screws placed through the infra-acetabular corridor using the modified Stoppa-approach on both sides is preferred to achieve high stability of the construct (Figs. 4d–f, 5f–h, 7b–d).

In contrast to other authors, pelvic external fixation for anterior stabilization is not recommended in fragility

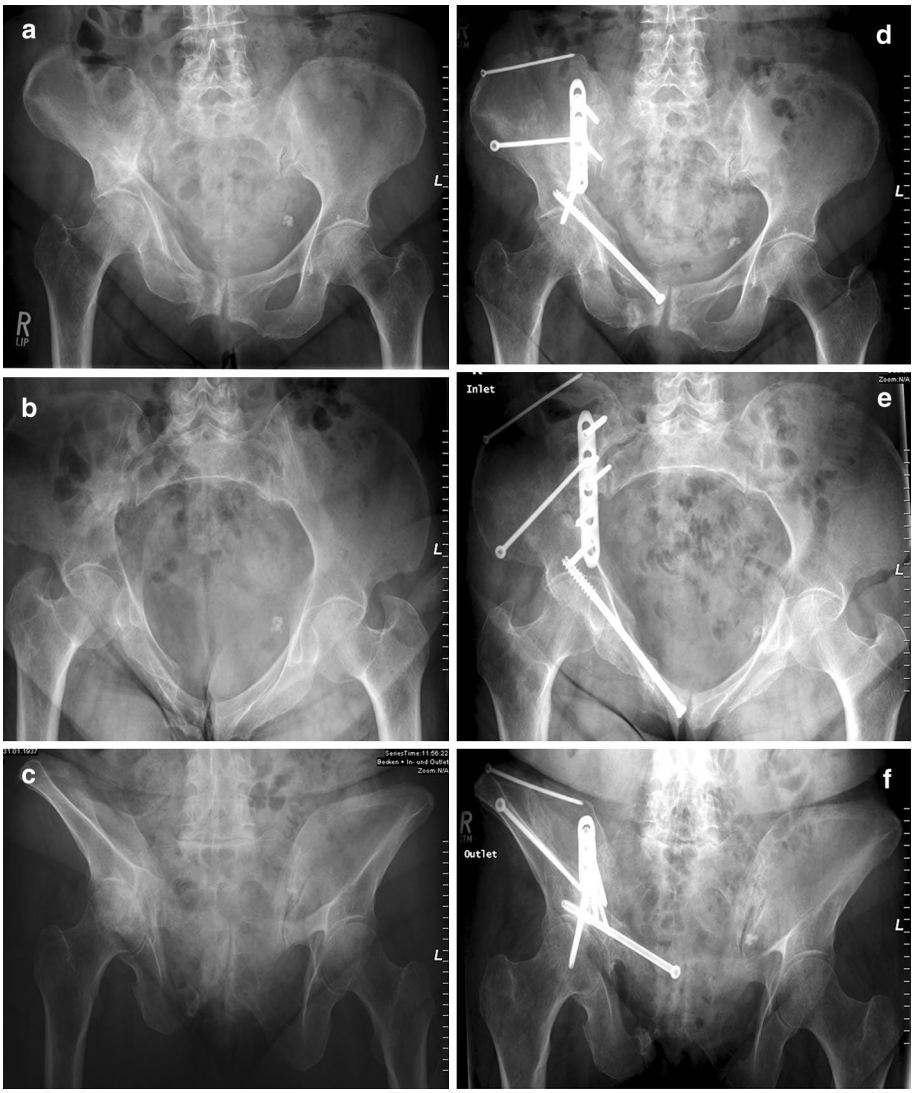

Fig. 6 **a** Seventy-four-year old female with an FFP Type IIIa lesion. A complete right-sided crescent fracture of the ilium and superior and inferior pubic ramus fractures with vertical displacement are visible in the pelvic a.p. view; **b** Pelvic inlet view; **c** Pelvic outlet view; **d** Postoperative pelvic a.p. view. The ilium fracture has been fixed with a large fragment angular stable plate and two long lag screws. The pubic ramus fracture has been splinted with a minimally invasive retrograde transpubic screw; **e** Postoperative pelvic inlet view; **f** Postoperative pelvic outlet view

fractures [27]. There is a high risk of loosening and pin track infection and, always critical, a lack of patient comfort. Internal fixators placed between both anterior superior or inferior iliac spines have been presented in recent literature. Although they can be inserted in a minimally invasive manner, there is a high risk of damage to the lateral cutaneous femoral nerve and occurrence of heterotopic ossification [28]. The implantation is in the proximity of the femoral vessels and nerve; furthermore, there is a little distance between the skin and screw head. Additionally, the implant must be removed in most cases, which involves a second operative procedure.

Displaced fragility fractures of the pelvic ring (FFP Types III and IV) necessitate a more aggressive surgical approach. As closed reduction is not possible, open reduction and internal fixation will be mandatory.

After open reduction of displaced sacral fractures or sacroiliac instabilities, similar techniques for stabilization can be used, as previously described, for the stabilization of non-displaced sacral fractures. In chronic cases, i.e., after failure of conservative treatment, gross instability is often combined with joint widening or bone loss. In those cases, we prefer performing a sacroiliac arthrodesis, as we estimate excessive risk of non-union in simple osteosynthesis. An anterior approach to the sacroiliac joint through the first window of the ilioinguinal approach is chosen. The joint is debrided and filled with cortico-spongious bone grafts of the ipsilateral iliac crest. Two short plates are inserted over the sacroiliac joint at an angle of 60°–90° to each other. One large fragment cancellous bone screw is inserted in the sacrum parallel to the joint and one or two screws are placed in the ilium. Sacroiliac screws or a transsacral positioning bar can be placed additionally to enhance stability.

In case of transiliac instabilities, the fracture runs from the inner curve of the ilium proximally and laterally. For stabilization, we prefer insertion of an angular stable plate placed parallel to the sacroiliac joint and the pelvic brim, bridging the medial edge of the fracture. As in other skeletal regions, angular stable plates have higher pull-out forces; therefore, there is a lower risk of loosening. The angular stable plate has to be pre-shaped and twisted to fit on the innominate bone as best as possible. The proximal screws should be directed parallel to the sacroiliac joint, the distal screws in the sagittal plane or slightly towards lateral (Fig. 6a–f). The ilium fracture running proximally and laterally ends at the iliac crest and is stabilized there with one long screw, which is inserted perpendicular to the fracture plane and between the inner and outer cortex of the

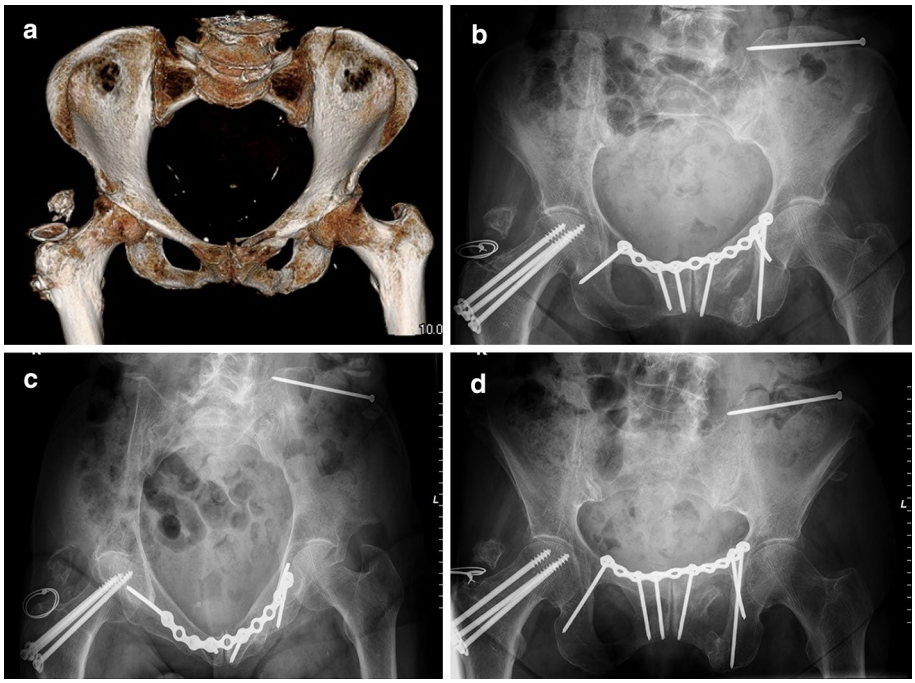

Fig. 7 **a** Surface rendering of the pelvic bone in an 87-year old female after a fall at home. An incomplete fracture of the dorsal ilium, a displaced fracture of the superior pubis ramus and an undisplaced inferior pubic ramus fracture are visible. The very low bone density in both sacral ala and in the center of the iliac wing are clearly visible. The lesion is classified as an FFP Type IIc; **b** Postoperative pelvic a.p. overview. The incomplete ilium fracture has been fixed with a single screw, the anterior instability with a bridging plate and screw osteosynthesis. To avoid loosening of the screws, an we chose the longest possible screw trajectory in the pubic bone and ischium; **c** Postoperative pelvic inlet overview; **d** Postoperative pelvic outlet overview. Six months after surgery, the patient walked independently and without complaints

crest (Fig. 7a–d). As an alternative, a small fragment plate is placed over the iliac crest.

In FFP Type IV fractures, there is bilateral dorsal instability with displacement. In bilateral fractures of the ilium, bilateral angular stable plate osteosynthesis is done in the same technique as in unilateral transiliac instabilities. In minimally-displaced bilateral fractures of the lateral mass of the sacrum, a transsacral positioning bar is inserted. The bilateral sacral fractures are compressed when the washers and nuts on both ends of the bar are pressed against the

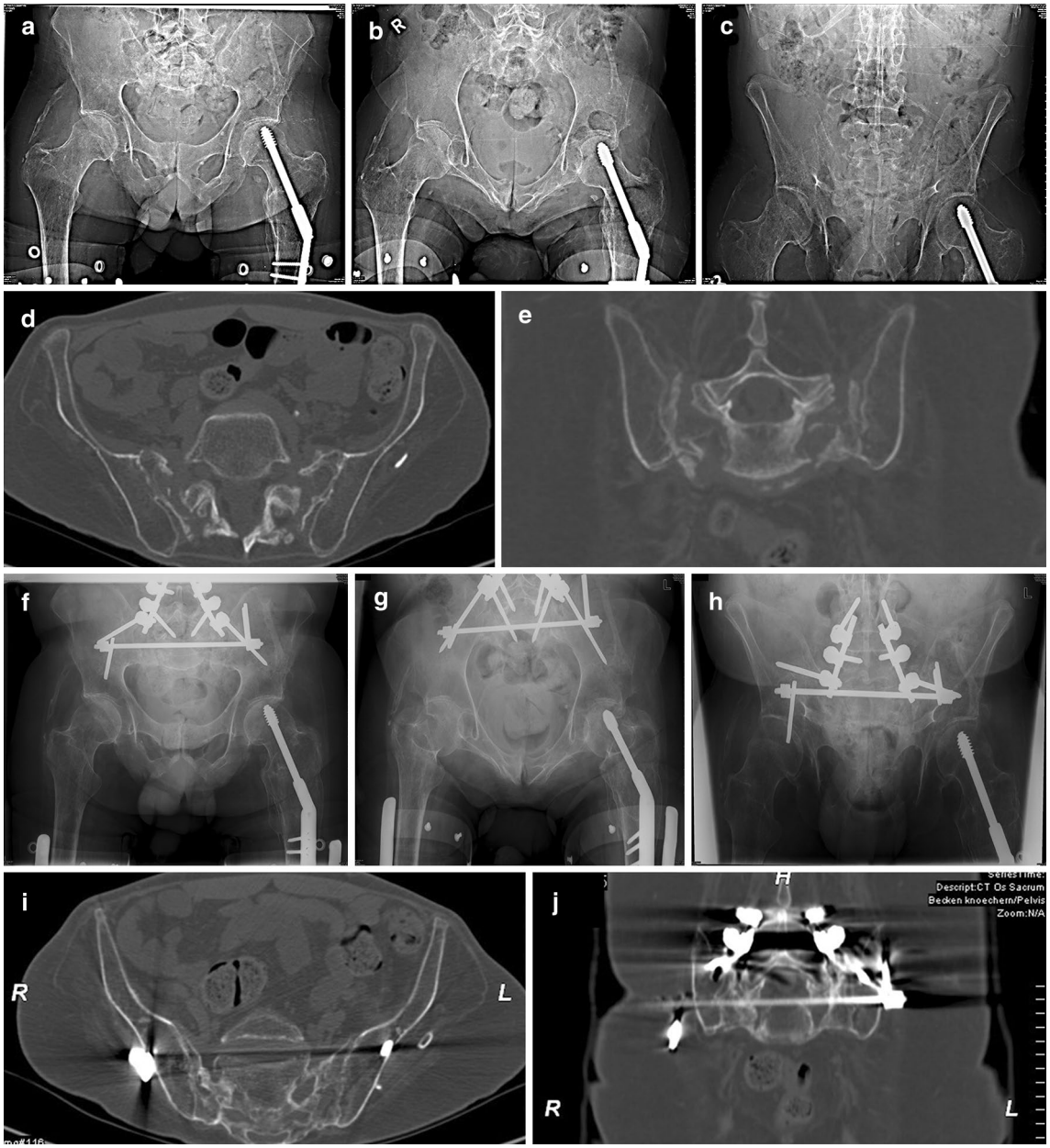

Fig. 8 **a** Pelvic a.p. overview of a 55-year old patient who became paraplegic at the age of 27. There is a rarefication of bone substance in the pelvic bone and lower extremities. The dorsal pelvis is difficult to appreciate; **b** Pelvic inlet overview. The sacrum seems intruded into the pelvic ring; **c** Pelvic outlet overview. The lumbosacral segment seems displaced distally when related to the pelvic ring; **d** Axial CT-reconstruction of the dorsal pelvis showing a severe rarefication of the bone substance and a complete bilateral fragility fracture of the lateral mass of the sacrum; **e** Coronal CT-reconstruction confirms the complete bilateral fragility fractures of the lateral mass of the sacrum; **f** Postoperative pelvic a.p. overview. An iliolumbar fusion between L4, L5 and the dorsal ilium was done. Additionally, a transsacral positioning bar was placed through the body of S1. Small plates were used as washers under the nuts of the sacral bar to hinder cut-through of the washers; **g** Postoperative pelvic inlet view; **h** Postoperative pelvic outlet view; **i** A representative axial CT-cut one year after surgery, showing complete healing of the sacral fragility fractures; **j** A representative coronal CT-cut showing the position of the transpedicular screws and the transsacral positioning bar. The healing of the sacrum is visible. The patient is able to stand with auxiliary means

lateral cortex of the dorsal ilium. For absolute rotational stability, we prefer placing an additional sacroiliac screw on both sides. This can only be done in cases where a transsacral corridor large enough for additional screw placement is available (Fig. 5f–h). Bilateral sacroiliac screws as the only measure of stabilization are not reliable, as there is a high risk of loosening due to poor bone stock. Iliolumbar fixation, which involves a much more prolonged surgery with bridging of the lumbosacral junction, is preserved for cases with gross instability or for patients in which a safe transsacral corridor is not available. Transpedicular screws are placed bilaterally in the L4 and L5 pedicles and in the dorsal ilium. The screw in the ilium is inserted between the two cortices in the direction of the greater sciatic notch. It can measure up to 70 mm of length. The pedicle screws are connected with a bar on each side and the two bars are connected with a transverse connector. Iliolumbar fixation prevents further intrusion of the lumbosacral segment into the pelvic ring. In very unstable situations, a combination of iliolumbar fusion and transsacral positioning bar is inserted (Fig. 8a–j) [29–31].

Aftercare

Patients receiving conservative treatment should be mobilized and bear weight, as tolerated. Physiotherapy should be adapted to the functional status of the patient before the fragility fracture occurred and certainly not enforced. Too aggressive mobilization may lead to additional fragility fractures in the pelvic ring with enhanced instability [10]. Patients undergoing operative treatment should have relative bed rest for six weeks. Short transfers and sitting in a wheelchair can be allowed, but long standing and walking with full weight bearing is not recommended. Due to low bone strength, there is a risk of loosening of the implants with delayed healing, non-union and revision surgery. Usually, after six weeks, conventional radiographs will confirm ongoing bone healing without implant migration. Then, weight bearing can be allowed as tolerated. A walking frame, a walker or crutches may be used temporarily. Full weight bearing without walking aids should be possible after three months. Further active physiotherapy will ameliorate the general condition and independency of the patient [32].

Conclusion

Fragility fractures of the pelvic ring have become a new entity within the spectrum of insufficiency fractures resulting from osteoporosis. We experience a rapidly growing ratio of these lesions in our total population of patients, with the need of in-patient treatment for pelvic injuries. There must be a high index of suspicion for dorsal lesions when patients present with a fracture of the anterior pelvic ring and further diagnostics with a CT scan should be carried out to appreciate the full dimension of the instability. A literature review of management alternatives has been given and compared with our own experience at treating 245 patients. The type of treatment is based on the localization and severity of instability, which is reflected in a new classification system. FFP Type I can be treated conservatively with painkillers and mobilization as tolerated. FFP Type II is often stabilized with a percutaneous procedure, whereas FFPs Types III and IV are usually stabilized with an open procedure. Sacroliliac screw osteosynthesis, bridging plate osteosynthesis, transsacral positioning bar and angle stable plating are valid alternatives. In FFP Type IV lesions, bilateral stabilization or iliolumbar fixation are recommended. Further clinical and biomechanical work is needed to shed light on the optimal treatment of these pelvic lesions.

Acknowledgments The authors declare that they do not have any conflict of interest.

References

1. World factbook: https://www.cia.gov/library/publications/the-world-factbook/rankorder/2102rank.html.
2. Dhanwal DK, Dennison EM, Harvey NC, Cooper C. Epidemiology of hip fracture: worldwide geographic variation. Indian J Orthop. 2011;45(1):15–22.
3. Watts NB. The Fracture Risk Assessment Tool (FRAX®): applications in clinical practice. J Womens Health (Larchmt). 2011;20(4):525–31.
4. Johnell O, Kanis JA. An estimate of the worldwide prevalence and disability associated with osteoporotic fractures. Osteoporos Int. 2006;17(12):1726–33.
5. Kates SL, Bukata SV, DiGiovanni BF, Friedman SM, Hoyen H, Kates A, Kates SL, Mears SC, Mendelson DA, Serna FH, Jr., Sieber FE and Tyler WK. A guide to improving the care of patients with fragility fractures. Geriatric orthopaedic surgery and rehabilitation 2011; 2: 5-37. http://gos.sagepub.com/content/2/1/5.
6. Dodge G, Brison R. Low-impact pelvic fractures in the emergency department. CJEM. 2010;12(6):509–13.
7. Rommens PM, Hofmann A. Comprehensive classification of fragility fractures of the pelvic ring. Recommendations for surgical treatment. Injury. 2013;44(12):1733–44.
8. Lau TW, Leung F. Occult posterior pelvic ring fractures in elderly patients with osteoporotic pubic rami fractures. J Orthop Surg (Hong Kong). 2010;18(2):153–7.
9. Linstrom NJ, Heiserman JE, Kortman KE, Crawford NR, Baek S, Anderson RL, Pitt AM, Karis JP, Ross JS, Lekovic GP, Dean BL. Anatomical and biomechanical analyses of the unique and consistent locations of sacral insufficiency fractures. Spine (Phila Pa 1976). 2009;34(4):309–15.
10. Freedman KB, Kaplan FS, Bilker WB, Strom BL, Lowe RA. Treatment of osteoporosis: are physicians missing an opportunity? J Bone Joint Surg Am. 2000;82(A(8)):1063–70.
11. Dell R, Greene D, Schelkun SR, Williams K. Osteoporosis disease management: the role of the orthopaedic surgeon. J Bone Joint Surg Am. 2008;90(Suppl 4):188–94.
12. Dell RM, Greene D, Anderson D, Williams K. Osteoporosis disease management: what every orthopaedic surgeon should know. J Bone Joint Surg Am. 2009;91(Suppl 6):79–86.

13. Bukata SV. Systemic administration of pharmacological agents and bone repair: what can we expect. Injury. 2011;42(6):605–8.
14. Wu CC, Wei JC, Hsieh CP, Yu CT. Enhanced healing of sacral and pubic insufficiency fractures by teriparatide. J Rheumatol. 2012;39(6):1306–7.
15. Rommens PM, Wagner D, Hofmann A. Surgical management of osteoporotic pelvic fractures: a new challenge. Eur J Trauma Emerg Surg. 2012;38(5):499–509.
16. Babayev M, Lachmann E, Nagler W. The controversy surrounding sacral insufficiency fractures: to ambulate or not to ambulate? Am J Phys Med Rehabil. 2000;79(4):404–9.
17. Peretz AM, Hipp JA, Heggeness MH. The internal bony architecture of the sacrum. Spine (Phila Pa 1976). 1998;23(9):971–4.
18. Rommens PM. Is there a role for percutaneous pelvic and acetabular reconstruction? Injury. 2007;38(4):463–77.
19. Mears SC, Sutter EG, Wall SJ, Rose DM, Belkoff SM. Biomechanical comparison of three methods of sacral fracture fixation in osteoporotic bone. Spine (Phila Pa 1976). 2010;35(10):E392–5.
20. Wähnert D, Raschke MJ, Fuchs T. Cement augmentation of the navigated iliosacral screw in the treatment of insufficiency fractures of the sacrum. A new method using modified implants. Int Orthop. 2013;37:1147–50.
21. Pommersheim W, Huang-Hellinger F, Baker M, Morris P. Sacroplasty: a treatment for sacral insufficiency fractures. Am J Neuroradiol. 2003;24:1003–7.
22. Frey ME, DePalma MJ, Cifu DX, Bhagia SM, Carne W, Daitch JS. Percutaneous sacroplasty for osteoporotic sacral insufficiency fractures: a prospective, multicenter, observational pilot study. Spine J. 2008;8(2):367–73.
23. Bayley E, Srinivas S, Boszczyk BM. Clincal outcomes of sacroplasty in sacral insufficiency fractures: a review of the literature. Eur Spine J. 2009;18(9):1266–71.
24. Bastian JD, Keel MJ, Heini PF, Seidel U, Benneker LM. Complications related to cement leakage in sacroplasty. Acta Orthop Belg. 2012;78(1):100–5.
25. Wagner D, Kamer L, Rommens PM, Sawaguchi T, Richards RG, Noser H. 3D statistical modeling techniques to investigate the anatomy of the sacrum, its bone mass distribution, and the trans-sacral corridors. J Orthop Res. 2014;32(11):1543–8.
26. Mehling I, Hessmann MH, Rommens PM. Stabilisation of fatigue fractures of the dorsal pelvis with a trans-sacral bar. Operative technique and outcome. Injury. 2012;43(4):446–51.
27. Culemann U, Scola A, Tosonoudis G, Pohlemann T, Gebhard F. Concept for treatment of pelvic ring injuries in elderly patients. A challenge. Unfallchirurg. 2010;113(4):258–71.
28. Vaidya R, Kubiak EN, Bergin PF, Dombroski DG, Critchlow RJ, Sethi A, Starr AJ. Complications of anterior subcutaneous internal fixation for unstable pelvis fractures: a multicenter study. Clin Orthop Relat Res. 2012;470(8):2124–31.
29. Moshirfar A, Rand FF, Sponseller PD, Parazin SJ, Khanna AJ, Kebaish KM, Stinson JT, Riley LH. Pelvic fixation in spine surgery. Historical overview, indications, biomechanical relevance, and current techniques. J Bone Joint Surg Am. 2005;87(Suppl 2):89–106.
30. Acharya NK, Bijukachhe B, Kumar RJ, Menon VK. Iliolumbar fixation—the Amrita technique. J Spinal Disord Tech. 2008;21(7):493–9.
31. Keel MJ, Benneker LM, Siebenrock KA, Bastian JD. Less invasive lumbopelvic stabilization of posterior pelvic ring instability: technique and preliminary results. J Trauma. 2011;71(3):E62–70.
32. Leslie MP, Baumgaertner MR. Osteoporotic pelvic ring injuries. Orthop Clin North Am. 2013;44(2):217–24.