

Peritumoral overexpression of ZBP-89 is associated with unfavorable disease-free survival rates in patients with hepatocellular carcinoma following hepatectomy

QIU-SHUANG WANG^{1*}, CHEN CHEN^{1*}, JING ZHAN², XIE-FAN FANG³, GEORGE G. CHEN⁴, SHENG-LI YANG¹, REN-WANG CHEN¹, FAN TONG¹ and JIAN-LI HU¹

¹Cancer Center, Union Hospital; ²Department of Gastroenterology and Hepatology, Union Hospital, Tongji Medical College, Huazhong University of Science and Technology, Wuhan, Hubei 430022, P.R. China; ³Department of Pediatrics, College of Medicine, University of Florida, Gainesville, FL 32610, USA; ⁴Department of Surgery, The Chinese University of Hong Kong, Prince of Wales Hospital, Shatin, New Territories, Hong Kong, SAR, P.R. China

Received August 29, 2017; Accepted February 9, 2018

DOI: 10.3892/ol.2018.8353

Abstract. Previous studies have revealed that the peritumoral environment has a profound influence on tumor initiation and progression. Zinc-binding protein-89 (ZBP-89) has been observed to be involved with tumor development, recurrence, and metastasis. High intratumoral expression of ZBP-89 has been associated with improved prognosis in several tumor types. However, the prognostic values of peritumoral expression of ZBP-89 remain to be elucidated in patients with hepatocellular carcinoma (HCC) following curative resection. In the present study, peritumoral ZBP-89 expression was examined using immunohistochemistry in 102 HCC patients who had received curative hepatectomy. Expression of ZBP-89 protein was positive in 66.3% of the peritumoral samples from 102 HCC patients. HCC patients with high peritumoral ZBP-89 expression exhibited significantly shorter disease-free survival (DFS) times ($P=0.012$) than those patients with low peritumoral ZBP-89 expression. Additionally, high ZBP-89 expression in peritumoral HCC tissue was positively associated with the presence of liver cirrhosis. Univariate and multivariate Cox proportional hazard regression analyses demonstrated that albumin levels ≤ 35 g/l, multiple tumors, tumor sizes ≥ 5 cm, and macroscopic vascular invasion may serve as independent prognostic factors for overall survival (OS) [hazard ratio (HR)=2.031; $P=0.014$] in patients with HCC. The multivariate Cox regression model identified that

high ZBP-89 expression, multiple tumors and macroscopic vascular invasion were independent prognostic factors for shorter DFS durations. High expression of ZBP-89 in peritumoral HCC tissues was associated with a shorter DFS in HCC patients following curative hepatectomy. Additionally, high ZBP-89 expression in peritumoral HCC tissue was positively associated with the presence of liver cirrhosis in HCC patients, indicating that cirrhosis accompanied by high ZBP-89 expression may be a contributing factor to the poor prognosis of patients with HCC. Therefore, peritumoral ZBP-89 expression may be a good prognostic marker to predict DFS time in HCC patients following curative hepatectomy and may provide novel insights into the molecular mechanisms of HCC initiation.

Introduction

Hepatocellular carcinoma (HCC) is a common cancer with poor prognosis in Chinese patients. In 2011, there were a reported ~355,595 new cases and ~322,416 incidences of mortality owing to liver cancer in China; the incidence and mortality rates of liver cancer were 26.39/100,000 and 23.93/100,000, respectively (1). Among all cancer types, deaths from liver cancer are increasing at the highest rate, with liver cancer incidence rates increasing rapidly in the United States (2). The burden of liver cancer is growing worldwide (2). Despite the substantial progress in surgical, interventional and targeted treatments, the long-term survival rates of patients with HCC remain bleak owing to postoperative recurrence and metastasis. The recurrence and metastasis of HCC are mainly intrahepatic following radical hepatectomy, which supports the theory that the peritumoral microenvironment may provide a suitable environment for colonization and proliferation of subclinical metastatic tumor cells (3,4). Removal of the primary tumor does not alter the peritumoral microenvironment, which remains suitable for HCC initiation and progression (3). Furthermore, the HCC tumor biomarkers currently under intensive investigation are primarily derived from cancerous tissues to predict early recurrence and prognosis (5). By contrast, previous studies have demonstrated that patients with HCC exhibit a

Correspondence to: Professor Jian-Li Hu, Cancer Center, Union Hospital, Tongji Medical College, Huazhong University of Science and Technology, 1277 JieFang Avenue, Wuhan, Hubei 430022, P.R. China
E-mail: jl5199@126.com

*Contributed equally

Key words: hepatocellular carcinoma, ZBP-89, peritumoral, prognosis

large degree of spatial and temporal genomic heterogeneity and that the extent of intratumor heterogeneity varies considerably among these patients (6-8). One tumor lesion may contain intratumor subregions with distinct genomes (8), and therefore the postoperative recurrence of disease may not share the same invasion characteristics as the primary HCC lesions (8). Therefore, biomarkers extracted from only one cancerous region may not represent the various HCC genomes owing to the substantial heterogeneity and subclonal diversity. This makes it critical to identify novel biomarkers, particularly those from peritumoral liver tissues, which may contribute to the prediction of HCC recurrence.

Zinc-binding protein-89 (ZBP-89), a ubiquitously expressed Krüppel-type zinc-finger transcription factor, binds to GC-rich DNA sequences and is involved in a number of cellular functions, including cellular proliferation, differentiation, and apoptosis (9). It has been reported that ZBP-89 possesses the properties of a transactivator and a tumor suppressor owing to its bifunctional regulatory domains (8). ZBP-89 is capable of transcriptionally activating the expression of a battery of genes, including BCL2 antagonist/killer 1, p21^{waf1}, matrix metalloproteinases, human programmed cell death protein 4, and proto-oncogene β -catenin (CTNNB1) (9-14). However, ZBP-89 acts as a suppressor for other genes, including gastrin, vimentin, p16, and ornithine decarboxylase promoter (15-19). The ZBP-89 protein is involved in several human cancer types, including HCC (20), gastric cancer (21), esophageal squamous cell cancer (22), colorectal cancer (CRC) (23), clear-cell renal cell carcinoma (24), and pancreatic cancer (25). However, the expression of ZBP-89 in cancerous tissues has been inconsistently associated with prognosis in patients with different tumor types. For instance, HCC patients with high ZBP-89 expression in intratumoral tissues exhibited superior survival rates to those with low ZBP-89 expression. On the contrary, high expression of intratumoral ZBP-89 is associated with decreased survival rates in patients with esophageal squamous cell cancer and clear-cell renal cell carcinoma (22,24). To the best of our knowledge, little research has investigated whether the expression of ZBP-89 in peritumoral liver tissues is associated with improved patient prognosis.

The present study investigated the expression of peritumoral ZBP-89 in 102 HCC patients who had received curative hepatectomy by immunohistochemistry. The aim of the present study was to reveal the possible association between peritumoral ZBP-89 expression and HCC patient survival, including disease-free survival (DFS) and overall survival (OS) rates.

Materials and methods

Patients and their clinicopathological data. In total, 93 men and 9 women, aged 31-81 years (median, 58.0 years), were involved in the present study. Archived, formalin-fixed, paraffin-embedded peritumoral liver tissue specimens were obtained from 102 patients with pathologically proven HCC and underwent curative resection between November 1995 and May 2017 at the Prince of Wales Hospital (Hong Kong, China). All patients involved in the present study were hepatitis B virus (HBV)-associated HCC patients. The study was performed in strict accordance with the Reporting Recommendations

for Tumor Marker Prognostic Studies (REMARK) and the Transparent Reporting of a Multivariable Prediction Model for Individual Prognosis or Diagnosis (TRIPOD) Statement (26,27). Informed written consent was obtained from all patients involved in the present study. Curative resection was defined as the complete removal of cancer tissue, with tumor-negative resection margins. The resection edge was at least 2 cm from the tumor margin. Tumor differentiation was graded by the Edmondson grading system (28). Patients had no signs of distant metastasis and did not receive any anticancer therapy prior to surgery. Following curative resection, all liver specimens were histologically evaluated by two independent pathologists blinded to all patient-associated information. Biochemical markers, including α -fetoprotein (AFP), albumin, alanine aminotransferase (ALT), and bilirubin, were acquired from the patients' medical records. All detailed clinicopathological features are listed in Table I. The present study was approved by the Joint Chinese University of Hong Kong-New Territories East Cluster Clinical Research Ethics Committee (Hong Kong, China).

Patient follow-up. All patients were followed up until May 2017, with a median observation time of 179 months. Patients were followed up by clinic visits every 3 months in the first year after surgery, every 4 months during the second year after surgery, and every 6 months thereafter. A contrast-enhanced abdomen computed tomography or magnetic resonance imaging scan was performed at least every three months during the postoperative follow-up. Mortality information of patients was obtained from the social security death index, medical records, or notifications from the family of the deceased.

Immunohistochemistry and western blot analysis. The expression of ZBP-89 was assessed in peritumoral hepatocytes, which are defined as liver tissues at least 2 cm from the tumor margin. The adjacent non-cancerous tissues were continuously sectioned into paraffin slices, and one slide/patient was processed for IHC staining and counted. Immunohistochemistry, western blot analysis and scoring was performed according to previously described protocols (20). On each slide, 1,000 cells were randomly selected, counted, and scored. Negative controls were prepared using PBS instead of the primary antibody. All the primary antibodies for ZBP-89 (sc-48811 X) were diluted at 1:200, were purchased from Santa Cruz Biotechnology (Santa Cruz Biotechnology, Inc., Dallas, TX, USA). The extent of IHC staining was defined as: (+), <10% of peritumor cells were positive; (++) , 10-50% of peritumor cells were positive; (+++), >50% of peritumoral cells were positive; (-), negative staining. Negative and (+) positive staining were defined as low expression, whereas (++) and (+++) positive staining were defined as high expression. All sections were observed by light microscopy (magnification, x200), and scoring was performed separately by two independent pathologists. The METAVIR scoring system was used for liver fibrosis scoring (29). F0=no fibrosis, F1=portal fibrosis without septa, F2=portal fibrosis with few septa, F3=numerous septa without cirrhosis, F4=cirrhosis. All patients involved in our present study were divided into three groups, F0-1, F1-2, and F3-4.

Table I. Demographic, biochemical and clinical characteristics of the 102 HCC patients.

Variable	Value
Age, years	58 (31-81)
Sex, male/female	93/9
Albumin, g/l	41 (26-49)
ALT, U/l	48 (11-283)
Total bilirubin, g/l	9 (3-83)
HCC diameter, cm	4 (0.7-15)
AFP, ng/ml	91 (1-625,000)

Data are presented as median value (range). ALT, alanine aminotransferase; AFP, α -fetoprotein; HCC, hepatocellular carcinoma.

Hematoxylin and eosin (H&E) staining. Routine H&E staining was conducted on paraffin slices of peritumoral liver tissue according to the previous H&E staining protocol (30). Paraffin slices would undergo the subsequent procedures at room temperature: Deparaffinisation using: Xylene I for 5 min and Xylene II for 5 min; followed by rehydration in a descending alcohol series of 90% alcohol for 5 min and 70% alcohol for 5 min. Samples were then washed with distilled water for 10 min. Nuclear Staining was conducted with Harris' haematoxylin solution for 8 min and following washing with distilled water for 2 min; cytoplasmic Staining with 1% eosin 1 min was conducted.

Statistical analysis. All statistical analyses were performed using the software SPSS version 19.0 (IBM Corp., Armonk, NY, USA). The association between ZBP-89 expression and clinicopathological variables was assessed by applying Pearson's χ^2 test. DFS was defined as the interval between the date of surgery and recurrence, whereas OS was defined as the dates of surgery and mortality. OS and DFS were assessed using the Kaplan-Meier method and compared using the log-rank test in the 102 HCC patients. Univariate Cox-regression model was performed against all the clinicopathological features as covariates. Multivariate Cox proportional hazards analysis was performed on the significant factors determined by univariate analysis. $P < 0.05$ was considered to indicate a statistically significant difference.

Results

Expression of ZBP-89 in HCC peritumoral tissues by immunohistochemistry and western blot analysis. The clinicopathological characteristics of the 102 patients are presented in Table I. IHC staining revealed that positive staining of ZBP-89 protein was mainly observed in the cytoplasm of peritumoral hepatocytes (Fig. 1). Negative peritumoral cytoplasmic/nuclei staining for ZBP-89 (Fig. 1A). High peritumoral cytoplasmic and nuclear staining for ZBP-89 (Fig. 1B). High peritumoral cytoplasmic staining for ZBP-89 (Fig. 1C). High peritumoral nuclear staining for ZBP-89 (Fig. 1D). The expression of ZBP-89 protein was categorized into low- and high-ZBP-89 expression samples. To confirm the results of IHC, western

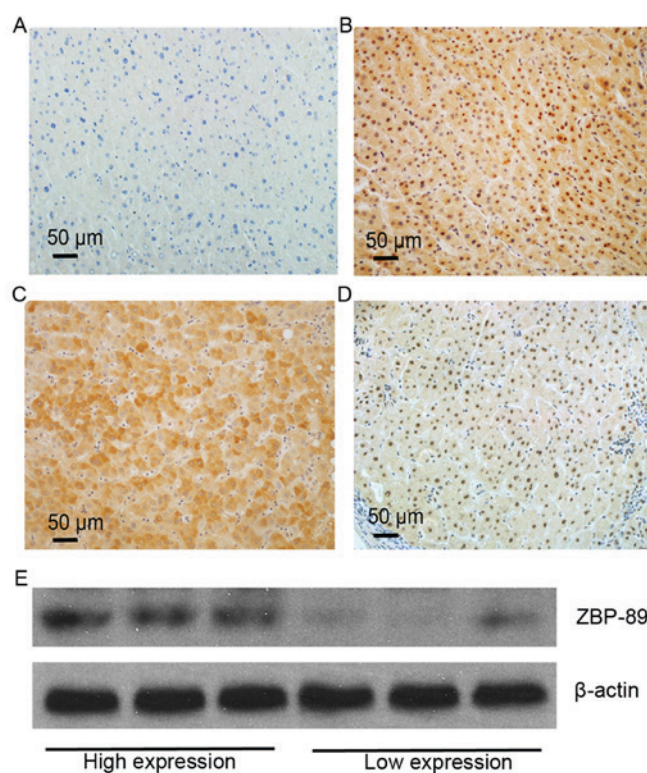


Figure 1. Immunohistochemical analysis of ZBP-89 in peritumoral liver tissues. (A) Negative peritumoral cytoplasmic/nuclei staining for ZBP-89. (B) High peritumoral cytoplasmic and nuclear staining for ZBP-89. (C) High peritumoral cytoplasmic staining for ZBP-89. (D) High peritumoral nuclear staining for ZBP-89. (E) Protein levels of ZBP-89 in six HCC peritumoral tissues, three of which exhibit high expression of ZBP-89 by IHC and three exhibiting low expression. ZBP-89, zinc-binding protein-89.

blotting was used to detect the protein levels of ZBP-89 in 6 HCC peritumoral tissues, 3 of which were assessed as exhibiting high expression of ZBP-89 by IHC and 3 were low expression (Fig. 1E). High ZBP-89 expression (++ and +++) was detected in 65.6% (67/102) of the patients, whereas low ZBP-89 expression (- and +) was detected in 33.4% (34/102) of the patients.

Association between ZBP-89 expression in HCC peritumoral tissues and clinicopathological variables. The association between clinicopathological features and peritumoral ZBP-89 expression in 102 HCC patients is summarized in Table II. Peritumoral ZBP-89 expression was positively associated with the presence of liver cirrhosis, ALT and albumin ($P < 0.05$), whereas no statistically significant association was observed with the remaining clinicopathological parameters, which included histological grade, tumor size, multinodular tumor, capsular infiltration, AFP, bilirubin, age and sex ($P = 0.167, 0.532, 0.804, 0.349, 0.676, 1.000, 0.488, \text{ and } 0.087$, respectively). In the peritumoral tissues, ZBP-89 levels in patients from the F2-4 groups were significantly higher (76.4%, 42/55) than those of in patients from the F0-1 group (53.2%, 25/47).

Association between ZBP-89 expression in HCC peritumoral tissues and patient survival. The association between peritumoral ZBP-89 expression in HCC and survival was analyzed by the Kaplan-Meier method (Fig. 2). Prognostic values of the

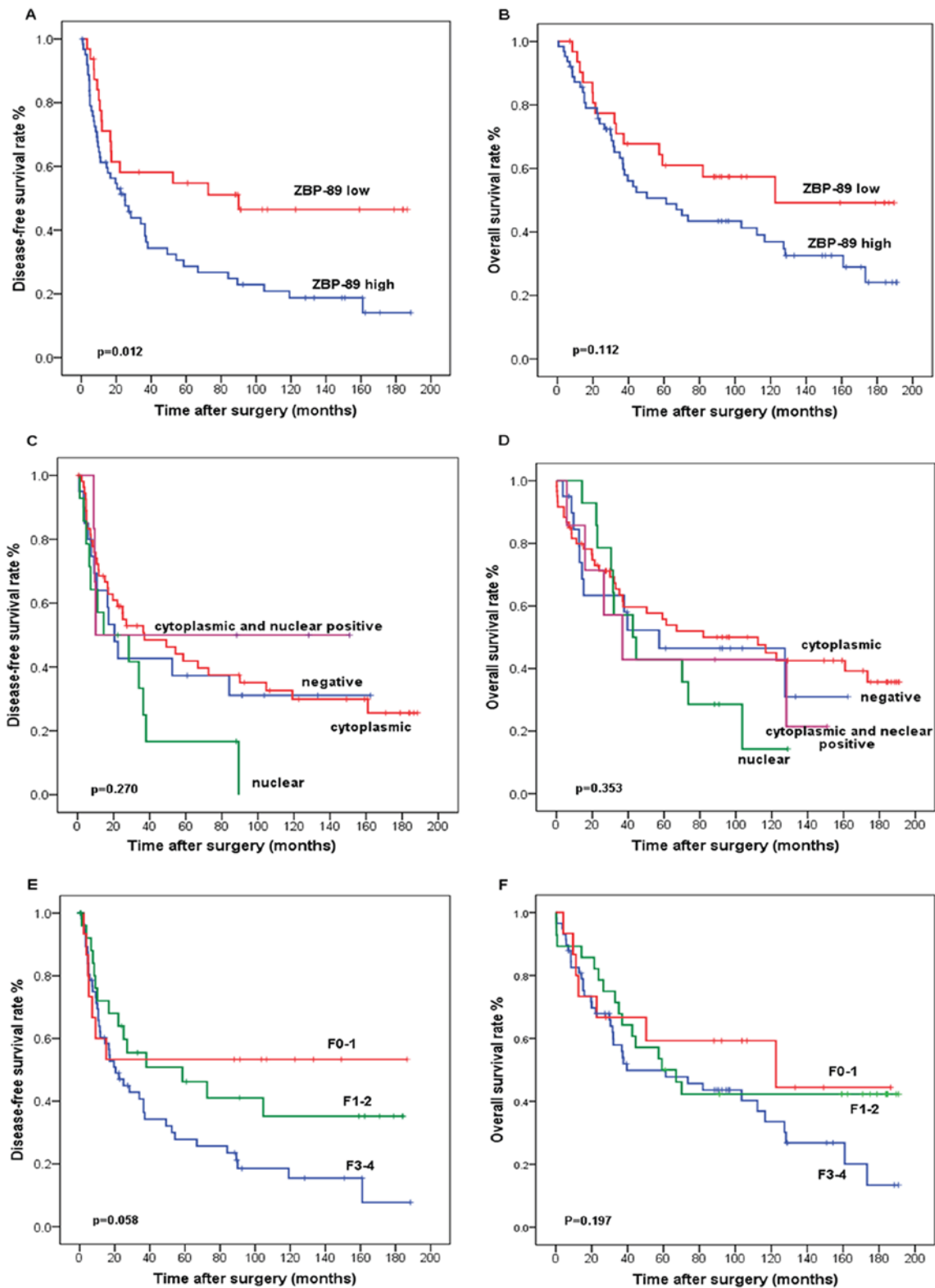


Figure 2. Prognostic values of the peritumoral hepatocellular expression of ZBP-89. Kaplan-Meier (A) DFS and (B) OS rate analysis of ZBP-89 in 102 patients with HCC who had received curative hepatectomy. Prognostic values of the subcellular localization of ZBP-89 expression in peritumoral hepatocytes. All patients were classified into 4 subgroups: Cytoplasmic type (n=60); nuclear type (n=14); cytoplasmic and nuclear type (n=8); as well as negative (n=20). Kaplan-Meier analysis of (C) DFS and (D) OS with 4 subgroups in the peritumoral liver tissue; Prognostic values of the METAVIR scores in peritumoral liver tissue. All patients were classified into 3 subgroups: F0-1 (n=15); F1-2 (n=28); and F3-4 (n=58). Kaplan-Meier analysis of (E) DFS and (F) OS with 3 subgroups in the peritumoral liver tissue. ZBP-89, zinc-binding protein-89; DFS, disease-free survival; OS, overall survival.

peritumoral hepatocellular expression of ZBP-89 illustrated by a Kaplan-Meier analysis of DFS and OS rate analysis of ZBP-89 in 102 patients with HCC who had received curative

hepatectomy (Fig. 2A and B). The prognostic values of the subcellular localization of ZBP-89 expression in peritumoral hepatocytes as shown by Kaplan-Meier analysis of DFS and

Table II. Association of ZBP-89 protein expression in peritumoral tissues with clinicopathological characteristics.

Parameter	ZBP-89 expression		P-value
	Positive	Negative	
Age, years			0.488
<50	21	8	
≥50	46	27	
Sex			0.087
Male	63	29	
Female	4	6	
AFP, μg/l			0.676
<400	39	22	
≥400	28	13	
ALT, IU/l			0.020
>80	16	2	
≥80	51	33	
Bilirubin, g/l			1.000
>20	3	1	
≤20	64	34	
Albumin, g/l			0.048
>35	52	33	
≤35	15	2	
Tumor lesions			0.804
Multiple	16	7	
Single	51	28	
Tumor size, cm			0.532
≥5	32	14	
<5	35	21	
Vascular invasion			0.349
Absence	47	28	
Presence	20	7	
Cirrhosis			0.020 ^a
Presence	42	13	
Absence	25	22	
Histological grade			0.167
Well and moderate	53	32	
Poor	13	3	

^aP<0.05. ZBP-89, zinc-binding protein-89; AFP, α-fetoprotein; ALT, alanine aminotransferase.

OS in 4 subgroups in the peritumoral liver tissue (Fig. 2C and D). Fig 2E and F illustrates the Kaplan-Meier analysis of DFS and OS of the 3 subgroups in the peritumoral liver tissue. Among the 102 HCC patients, 67 patients had succumbed to disease and 35 were alive at the end of the follow-up studies. The median observation period was 179 months (range, 128-270 months).

The median survival time of patients with high peritumoral ZBP-89 expression levels was 44.5 months, whereas the median survival time of patients with low peritumoral ZBP-89 levels

was 122.6 months. In the high-peritumoral-ZBP-89-expression group, the cumulative 5-year survival rate was 45.6% (n=90), whereas in the low-peritumoral-ZBP-89-expression group, the survival rate was 58.0%. The high peritumoral ZBP-89 expression group had a significantly shorter duration of DFS (P=0.012) compared with the ZBP-89-low group, whereas no significant association was observed between peritumoral ZBP-89 expression and OS (Fig. 1A and D). Univariate analysis revealed that a tumor size >5 cm, multiple tumors, and a poor histological grade were all statistically significant predictors of poor survival in patients with HCC (Table III). Meanwhile, multiple tumors and macroscopic vascular invasion were also statistically associated with poor DFS. The univariate Cox proportional hazard ratio (HR) of high vs. low peritumoral ZBP-89 expression was 1.797 (95% CI: 0.972-3.322; P=0.061) for DFS rate (Table IV).

Multivariate Cox proportional hazard analysis was performed based on factors that had been demonstrated to be significant in the univariate analysis. This analysis revealed that multiple tumors and macroscopic vascular invasion independently and significantly increased the recurrence of HCC. In the multivariate model, the adjusted Cox proportional HR for peritumoral ZBP-89-high patients was 2.031 (95% CI: 1.152-3.580; P=0.014) for DFS (Table IV). The univariate and the multivariate model demonstrated that the association between positive peritumoral ZBP-89 expression and OS rate in patients with HCC were not statistically significant (Table III). Taken together, the results of the present study indicated that peritumoral ZBP-89 expression may be a good prognostic marker for DFS in HCC patients.

Discussion

ZBP-89, commonly expressed at a low level in a number of adult tissues (31), has been found to be increased in multiple types of cancer, including HCC (20), breast cancer (21), esophageal squamous cell carcinomas (ESCC) (22), melanoma, gastric cancer, and CRC (21,32), but was reduced in clear-cell renal cell carcinoma (24), 30% of pancreatic adenocarcinomas, and Duke's B colon cancer (25). ZBP-89 expression differs in various tumor types owing to the different cell origins. Furthermore, positive ZBP-89 expression in different tumors may be indicative of completely different outcomes. For instance, high ZBP-89 expression in clear cell renal cell carcinoma and ESCC is associated with poor survival (22,24), whereas ZBP-89 overexpression is associated with prolonged OS and DFS times in patients with HCC and CRC (stages I-IV) (20,30). The contrasting effects of high intra-HCC and peri-HCC ZBP-89 expression levels on survival rates are probably due to the different subcellular localization of ZBP-89 in the HCC cell and normal hepatocyte. However the specific role of cytoplasmic ZBP-89 has not been confirmed and further investigation is required. ZBP-89 expression in adjacent non-tumor tissues and the associated prognostic impact on HCC has not, to the best of our knowledge, been systematically studied at present. The present study revealed an association between peritumoral ZBP-89 expression and patient survival, including DFS and OS rates.

The results of IHC staining identified high peritumoral ZBP-89 expression in 66.7% of the peritumoral samples from 102 HCC patients. ZBP-89 expression was localized

Table III. Cox proportional hazard regression analysis of patients' overall survival rates.

Parameter	Univariable			Multivariable		
	Hazard ratio	95% CI	P-value	Hazard ratio	95% CI	P-value
Age (<50 vs. ≥50 years)	1.275	0.677-2.398	0.452	-	-	-
Gender (female vs. male)	0.957	0.309-2.965	0.940	-	-	-
Cirrhosis (absence vs. presence)	1.614	0.932-2.794	0.087	-	-	-
Fibrosis vs. normal	0.701	0.373-1.316	0.269	-	-	-
Cirrhosis vs. normal	0.574	0.224-1.470	0.247	-	-	-
Tumor size (<5 vs. >5 cm)	2.577	1.402-4.739	0.002 ^a	2.454	1.447-4.160	0.001 ^a
AFP (<400 vs. ≥400 μg/l)	0.999	0.561-1.777	0.996	-	-	-
ALT (≤80 vs. >80 IU/l)	0.697	0.335-1.452	0.335	-	-	-
Albumin (>35 vs. ≤35 g/l)	0.383	0.190-0.774	0.007	0.375	0.205-0.683	0.001
Bilirubin (>20 vs. ≤20 μmol/l)	2.239	0.592-8.471	0.235	-	-	-
Histological grade (moderate vs. well)	0.665	0.313-1.416	0.290	-	-	-
Histological grade (poor vs. well)	0.242	0.063-0.929	0.039	0.241	0.067-0.872	0.03
Vascular invasion (absent vs. present)	0.672	0.363-1.246	0.207	-	-	-
Number of tumor lesions (single vs. multiple)	2.577	1.402-4.739	0.002 ^a	2.98	1.647-5.390	0.001 ^a
ZBP-89 (low vs. high)	0.989	0.523-1.870	0.972	-	-	-

^aP<0.05. CI, confidence interval; AFP, α-fetoprotein; ALT, alanine aminotransferase.

Table IV. Cox proportional hazard regression analysis of patients' disease-free survival rates.

Parameter	Univariable			Multivariable		
	Hazard ratio	95% CI	P-value	Hazard ratio	95% CI	P-value
Age (<50 vs. ≥50 years)	1.143	0.670-2.076	0.652	-	-	-
Gender (female vs. male)	0.401	0.155-1.273	0.150	-	-	-
Cirrhosis (absence vs. presence)	1.201	0.682-2.117	0.525	-	-	-
Fibrosis vs. normal	0.831	0.439-1.572	0.570	-	-	-
Cirrhosis vs. normal	0.608	0.246-1.505	0.282	-	-	-
Tumor size (<5 vs. >5 cm)	1.420	0.797-2.530	0.235	-	-	-
AFP (<400 vs. ≥400 μg/l)	0.966	0.556-1.680	0.904	-	-	-
ALT (≤80 vs. >80 IU/l)	1.271	0.637-2.535	0.497	-	-	-
Albumin (>35 vs. ≤35 g/l)	0.821	0.404-1.665	0.583	-	-	-
Bilirubin (>20 vs. ≤20 μmol/l)	1.608	0.447-5.786	0.468	-	-	-
Histological grade (moderate vs. well)	0.996	0.439-2.258	0.991	-	-	-
Histological grade (poor vs. well)	0.674	0.203-2.239	0.519	-	-	-
Vascular invasion (absent vs. present)	0.553	0.307-0.996	0.048 ^a	0.543	0.321-0.918	0.023 ^a
Number of tumor lesions (single vs. multiple)	2.796	1.504-5.196	0.001 ^a	3.145	1.783-5.547	0.001 ^a
ZBP-89 (low vs. high)	1.797	0.972-3.322	0.061	2.031	1.152-3.580	0.014 ^a

^aP<0.05. CI, confidence interval; AFP, α-fetoprotein; ALT, alanine aminotransferase.

predominantly in the cytoplasm of the peritumoral hepatocytes. In certain tissues with high cytoplasmic staining of ZBP-89 protein, a few nuclei also exhibited non-uniform immunostaining. This phenomenon may be associated with the heterogeneity present in peritumoral liver tissues or due to technical issues with IHC. The recurrence of HCC is a complex and multifactorial consequence, including the

infiltration of neoplastic into the peritumoral tissues or the malignant transformation of previously untransformed or precancerous hepatocytes. However, in the current study, the later hypothesis is more plausible as there is no histopathological evidence to support neoplastic hepatocyte infiltration to the peritumoral tissues by the review of the corresponding hematoxylin/eosin-stained slide.

Among all the clinicopathological parameters, the high expression of ZBP-89 in peritumoral hepatocytes is associated with the presence of liver cirrhosis. In the present study, HCC recurrence (that is, DFS time) as one indicator of poor patient prognosis. The direct cause of this poor prognosis, including HCC recurrence, in HCC patients with high ZBP-89 expression may be cirrhosis. Significantly, HCC patients expressing high levels of ZBP-89 in the corresponding non-tumor tissues exhibited a substantially shorter DFS time than those expressing low peritumoral ZBP-89 levels, which is consistent with the results of a previous study (20). Cox proportional hazard regression analysis of DFS and OS rates revealed that peritumoral ZBP-89 was a more sensitive factor for predicting HCC recurrence than cirrhosis. The results of the present study thus demonstrated that ZBP-89 expression in peritumoral liver tissues is a highly promising prognostic biomarker for recurrence of HCC.

The present study revealed that peritumoral ZBP-89 expression is predominantly localized in the cytoplasm, and its positive expression is associated with a higher risk of HCC recurrence following hepatic resection. By contrast, ZBP-89 is mainly expressed in the nuclei of HCC cells, and its over-expression is associated with prolonged OS and DFS times. A similar phenomenon also exists in gastric adenocarcinoma and CRC (21,32). ZBP-89 is mainly expressed in the nuclei of CRC and gastric adenocarcinoma cells; however, intensive cytoplasmic ZBP-89 staining is present in the surface epithelial cells in the areas of atrophic gastritis with intestinal metaplasia, which is pre-malignant (21). Similarly, ZBP-89 staining is localized in the cytoplasm of adenoma cells, which are precursors of adenocarcinoma. In familial adenomatous polyposis, the expression of ZBP-89 increases steadily during the transition from normal mucosa to adenoma and adenocarcinoma (32). ZBP-89 expression then decreases during the progression from stage I to stage IV CRC. These results indicate that ZBP-89 expression is upregulated at tumor initiation (23,32). Furthermore, the cytoplasmic accumulation of ZBP-89 protein occurs in certain pre-malignant states, particularly during the progression from normal mucosa to adenocarcinoma (32). We hypothesized that cytoplasmic ZBP-89 has a role in promoting cancer initiation, but that nuclear ZBP-89 has a role in tumor suppression (20), and prognosis analysis was performed concerning whether the sub-localization of the ZBP-89 protein affects patient prognosis. Although there was a trend of different survival rates for the four subtypes, the results were not significant (Fig. 2C and D). Inspired by this phenomenon, we hypothesized that the subcellular localization of ZBP-89 in the cytoplasm and nuclei may have a distinct role in HCC development. However, the molecular pathways and regulatory mechanisms involved require further investigation.

Previous studies have focused on the intratumoral expression of ZBP-89, revealing that its antitumor properties result from the binding of ZBP-89 to tumor protein p53 (hereafter p53), which prevents nuclear export and results in an elevated level of nuclear p53 (33,34). However, evidence indicates that ZBP-89 promotes tumor initiation (23,32,35). Recent reports indicate that ZBP-89 suppresses the activity of p53; therefore, reducing ZBP-89 expression could restore p53 activity and protect against cancer development (23). In addition, a recent

study revealed that the ZBP-89 protein binds directly to the promoter of CTNBN1 to induce transcription and drives a feed-forward loop of β -catenin expression (9). The hyper-activation of Wnt/ β -catenin signaling is closely associated with tumor aggressiveness and resistance to chemotherapeutic agents in HCC (36-38). Furthermore, ZBP-89 and β -catenin induce gene expression reciprocally and synergistically (9), which may be the mechanism by which ZBP-89 promotes the neoplastic transformation in adjuvant non-cancerous tissue.

Evidence indicates that patients with HBV infection are more likely to exhibit high ZBP-89 expression, which could drive a feed-forward loop of β -catenin expression. The reactivation of the sustained Wnt/ β -catenin pathway is associated with the pathogenesis of liver cirrhosis and could represent a promising novel target for fibrotic diseases (36-40). The results from these previous reports are consistent with those of the present study, demonstrating that ZBP-89 expression was elevated in fibrosis or cirrhosis tissues of the liver. Therefore, the direct cause of poor prognosis in patients HCC with high ZBP-89 expression may also be cirrhosis. However, the specific mechanisms by which ZBP-89 is involved in the formation of liver cirrhosis or how liver cirrhosis induces the high expression of ZBP-89 remains unclear and require more in-depth research.

The present study used the METAVIR scoring system for liver fibrosis scoring. In the peritumoral tissues, The pathological status of hepatocirrhosis, and the DFS and OS rates was examined in the current study; although there was a trend of different survival rates among patients with different severity of liver cirrhosis, the differences were not significant (Fig. 2E and F).

The present study had several limitations. First, the clinicopathological data and samples were collected from a single institution, which the data inadequate for further stratified analysis. Furthermore, the sample size was not large, and a prospective multi-center study consisting of a large number of patients who are uniformly classified and treated is required in the future. Evaluating only one slide per patient is a further limitation of the present study. Additionally, intratumoral and peritumoral expression was not directly compared in the current study as previous studies (20,22,24) have already investigated the intratumoral ZBP-89 expression and concluded that high intratumoral ZBP-89 expression is associated with improved survival rates.

In conclusion, the results of the present study indicate that high expression of ZBP-89 in peritumoral HCC tissues was associated with a shorter DFS time in HCC patients following curative hepatectomy. Additionally, high ZBP-89 expression in peritumoral HCC tissue was positively associated with the presence of liver cirrhosis in HCC patients, indicating that cirrhosis with high peritumoral ZBP-89 expression may be a contributing factor to the poor prognosis of patients with HCC. Therefore, peritumoral ZBP-89 expression may be a good prognostic marker to predict DFS time in HCC patients following curative hepatectomy and may provide novel insights into the molecular mechanisms of HCC initiation.

Acknowledgements

Not applicable.

Funding

The present study was supported by the National Natural Science Foundation of China (grant nos. 81472339 and 81402041).

Availability of data and materials

All data generated or analyzed during this study are included in this published article.

Authors' contributions

WQS analyzed and interpreted the patient data regarding the HCC and CC performed the histological examination of the peritumoral liver slides, both of them were the major contributors in writing the manuscript. All authors read and approved the final manuscript.

Ethics approval and consent to publish

This study was approved by the Joint Chinese University of Hong Kong-New Territories East Cluster Clinical Research Ethics Committee. Informed written consent was obtained from all patients involved in the study.

Consent for publication

Informed written consent was obtained from all patients involved in the study.

Competing interests

The authors declare that they have no competing interests.

References

- Zuo TT, Zheng RS, Zhang SW, Zeng HM and Chen WQ: Incidence and mortality of liver cancer in China in 2011. *Chin J Cancer* 34: 508-513, 2015.
- Ryerson AB, Ehemann CR, Altekruse SF, Ward JW, Jemal A, Sherman RL, Henley SJ, Holtzman D, Lake A, Noone AM, *et al*: Annual report to the nation on the status of cancer, 1975-2012, featuring the increasing incidence of liver cancer. *Cancer* 122: 1312-1337, 2016.
- Utsunomiya T, Shimada M, Imura S, Morine Y, Ikemoto T and Mori M: Molecular signatures of noncancerous liver tissue can predict the risk for late recurrence of hepatocellular carcinoma. *J Gastroenterol* 45: 146-152, 2010.
- Jain RK: Normalizing tumor microenvironment to treat cancer: Bench to bedside to biomarkers. *J Clin Oncol* 31: 2205-2218, 2013.
- Llovet JM, Paradis V, Kudo M and Zucman-Rossi J: Tissue biomarkers as predictors of outcome and selection of transplant candidates with hepatocellular carcinoma. *Liver Transpl* 17 (Suppl 2): S67-S71, 2011.
- Lu LC, Hsu CH, Hsu C and Cheng AL: Tumor heterogeneity in hepatocellular carcinoma: Facing the challenges. *Liver Cancer* 5: 128-138, 2016.
- Gao Q, Wang ZC, Duan M, Lin YH, Zhou XY, Worthley DL, Wang XY, Niu G, Xia Y, Deng M, *et al*: Cell culture system for analysis of genetic heterogeneity within hepatocellular carcinomas and response to pharmacologic agents. *Gastroenterology* 152: 232-242, 2017.
- Xue R, Li R, Guo H, Guo L, Su Z, Ni X, Qi L, Zhang T, Li Q, Zhang Z, *et al*: Variable intra-tumor genomic heterogeneity of multiple lesions in patients with hepatocellular carcinoma. *Gastroenterology* 150: 998-1008, 2016.
- Essien BE, Sundaresan S, Ocadiz-Ruiz R, Chavis A, Tsao AC, Tessier AJ, Hayes MM, Photenhauer A, Saqui-Salces M, Kang AJ, *et al*: Transcription factor ZBP-89 drives a feedforward loop of β -catenin expression in colorectal cancer. *Cancer Res* 76: 6877-6887, 2016.
- Borghaei RC, Gorski G, Seutter S, Chun J, Khaselov N and Scianni S: Zinc-binding protein-89 (ZBP-89) cooperates with NF- κ B to regulate expression of matrix metalloproteinases (MMPs) in response to inflammatory cytokines. *Biochem Biophys Res Commun* 471: 503-509, 2016.
- Ye CG, Chen GG, Ho RLK, Merchant JL, He ML and Lai PBS: Epigenetic upregulation of Bak by ZBP-89 inhibits the growth of hepatocellular carcinoma. *Biochim Biophys Acta* 1833: 2970-2979, 2013.
- Leupold JH, Asangani IA, Mudduluru G and Allgayer H: Promoter cloning and characterization of the human programmed cell death protein 4 (*pdc4*) gene: Evidence for ZBP-89 and Sp-binding motifs as essential *Pdc4* regulators. *Biosci Rep* 32: 281-297, 2012.
- Bai L and Merchant JL: Transcription factor ZBP-89 is required for STAT1 constitutive expression. *Nucleic Acids Res* 31: 7264-7270, 2003.
- Bai L and Merchant JL: Transcription factor ZBP-89 cooperates with histone acetyltransferase p300 during butyrate activation of *p21waf1* transcription in human cells. *J Biol Chem* 275: 30725-30733, 2000.
- Feng Y, Wang X, Xu L, Pan H, Zhu S, Liang Q, Huang B and Lu J: The transcription factor ZBP-89 suppresses p16 expression through a histone modification mechanism to affect cell senescence. *FEBS J* 276: 4197-4206, 2009.
- Wu Y, Zhang X, Salmon M and Zehner ZE: The zinc finger repressor, ZBP-89, recruits histone deacetylase 1 to repress vimentin gene expression. *Genes Cells* 12: 905-918, 2007.
- Zhang X, Diab IH and Zehner ZE: ZBP-89 represses vimentin gene transcription by interacting with the transcriptional activator, Sp1. *Nucleic Acids Res* 31: 2900-2914, 2003.
- Remington MC, Tarle SA, Simon B and Merchant JL: ZBP-89, a Kruppel-type zinc finger protein, inhibits cell proliferation. *Biochem Biophys Res Commun* 237: 230-234, 1997.
- Merchant JL, Iyer GR, Taylor BR, Kitchen JR, Mortensen ER, Wang Z, Flintoft RJ, Michel JB, Bassel-Duby R: ZBP-89, a Kruppel-like zinc finger protein, inhibits epidermal growth factor induction of the gastrin promoter. *Mol Cell Biol* 16: 6644-6653, 1996.
- Zhang CZ, Cao Y, Yun JP, Chen GG and Lai PB: Increased expression of ZBP-89 and its prognostic significance in hepatocellular carcinoma. *Histopathology* 60: 1114-1124, 2012.
- Taniuchi T, Mortensen ER, Ferguson A, Greenon J and Merchant JL: Overexpression of ZBP-89, a zinc finger DNA binding protein, in gastric cancer. *Biochem Biophys Res Commun* 233: 154-160, 1997.
- Yan SM, Wu HN, He F, Hu XP, Zhang ZY, Huang MY, Wu X, Huang CY and Li Y: High expression of zinc-binding protein-89 predicts decreased survival in esophageal squamous cell cancer. *Ann Thorac Surg* 97: 1966-1973, 2014.
- Nilton A, Sayin VI, Zou ZV, Sayin SI, Bondjers C, Gul N, Agren P, Fogelstrand P, Nilsson O, Bergo MO and Lindahl P: Targeting *Zfp148* activates p53 and reduces tumor initiation in the gut. *Oncotarget* 7: 56183-56192, 2016.
- Cai MY, Luo RZ, Li YH, Dong P, Zhang ZL, Zhou FJ, Chen JW, Yun JP, Zhang CZ and Cao Y: High-expression of ZBP-89 correlates with distal metastasis and poor prognosis of patients in clear cell renal cell carcinoma. *Biochem Biophys Res Commun* 426: 636-642, 2012.
- Bai L, Logsdon C and Merchant JL: Regulation of epithelial cell growth by ZBP-89: Potential relevance in pancreatic cancer. *Int J Gastrointest Cancer* 31: 79-88, 2002.
- Altman DG, McShane LM, Sauerbrei W and Taube SE: Reporting recommendations for tumor marker prognostic studies (REMARK): Explanation and elaboration. *PLoS Med* 9: e1001216, 2012.
- Moons KG, Altman DG, Reitsma JB and Collins GS: Transparent Reporting of a Multivariate Prediction Model for Individual Prognosis or Development Initiative: New guideline for the reporting of studies developing, validating, or updating a multivariable clinical prediction model: The TRIPOD statement. *Adv Anat Pathol* 22: 303-305, 2015.

28. Pirisi M, Leutner M, Pinato DJ, Avellini C, Carsana L, Toniutto P, Fabris C and Boldorini R: Reliability and reproducibility of the edmondson grading of hepatocellular carcinoma using paired core biopsy and surgical resection specimens. *Arch Pathol Lab Med* 134: 1818-1822, 2010.
29. Mohamadnejad M, Tavangar SM, Sotoudeh M, Kosari F, Khosravi M, Geramizadeh B, Montazeri G, Estakhri A, Mirnasseri MM, Fazlollahi A, *et al*: Histopathological study of chronic hepatitis B: A comparative study of ishak and METAVIR scoring systems. *Int J Organ Transplant Med* 1: 171-176, 2010.
30. Chan JK: The wonderful colors of the hematoxylin-eosin stain in diagnostic surgical pathology. *Int J Surg Pathol* 22: 12-32, 2014.
31. Zhang CZ, Chen GG and Lai PB: Transcription factor ZBP-89 in cancer growth and apoptosis. *Biochim Biophys Acta* 1806: 36-41, 2010.
32. Gao XH, Liu QZ, Chang W, Xu XD, Du Y, Han Y, Liu Y, Yu ZQ, Zuo ZG, Xing JJ, *et al*: Expression of ZNF148 in different developing stages of colorectal cancer and its prognostic value: A large Chinese study based on tissue microarray. *Cancer* 119: 2212-2222, 2013.
33. Bai L and Merchant JL: ZBP-89 promotes growth arrest through stabilization of p53. *Mol Cell Biol* 21: 4670-4683, 2001.
34. Okada M, Tessier A, Bai L and Merchant JL: P53 mutants suppress ZBP-89 function. *Anticancer Res* 26: 2023-2028, 2006.
35. Fang J, Jia J, Makowski M, Xu M, Wang Z, Zhang T, Hoskins JW, Choi J, Han Y, Zhang M, *et al*: Functional characterization of a multi-cancer risk locus on chr5p15.33 reveals regulation of TERT by ZNF148. *Nat Commun* 8: 15034, 2017.
36. Xiang T, Zhang S, Cheng N, Ge S, Wen J, Xiao J and Wu X: Oxidored-nitro domain-containing protein 1 promotes liver fibrosis by activating the Wnt/ β -catenin signaling pathway in vitro. *Mol Med Rep* 16: 5050-5054, 2017.
37. Miao CG, Yang YY, He X, Huang C, Huang Y, Zhang L, Lv XW, Jin Y and Li J: Wnt signaling in liver fibrosis: Progress, challenges and potential directions. *Biochimie* 95: 2326-2335, 2013.
38. Cheng JH, She H, Han YP, Wang J, Xiong S, Asahina K and Tsukamoto H: Wnt antagonism inhibits hepatic stellate cell activation and liver fibrosis. *Am J Physiol Gastrointest Liver Physiol* 294: G39-G49, 2008.
39. Whittaker S, Marais R and Zhu AX: The role of signaling pathways in the development and treatment of hepatocellular carcinoma. *Oncogene* 29: 4989-5005, 2010.
40. Guo Y, Xiao L, Sun L and Liu F: Wnt/beta-catenin signaling: A promising new target for fibrosis diseases. *Physiol Res* 61: 337-346, 2012.



This work is licensed under a Creative Commons Attribution-NonCommercial-NoDerivatives 4.0 International (CC BY-NC-ND 4.0) License.