

Facilitation techniques to cross the interatrial septum with intracardiac echocardiography during left atrial appendage closure

Maarten Vanhaverbeke MD, PhD  | Philippe Nuyens MD |
Gintautas Bieliauskas MD | Lars Sondergaard MD, DMSc | Niels Vejstrup MD, PhD |
Ole De Backer MD, PhD 

The Heart Centre, Rigshospitalet,
Copenhagen, Denmark

Correspondence

Ole De Backer, MD, PhD, Rigshospitalet -
The Heart Center, Blegdamsvej 9, 2100
Copenhagen, Denmark.
Email: ole.debacker@gmail.com

Abstract

Objectives: This study aimed to assess the rate of difficult interatrial septum (IAS) crossing with the intracardiac echocardiography (ICE) probe during percutaneous left atrial appendage (LAA) closure and to identify techniques that facilitate IAS crossing with the ICE probe.

Background: Percutaneous LAA closure is increasingly performed by ICE guidance. Although such an approach omits the need for general anesthesia, crossing of the IAS with the ICE probe may sometimes be challenging.

Methods: All consecutive patients that underwent ICE-guided percutaneous LAA closure with an Amplatzer Amulet (Abbott) or WatchmanFLX (Boston Scientific) at our center in the period 2018–2021 were included. Cases in which IAS crossing with ICE was difficult were identified and techniques used to facilitate IAS crossing were identified and listed.

Results: In 17 (5%) out of 354 cases, IAS crossing with the ICE probe was difficult and required use of additional techniques. Ultimately, IAS crossing was also successful in these 17 cases by using one of three possible facilitation techniques: the probing technique (12 cases), the double-wire technique (3 cases), and the snaring technique (2 cases). In one case, the double-wire technique was converted to the snaring technique, as crossing of the ICE probe remained challenging despite the use of two stiff guidewires.

Conclusion: Crossing of the IAS with the ICE probe can be challenging in 5% of ICE-guided percutaneous LAA closure procedures. Operators should be aware of possible facilitation techniques in challenging cases, as these show to be safe and effective.

KEYWORDS

crossing technique, interatrial septum, intracardiac echocardiography, left atrial appendage closure

This is an open access article under the terms of the Creative Commons Attribution-NonCommercial License, which permits use, distribution and reproduction in any medium, provided the original work is properly cited and is not used for commercial purposes.

© 2022 The Authors. *Catheterization and Cardiovascular Interventions* published by Wiley Periodicals LLC.

1 | INTRODUCTION

Percutaneous left atrial appendage (LAA) closure is a valuable alternative for oral anticoagulation (OAC) as stroke prevention in patients with non-valvular atrial fibrillation (AF).^{1,2} It is currently a class IIb indication for patients with AF and contra-indications for long-term OAC therapy.³ Traditionally, these procedures are performed in general anesthesia and by guidance of transesophageal echocardiography (TEE) imaging. However, intracardiac echocardiography (ICE) has recently gained more interest to guide these interventions, as ICE-guidance omits the necessity for general anesthesia.⁴

ICE guidance of the transseptal puncture is typically straightforward, with placement of the ICE catheter in the right atrium. However, for guidance of the actual LAA closure, the ICE probe should be crossed over toward the left atrium (LA) for optimal imaging of the LAA and device implantation.⁵ In contemporary practice, only one transseptal puncture is performed to accommodate both the delivery system and the ICE probe.⁶ The most frequently used view is from the left upper pulmonary vein (LUPV). Positioning the ICE probe in the LA and/or LUPV requires crossing the interatrial septum (IAS) with the ICE probe.

Manipulation of the ICE probe should be done carefully and since the ICE probe is not an 'over-the-wire' system, steering this probe toward and across the IAS puncture site is not always straightforward. Consequently, operators should be knowledgeable about possible bailout techniques to cross the IAS with the ICE catheter in case of difficult crossing. In the current retrospective study, we identified cases in which first attempts to cross the IAS with the ICE probe failed. We then extensively describe and illustrate three possible bail-out techniques, which offer operators an alternative in case of difficult IAS crossing.

2 | METHODS

2.1 | Study population

All consecutive patients that underwent ICE-guided percutaneous LAA closure in local anesthesia with an Amplatzer Amulet (Abbott) or Watchman FLX (Boston Scientific) device in Copenhagen (Denmark) in the period 2018–2021 were included. All patients gave written informed consent for the procedure and the use of anonymous data for clinical research. All baseline patient and procedural data were prospectively collected in the Copenhagen LAA Registry.

2.2 | Standard ICE-guided LAA closure procedure

Two venous accesses are needed. At our center, one 6F sheath is placed in the left femoral vein (for ICE) and one other 6F sheath is placed in the right femoral vein (for the LAA closure device delivery sheath). The left 6F sheath is exchanged for a 30 cm 10F Super Arrow-Flex sheath (Teleflex) over a stiff guidewire and the ICE

catheter is positioned in the right atrium. The right 6F sheath is exchanged for an 8.5F SLO/1 transseptal introducer sheath (Abbott) and advanced over the transseptal wire into the superior vena cava. Next, the transseptal wire is removed and a BRK-1 transseptal needle (Abbott) is introduced. Following ICE-guided transseptal puncture, the transseptal sheath is advanced into the LA. By means of a regular J-tipped guidewire and MP catheter, the LUPV is cannulated and the J-tipped guidewire exchanged for an Amplatz Super Stiff guidewire (Abbott). Next, the transseptal introducer sheath is removed and the appropriate 12–14F LAA closure device delivery sheath is introduced. After predilating the IAS with the delivery sheath, the delivery sheath is withdrawn to the right atrium and the IAS is crossed with the ICE probe. As soon as the ICE probe is across the IAS, the LAA closure device delivery sheath is re-introduced into the LA and a standard percutaneous LAA closure can be performed.

2.3 | The probing technique

This technique is illustrated in Figure 1 and Video S1. From the left femoral vein, the ICE probe is removed and a floppy wire (Terumo) is advanced in a 6F MP catheter. The predilated IAS puncture site is crossed with the floppy wire in a similar way as crossing a patent foramen ovale. Alternatively, the 8.5 F transseptal sheath can be used instead of an MP catheter; this to facilitate finding the IAS puncture site. Once the IAS is crossed with the floppy wire, the floppy wire and MP catheter are advanced into the LUPV and the floppy wire exchanged for an Amplatz stiff guidewire. Next, the MP catheter and 30 cm Super Arrow-Flex sheath are removed, and a 65 cm 10F Super Arrow-Flex sheath is introduced, which can be advanced all the way up into the LUPV. As a result, the ICE-probe can then be easily positioned in the LUPV without the need for any further manipulation.

2.4 | The double-wire technique

This technique is illustrated in Figure 2 and Video S2. By means of the double-wire technique, the operator actually aims to keep open the IAS puncture site after this IAS puncture site was predilated by the LAA closure device delivery sheath. Following retraction of the LAA closure device delivery sheath into the right atrium, the dilator of the delivery sheath is removed and a Safari² Guidewire small-curve (Boston Scientific) is introduced into the LA; this besides the Amplatz stiff guidewire which is kept in the LUPV. While the two stiff guidewires can be externally manipulated to maximally open the IAS puncture site, the ICE-probe is directed toward the "crossing zone" of the two stiff guidewires and can cross the IAS puncture site.

2.5 | The snaring technique

This technique is illustrated in Figure 3 and Video S3. By means of the snaring technique, the operator aims to snare and approximate the

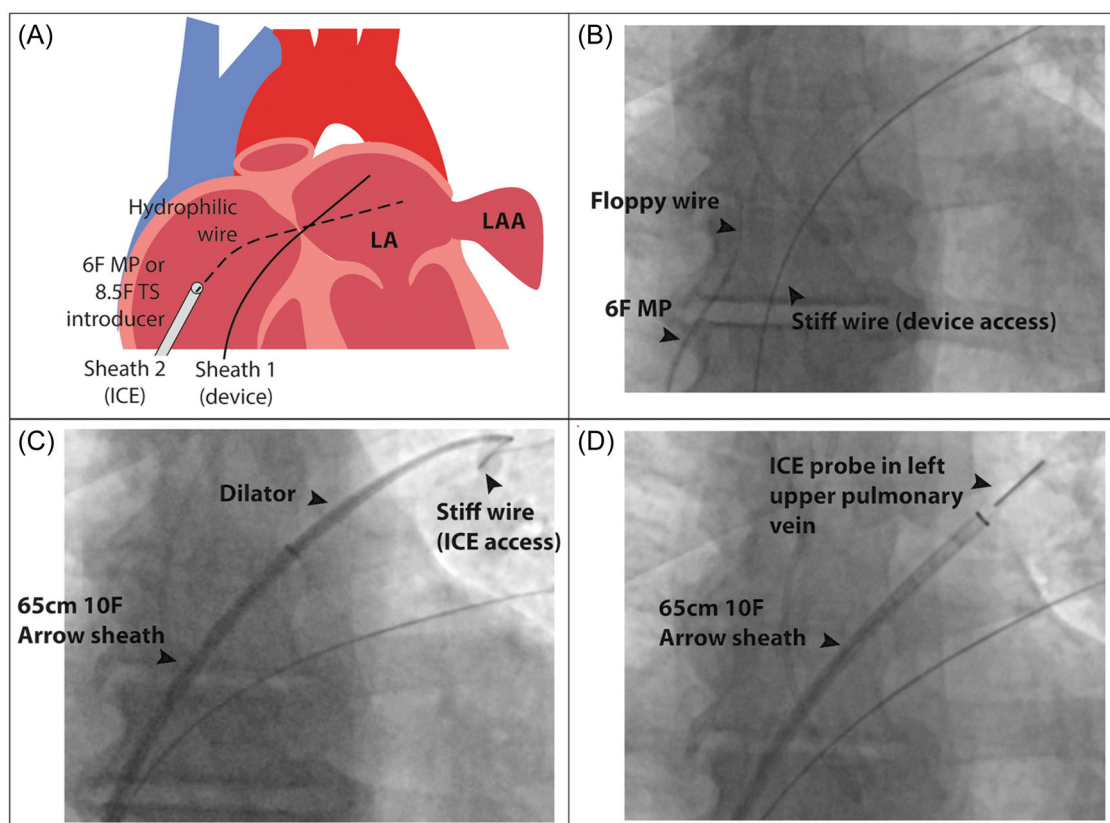


FIGURE 1 Probing technique. (A) Graphical illustration. (B) Fluoroscopic anteroposterior view to cross the IAS puncture site with a hydrophilic floppy Terumo wire. (C) After exchanging the floppy guidewire for an Amplatz stiff guidewire, a 65-cm-long 10F Arrow sheath is advanced over the stiff guidewire into the LUPV.⁴ Finally, the ICE probe can be advanced directly into the LUPV. ICE, intracardiac echocardiography; LA, left atrium; LAA, left atrial appendage; LUPV, left upper pulmonary vein; MP, multipurpose; TS, transseptal. [Color figure can be viewed at wileyonlinelibrary.com]

distal tip of the ICE probe toward the Amplatz stiff guidewire and guide the ICE probe toward the IAS puncture site. Following retraction of the LAA closure device delivery sheath into the right atrium, the dilator of the delivery sheath is removed and a 25 mm gooseneck snare (e.g., ONE Snare, Merit Medical) is snared (externally) around the Amplatz stiff guidewire. A 6F MP guiding catheter is then advanced over the snare and introduced into the delivery system. Alternatively, an 8F MP guiding catheter can be used in case the hemostatic valve permits this (e.g., when using the Watchman TruSeal Access System). In the right atrium, the snare is opened and the ICE probe is snared along the Amplatz stiff guidewire. While snaring the distal tip of the ICE probe by means of the MP guiding catheter, the ICE probe is advanced toward the IAS puncture site. As soon as the distal tip of the ICE probe is introduced into the LA, the snare is released and removed from the delivery sheath together with the MP guiding catheter.

2.6 | Statistical analysis

Categorical variables are reported as absolute values and percentages. Continuous variables are presented as means \pm standard

deviation. All statistical analyses were performed with SPSS software version 24 (IBM Corp.).

3 | RESULTS

In this series of 354 percutaneous LAA closure procedures guided by ICE, crossing of the IAS puncture site with the ICE probe succeeded within 5 min in 337 cases (95%). In 17 cases (5%), crossing of the IAS puncture site with the ICE probe was more challenging.

Ultimately, crossing of the IAS puncture site was also successful in these 17 cases by using one of the facilitation techniques: the probing technique was used in 12 cases, the double-wire technique in three cases and the snaring technique in two cases. In one particular case, the double-wire technique had to be converted to the snaring technique as crossing of the ICE probe remained challenging despite use of two stiff guidewires. An overview of additional materials needed for the respective techniques can be found in Table 1.

No procedural complications related to the use of ICE and ICE crossing occurred. Only in one case, there was a minor pericardial effusion post-LAA closure device implantation, which was treated conservatively without the need for pericardiocentesis.

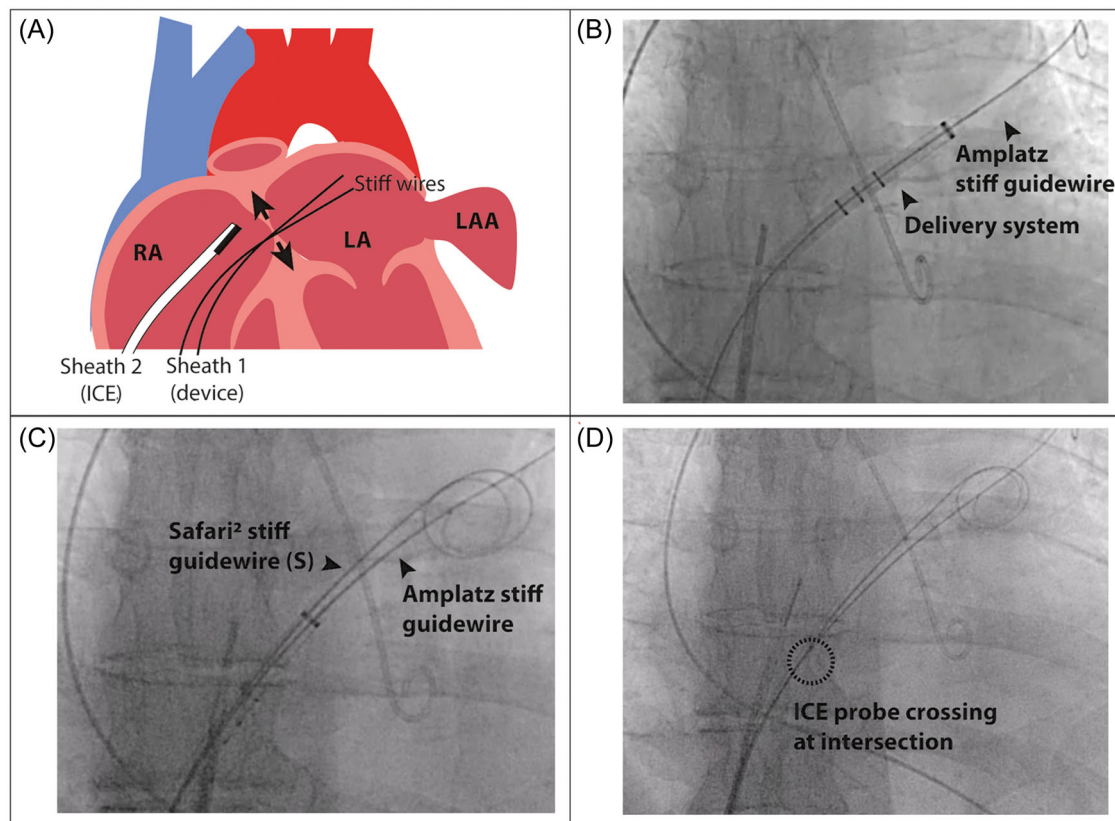


FIGURE 2 Double-wire technique. (A) Graphical illustration. (B) Fluoroscopic anteroposterior view, showing the LAA closure device delivery sheath (in this case TruSeal Access System) advanced into the LA. (C) After removal of the delivery sheath dilator, a second stiff guidewire (Safari² Guidewire, small-curve) is introduced into the LA. (D) Following retraction of the delivery sheath into the RA, the ICE probe can be crossed at the intersection of the two stiff guidewires. ICE, intracardiac echocardiography; LA, left atrium; LAA, left atrial appendage; RA, right atrium. [Color figure can be viewed at wileyonlinelibrary.com]

4 | DISCUSSION

In this registry-based study, we for the first time report the rate of difficult IAS crossing with the ICE probe during percutaneous LAA closure and describe techniques used to facilitate IAS crossing with the ICE probe. The required materials and advantages of each technique are summarized in Table 1. These techniques can be easily applied in clinical practice and allow percutaneous LAA closure procedures to be performed in local anesthesia and with a single IAS puncture.

Since a few years, percutaneous LAA closure procedures are increasingly performed in local anesthesia and by guidance of ICE. Importantly, this requires a proper preprocedural planning based on cardiac computed tomography (CT) imaging of the LAA. For guidance of the transseptal puncture, the ICE probe can just be positioned in the right atrium. However, for guidance of the actual LAA closure with the closure device, one has to advance the ICE probe to the LA and/or LUPV. To get the ICE probe from the right to the left atrium, the IAS has to be crossed. Initially, there were two different approaches: either (A) by two separate transseptal punctures; one for the LAA closure device delivery sheath and one for the ICE probe; or (B) by advancing both the delivery sheath and ICE probe through

the same IAS puncture site. As the strategy with two separate transseptal punctures is more cumbersome and time-consuming, does not necessarily improve procedural safety, and does not make crossing of the IAS with the ICE probe easier, most centers are nowadays using the single IAS puncture strategy to cross the delivery sheath and ICE probe to the LA.

In this real-world registry-based study, we report that IAS crossing with the ICE probe can be challenging in 1 out of 20 cases. Typically, crossing the ICE probe through the IAS puncture site is guided by both fluoroscopy and ICE imaging and is already facilitated by the presence of a stiff guide wire passing across the IAS puncture site. However, as the ICE probe is not an ‘over-the-wire’ system, steering this ICE probe toward the IAS puncture site is not always straightforward. Hence, operators should be knowledgeable about possible facilitation techniques to cross the IAS with the ICE probe in case of difficult crossing.

The “probing technique” could be the first-choice technique since this strategy is easy, safe, and was 100% successful in our experience in 12 cases. Moreover, in case the floppy Terumo wire can be advanced into the LUPV, an additional advantage of this technique is that the 65-cm-long 10F Arrow sheath—and as a next step the ICE probe—can be immediately placed into the LUPV. In this way, a

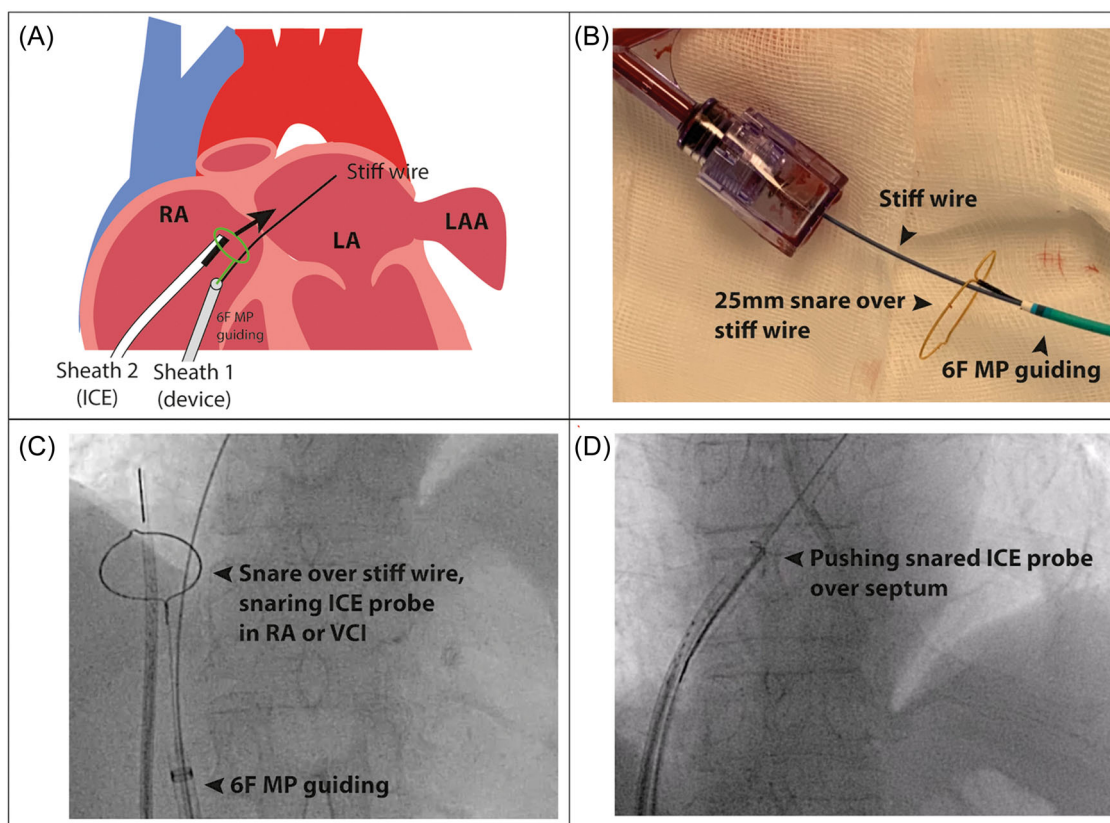


FIGURE 3 Snaring technique. (A) Graphical illustration. (B) A 25 mm gooseneck snare is mounted over the Amplatzer stiff guidewire and advanced to the distal end of delivery sheath by means of a 6F MP guiding catheter. (C) Fluoroscopic anteroposterior view showing snaring of the ICE probe in the RA. (D) The snared distal tip of the ICE probe is gently directed toward and pushed over the IAS puncture site, facilitated by the snare. ICE, intracardiac echocardiography; LA, left atrium; LAA, left atrial appendage; MP, multipurpose; RA, right atrium. [Color figure can be viewed at wileyonlinelibrary.com]

possible difficult placement of the ICE probe into the LUPV is also tackled. Limitations of this technique are the logistics and/or economical aspects, as this technique is fully dependent upon the availability of a 65-cm-long 10 F Arrow-Flex sheath.

The “double-wire technique” for IAS crossing of the ICE probe has been described earlier⁷ and is probably the most simplistic approach. However, this approach was not successful in all cases. In one case, the double-wire technique had to be converted to the snaring technique as ICE crossing remained challenging despite use of two stiff guidewires.

Finally, we also used the “snaring technique” successfully in two cases. This approach is technically somewhat more complex, requires additional materials, and has some limitations, especially when used in combination with the Amplatzer Torqvue Delivery Sheath (Abbott). In the latter case, a Y-connector has to be mounted on the delivery sheath to prevent continuous blood loss – however, this makes the advancement of the snare and 6F guiding catheter (besides the Amplatzer stiff guidewire) more difficult. This is not an issue when used in combination with the Amplatzer Steerable Delivery Sheath (Abbott) or Watchman TruSeal Access System (Boston Scientific).

Whenever the above approaches fail, the IAS puncture site can also be further expanded by a balloon predilatation. Since the

delivery sheaths have an outer diameter of approximately 5 mm, it will require an 8–10 mm balloon (eg. 8 mm Z-Med II balloon, which is compatible with a 0.035” stiff guidewire) to obtain an additional expansion of the IAS puncture site. Although this technique may be less complex than the snaring approach, it may increase the risk of a persistent IAS defect postprocedure and it would also be the most expensive solution (Table 1).

Taken together, crossing of the IAS with the ICE probe should be performed carefully. Although this study was not designed to identify predictors of difficult IAS crossing, based on our experience, IAS crossing can be particularly challenging in patients with severely dilated atria. The use of both fluoroscopic and ICE imaging can be useful and is often needed. If resistance is felt when pushing or torquing the ICE probe, one should refrain from further ICE manipulation and reassess fluoroscopy and ICE, as the ICE probe remains a relatively stiff catheter that is moved around in the heart chambers without the comfort of an “over-the-wire” principle.

Knowledge of some of these facilitation techniques is useful when performing ICE-guided percutaneous LAA closure. These approaches may also be useful when ICE-guidance of transcatheter mitral interventions will be further developed. The data in this all-comers registry study confirms that ICE-guided LAA closure is safe

TABLE 1 Facilitation techniques to cross the IAS puncture site with the ICE probe in case of challenging crossing during percutaneous LAA closure

	Additional material	Ease of use	Success rate	Cost
Probing technique	- 6F MP catheter - Floppy wire (e.g., Terumo) - 65 cm 10F Arrow-Flex sheath	+++	+++	€
Two-wire technique	- Additional stiff guidewire (e.g., Safari ² Guidewire small-curve)	++	++	€€
Snaring technique	- 6F/8F MP guiding catheter - 25 mm gooseneck snare - Additional Y-connector in case of Amplatzer TorqVue Delivery Sheath	+	+++	€€€

Abbreviations: IAS, interatrial septum; ICE, intracardiac echocardiography; LAA, left atrial appendage; MP, multipurpose.

and efficient, and that facilitation techniques for IAS crossing with ICE are only needed in few cases, but with good procedural outcomes.

5 | CONCLUSIONS

Crossing of the IAS with the ICE probe can be challenging in 5% of ICE-guided percutaneous LAA closure procedures. In case of difficult IAS crossing, the probing technique or double-wire technique can be used. In selected cases, snaring of the ICE probe can also be an option and facilitate IAS crossing. These facilitation techniques allow operators to successfully perform and finish ICE-guided LAA closure procedures, even in case of difficult IAS crossing.

ACKNOWLEDGMENT

There was no funding for this manuscript.

CONFLICT OF INTEREST

The authors declare no conflict of interest.

DATA AVAILABILITY STATEMENT

The data that support the findings of this study are available from the corresponding author upon reasonable request.

ORCID

Maarten Vanhaverbeke  <http://orcid.org/0000-0002-4385-7069>

Ole De Backer  <http://orcid.org/0000-0002-9674-0278>

REFERENCES

1. Osmancik P, Herman D, Neuzil P, et al. Left atrial appendage closure versus direct oral anticoagulants in high-risk patients with atrial fibrillation. *J Am Coll Cardiol*. 2020;75(25):3122-35.
2. Kar S, Doshi SK, Sadhu A, et al. Primary outcome evaluation of a next-generation left atrial appendage closure device: results from the PINNACLE FLX trial. *Circulation*. 2021;143(18):1754-62.
3. Hindricks G, Potpara T, Dagres N, et al. ESC guidelines for the diagnosis and management of atrial fibrillation developed in collaboration with the European Association for Cardio-Thoracic Surgery (EACTS): the task force for the diagnosis and management of atrial fibrillation of the European Society of Cardiology (ESC) developed with the special contribution of the European Heart Rhythm Association (EHRA) of the ESC. *Eur Heart J*. 2020;42(5):373-498.
4. Berti S, Pastormerlo LE, Korsholm K, et al. Intracardiac echocardiography for guidance of transcatheter left atrial appendage occlusion: an expert consensus document. *Catheter Cardiovasc Interv*. 2021;98(4):815-25.
5. Alkhouli M, Hijazi ZM, Holmes DR Jr, Rihal CS, Wiegers SE. Intracardiac echocardiography in structural heart disease interventions. *JACC Cardiovasc Interv*. 2018;11(21):2133-47.
6. Aguirre D, Pincetti C, Perez L, et al. Single trans-septal access technique for left atrial intracardiac echocardiography to guide left atrial appendage closure. *Catheter Cardiovasc Interv*. 2018;91(2):356-61.
7. Palma Dallan LA, Yoon S-H, Filby SJ. Dual wire technique for transseptal passage of intracardiac echocardiogram probe during left atrium appendage closure. *Structural Heart*. 2022. In press, online.

SUPPORTING INFORMATION

Additional supporting information can be found online in the Supporting Information section at the end of this article.

How to cite this article: Vanhaverbeke M, Nuyens P, Bieliauskas G, Sondergaard L, Vejstrup N, De Backer O. Facilitation techniques to cross the interatrial septum with intracardiac echocardiography during left atrial appendage closure. *Catheter Cardiovasc Interv*. 2022;100:795-800. doi:10.1002/ccd.30348