

Rapid ventricular pacing assisted hypotension in the management of sudden intraoperative hemorrhage during cerebral aneurysm clipping

Shariq Ali Khan^{1,2}, Miles Berger¹, Abhishek Agrawal³, Mary Huang⁴, Isaac Karikari⁴, Shahid M. Nimjee³, Ali R. Zomorodi³, David L. McDonagh¹

Departments of ¹Anesthesiology, ³Surgery (Neurosurgery) and Radiology, and ⁴Surgery (Neurosurgery), Duke University Medical Centre, Durham, North Carolina, USA, ²Anaesthesiology, Singapore General Hospital, Singapore

ABSTRACT

Sudden intraoperative hemorrhage during intracranial aneurysm surgery from vascular injury or aneurysmal rupture has been known to dramatically increase the associated morbidity and mortality. We describe the first reported use of rapid ventricular pacing (RVP) assisted hypotension to control sudden intraoperative hemorrhage during intracranial aneurysm surgery where temporary arterial occlusion was not achievable.

Key words: Cerebral aneurysm, rapid ventricular pacing, adenosine

Introduction

Sudden intraoperative hemorrhage during intracranial aneurysm surgery from vascular injury or aneurysmal rupture has been known to dramatically increase the associated morbidity and mortality.^[1-4] We describe the first reported use of rapid ventricular pacing (RVP) assisted hypotension to control sudden intraoperative hemorrhage during intracranial aneurysm surgery where temporary arterial occlusion was not achievable.

Case Report

A 41-year-old female patient with a past history of subarachnoid hemorrhage with aneurysm clip ligation, multiple intracranial aneurysms, and substance abuse presented with increasingly severe right sided headaches. She underwent a cerebral angiogram, which revealed the presence of a 17.2 mm × 15.6 mm × 13.9 mm aneurysm in the right communicating segment of the internal carotid

artery (ICA) with a neck of 5.7 mm [Figure 1]. Further aneurysms identified included a right middle cerebral artery (MCA) bifurcation aneurysm (5.7 mm × 5.2 mm with a neck of 2.6 mm), a right anterior temporal artery aneurysm (3.9 mm × 3.7 mm with a neck of 2.4 mm), a bi-lobed left MCA bifurcation aneurysm (7.5 mm × 7.2 mm × 6.9 mm with a neck of 2.5 mm) and a left superior cerebellar artery aneurysm (5.4 mm × 5.2 mm with a neck of 3.2 mm). Due to the size of the largest aneurysm and the inaccessibility of many of the other aneurysms, a decision was made to proceed with an open craniotomy and clipping with intraoperative RVP. The patient after being informed of the risk and benefits of this technique consented for its use.

On the day of the operation, after placement of routine American Society of Anesthesiologists monitors and with invasive radial artery blood pressure monitoring, anesthesia was induced. Following, intubation of the airway, two additional large bore peripheral intravenous access catheters and a five French sheath was placed aseptically into the right internal jugular vein. An intravenous bipolar pacing catheter (Bipolar pacing catheter, Edwards Lifesciences, Irvine, CA) was inserted into the right ventricle through the five French sheath. Position of the pacing electrode was confirmed by the ability to adequate sense ventricular conduction and by the ability to override pace the ventricle. Test pacing was performed to determine thresholds using a temporary pacemaker (Model 5388 dual chamber temporary pacemaker; Medtronic, Inc., Minneapolis, MN, USA) set to Ventriculo-ventricle inhibition (VVI) mode. The patient underwent a right sided pterional craniotomy. The dissection through the planes was difficult due to extensive amounts of adhesions and friable vasculature.

Access this article online

Quick Response Code:



Website:

www.asianjns.org

DOI:

10.4103/1793-5482.131066

Address for correspondence:

Dr. Shariq Ali Khan, DUMC Box 3094, Durham, North Carolina 27710, USA. E-mail: shariq.ali.khan@sgh.com.sg

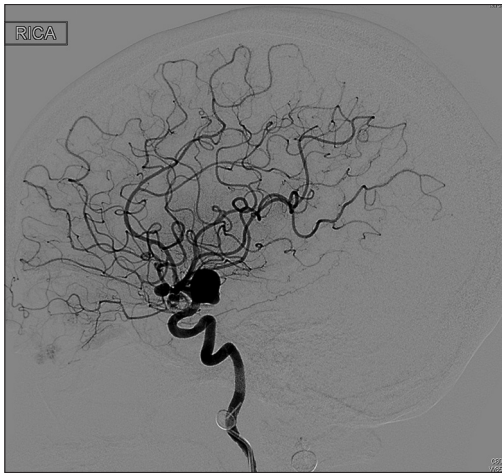


Figure 1: Digital subtraction angiogram of right anterior circulation (preoperative)

On adequate exposure of the large aneurysm at the right communicating segment of the ICA, the surgeon requested hypotension to decrease intra-aneurysmal turgor and allow clip placement. The patient was administered 100% oxygen, burst suppressed with propofol (guided by Bispectral index monitoring), and paced in VVI mode to 180 beats/min (bpm). There was an instantaneous fall in mean arterial blood pressure (MAP) from 80 to 40 mmHg. The surgeon was then able to place the clip to secure the aneurysm within 47 s of RVP at 180 bpm. As soon as the RVP was discontinued normal sinus rhythm was restored and the MAP recovered back to the baseline value of 75-80 mmHg. While attempting to decompress the clipped right communicating segment ICA aneurysm, a small tear developed on the ICA. Due to profuse hemorrhage, the surgical field was completely obscured, and temporary clipping to control the hemorrhage became impossible. A decision was made to institute RVP as a means to induce hypotension in order to clear the field. With an instantaneous drop in MAP to 35 mmHg with RVP, the surgical field cleared well enough to allow temporary clip placement on the injured ICA. RVP was discontinued (56 s) and there was a rapid recovery of MAP to baseline values. Following the arterial repair, a decision was made to secure only the aneurysms on the right anterior circulation and to secure the remaining in a subsequent setting. An intraoperative angiogram revealed well-secured aneurysms and adequate cerebral blood flow [Figure 2]. The patient was uneventfully extubated and transferred to the neurointensive care unit. The immediate neurological exam revealed no new neurological deficits. The patient was transferred to the ward the next day and discharged home 2 days later.

Discussion

Rapid ventricular pacing in cerebral aneurysms

The use of RVP in neurosurgery was first described in 1971 by Rovit in 13 patients (nine with aneurysms).^[5] More recently, there have been two reports of the use of RVP to facilitate aneurysm

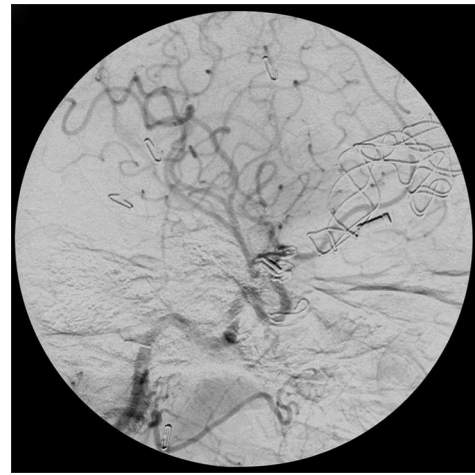


Figure 2: Digital subtraction angiogram of right anterior circulation (postoperative)

clipping without complications.^[6,7] Safety data from the use of RVP in cardiological procedures suggests that the complication rate is between 0% and 3%, with ventricular tachyarrhythmias being the most common reported complications which are usually reversed with override pacing or cardioversion.^[7-10]

Management of sudden intraoperative hemorrhage – Adenosine versus rapid ventricular pacing

A number of maneuvers have been recommended to control profound hemorrhage associated with such an event, including suction dissection of the aneurysm, coagulation of the aneurysmal rent, clip application to the distal sac, and temporary arterial occlusion.^[1,2] The success of many of these maneuvers depends largely on the ability of the surgeon to work in a bloodless field, which can be augmented by induction of intraoperative hypotension. Traditionally, hypotension in this situation is produced with pharmacological means with large doses of propofol, thiopentone, or adenosine.^[11] Although adenosine is a useful means to achieve this goal, it has considerable dose-response variability.^[12,13] In contrast, RVP induced hypotension has an almost “on-off” effect and predictable duration.^[5,7] Moreover, unlike adenosine, the consideration to use RVP is not affected by patient factors including allergies or medical conditions such as asthma and heart blocks.

Conclusion

We described the first use of RVP to induce hypotension in the face of sudden intraoperative hemorrhage which could not be controlled with conventional means during intracranial aneurysm surgery. We consider using RVP in patients with complex aneurysms where temporary clip placement is not feasible or high risk. Although, RVP has a more user-friendly profile than repeated boluses of adenosine, its use in patients with severe left ventricular dysfunction and coronary artery

disease may increase the risk of myocardial ischemia and ventricular arrhythmias.^[14]

References

- Batjer H, Samson D. Intraoperative aneurysmal rupture: Incidence, outcome, and suggestions for surgical management. *Neurosurgery* 1986;18:701-7.
- Batjer H, Samson DS. Management of intraoperative aneurysm rupture. *Clin Neurosurg* 1990;36:275-88.
- Chandler JP, Getch CC, Batjer HH. Intraoperative aneurysm rupture and complication avoidance. *Neurosurg Clin N Am* 1998;9:861-8.
- Giannotta SL, Oppenheimer JH, Levy ML, Zelman V. Management of intraoperative rupture of aneurysm without hypotension. *Neurosurgery* 1991;28:531-5.
- Rovit RL. Operative hypotension for intracranial vascular surgery using pacemaker-induced ventricular tachycardia. *J Neurosurg* 1971;35:51-8.
- Whiteley JR, Payne R, Rodriguez-Diaz C, Ellegala DB, Reeves ST. Rapid ventricular pacing: A novel technique to decrease cardiac output for giant basilar aneurysm surgery. *J Clin Anesth* 2012;24:656-8.
- Saldien V, Menovsky T, Rommens M, Van der Steen G, Van Loock K, Vermeersch G, *et al.* Rapid ventricular pacing for flow arrest during cerebrovascular surgery: Revival of an old concept. *Neurosurgery* 2012;70:270-5.
- Webb JG, Pasupati S, Achtem L, Thompson CR. Rapid pacing to facilitate transcatheter prosthetic heart valve implantation. *Catheter Cardiovasc Interv* 2006;68:199-204.
- Nashed G, French B, Gallagher D, Hopkins A, Juergens C, Leung D, *et al.* Right ventricular perforation with cardiac tamponade associated with use of a temporary pacing wire and abciximab during complex coronary angioplasty. *Catheter Cardiovasc Interv* 1999;48:388-9.
- Sack S, Kahlert P, Khandanpour S, Naber C, Philipp S, Möhlenkamp S, *et al.* Revival of an old method with new techniques: Balloon aortic valvuloplasty of the calcified aortic stenosis in the elderly. *Clin Res Cardiol* 2008;97:288-97.
- Nussbaum ES, Sebring LA, Ostanny I, Nelson WB. Transient cardiac standstill induced by adenosine in the management of intraoperative aneurysmal rupture: Technical case report. *Neurosurgery* 2000;47:240-3.
- Bebawy JF, Gupta DK, Bendok BR, Hemmer LB, Zeeni C, Avram MJ, *et al.* Adenosine-induced flow arrest to facilitate intracranial aneurysm clip ligation: Dose-response data and safety profile. *Anesth Analg* 2010;110:1406-11.
- Guinn NR, McDonagh DL, Borel CO, Wright DR, Zomorodi AR, Powers CJ, *et al.* Adenosine-induced transient asystole for intracranial aneurysm surgery: A retrospective review. *J Neurosurg Anesthesiol* 2011;23:35-40.
- Davidavicius G, Chieffo A, Shannon J, Arioli F, Ielasi A, Mussardo M, *et al.* A high dose of adenosine to induce transient asystole for valvuloplasty in patients undergoing transcatheter aortic valve implantation (TAVI): Is it a valid alternative to rapid pacing? A prospective pilot study. *J Invasive Cardiol* 2011;23:467-71.

How to cite this article: Khan SA, Berger M, Agrawal A, Huang M, Karikari I, Nimjee SM, *et al.* Rapid ventricular pacing assisted hypotension in the management of sudden intraoperative hemorrhage during cerebral aneurysm clipping. *Asian J Neurosurg* 2014;9:33-5.

Source of Support: Nil, **Conflict of Interest:** None declared.

Author Help: Reference checking facility

The manuscript system (www.journalonweb.com) allows the authors to check and verify the accuracy and style of references. The tool checks the references with PubMed as per a predefined style. Authors are encouraged to use this facility, before submitting articles to the journal.

- The style as well as bibliographic elements should be 100% accurate, to help get the references verified from the system. Even a single spelling error or addition of issue number/month of publication will lead to an error when verifying the reference.
- Example of a correct style
Sheahan P, O'leary G, Lee G, Fitzgibbon J. Cystic cervical metastases: Incidence and diagnosis using fine needle aspiration biopsy. *Otolaryngol Head Neck Surg* 2002;127:294-8.
- Only the references from journals indexed in PubMed will be checked.
- Enter each reference in new line, without a serial number.
- Add up to a maximum of 15 references at a time.
- If the reference is correct for its bibliographic elements and punctuations, it will be shown as CORRECT and a link to the correct article in PubMed will be given.
- If any of the bibliographic elements are missing, incorrect or extra (such as issue number), it will be shown as INCORRECT and link to possible articles in PubMed will be given.