

## Single Case

---

# Thinking Beyond Acute Kidney Injury

Emran El-Alali<sup>a</sup> Cesar Moreno<sup>b</sup> Emad Al Jaber<sup>c</sup>

<sup>a</sup>Department of Medicine, Anne Arundel Medical Center, Annapolis, MD, USA; <sup>b</sup>Department of Medicine, University of South Alabama, Mobile, AL, USA; <sup>c</sup>Division of Nephrology, Department of Medicine, University of South Alabama, Mobile, AL, USA

## Keywords

Obstructive uropathy · Retroperitoneal fibrosis · Breast cancer · Acute kidney injury

## Abstract

Acute kidney injury (AKI) can be a significant clue to solving a puzzling patient presentation. Postrenal AKI should be suspected if imaging shows any degree of hydronephrosis and can be caused by a variety of conditions. Diagnosis of urinary obstruction without significant dilatation of the pelvic-ureteral system requires a higher degree of suspicion, and hence, its identification can become late. In patients without prior cancer screening, the etiology of obstructive uropathy must be broadened to include primary or metastatic malignancy. Clinicians should look beyond the AKI to properly evaluate the etiology of the patient's presentation and symptoms. In this report, we present the case of a middle-aged female with no known past medical history who presented with AKI secondary to malignant retroperitoneal fibrosis as the first manifestation of metastatic breast cancer. Her AKI was associated with acute onset anuria and was found to have nondilated postrenal AKI with no significant abnormalities on renal imaging. Early onset anuria in the setting of AKI, which persists despite fluid resuscitation, can suggest complete urinary tract obstruction even with reassuring results of initial renal images, and in the patient with no history of cancer screening, malignancy should be suspected as a primary cause of obstructive uropathy.

© 2022 The Author(s).  
Published by S. Karger AG, Basel

## Introduction

Acute kidney injury is associated with poor clinical outcomes. It is commonly encountered in the inpatient setting, especially, in those who are critically ill. Etiologies of AKI can most often be attributed to prerenal and intrinsic causes. Nevertheless, postrenal etiologies

---

Correspondence to:  
Emran El-Alali, [emranalali@yahoo.com](mailto:emranalali@yahoo.com)

must be excluded as management of obstruction may ensure prompt renal function recovery. Renal ultrasonography is an important diagnostic tool to evaluate for obstruction and dilatation of the urinary tract in patients with azotemia [1]; however, nondilated obstructive uropathy (NDOU) has been reported. The differential diagnoses for post-obstructive uropathy leading to AKI include urolithiasis, malignancy, and retroperitoneal fibrosis (RPF); the latter can be idiopathic or associated with infections, malignancies, drugs, and radiation. RPF can be secondary to primary or metastatic malignancy including lymphoma; sarcoma; carcinoma of the breast, lung, stomach, colon, kidney, or prostate; and carcinoid tumor.

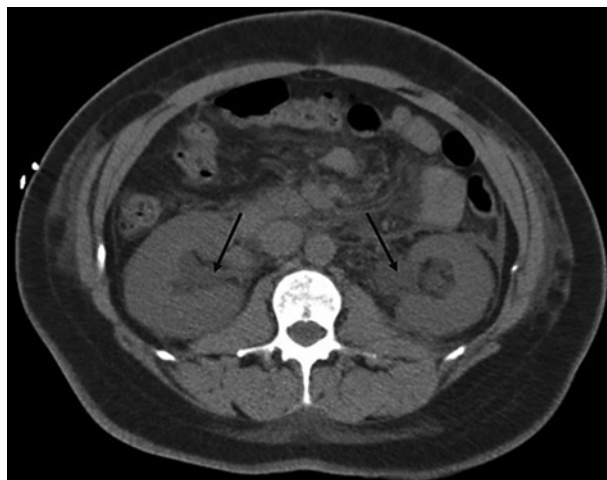
### Case Presentation

A 55-year-old female with no significant past medical history presented to the emergency department with a 3-week history of lower abdominal pain, shortness of breath, bilateral lower extremity swelling, and decreased urination. She denied any lower urinary tract symptoms. She does not take any medications and has history of no tobacco, alcohol, or illicit drug use. Physical examination showed periorbital swelling, bibasilar crackles, and +2 lower extremity pitting edema. Laboratory studies showed a blood urea nitrogen of 149 mg/dL and serum creatinine of 20.9 mg/dL (unknown baseline), and hemoglobin was 11 g/dL, and white blood cell count was 25,000/mm<sup>3</sup>. Urine analysis showed negative leukocyte esterase, 3–5 WBCs and 0–2 red blood cells per high power field, and squamous cells. The urine pregnancy test was negative. The remaining labs showed high anion gap metabolic acidosis, hyperkalemia, and hyperphosphatemia. The patient's urine output was approximately 100 mL in 24 h despite intravenous fluids use and a diuretic challenge.

Renal ultrasound showed normal size right kidney, left renal pelviectasis without evidence of left-sided hydronephrosis, normal parenchymal echogenicity, and no nephrolithiasis. Urology was consulted to evaluate for postrenal obstruction, and they were reluctant to be involved in the care of this patient without objective evidence of urinary obstruction. The patient's condition continued to deteriorate, requiring oxygen supplementation, and she was started on hemodialysis to relieve her volume overload, and profound acidemia not responsive to medical therapy. Because of the nonrevealing workup for AKI, a kidney biopsy was planned.

Based on the subtle signs of possible urinary obstruction seen on renal ultrasound, which showed left renal pelviectasis, the urology team was reconsulted to reevaluate the patient for potential obstruction. A cystoscopy and retrograde pyelogram were performed and showed evidence of extrinsic compression causing bilateral ureteral strictures. These features were concerning for RPF. After bilateral ureteral stents were placed, the immediate urine output was brisk, the patient's symptoms had rapidly resolved, and serum creatinine trended down to 2.1 mg/dL within 2 days. The plan for kidney biopsy was canceled since we knew it was a postrenal AKI based on the pyelogram findings, and computed tomography (CT) of the abdomen and pelvis was done to evaluate the cause of the ureteral compression which showed diffuse stranding within the retroperitoneum and edematous kidneys with mild hydronephrosis as in Figure 1, in addition to anasarca and moderate pleural effusions.

To establish the underlying etiology of the suspected RPF, CT-guided retroperitoneal biopsy was done. Final histopathology examination revealed fibroadipose tissue with poorly differentiated adenocarcinoma involving vascular spaces with nonspecific immunophenotyping. Oncology team was consulted. Positron emission tomography and CT showed a suspicious hypermetabolic left breast mass. A subsequent mammogram confirmed the presence of the mass, and biopsy showed invasive ductal carcinoma. The patient received one cycle of chemotherapy with Abraxane. The patient's clinical course was complicated by frequent hospitalizations



**Fig. 1.** CT abdomen depicts bilateral hydronephrosis and diffuse retroperitoneal stranding (arrows).

for symptomatic pleural effusions. She decided to pursue hospice care and passed away 4 months from time of presentation.

## Discussion

Our patient's presentation along with the initial imaging results did not strongly point to a possible urinary obstruction. Renal ultrasound showed only mild unilateral pelviectasis. Interestingly, cystoscopy and retrograde pyelogram revealed a significant degree of bilateral extrinsic compression of the proximal ureters requiring stents placement with subsequent improvement in renal infection. The external compression leading to renal entrapment most likely heralded a severe dilatation from occurring. The reason behind the patient's urinary obstruction was RPF secondary to metastatic breast cancer.

Renal ultrasonography has a high negative predictive value in ruling out urinary obstruction [2]; nevertheless, there have been several cases of NDOU in the literature, which represent 4–5% of obstructive uropathy, indicating the importance of retaining a high index of suspicion for postrenal etiologies despite the nonsignificant pelvic-ureteric dilatation found on ultrasound. Moreover, the majority of NDOU cases reviewed in the literature were secondary to malignant obstruction [3–12].

RPF secondary to metastatic breast cancer was the etiology for the obstructive uropathy in our patient. RPF is a rare condition characterized by the presence of fibro-inflammatory tissue in the retroperitoneum that is generally localized around the infrarenal portion of the abdominal aorta and the iliac arteries, often encasing the ureters or other abdominal organs, and it is part of the disease spectrum of peri-aortitis [13, 14]. Ureteral obstruction occurs in up to 80–100% of cases [13]. RPF is idiopathic in more than 70% of cases or can be secondary to drugs, malignancies, infections, radiation, or surgery [15–17].

Approximately 8% of cases of RPF are associated with malignancy. The mechanism that causes malignant RPF is not yet known. One theory describes a desmoplastic reaction in response to the presence of malignant cells in the retroperitoneum and reactive inflammation due to cytokines released by tumor cells [18].

Postrenal AKI due to obstructive uropathy as a first sign of metastatic breast cancer is exceedingly rare. A few cases in the literature were reviewed. Singh and Bhinder [19] described a case of NDOU as the first manifestation of metastatic breast cancer, whose initial ultrasonography showed bilateral pelviectasis with no discernible hydronephrosis, similar to our

patient's presentation. Patient expired in 6 weeks of diagnosis, indicating the dismal prognosis associated with this type of presentation.

In other cases, hydronephrosis with or without renal failure and oliguria was the presenting feature of metastatic breast cancer. In contrast to our patient and the cases described, malignant RPF with accompanying obstructive uropathy can appear years after breast cancer diagnosis [18, 20, 21]. The mean duration between the two conditions was more than 10 years in the 5 cases reported by Carloss and Saab [22].

Patients may present with nonspecific symptoms including abdominal fullness, flank pain, dysuria, palpable masses, hypertension, anuria [4], or symptoms of volume overload as in the patient described in this report. The clinical presentation depends on several factors including timing of the onset, degree of obstruction, and underlying comorbidities.

AKI is common among cancer patients. The evaluation of AKI in a patient with malignancy does not significantly differ from that of the general population. Both nephrologists and oncologists need to be aware of the unique causes of AKI in this population and its optimal management [23]. The initial workup of postrenal AKI includes imaging such as ultrasound to evaluate for hydronephrosis. If clinical suspicion is high and initial ultrasound is equivocal, CT or MRI may provide additional diagnostic detail. Imaging usually provides a diagnosis. False-negative imaging in the evaluation of obstructive uropathy may be due to hypovolemia, partial obstruction, or renal entrapment secondary to RPF causing obstruction [24]. Further diagnostic evaluations may include cystoscopy and retrograde pyelogram.

## Conclusion

This case highlights the importance of escalating diagnostic modalities in a patient with AKI and anuria. A good lesson we learned is that an early onset anuria in AKI is an important clue to obstructive pathology even if hydronephrosis is lacking or mild, and diagnosis of NDOU requires a high index of suspicion. Early urinary tract evaluation via cystoscopy and retrograde pyelogram may prove beneficial.

In a patient without prior history of cancer screening who presents with postrenal AKI, malignancy must be considered as a possible cause of obstructive uropathy. Primary or metastatic malignant processes may lead to extrinsic compression of the urinary system. This case emphasizes the importance of routine breast cancer screening in marginalized populations without regular access to routine care. In summary, clinicians should look beyond the AKI to ensure proper evaluation and treatment of the undifferentiated patient.

## Statement of Ethics

The need for ethics approval and consent is waived by the Anne Arundel Medical Center (AAMC) Clinical Research Committee. AAMC Clinical Research Committee director: Erika Siegrist MS, RN, ACRP-CP, phone: +1 (443) 4811320, e-mail: esiegrist@aaahs.org. A written informed consent was obtained from the patient for publication of this case report and any accompanying images, prior to their expiration. A copy of the written consent is available for review by the Editor of this journal.

## Conflict of Interest Statement

The authors have no conflicts of interest to declare.

### Funding Sources

No grant support, funding, or writing assistance were provided to assist in this manuscript preparation.

### Author Contribution

E.E.-A. contributed to the conception of the manuscript; acquisition and analysis of data; drafting, editing, and critically revising the manuscript and performed the literature search, final approval of the work, and agreed to be accountable for all aspects of the work. C.M. contributed to the design of manuscript; revised and edited the manuscript; assisted in literature review and final approval of the work; and agreed to be accountable for the work. E.A. contributed to the design of manuscript; critically revised and edited the manuscript; and assisted in literature review and final approval of the work; and agreed to be accountable for the work.

### Data Availability Statement

All data generated or analyzed during this case report are included in this article. Further inquiries can be directed to the corresponding author.

### References

- 1 Khati NJ, Hill MC, Kimmel PL. The role of ultrasound in renal insufficiency: the essentials. *Ultrasound Q*. 2005;21:227.
- 2 Ellenbogen PH, Scheible FW, Talner LB, Leopold GR. Sensitivity of gray scale ultrasound in detecting urinary tract obstruction. *AJR Am J Roentgenol*. 1978;130:731.
- 3 Onuigbo MA, Lawrence K, Onuigbo NT. Non-dilated obstructive uropathy - an unrecognized cause of acute renal failure in hospitalized US patients: three case reports seen over 6 months in a northwestern Wisconsin nephrology practice. *Ren Fail*. 2010;32:1226.
- 4 Mohidin B, Bass P, Salama A, Hamour S. Malignant renal obstruction without dilatation. *Acute Med*. 2019;18:121.
- 5 Kulkarni S, Jayachandran M, Davies A, Mamoun W, Al-Akraa M. Non-dilated obstructed pelvicalyceal system. *Int J Clin Pract*. 2005;59:992.
- 6 Somerville CA, Chmiel R, Niall JF, Murphy BF. Non-dilated urinary tract obstruction. *Med J Aust*. 1992;156:721.
- 7 Kocurek JN, Orihuela E, Saltzstein DR. Nondilated obstructive uropathy and renal failure as a result of carcinoma of the intrapelvic area. *Surg Gynecol Obstet*. 1991;173:470–2.
- 8 Charasse C, Camus C, Darnault P, Guillé F, le Tulzo Y, Zimbacca F, et al. Acute nondilated anuric obstructive nephropathy on echography: difficult diagnosis in the intensive care unit. *Intensive Care Med*. 1991;17(7):387–91.
- 9 Spector DA, Katz RS, Fuller H, Cristiano LM, Vitalis S, Jarrow J. Acute non-dilating obstructive renal failure in a patient with AIDS. *Am J Nephrol*. 1989;9:129.
- 10 Spital A, Valvo JR, Segal AJ. Nondilated obstructive uropathy. *Urology*. 1988;31:478.
- 11 Maillet PJ, Pelle-Francoz D, Laville M, Gay F, Pinet A. Nondilated obstructive acute renal failure: diagnostic procedures and therapeutic management. *Radiology*. 1986;160:659.
- 12 Rascoff JH, Golden RA, Spinowitz BS, Charytan C. Nondilated obstructive nephropathy. *Arch Intern Med*. 1983;143:696.
- 13 Shiber S, Eliakim-Raz N, Yair M. Retroperitoneal fibrosis: case series of five patients and review of the literature. *Rev Bras Reumatol Engl Ed*. 2016;56:101.
- 14 Vaglio A, Buzio C. Chronic periaortitis: a spectrum of diseases. *Curr Opin Rheumatol*. 2005;17:34–40.
- 15 Gilkeson GS, Allen NB. Retroperitoneal fibrosis. A true connective tissue disease. *Rheum Dis Clin North Am*. 1996;22:23.
- 16 van Bommel EF, Jansen I, Hendriksz TR, Aarnoudse AL. Idiopathic retroperitoneal fibrosis: prospective evaluation of incidence and clinicoradiologic presentation. *Medicine*. 2009;88:193.
- 17 Gómez RJ, Quintana LM, Álvarez-Maestro M, Aguilera A, Martínez Piñeiro L, Sarikaya S. Retroperitoneal fibrosis: a literature review. *Arch Esp Urol*. 2020;73(1):60–7.

- 18 Vega J, Ceriani A, Jensen D. Retroperitoneal fibrosis associated with malignancies: report of eight cases. [Rev Med Chil](#). 2014;142:791.
- 19 Singh N, Bhinder A. Metastatic retroperitoneal fibrosis as first sign of breast cancer. [Int J Case Rep Imag](#). 2012; 3(6):23–5.
- 20 Gogas J, Markopoulos C, Kouskos E, Gogas H, Kiriakou V. Metastatic retroperitoneal and mediastinal fibrosis as first sign of recurrence of breast cancer. [Eur J Surg](#). 2001;167:715.
- 21 Srinivas V, Dow D. Retroperitoneal fibrosis with azotaemia secondary to metastatic breast cancer. [Br J Urol](#). 1986;58:231.
- 22 Carloss H, Saab G. Breast cancer and retroperitoneal metastasis. [South Med J](#). 1980;73:1570.
- 23 Lam AQ, Humphreys BD. Onco-nephrology. AKI in the cancer patient. [Clin J Am Soc Nephrol](#). 2012;7:1692.
- 24 César BN, Durão Júnior MS. Acute kidney injury in cancer patients. [Rev Assoc Med Bras](#). 2020;66(Suppl 1):s25–30.