

# Coronary artery aneurysm formation after drug-coated balloon treatment of de novo lesions

## Two case reports

Hui-Ping Zhang, MD, PhD, Xue Yu, MD, Fu-Sui Ji, MD, Fu-Cheng Sun, MD\*

### Abstract

**Rationale:** The safety and efficacy of drug-coated balloon (DCB) technology have primarily been proven in the treatment of coronary in-stent restenosis. Whereas increasing evidences show that DCB use was feasible in certain de novo coronary lesions. In 2012, Vassilev reported the 1st case in which a coronary aneurysm formed after a DCB was used to treat drug-eluting stent (DES) restenosis. To date, limited information has been reported on coronary artery aneurysm (CAA) development following DCB treatment of de novo lesions.

**Patient concerns:** A 42-year-old male underwent delayed coronary angiography due to extensive anterior wall myocardial infarction. After balloon predilation in the mid-left anterior descending (LAD) artery, the residual 30% stenosis without major dissection was treated with a DCB. Angiographic follow-up at 6 and 12 months revealed an aneurysm in the treated area of the LAD artery, with positive vascular remodeling behind this aneurysm. A 54-year-old male with nonstent thrombosis elevation myocardial infarction underwent elective catheterization. Coronary angiography revealed critical stenosis in the LAD and significant narrowing at the distal segments of both the left circumflex artery (LCX) and the nondominant right coronary artery. After predilation of the lesion in the LCX, the residual 30% stenosis was treated with a DCB. The lesion in the LAD was treated with a DCB either. Angiography follow-up at 6 months revealed good results in the LAD; however, an aneurysm was observed in the DCB-treated area of the LCX.

**Diagnosis:** The CAA formation after DCB treatment of de novo lesions.

**Interventions and outcomes:** Because the 2 patients were asymptomatic upon diagnosis, the aneurysms were left untreated. Long-term dual antiplatelet therapy and intense follow-up were recommended.

**Lessons:** Our cases raise questions regarding the safety of DCB treatment for de novo lesions in real-world contexts. There might be a need to clarify the appropriate doses for drugs coated on DCBs. Although indications for DCB treatment for de novo coronary lesions should not be overly aggressively broadened, the potential role of such treatment in this context merits additional elucidation in future studies.

**Abbreviations:** CAA = coronary artery aneurysm, CAD = coronary artery disease, DAPT = dual antiplatelet therapy, DCB = drug-coated balloon, DES = drug-eluting stent, IVUS = intravascular ultrasound, LAD = left anterior descending, ST = stent thrombosis.

**Keywords:** coronary aneurysm, de novo lesions, drug-coated balloon

Editor: N/A.

The case report was approved by the institutional ethics committee. The 2 patients signed ethics approval and informed consent to undergo coronary angiography and intervention procedure.

Consents for publication were obtained from the 2 patients.

All data analyzed during this case report are available from the corresponding author on reasonable request.

The authors have no funding and conflicts of interest to disclose.

Department of Cardiology, Beijing Hospital, National Center of Gerontology, Dong Dan, Beijing, China.

\* Correspondence: Fu-Cheng Sun, Department of Cardiology, Beijing Hospital, National Center of Gerontology, No 1 DaHua Road, Dong Dan, Beijing 100730, China (e-mail: sunfucheng170512@163.com).

Copyright © 2018 the Author(s). Published by Wolters Kluwer Health, Inc. This is an open access article distributed under the terms of the Creative Commons Attribution-Non Commercial-No Derivatives License 4.0 (CCBY-NC-ND), where it is permissible to download and share the work provided it is properly cited. The work cannot be changed in any way or used commercially without permission from the journal.

Medicine (2018) 97:45(e13208)

Received: 11 July 2018 / Accepted: 18 October 2018

<http://dx.doi.org/10.1097/MD.0000000000013208>

### Established facts

- Already known fact 1: The safety and efficacy of drug-coated balloon (DCB) technology have primarily been proven in the treatment of coronary in-stent restenosis.
- Already known fact 2: A coronary aneurysm occasionally could be observed after a DCB was used to treat stents restenosis.
- Already known fact 3: Increasing evidences show that DCB use was feasible in certain de novo coronary lesions.

### Novel insights

- New information 1: Coronary artery aneurysm (CAA) formation after DCB treatment of de novo lesions might be not a rare situation.
- New information 2: The safety of DCB treatment for de novo lesions in real-world contexts merits additional elucidation in future.

## 1. Introduction

Drug-coated balloons (DCBs) have emerging applications in percutaneous coronary intervention. They circumvent certain limitations of drug-eluting stents (DESs), such as stent thrombosis (ST), the need for prolonged dual antiplatelet therapy (DAPT) and bleeding risks associated with prolonged DAPT.<sup>[1,2]</sup> The safety and efficacy of DCB technology have primarily been proven in the treatment of coronary in-stent restenosis.<sup>[3]</sup> At present, bare-metal stent in-stent restenosis and DES in-stent restenosis are the only approved indications for DCB use in the Chinese and European guidelines.<sup>[4,5]</sup> Although studies have provided increasing evidence that DCB use is feasible for certain de novo coronary lesions, these studies have primarily focused on the treatment of small-vessel coronary artery disease (CAD) or on DCB use as part of a treatment strategy for bifurcation lesions.<sup>[2,6,7]</sup>

During the DES era, the formation of a coronary artery aneurysm (CAA) has been relatively rare, with a reported incidence of 0.2% to 2.3% after 1st-generation DES implantation.<sup>[8]</sup> Although most patients with a CAA are asymptomatic, certain rare adverse events resulting from thrombosis, such as myocardial infarction and even cardiac death, can occasionally be observed.<sup>[9]</sup> In 2012, Vassilev reported the 1st case in which a coronary aneurysm formed after a DCB was used to treat DES restenosis.<sup>[10]</sup> To date, limited information has been reported on CAA development following DCB treatment of de novo lesions. Here, we report 2 cases involving CAA formation after DCB treatment of a de novo coronary lesion.

## 2. Case reports

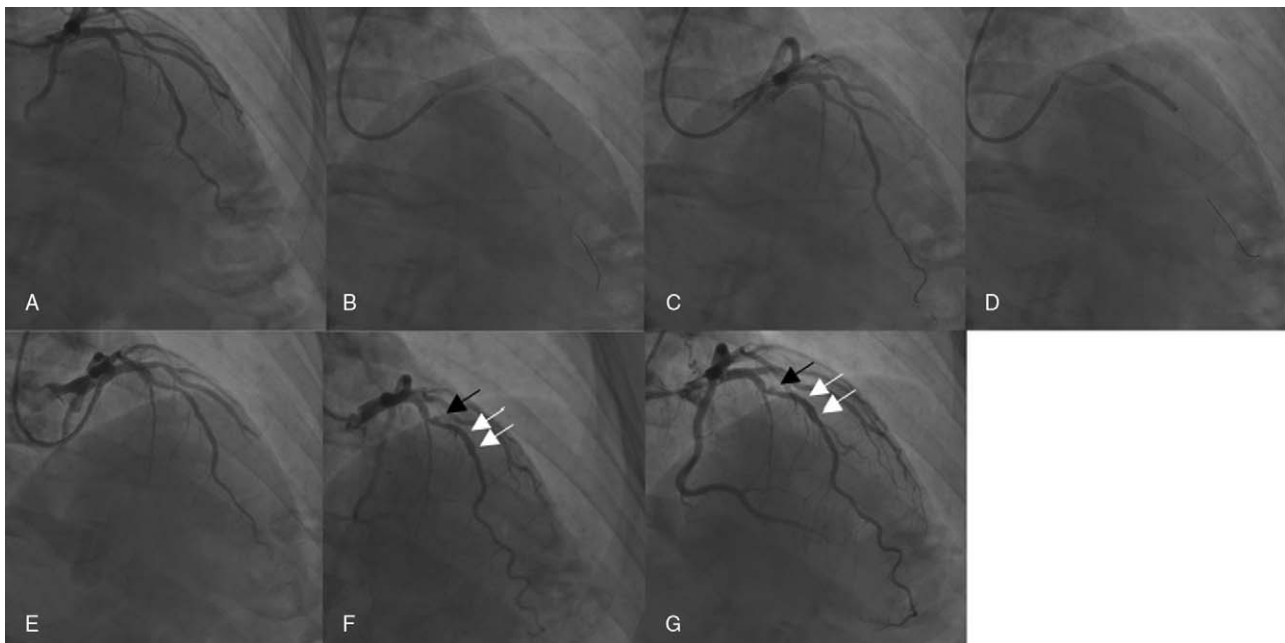
### 2.1. Case 1

A male, 42-year-old active smoker with the CAD risk factor of dyslipidemia (who was on statin treatment) was admitted to our

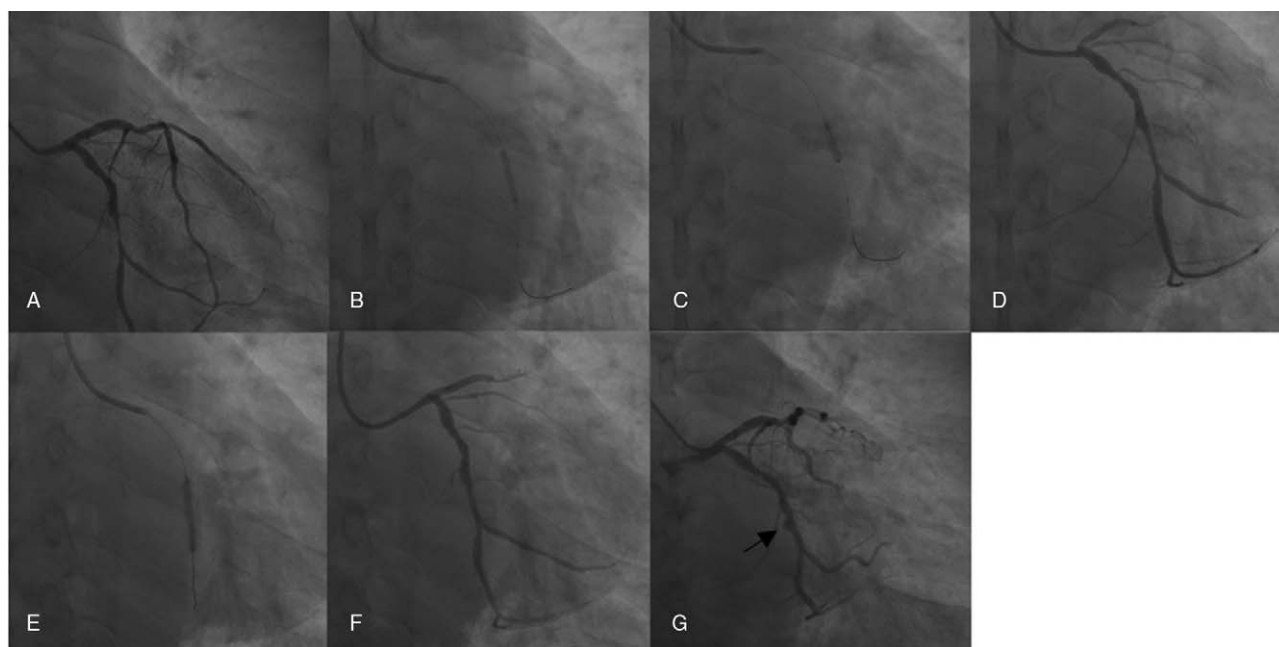
department due to extensive anterior wall myocardial infarction that had been diagnosed one month ago, prior to his hospitalization. He had not received coronary reperfusion therapy before admission. Coronary angiography revealed significant narrowing in the mid-left anterior descending (LAD) artery (Fig. 1A). After predilation with a 2.5- to 20-mm balloon at 16 atm, the residual 30% stenosis without major dissection was considered to be acceptable (Fig. 1B and C). A DCB (SeQuent Please 3.5–26 mm; B Braun Melsungen AG, Berlin, Germany) was inflated at 10 atm for 50 s (Fig. 1D). Good final results appeared to have been achieved (Fig. 1E), and the patient was scheduled for routine follow-up. He was completely asymptomatic and in good physical condition after the procedure. Angiographic follow-up at 6 months revealed an aneurysm in the treated area of the LAD, with slight positive vascular remodeling behind this aneurysm (Fig. 1F). The patient continued to receive DAPT (aspirin 100 mg and clopidogrel 75 mg) and was scheduled for angiography follow-up in 12 months for further evaluation of the aneurysm. This angiography follow-up demonstrated that the coronary aneurysm remained visible in the treated area, with apparent positive vascular remodeling behind the aneurysm (Fig. 1G). Given the potential risk of coronary thrombosis, we decided to indefinitely maintain DAPT for the patient.

### 2.2. Case 2

A 54-year-old male with a history of hypertension and chronic kidney disease presented with non-ST elevation myocardial infarction and acute heart failure and was admitted to our department. After the patient's condition was stabilized and optimal medical treatment was administered, elective catheterization was performed. Coronary angiography revealed disease in



**Figure 1.** (A–E) Initial angiography, April 2015. (A) A significant narrowing in the middle segment of the left anterior descending (LAD) (RAO cranial view). (B) Predilation balloon inflation in the LAD (AP cranial view). (C) Pretreatment results for the LAD that revealed residual stenosis (of approximately 30%) (AP cranial view). (D) B Braun Sequent Please balloon inflation in the LAD (AP cranial view). (E) Final results in the LAD (RAO view). (F) Angiography from October 2015: A coronary aneurysm (black arrow) has appeared in the drug-coated balloon (DCB)-treated area of the LAD, with slight positive vascular remodeling behind the aneurysm (white arrow) (RAO cranial view). (G) Angiography from April 2016: The coronary aneurysm could still be observed (black arrow) in the DCB-treated area of the LAD, with apparent positive vascular remodeling behind the aneurysm (white arrow) (RAO view).



**Figure 2.** (A–F) Initial angiography, April 2017. (A) A severe stenosis in the distal segment of the left circumflex artery (LCX) (AP caudal view). (B) Predilation balloon inflation in the LCX (AP caudal view). (C) Cutting balloon inflation in the LCX (AP caudal view). (D) Pretreatment results for the LCX that revealed residual stenosis (of approximately 50%) (AP caudal view). (E) B Braun Sequent Please balloon inflation in the LCX (AP caudal view). (F) Final results in the LCX (AP view). (G) Angiography from December 2017: A coronary aneurysm (black arrow) has appeared in the drug-coated balloon (DCB)-treated area of the LCX (AP caudal view).

3 vessels, with critical stenosis in the LAD coronary artery and significant narrowing at the distal segments of both the left circumflex artery (LCX) (Fig. 2A) and the right coronary artery (RCA). Because the diameter of the distal RCA was relatively small, we left the RCA untreated. After predilation of the lesion in the LCX with a 2.5- to 15-mm balloon at 12 atm and a cutting balloon (3.0–10 mm) at 12 atm (Fig. 2B and C), the residual 30% stenosis was treated with a DCB (SeQuent Please 3.0–20 mm; B Braun Melsungen AG) inflated at 10 atm for 50 seconds (Fig. 2D and E). The final results for the LCX after DCB use appeared to be acceptable (Fig. 2F). After predilation with a 2.5- to 15-mm balloon at 14 atm and a cutting balloon (3.0–10 mm) at 12 atm, the lesion in the LAD was treated with a DCB (SeQuent Please 3.0–20 mm; B Braun Melsungen AG) with good results (not shown). After the procedure, the patient's hospital stay was uneventful, and standard medical therapy was continued after discharge. Angiography follow-up at 6 months revealed good results in the LAD artery; however, an aneurysm was observed in the DCB-treated area of the LCX artery (Fig. 2G). Although the patient was asymptomatic, long-term DAPT and intense follow-up were recommended.

### 3. Discussion

The development of a CAA after coronary intervention is considered to be a rare complication, particularly after DES implantation. A true CAA is defined as a luminal dilation to 50% larger than the adjacent reference segment on angiography.<sup>[11]</sup> When coronary intervention-associated aneurysms are evaluated using intravascular ultrasound (IVUS), luminal dilation typically involves all layers of the vessel wall, including the external elastic membrane.<sup>[12]</sup> Coronary aneurysms can potentially be caused by mechanical effects induced by stent implantation, such as over-stent strut stretch, and by residual dissections. Other mechanisms

can contribute to the formation of CAAs after DES implantation, including delayed reendothelialization and incomplete healing secondary to the antiproliferative action of the eluted drug; inflammatory changes of the medial wall; and hypersensitivity reactions to the drug/polymer mixture on the DES.<sup>[13,14]</sup> Late-acquired malapposition resulting from positive vascular remodeling and/or dissolution of the thrombus might be another mechanism underlying CAA formation.<sup>[15]</sup>

The development of an aneurysm after DCB treatment of DES restenosis may slightly differ from CAA formation after DES implantation. A high concentration of an antirestenotic drug powerfully induces cell apoptosis, which, likely in combination with repetitive mechanical trauma from the use of oversized balloons or high-pressure balloon predilation procedures, promotes aneurysm formation.<sup>[10]</sup> We assume that CAA formation after DCB treatment of de novo lesions has similar mechanisms. In general, whichever inflation pressure and the time were used according to the DCB's instructions for use, the recommended inflation pressure of the DCB should not be exceeded. Depending on patient situation and vessel morphology, the inflation should be kept for a period of at least 30 seconds. In our 2 cases in which a paclitaxel-coated balloon was used to treat de novo lesions, the DCB was inflated for a relatively long period of 50 seconds at 10 atm, above the nominal pressure of 7 atm. Due to the high concentration and rapid local release of the eluted drug, the regional tissue concentration of the DCB-administered drug, dosage of paclitaxel 3  $\mu\text{g}/\text{mm}^2$ , was nearly 100 times larger than that produced by a DES, thus worsening the incomplete healing and inflammatory processes secondary to the detrimental effects of this drug. Regional positive vascular remodeling may also have been involved in the described situations.

In general, coronary aneurysms are detected at the time of repeated angiography for recurrent symptoms or as part of

routine angiographic follow-up. In 1 study, patients with DES-associated CAA, as revealed by IVUS, were usually asymptomatic and had relatively benign clinical outcomes.<sup>[8]</sup> However, CAA formation after DES implantation is occasionally associated with adverse events resulting from ST.<sup>[9]</sup> The clinical implications of CAA development after DCB treatment of de novo lesions remain unclear. Given the turbulent and sluggish flow near the aneurysm, patients with CAA that developed after DCB treatment of de novo lesions may be at increased risk for adverse events, such as thrombosis or distal embolism. In such situations, we propose that long-term DAPT should be considered to reduce the risk of thrombosis. With respect to the limited published data on the management of CAA formation after DCB treatment of de novo lesions, various therapeutic strategies, including the use of stent grafts, coils, or surgical treatment, remain controversial. Treatment options should be individualized depending on the aneurysm's location, its volumetric size, the speed of progression of the CAA and the combination of the patient's symptoms. For patients with CAA, intense clinical follow-up is needed. Given the increased risk of thrombosis, late angiography or computed tomography angiography should be considered to detect delayed development or progression of the aneurysm. The patients in our 2 cases were asymptomatic, and their aneurysms were relatively small, less than 2 times the diameter of the reference vessel. Therefore, we maintained medical therapy for these patients, including long-term DAPT, and continued closely following them.

#### 4. Conclusion

Our cases raise questions regarding the safety of DCB treatment for de novo lesions in real-world contexts. To date, although there is promising evidence for the efficacy and safety of DCB treatment for certain de novo coronary lesions, current evidence does not support the superiority, or even equivalence, of DCB treatment relative to DES treatment. There might be a need to clarify the appropriate doses for drugs coated on DCBs. Although indications for DCB treatment for de novo coronary lesions should not be overly aggressively broadened, the potential role of such treatment in this context merits additional elucidation in future studies.

#### Author contributions

**Acquisition of data:** H-PZ, X-YW, XY.

**Analysis and interpretation of cases:** H-PZ, XY, F-CS.

**Case report supervision:** FX, F-CS, F-SJ.

**Conceptualization:** Hui-Ping Zhang, Xue Yu, Fu-Cheng Sun.

**Data curation:** Hui-Ping Zhang, Xue Yu.

**Formal analysis:** Xue Yu.

**Investigation:** Hui-Ping Zhang, Xue Yu.

**Question raised:** H-PZ, X-YW, XY.

**Supervision:** Xue Yu, Fu-Sui Ji, Fu-Cheng Sun.

**Writing – original draft:** Hui-Ping Zhang, Xue Yu.

**Writing – review & editing:** Hui-Ping Zhang, Xue Yu, Fu-Sui Ji, Fu-Cheng Sun.

**Writing, review, and/or revision of the manuscript:** H-PZ, W-DZ, XY.

All authors read and approved the final manuscript.

#### References

- [1] Camenzind E, Steg PG, Wijns W. Stent thrombosis late after implantation of first-generation drug-eluting stents: a cause for concern. *Circulation* 2007;115:1440–55.
- [2] Loh JP, Waksman R. Paclitaxel drug-coated balloons. A review of current status and emerging applications in native coronary artery de novo lesions. *J Am Coll Cardiovasc Interv* 2010;5:1001–12.
- [3] Rittger H, Brachmann J, Sinha AM, et al. A randomized, multicenter, single-blinded trial comparing paclitaxel-coated balloon angioplasty with plain balloon angioplasty in drug-eluting stent restenosis: the PEPACAD-DES study. *J Am Coll Cardiol* 2012;59:1377–82.
- [4] Section of Interventional Cardiology of Chinese Society of Cardiology of Chinese Medical Association; Specialty Committee on Prevention and Treatment of Thrombosis of Chinese College of Cardiovascular Physicians; Editorial Board of Chinese Journal of Cardiology Section of Interventional Cardiology of Chinese Society of Cardiology of Chinese Medical Association; Specialty Committee on Prevention and Treatment of Thrombosis of Chinese College of Cardiovascular Physicians; Editorial Board of Chinese Journal of Cardiology Chinese guideline for percutaneous coronary intervention [in Chinese]. *Zhonghua Xin Xue Guan Bing Za Zhi* 2016;44:382–400.
- [5] Windecker S, Kolh P, Alfonso F, et al. 2014 ESC/EACTS Guidelines on myocardial revascularization. *Eur Heart J* 2014;35:2541–619.
- [6] Latib A, Colombo A, Castriota F, et al. A randomized multicenter study comparing a paclitaxel drug-eluting balloon with a paclitaxel-eluting stent in small coronary vessels. The BELLO (Balloon Elution and Late Loss Optimization) Study. *J Am Coll Cardiol* 2012;60:2473–80.
- [7] Mathey DG, Wendig I, Boxberger M, et al. Treatment of bifurcation lesions with a drug-eluting balloon: the PEPACAD V (paclitaxel eluting PTCA balloon in coronary artery disease) trial. *EuroIntervention* 2011;7:K61–5.
- [8] Alfonso F, Perez-Vizcayno MJ, Ruiz M, et al. Coronary aneurysms after drug-eluting stent implantation: clinical, angiographic, and intravascular ultrasound findings. *J Am Coll Cardiol* 2009;53:2053–60.
- [9] Kim U, Seol SH, Kim DI, et al. Clinical outcomes and the risk factors of coronary artery aneurysms that developed after drug-eluting stent implantation. *Circ J* 2011;75:861–7.
- [10] Vassilev D, Hazan M, Dean L. Aneurysm formation after drug-eluting balloon treatment of drug-eluting in-stent restenosis: first case report. *Catheter Cardiovasc Interv* 2012;80:1223–6.
- [11] Demopoulos VP, Olympios CD, Fakiolas CN, et al. The natural history of aneurysmal coronary artery disease. *Heart* 1997;78:136–41.
- [12] Porto I, MacDonald S, Banning AP. Intravascular ultrasound as a significant tool for diagnosis and management of coronary aneurysms. *Cardiovasc Intervent Radiol* 2004;27:666–8.
- [13] Luscher TF, Steffel J, Eberli FR, et al. Drug-eluting stent and coronary thrombosis: biological mechanisms and clinical implications. *Circulation* 2007;115:1051–8.
- [14] Finn AV, Nakazawa G, Joner M, et al. Vascular responses to drug eluting stents: importance of delayed healing. *Arterioscler Thromb Vasc Biol* 2007;27:1500–10.
- [15] Hur SH, Ako J, Honda Y, et al. Late-acquired incomplete stent apposition: morphologic characterization. *Cardiovasc Revasc Med* 2009;10:234–46.