

Multi-axial correction system in the treatment of radial club hand

Suneel B. Bhat · Atul F. Kamath · Kriti Sehgal ·
B. David Horn · Harish S. Hosalkar

Received: 27 April 2009 / Accepted: 6 August 2009 / Published online: 4 September 2009
© The Author(s) 2009. This article is published with open access at Springerlink.com

Abstract

Background Radial club hand is a well-recognized congenital malformation characterized by hypoplasia of bone and soft tissue on the radial aspect of the forearm and hand. The modalities of treatment have traditionally varied from stretching casts with soft-tissue procedures to the use of multiple corrective osteotomies. These osteotomies can be stabilized by a variety of methods, including external fixators that allow the possibility of gradual distraction with neohistogenesis. This current study outlines the usage of one such device (multi-axial correction system [MAC]) in the management of deformity associated with severe radial club hand.

Methods Three consecutive cases of unilateral or bilateral severe (Bayne type IV) congenital radial club hand were corrected using MAC fixation in the last 5 years. This is a retrospective review of all three cases. Data parameters included: patient demographics, presentation findings,

degree of deformity, amount of correction/lengthening, length of procedure, length of treatment, and associated complications. The surgical technique is described in detail for the benefit of the readership.

Results The three patients with severe congenital radial club hand had a total of four limb involvements that underwent correction using osteotomies and usage of the MAC device for external fixation. All three patients underwent successful correction of deformity with the restoration of alignment, lengthening of forearm for improvement of function, and stabilization of the wrist (mean duration, mean lengthening, mean time to consolidation). The MAC system was well tolerated in all patients and associated complications were limited.

Conclusion The MAC fixator seems to be a good alternative modality of stabilization and correction for severe congenital radial club hand deformities. Its usage is fairly simple and it provides the ease of application of a mono-lateral fixator with far superior three-dimensional control, like the circular external fixator. We recommend that clinicians should add this modality to their armamentarium for the deformity correction of severe radial club hand and others in general.

S. B. Bhat · K. Sehgal · B. D. Horn
Division of Pediatric Orthopaedic Surgery, The Children's
Hospital of Philadelphia, 34th Street and Civic Center
Boulevard, Philadelphia, PA 19104, USA

S. B. Bhat
University of Pennsylvania School of Medicine,
Philadelphia, PA 19104, USA

A. F. Kamath
Department of Orthopaedic Surgery, Hospital of the University
of Pennsylvania, 34th and Spruce Streets, 2nd Floor,
Silverstein Building, Philadelphia, PA 19104, USA

H. S. Hosalkar (✉)
Department of Orthopaedic Surgery, Rady Children's Hospital,
UCSD, 3030 Children's Way, Suite 410,
San Diego, CA 92123, USA
e-mail: hhosalkar@rchsd.org

Keywords MAC fixator · Radial club hand ·
Multi-axial correction system

Introduction

Longitudinal radial deficiency, or radial club hand, encompasses a collection of congenital deformities characterized by hypoplasia of bones, joints, muscles, tendons, ligaments, nerves, and vasculature on the radial aspect of the forearm [1, 2]. Radial club hand is a rare condition,

occurring in approximately 1 in every 30,000 live births, with a slightly increased incidence in males. The anomaly occurs bilaterally 50% of the time, and is frequently asymmetrical [3]. Most cases of radial deficiency are sporadic, and they are commonly associated with a number of congenital syndromes: thrombocytopenia absent radius (TAR) syndrome; vertebral defects, anal atresia, cardiac malformation, tracheoesophageal fistula, esophageal atresia, renal anomalies, and limb anomalies (VACTERL); Fanconi's anemia; Holt-Oram syndrome; and trisomies 13 and 18 [1, 4].

Clinically, the radial club hand spectrum is classifiable by severity into one of four types based on the degree of radius present (as described by Bayne and Klug [5]) or by a modified scheme that grades thumb, carpal, and radius deficiencies in summation [2, 5]. The treatment of radial club hand varies considerably with the extent of the deformity and the age of the patient. Mild cases of Bayne type I may be sufficiently treated by stretching and splinting. More severe cases may require preliminary soft tissue distraction and tendon transfer to rebalance the wrist [6–10], followed by surgical centralization of the wrist on the ulna and tendon transfer to rebalance the wrist [11–13]. Subsequent ulnar lengthening and angular correction may be performed, particularly in the case of failed soft tissue surgery, progressive angular deformity, or inadequate functional length; these procedures are preferable at early adolescence, where an external fixator can be tolerated and treatment does not interfere with psychosocial development [14–20].

Forearm lengthening and subsequent deformity corrections have, for the most part, been approached with gradual distraction using the Ilizarov technique involving a circular external fixator. Although successful in producing multi-planar deformity correction and an approximately 50% increase in ulnar length, the Ilizarov technique brings with it a steep clinician learning curve. Device application, cumbersome hardware, lengthy total treatment time, and relatively high risk of complications may prove problematic and have effectively limited the use of the device to adolescents and older [14, 16–20].

The multi-axial correction (MAC) system (Biomet, Parsippany, NJ) is an external fixator capable of gradual or acute correction, as well as tri-planar angulation, translational, rotational, and length deformity correction that overcomes many of the issues faced by the traditional Ilizarov technique; this approach is particularly suited for angularity and length correction in early adolescents with previous failed soft tissue procedures. In this report, we describe a series of three cases (previously presented at the 2007 Pediatric Orthopaedic Society of North America [POSNA] Conference) of severe radial club hand in which

the MAC fixation system was used to achieve successful deformity resolution and ulnar lengthening.

Methods

After obtaining institutional review board (IRB) approval, the surgical database of a senior surgeon at the Children's Hospital of Philadelphia was reviewed retrospectively from 2003 to 2008 to identify patients with congenital radial club hand that underwent treatment. Patients were included in the study if they had either unilateral or bilateral Bayne type IV congenital radial club hand, were less than 18 years old at the time of surgery, had adequate clinical and radiographic data, and underwent treatment using the MAC fixation system. Exclusion criteria included age and prior trauma to the affected extremity. Three cases that met the inclusion criteria were selected for further evaluation; all patients were consecutive cases of radial club hand and were all operated on by the same attending physician. Data collected included patient information, history of the condition, degree of deformity, amount of correction/lengthening, duration of procedure, duration of treatment, and complications. Complications were defined as neurovascular injury, infection requiring antibiotics, over-correction, under-correction, delayed union of osteotomy, non-union of osteotomy, device failure, and any intra-operative problems encountered.

Operative technique

The MAC fixation system is a monolateral external fixator capable of multi-axial correction. The central component consists of two hinges and two translators at 90° to each other. The primary hinge is capable of 80° of correction, while the secondary hinge is capable of 35°–45° of correction based on the position of the primary hinge. The two translating screws are capable of up to 3 cm of correction in an orthogonal plane (90° to each other). Further components (rings, arcs, rotating arcs, or linear compression/distraction devices) can be subsequently attached to the MAC device, depending on its location on the extremity (Fig. 1).

For the correction of radial deviation in this series of cases, the primary hinge of the MAC fixator is centered on the center of rotation of angulation (CORA) along the ulna, and angulated to match the deformity [21, 22]. A rotational arc capable of at least 80° of rotational correction is attached proximally to the primary hinge, and a compression/distraction clamp is attached to the MAC fixator distally. Three bicortical hydroxyapatite-coated cortical screws are placed proximally, which do not have to be

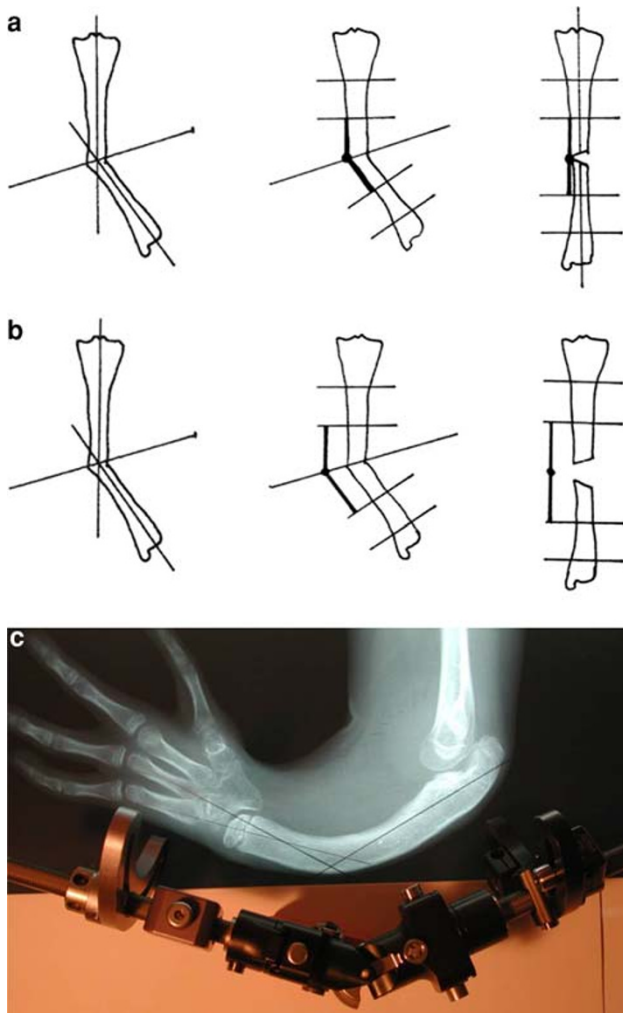


Fig. 1 **a, b** Appropriate alignment options for the primary hinge of the multi-axial correction (MAC) fixator along the ulnar center of rotation of angulation (CORA) for angular deformity correction only or angular correction with lengthening. **c** Composite image of appropriate alignment of the MAC fixator along the ulnar CORA demonstrated on a radiograph

perpendicular to the ulna. Three screws are placed distally in the medial aspect of the ulna or across the carpals.

The ulnar osteotomy is performed distal to the CORA from the lateral aspect of the ulna in order to avoid damage to the vasculature and nervous tissue. No corrections are performed acutely to avoid ulnar nerve stretch injury. In the first post-operative week, patients are taught to perform range of motion exercises at the ipsilateral shoulder, elbow, and hand. Post-operatively, patients are taught to turn the compression/distraction mechanism for distraction of the osteotomized ulnar bone fragments. Lengthening is carried out at a rate of 1–2 cm per month, until satisfactory length is achieved. Monthly X-rays are obtained until consolidation, usually over 6 or 7 months, after which the device is removed. Sports are not permitted until at least 6 weeks

after removal of the fixator, and contact sports are not permitted for 6 months.

Results/case series

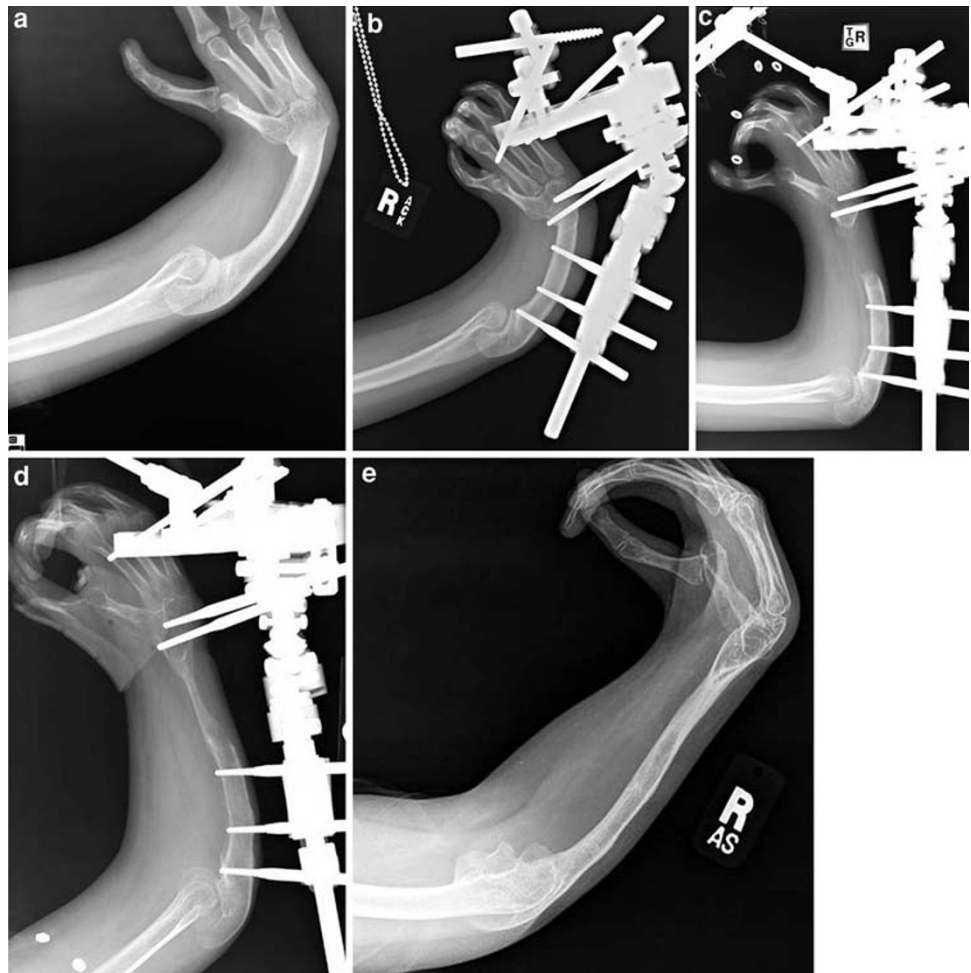
Three cases of radial club hand were identified, all of which were associated with VATER (vertebrae, anus, trachea, esophagus, and renal) syndrome. Two of the patients had bilateral radial club hand, while one had unilateral deficiency. A total of four limbs underwent application of the MAC fixator; the results were followed through the removal of each device.

Patient 1 presented at age 16 years with severe bilateral radial club hand. She had previous carpal slot centralizations and stabilization of her wrists bilaterally at age 2 years with subsequent pollicization. The right wrist was fixed in a position of 40° pronation, 45° flexion, and 30° radial deviation. The left wrist demonstrated a 60° arc of palmar flexion; radial angulation was 40°, and ulnar angulation was 10°. An MAC fixator was applied to the right arm for 216 days for ulnar deformity and length correction, arc of motion improvement, and more functional wrist alignment. At the latest follow-up, subsequent to fixator removal, the patient had improved alignment of the wrist and is capable of extension to 20° from normal. There was a 5-cm gain in ulnar length from an initial length of 10 cm (Fig. 2).

Patient 2 presented at age 17 years with severe bilateral radial club hand. He had previously failed non-slot centralization/stabilization attempts at both wrists at age 2 years without pollicization or tendon transfer. There was a 90° annular bend of the left ulna and moderate bowing of the right ulna. His right wrist was fairly centered on the ulna, while the left wrist was on the radial side of the ulna. Both wrists were radially deviated and had limited mobility. MAC fixator systems were applied to the left and right arms sequentially for 245 and 173 days, respectively, in order to achieve lengthening and correction of ulnar bowing. Deformity was corrected successfully in both arms, with the left forearm lengthened an additional 8 cm from 10 cm, and the right forearm lengthened an additional 7 cm from 10 cm. Following alignment and lengthening, the MAC fixation device on the left wrist was used to achieve centralization. After the correction of wrist alignment and stable fusion, the fixator was removed after 188 days.

Patient 3 presented at age 10 years with a severe radial club hand. He had a previous failed centralization procedure at age 3 years with subsequent pollicization. After a right wrist arthrotomy and flexion contracture release with a flexor carpi ulnaris to extensor carpi ulnaris transfer was not tolerated, surgical lengthening with the MAC fixator

Fig. 2 **a** Pre-operative radiograph of the right ulna of Patient 1. **b** Post-operative radiograph of the right ulna of Patient 1 demonstrating appropriate alignment of the MAC fixator and the placement of proximal and distal screws. **c** Three-months post-operative radiograph of the right ulna of Patient 1 subsequent to osteotomy and tissue distraction. **d** Eight-months post-operative radiograph of the right ulna of Patient 1 with continued lengthening and bone growth. **e** Twelve-months post-operative radiograph of the right ulna of Patient 1 after removal of the MAC fixator with final achieved angular and length correction



was pursued. The right wrist was passively extensible to near full extension, but no active wrist extension was present. An osteotomy was performed with application of the MAC fixator. After 260 days with the device in place, alignment had been restored and 8 cm of lengthening was achieved from 11 cm (Fig. 3).

Discussion

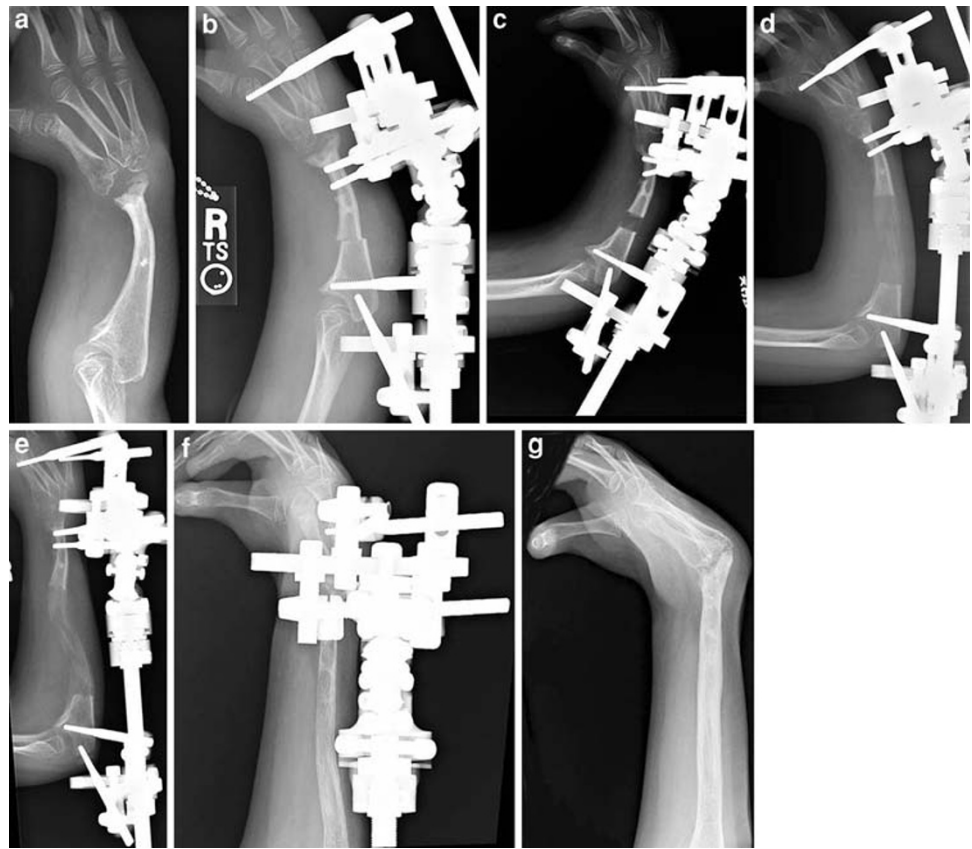
The MAC fixation system has been available and clinically used for some time now. The purpose of this study was to answer the following question: is it possible to successfully correct the deformity in severe congenital radial club hand, with lengthening of the forearm and wrist stabilization, using the MAC device? The other point of the study was to establish if the device, technique, and treatment process was considered to be cumbersome by the patients/parents.

We present a retrospective review of three cases of severe congenital radial club hand that proved to be resistant to initial soft tissue surgeries and demonstrated progressive deformity. Corrective treatment was essential

not only for deformity correction, but also to gain forearm length for functional improvement (increasing oral/aboral reach and overhead range of motion) and to stabilize the wrist. Traditionally at our institution, the circular external fixation system of Ilizarov has been used for ulnar lengthening and deformity correction in these cases [1, 23]. However, there can be some challenges with the Ilizarov device, especially in the pediatric patient population, being heavy, technically challenging to apply, and bulky in terms of occupying space. The MAC fixation system is presented in this study as an alternative to the complex circular external fixation system.

In this current study, we have shown the utility of the MAC fixation system for multi-axial deformity correction and gradual lengthening in severe radial club hand. The device is surgeon-friendly, and its technical application and adjustment could be learned very quickly. The placement and adjustment of the device requires no special instrumentation and can be easily conducted via follow-up radiographs that are available in all practice locations. Patients may readily adjust the fixator from home as per the surgeon's directions for progressive correction. The

Fig. 3 **a** Pre-operative radiograph of the right ulna of Patient 3. **b** Post-operative radiograph of the right ulna of Patient 3 demonstrating appropriate alignment of the MAC fixator and the placement of proximal and distal screws and osteotomy site. **c** One-month post-operative radiograph of the right ulna of Patient 3 with tissue distraction. **d** Two-months post-operative radiograph of the right ulna of Patient 3 with continued lengthening and bone growth. **e** Three-months post-operative radiograph of the right ulna of Patient 3 with continued lengthening and bone growth. **f** Seven-months post-operative radiograph of the right ulna of Patient 3 with continued lengthening and bone growth. **g** Eleven-months post-operative radiograph of the right ulna of Patient 3 after removal of the MAC fixator with final achieved angular and length correction



complications associated with the placement and maintenance of the device are equal to or less than that associated with the use of other fixators; an occasional over-correction may be addressed by outpatient device adjustment, without removal/replacement of the fixator or complicated analysis. Lastly, the device itself is significantly less cumbersome than other circular external fixators, and it is tolerated better by pediatric patients.

The MAC external fixation system is a versatile approach to upper limb deformities, and it is capable of correction of carpal translation for wrist stabilization while improving hand and limb function, in addition to gradual lengthening. This series of three cases represents the unique utilization of the MAC fixator in treating four different aspects of treatment of the radial club hand deformity: the fixator system may be used for ulnar lengthening and straightening after previous wrist centralization (Patient 1), for ulnar lengthening and straightening in the case of an unstable wrist (Patient 2), for wrist distraction and centralization preceding fusion (Patient 2), and simultaneous ulnar lengthening and straightening with wrist stabilization (Patient 3).

There are limitations to this study. As it is a retrospective case series, no control group is available to compare the utilization of the MAC fixation system to another acceptable method. Furthermore, as the application of the

fixator is case-dependent, and individual cases of radial longitudinal deficiency are often heterogeneous, the consistency of quantitative comparative measures between cases is limited. Finally, a clinical assessment of each of these patients was not performed due, in part, to the difficulty of quantifying the gain of function and patient satisfaction, and the difficulties in requiring corrected patients to return for follow-up several years after discharge from care.

In conclusion, this case series suggests that the MAC fixation system is a successful alternative modality of using external fixation in the correction of deformity associated with radial club hand and results in effective ulnar lengthening. The desired clinical outcomes are achieved with minimal complications. The MAC system offers many advantages over circular external fixation techniques and implements, including ease of application by the clinician and toleration by the patient. The MAC external fixator is a viable option for the surgical correction of radial longitudinal deficiencies and should be a part of the surgical armamentarium in deformity correction.

Acknowledgments There were no grants or external sources of funding utilized for this study.

Conflict of interest statement The authors declare no conflict of interest.

Open Access This article is distributed under the terms of the Creative Commons Attribution Noncommercial License which permits any noncommercial use, distribution, and reproduction in any medium, provided the original author(s) and source are credited.

References

- James MA, Bednar M (2005) Deformities of the wrist and forearm. In: Wolfe SW, Hotchkiss RN, Green DP, Pederson WC (eds) Green's operative hand surgery. Elsevier, Philadelphia, pp 1469–1506
- James MA, McCarroll HR Jr, Manske PR (1999) The spectrum of radial longitudinal deficiency: a modified classification. *J Hand Surg Am* 24:1145–1155
- Giele H, Giele C, Bower C et al (2001) The incidence and epidemiology of congenital upper limb anomalies: a total population study. *J Hand Surg Am* 26:628–634
- Goldfarb CA, Wall L, Manske PR (2006) Radial longitudinal deficiency: the incidence of associated medical and musculoskeletal conditions. *J Hand Surg Am* 31:1176–1182
- Bayne LG, Klug MS (1987) Long-term review of the surgical treatment of radial deficiencies. *J Hand Surg Am* 12:169–179
- Goldfarb CA, Murtha YM, Gordon JE et al (2006) Soft-tissue distraction with a ring external fixator before centralization for radial longitudinal deficiency. *J Hand Surg Am* 31:952–959
- Kessler I (1989) Centralisation of the radial club hand by gradual distraction. *J Hand Surg Br* 14:37–42
- Nanchahal J, Tonkin MA (1996) Pre-operative distraction lengthening for radial longitudinal deficiency. *J Hand Surg Br* 21:103–107
- Sabharwal S, Finuoli AL, Ghobadi F (2005) Pre-centralization soft tissue distraction for Bayne type IV congenital radial deficiency in children. *J Pediatr Orthop* 25:377–381
- Smith AA, Greene TL (1995) Preliminary soft tissue distraction in congenital forearm deficiency. *J Hand Surg Am* 20:420–424
- Buck-Gramcko D (1985) Radialization as a new treatment for radial club hand. *J Hand Surg Am* 10:964–968
- Manske PR, McCarroll HR Jr, Swanson K (1981) Centralization of the radial club hand: an ulnar surgical approach. *J Hand Surg Am* 6:423–433
- Watson HK, Beebe RD, Cruz NI (1984) A centralization procedure for radial clubhand. *J Hand Surg Am* 9:541–547
- Catagni MA, Szabo RM, Cattaneo R (1993) Preliminary experience with Ilizarov method in late reconstruction of radial hemimelia. *J Hand Surg Am* 18:316–321
- Horii E, Nakamura R, Nakao E et al (2000) Distraction lengthening of the forearm for congenital and developmental problems. *J Hand Surg Br* 25:15–21
- Hülsbergen-Krüger S, Preisser P, Partecke BD (1998) Ilizarov distraction-lengthening in congenital anomalies of the upper limb. *J Hand Surg Br* 23:192–195
- Kawabata H, Shibata T, Masatomi T et al (1998) Residual deformity in congenital radial club hands after previous centralisation of the wrist. Ulnar lengthening and correction by the Ilizarov method. *J Bone Joint Surg Br* 80:762–765
- Peterson BM, McCarroll HR Jr, James MA (2007) Distraction lengthening of the ulna in children with radial longitudinal deficiency. *J Hand Surg Am* 32:1402–1407
- Pickford MA, Schecker LR (1998) Distraction lengthening of the ulna in radial club hand using the Ilizarov technique. *J Hand Surg Br* 23:186–191
- Raimondo RA, Skaggs DL, Rosenwasser MP et al (1999) Lengthening of pediatric forearm deformities using the Ilizarov technique: functional and cosmetic results. *J Hand Surg Am* 24:331–338
- Paley D (2002) Principles of deformity correction. Springer, New York
- Paley D, Herzenberg JE, Tetsworth K et al (1994) Deformity planning for frontal and sagittal plane corrective osteotomies. *Orthop Clin North Am* 25:425–465
- Lourie GM, Lins RE (1998) Radial longitudinal deficiency. A review and update. *Hand Clin* 14:85–99