

in morbidity and needless frustration for the operating surgeon. The technique described here overcomes these difficulties while achieving gold standard repair.

References

1. Lighthart WA, Cohen DA, Levine RG *et al.* Suture anchor versus suture through tunnel fixation for quadriceps tendon rupture: a biomechanical study. *Orthopedics* 2008; **31**: 441.
2. Rasul AT, Fischer DA. Primary repair of quadriceps tendon ruptures. Results of treatment. *Clin Orthop Relat Res* 1993; **289**: 205–207.

T-shaped mesh improvisation for laparoscopic ventral mesh rectopexy: a novel technique

A Bagul, A Clarke

Poole Hospital NHS Foundation Trust, UK

CORRESPONDENCE TO

Anil Bagul, E: anil.bagul@nhs.net

BACKGROUND

Laparoscopic ventral mesh rectopexy using a composite mesh is a technique gaining more recognition for management of pelvic floor disorders such as full thickness rectal prolapse, obstructive defecation symptoms and vaginal vault prolapse. A recent Cochrane review concluded that laparoscopic rectopexy results in fewer postoperative complications and an earlier discharge¹ over open methods.² We describe a novel technique for preparation of the mesh.

TECHNIQUE

Two longitudinal pieces of the standard 3cm x 20cm strip of polypropylene or polyester mesh are used; the second piece is placed at right angles to prepare a T shape. The second piece is stitched with four sutures, forming a T shape (Fig 1).

DISCUSSION

This prepared mesh is cheaper than pre-packed/shaped meshes. The T shape allows better sitting in the pelvis. It improves area for fixation to the anterior rectum and offers better support.

References

1. Bachoo P, Brazzelli M, Grant A. Surgery for complete rectal prolapse in adults. *Cochrane Database Syst Rev* 2000; **2**: CD001758.
2. Tou S, Brown SR, Malik AI, Nelson RL. Surgery for complete rectal prolapse in adults. *Cochrane Database Syst Rev* 2008; **4**: CD001758.

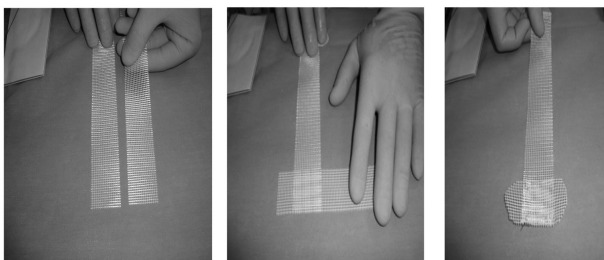


Figure 1 Construction of T-shaped mesh

How to avoid bulky knots when using loop sutures

R Durai, T Oke

Department of Surgery, Queen Elizabeth Hospital, Woolwich, London, SE18 4QH

CORRESPONDENCE TO

Rajaraman Durai, E: dr_durai@yahoo.com

BACKGROUND

Monofilament absorbable and non-absorbable sutures are commonly used for closure of the anterior abdominal wall during laparotomy. Monofilament sutures have a memory and, as a result, have a poor knot holding capacity: 5–6 throws are required to make the knot secure. The resultant bulky knot can be difficult to bury and, when it is not buried properly, the patient may suffer from pain, a palpable lump or a stitch sinus resulting in a persistent discharge. We report a simple method that can be used to reduce the bulkiness of the knot.

TECHNIQUE

This technique is used for the closure of pfannenstiel and transverse incisions where one suture is sufficient enough to close the entire abdominal wall. Once the abdominal wall wound is closed by one continuous loop suture, instead of making an Aberdeen knot, one of the two threads attached to the needle is cut and passed under the loop of the thread. The two individual ends of the thread are tied together, the excess length of the free thread is cut off and the suture attached to the needle is passed through the middle of the suture line, in the process the knot is buried (Fig 1). When two loop sutures are used to close a midline laparotomy wound (one from each end), one of the needles is cut off when the wound is fully approximated. The free thread is tied to the thread attached to the opposite needle. The excess length of the free thread is cut off and the knot is buried in the suture line; the 4 threads of suture including the remaining needle are cut flush on the wound.

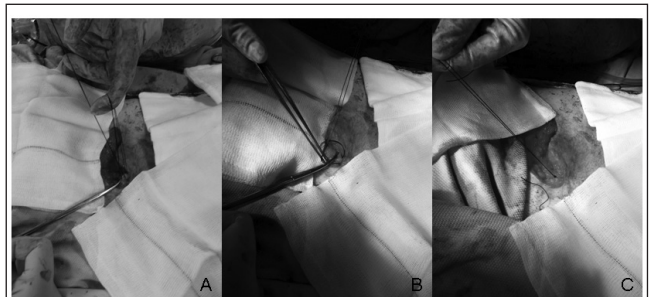


Figure 1 Figure 1 A) Before feeding the suture through the loop B) Passing the suture through the loop C) Completed knot with 6 throws

DISCUSSION

The main purpose of this technique is to make the knot less bulky and easy to bury. With several years of use, we have not encountered any stitch sinuses from this method. It is simple, quick, easy and reproducible without any difficulty. This technique reduces the bulk of the knot and enables the knot to be completely buried in the wound.