



Case report

Cryptococcosis as a cause of organizing pneumonia

Ayumi Chikumoto^a, Keiji Oishi^{b,*}, Kazuki Hamada^a, Kazuki Matsuda^a, Sho Uehara^a, Ryo Suetake^a, Yoshikazu Yamaji^a, Maki Asami-Noyama^a, Nobutaka Edakuni^a, Tsunahiko Hirano^a, Tomoyuki Murakami^c, Kazuto Matsunaga^a

^a Department of Respiratory Medicine and Infectious Disease, Graduate School of Medicine, Yamaguchi University, 1-1-1 Minami-Kogushi, Ube, Yamaguchi, 755-8505, Japan

^b Department of Medicine and Clinical Science, Graduate School of Medicine, Yamaguchi University, 1-1-1 Minami-Kogushi, Ube, Yamaguchi, 755-8505, Japan

^c Department of Pathology, National Hospital Organization Kanmon Medical Center, 1-1 Chofusotouracho, Shimonoseki, Yamaguchi 752-8510, Japan

ARTICLE INFO

Keywords:

Cryptococcosis
Organizing pneumonia
Immunocompromised host
Bronchoscopy
Serum cryptococcal antigen test

ABSTRACT

In cases showing organizing pneumonia (OP) with radiologic findings and pathological images, it is necessary to differentiate between idiopathic and secondary diseases as the cause of OP. *Cryptococcus* infection as a cause of OP is not well known. We herein report two cases of secondary pulmonary cryptococcosis in immunocompromised patients who showed OP, and the usefulness of bronchoscopy and serum cryptococcal antigen test for an early diagnosis. Common to both cases was that antibiotic therapy and corticosteroid therapy were ineffective, while antifungal agents were effective. In cases of immunocompromised patients who present OP with radiologic findings or pathological images, prompt administration of antifungal treatment at an early stage is important when pulmonary cryptococcosis is identified by bronchoscopy and serum cryptococcal antigen test.

1. Introduction

Pulmonary cryptococcosis is a fungal infection caused by *Cryptococcus neoformans*, which is found in the soil and grows in the feces of birds such as pigeons [1]. When the diagnosis and treatment are delayed, it can follow a fatal course by infecting the central nerve system [1]. Pulmonary cryptococcosis is classified as primary cryptococcosis that develops in immunocompetent patients and secondary cryptococcosis that develops in immunocompromised patients. Although the most common radiologic finding is nodular shadows in immunocompetent patients, in immunocompromised patients, the signs of cryptococcosis can easily be confused by the various radiologic findings such as infiltrative shadows besides the nodular shadows [2–5], which may delay timely diagnosis and treatment.

Cryptococcus infection as a cause of OP is not well known. Only a few cases have been reported so far [6–10]. We herein report two cases of pulmonary cryptococcosis in immunocompromised patients who showed OP with radiologic findings and pathological images and became worse when receiving corticosteroid therapy. Bronchoscopy and serum cryptococcal antigen test were useful for the diagnosis and prompt administration of antifungal treatment was effective.

2. Case report

2.1. Patient 1

A 65-year-old woman was diagnosed as a neurosarcoidosis and oral administration of prednisolone (PSL) 45 mg/day was started. Methotrexate (MTX) 8 mg/week was added 4 months after PSL administration. A month later, she complained of fever and productive cough. A chest computed tomography (CT) revealed an abnormal shadow in the right upper lobe of the lung and right pleural effusion. She was treated with oral levofloxacin, but her symptoms and abnormal chest shadow did not improve. She was referred to our hospital for further examination and treatment.

Vital signs were stable and no abnormality was noted in physical examination. Laboratory testing revealed a white blood cell count of 6,670 per mm³, erythrocyte sedimentation rate of 30mm/1h, C-reactive protein of 1.2mg/dl, immunoglobulin (Ig) G of 622 mg/dl. β-D glucan and KL-6 were within normal limits. Chest radiograph showed infiltrative shadows in the upper right lobe and right pleural effusion. Chest CT revealed right dominant non-segmental infiltrative shadows, multiple nodules, and right pleural effusion (Fig. 1a). Although we suspected the possibility of MTX-induced interstitial lung disease and

* Corresponding author. Tel.: +81 836 22 2248; fax: +81 836 22 2246.

E-mail address: ohishk@yamaguchi-u.ac.jp (K. Oishi).

<https://doi.org/10.1016/j.rmcr.2019.100851>

Received 26 March 2019; Received in revised form 29 April 2019; Accepted 29 April 2019

2213-0071/© 2019 The Authors. Published by Elsevier Ltd. This is an open access article under the CC BY-NC-ND license (<http://creativecommons.org/licenses/by-nc-nd/4.0/>).

Abbreviations

BALF	bronchoscopy and bronchoalveolar lavage fluid
CT	computed tomography
Ig	immunoglobulin
MTX	methotrexate
OP	organizing pneumonia
PaO ₂	partial pressure of oxygen in arterial blood
PSL	prednisolone
TBLB	transbronchial lung biopsy

discontinued this treatment, her symptoms and chest radiograph became worse.

Considering the immunocompromised host and radiological OP pattern such as non-segmental infiltrative shadows, we had to differentiate between idiopathic, collagen diseases, infection, malignant tumors, and drug reaction as causes of OP, and therefore performed a bronchoscopy obtaining a transbronchial lung biopsy (TBLB) of the right S2 region. The biopsy specimens revealed diffuse lymphocytes in the alveolar wall, and some of the alveolar spaces contained Masson bodies, which was consistent with OP. Moreover, intra-alveolar granulomas and high fibrin precipitation and bleeding, which strongly indicated various degrees of inflammation, were revealed (Fig. 1b). Spherical fungi of large variation sizes of about several μm to 20 μm were revealed by Grocott's silver stain (Fig. 1c). According to the finding of Grocott's silver stain, we considered the possibility of *Cryptococcus neoformans* or *Pneumocystis jirovecii*. Mucicarmine staining, which stains the yeast capsule of *Cryptococcus* red [11], was negative. However, the tissue specimens also lacked the characteristic of *Pneumocystis jirovecii* such as size uniformity of 4–10 μm , crescent-shaped, helmet-shaped, and intracystic dots. In the culture test of bronchial wash, general bacteria, acid-fast bacteria and fungi were all negative. Furthermore, the serum cryptococcal antigen was positive. It is known that there is the capsule-deficient form of cryptococcus, which is negative of mucicarmine staining [12]. Finally, we diagnosed her as secondary pulmonary cryptococcosis. After fluconazole treatment, her symptoms, chest radiograph and CT finding improved (Fig. 1d).

2.2. Patient 2

A 76-year-old man was diagnosed with rheumatoid arthritis, and oral administration of PSL 8 mg/day, MTX 4 mg/week and anti-TNF- α monoclonal antibody was therefore started. 5 months after the initiation of treatment, he became feverish. A chest CT revealed infiltrative shadows of the bilateral lung fields and he was hospitalized. At the time of admission, he complained of productive cough, chest pain at inspiration and bloody sputum. MTX and anti-TNF- α monoclonal antibody were discontinued and he was treated with intravenous antibiotics. Even after that, the infiltrative shadows expanded and he developed hypoxemia. Since he did not respond to steroid pulse therapy, he was referred to our hospital.

His occupation was as a member of the zoo staff, and he had kept birds in the past. Fine crackles were heard over the bilateral lower chest. Chest radiograph showed a decrease in permeability of the bilateral lower lungs and a decrease in the volume of the right lung. Chest CT revealed non-segmental infiltrative shadows with air bronchogram and surrounding ground-glass opacity in the bilateral lungs (Fig. 2a). In the arterial blood gas analysis, partial pressure of oxygen in arterial blood (PaO₂) was 69.6 mmHg. Laboratory testing revealed a white blood cell count of 15,850 per mm³, C-reactive protein of 10.8 mg/dl, IgG of 791 mg/dl. β -D glucan and serum tumor markers in lung cancer was within normal limits. Interferon gamma release assays by T-SPOT were also negative.

Considering an immunocompromised host and radiological OP

pattern, infection, malignant tumors, and drug-induced pneumonitis could be cited as a differential diagnosis. He underwent a bronchoscopy and bronchoalveolar lavage fluid (BALF) study performed from left B5 demonstrated a cell population of 76.0% lymphocytes, 10.5% neutrophils, and 4.0% alveolar macrophages. Biopsy could not be performed because he had taken antiplatelet medicine. A few yeast-like fungi were observed by the Grocott's silver stain of BALF. A small number of *Cryptococcus neoformans* was detected from the fungal culture of BALF (Fig. 2b). The serum cryptococcal antigen was positive, therefore we diagnosed him as secondary pulmonary cryptococcosis. There was no finding suggesting cryptococcal meningitis in cerebrospinal fluid examination. After antifungal treatment, his hypoxemia, chest radiograph and CT finding were improved (Fig. 2c).

3. Discussion

We found 2 clinical issues. Secondary cryptococcosis that develops in immunocompromised patients can present as OP with radiologic findings and pathological images, and bronchoscopy and serum cryptococcal antigen test were useful for the differential diagnosis of OP. It was revealed that, in cases of OP during the acute phase of fungal infection, steroid therapy is harmful and treatment for the original disease by antifungal drug should be given priority.

Secondary cryptococcosis can present as OP with radiologic findings and pathological images. In our 2 cases, the radiological OP patterns, such as non-segmental infiltrative shadows, were observed in HRCT. Additionally, in our first case, the pathological OP pattern was proved. Some reports suggested that comparison of HRCT findings be made in primary and secondary cryptococcosis. The most common HRCT finding in primary cryptococcosis was a solitary nodule [2–5,7]. On the other hand, secondary cryptococcosis had various radiologic findings such as infiltrative shadows, multiple nodules, and especially the proportion of infiltrative shadows is high [2,7]. For the prevention of infection, the role of cell-mediated immunity centered on Th1 cells is important because *Cryptococcus* grows in macrophages. When the Th1 immune response is activated, lymphocytes and macrophages surround the *Cryptococcus* and form granulomas, which are sealed so that the fungus does not diffuse into the surrounding tissues [13,14]. For this reason, the higher proportion of infiltrative shadows may help to explain that containment of *Cryptococcus neoformans* by lymphocytes and macrophages does not work well in immunocompromised patients.

Although OP proved pathologically to be due to *Cryptococcus neoformans* is not well documented in the literature, it is interesting to note that all cases had infiltrative shadows [6–10]. According to McDonnell's pathological classification of pulmonary cryptococcosis, 4 basic morphologic patterns were observed: peripheral pulmonary granuloma, granulomatous pneumonia, intracapillary/interstitial involvement, and massive pulmonary involvement [15]. Among them, granulomatous pneumonia is typical for immunocompromised patients. In our case, based on the features of intra-alveolar granulomas and surroundings with various degrees of inflammation, it was judged as a granulomatous pneumonia pattern. As discussed so far, if a detailed pathologic examination is performed in secondary cryptococcosis showing infiltrative shadows, pathological OP might have been presented.

Bronchoscopy and serum cryptococcal antigen test were useful for the differential diagnosis of OP. Even if pathological OP was obtained, we cannot detect the underlying reason or disease unless detailed examinations are added. Grocott's silver staining is easy to grasp the characteristic structure of fungi and it is indispensable for the identification of fungal species [16]. Furthermore, the positive mucicarmine staining is helpful in distinguishing cryptococci from other fungi. In the serum cryptococcal antigen test, the cutoff value of $\geq 1:1$ showed a sensitivity of 92% and a specificity of 96.5% [17]. For definitive diagnosis, it is necessary to confirm *Cryptococcus neoformans* by biopsy or fungal culture, but since histopathological diagnosis and culture take time, serum cryptococcal antigen test, which can be carried out simply

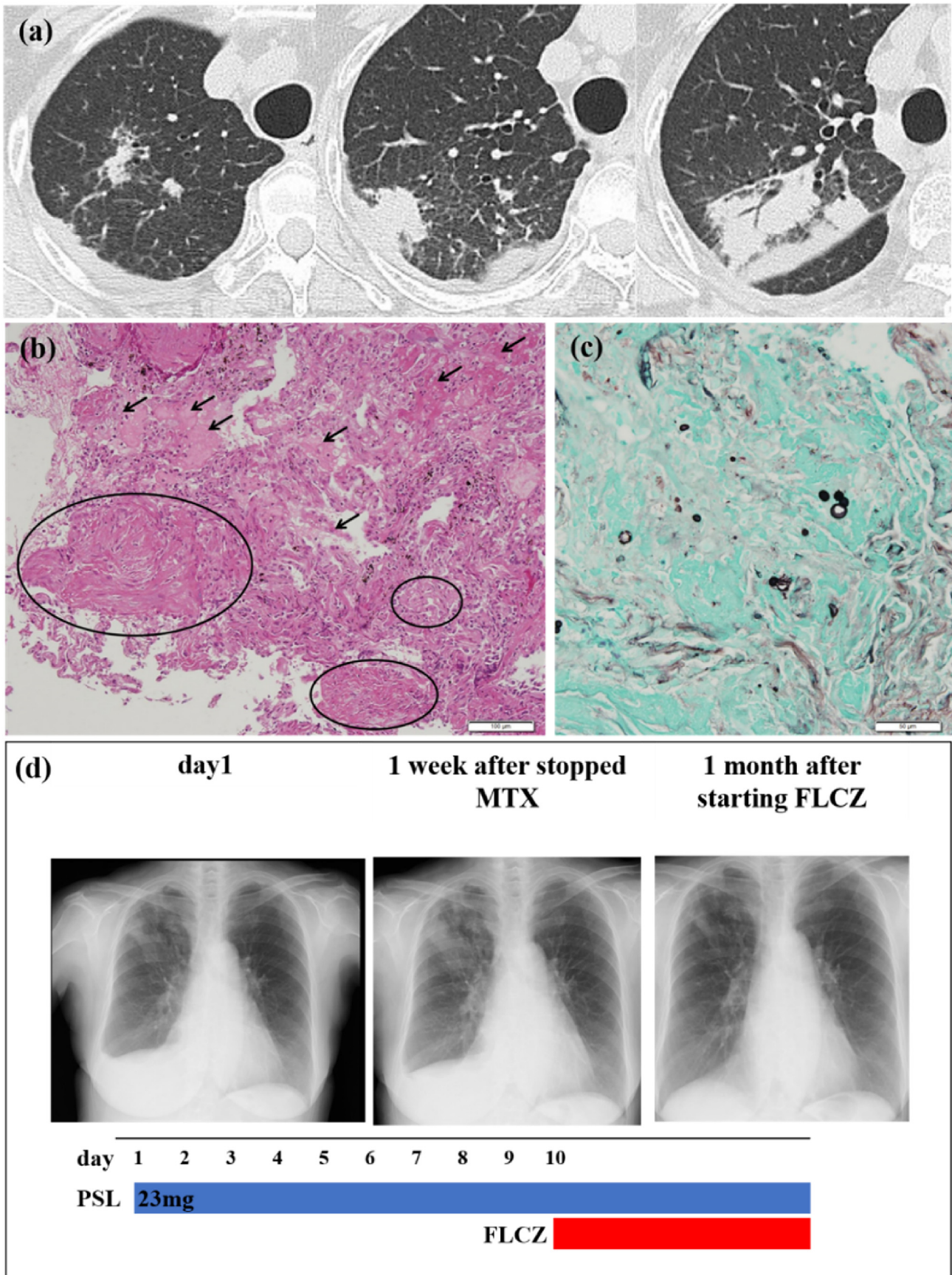


Fig. 1. (a) Chest CT revealed right dominant non-segmental infiltrative shadows, multiple nodules, and right pleural effusion. (b) Hematoxylin and eosin staining, detecting some of the alveolar spaces containing Masson bodies (circles) and showing high fibrin precipitation and bleeding (arrows). (c) Grocott's silver staining showing the spherical fungi of different sizes. (d) Treatment course of patient 1.

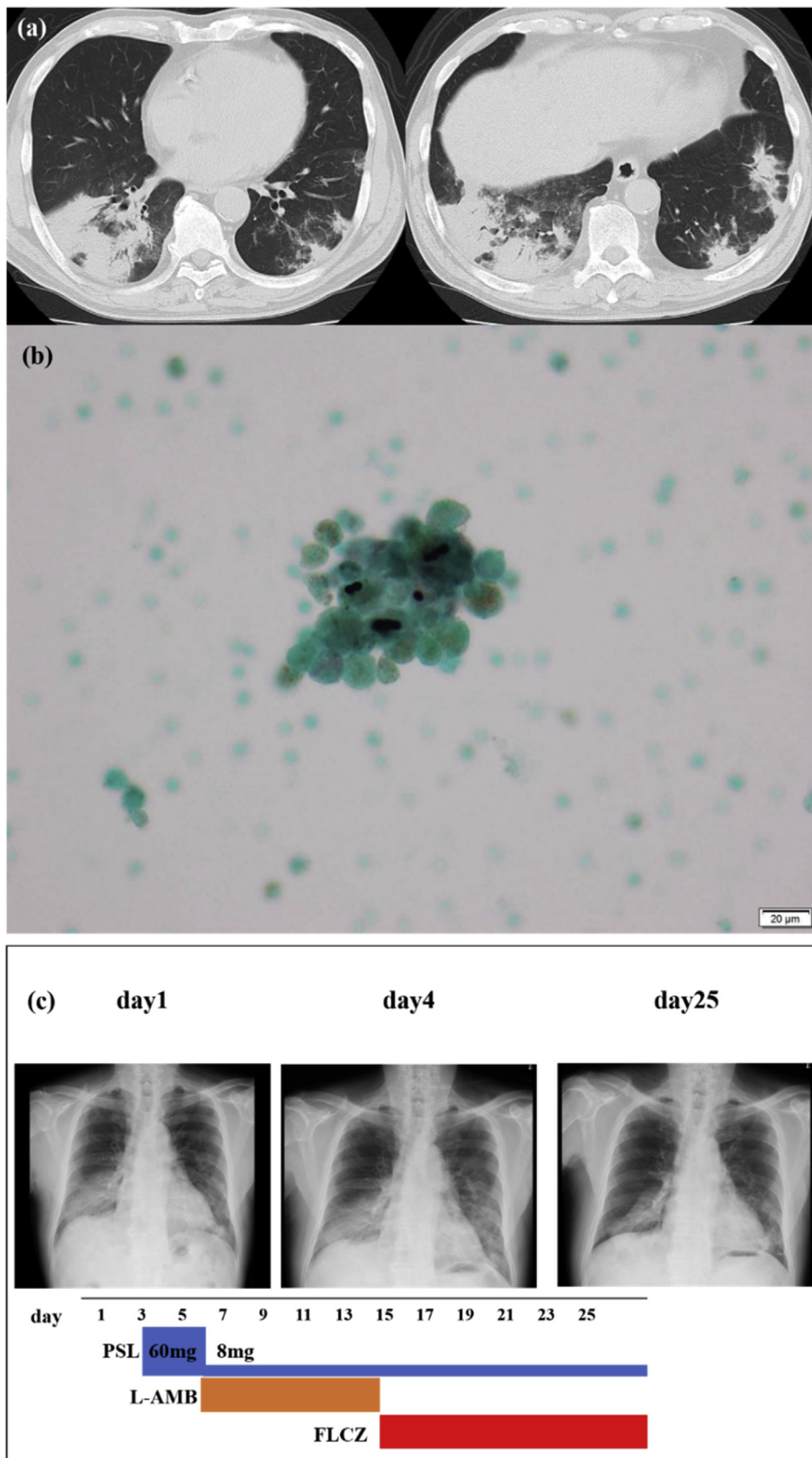


Fig. 2. (a) Chest CT revealed non-segmental infiltrative shadows with air bronchogram and surrounding ground-glass opacity in bilateral lungs. (b) A few spores of cryptococcus yeast were detected in the smear of BALF by Grocott's silver stain. (c) Treatment course of patient 2.

Table 1
Comparison between past case reports and this case report.

Case [ref.]	Year	Author	Age Sex	Radiologic findings	Pathological images	sCRAG test	Steroid therapy	Antifungal therapy
1 [6]	2004	Kishi et al.	31 M	Bilateral consolidations	OP pattern	(+)	(-)	(+)
2 [7]	2005	Ouchi et al.	54 M	Bilateral infiltrative shadows	Cryptococcus Phagocytosed by Macrophages	(+)	(-)	(+)
3 [8]	2005	Chantranuwat et al.	67 M	Bilateral multiple nodules	OP pattern, Cryptococcus in alveolar macrophages	N/A	(-)	(+)
4 [9]	2010	Taniguchi et al.	78 F	Bilateral infiltrative shadows	Multinucleated giant cell and Cryptococcus	(+)	(-)	(+)
5 [10]	2010	Kessler et al.	30 M	Bilateral consolidations	OP pattern, multinucleated giant cell with Cryptococcus	(+)	(-)	(+)
Present case (1)	2019		65 F	Bilateral non-segmental infiltrative shadows, multiple nodules	OP pattern and Cryptococcus	(+)	(+)	(+)
Present case (2)	2019		72 M	Bilateral non-segmental infiltrative shadows	N/A	(+)	(+)	(+)

Ref, reference; sCRAG, serum Cryptococcal Antigen; N/A, not applicable; OP, organizing pneumonia.

and quickly, is useful [1].

In cases showing OP, it is necessary to first consider of immune states because OP is a very specific pattern of lung repair to several different injuries. After that, we have to differentiate between idiopathic, collagen diseases, infection, malignant tumors, and drug-induced as causes of OP [18], because the appropriate treatments differ. If it is caused by idiopathic, collagen diseases or drug-induced, steroid therapy exerts beneficial effects. Conversely, in the case of OP caused by infection such as *Cryptococcus neoformans*, steroid therapy can worsen the condition [19]. Similarly, our cases were also deteriorated by the steroid therapy. There is an effectiveness of steroids for the OP of post infection. It has been reported that steroid therapy is the best treatment option for OP and the results are good, with up to 80% of individuals cured [20]. However, it has not been known until now whether steroid therapy is effective for OP in the acute phase of infection. Indeed, in the case reports on OP due to cryptococcus infection so far published, treatment with a single steroid had not been tried and so its effect was unknown (Table 1).

From our cases, it was revealed that steroid therapy is harmful if it is OP during fungal infection and that treatment for the original disease by antifungal drugs should be given priority.

In conclusion, secondary cryptococcosis that develops in immunocompromised patients can present as OP with radiologic findings and pathological images. In cases of immunocompromised patients who present as OP with radiologic findings or pathological images, or in cases in which antibiotics and steroid therapy are not successful, it is useful for the prompt administration of antifungal treatment to differentiate cryptococcal infection and to perform bronchoscopy and serum cryptococcal antigen test from an early stage. Further reports should be accumulated to establish the mechanisms in the pathogenesis of cryptococcosis as a cause of OP.

Declarations of interest

None.

Funding

This research did not receive any specific grant from funding agencies in the public, commercial, or not-for-profit sectors.

Acknowledgements

The authors thank Mr. Brent Bell for reading the manuscript.

References

- [1] E.K. Maziarz, J.R. Perfect, Cryptococcosis, *Infect. Dis. Clin. N. Am.* 30 (1) (2016) 179–206.
- [2] K. Ogata, H. Wataya, M. Morooka, M. Hamatake, S. Kaneko, H. Nakahashi, N. Hara, Pulmonary cryptococcosis : two new cases and a comparative historical review of the literature, *Jpn. Soc. Bronchol.* 19 (2) (1997) 122–126.
- [3] R.M. Lindell, T.E. Hartman, H.F. Nadrous, J.H. Ryu, Pulmonary cryptococcosis: CT findings in immunocompetent patients, *Radiology* 236 (1) (2005) 326–331.
- [4] K. Kishi, S. Homma, A. Kurosaki, T. Kohno, N. Motoi, K. Yoshimura, Clinical features and high-resolution CT findings of pulmonary cryptococcosis in non-AIDS patients, *Respir. Med.* 100 (5) (2006) 807–812.
- [5] W.C. Chang, C. Tzao, H.H. Hsu, S.C. Lee, K.L. Huang, H.J. Tung, C.Y. Chen, Pulmonary cryptococcosis: comparison of clinical and radiographic characteristics in immunocompetent and immunocompromised patients, *Chest* 129 (2) (2006) 333–340.
- [6] K. Kishi, S. Homma, A. Kurosaki, S. Nakamura, K. Yoshimura, [Primary pulmonary cryptococcosis exhibiting the radiological characteristics of bronchiolitis obliterans organizing pneumonia], *Kansenshogaku Zasshi* 78 (4) (2004) 327–330.
- [7] H. Ouchi, M. Fujita, T. Minami, I. Inoshima, Y. Nakanishi, Clinical evaluation of pulmonary cryptococcosis: including a case report of pulmonary cryptococcosis mimicking COP and a review of 17 cases, *Jpn. J. Chest Dis.* 64 (2) (2005) 161–166.
- [8] C. Chantranuwat, C. Sittipunt, Bronchiolitis obliterans organizing pneumonia caused by capsule-deficient cryptococcosis, *Southeast Asian J. Trop. Med. Publ. Health* 36 (1) (2005) 174–177.
- [9] H. Taniguchi, T. Hayashi, A. Uchiyama, K. Kambara, H. Abo, H. Shinnou, H. Miyazawa, H. Noto, S. Izumi, A case of pulmonary cyptococcosis mimicking organizing pneumonia, *Jpn. J. Chest Dis.* 69 (12) (2010) 1144–1147.
- [10] A.T. Kessler, T. Al Kharrat, A.P. Kourtis, Cryptococcus neoformans as a cause of bronchiolitis obliterans organizing pneumonia, *J. Infect. Chemother.* 16 (3) (2010) 206–209.
- [11] O. Lazcano, V.O. Speights Jr., J. Bilbao, J. Becker, J. Diaz, Combined Fontana-Masson-mucin staining of cryptococcus neoformans, *Arch. Pathol. Lab Med.* 115 (11) (1991) 1145–1149.
- [12] S.A. Harding, W.M. Scheld, P.S. Feldman, M.A. Sande, Pulmonary infection with capsule-deficient cryptococcus neoformans, *Virchows Arch. A Pathol. Anat. Histol.* 382 (1) (1979) 113–118.
- [13] K. Voelz, R.C. May, Cryptococcal interactions with the host immune system, *Eukaryot. Cell* 9 (6) (2010) 835–846.
- [14] K. Sato, K. Kawakami, Recognition of cryptococcus neoformans by pattern recognition receptors and its role in host defense to this infection, *Med. Mycol. J* 58 (3) (2017) J83–J90.
- [15] J.M. McDonnell, G.M. Hutchins, Pulmonary cryptococcosis, *Hum. Pathol.* 16 (2) (1985) 121–128.
- [16] J. Guarner, M.E. Brandt, Histopathologic diagnosis of fungal infections in the 21st century, *Clin. Microbiol. Rev.* 24 (2) (2011) 247–280.
- [17] K. Tanaka, S. Kohno, T. Miyazaki, H. Miyazaki, K. Mitsutake, S. Maesaki, M. Kaku, H. Koga, The Eiken Latex test for detection of a cryptococcal antigen in cryptococcosis. Comparison with a monoclonal antibody-based latex agglutination test, *Pastorex Cryptococcus, Mycopathologia* 127 (3) (1994) 131–134.
- [18] G.R. Epler, Bronchiolitis obliterans organizing pneumonia, *Arch. Intern. Med.* 161 (2) (2001) 158–164.
- [19] J.R. Perfect, W.E. Dismukes, F. Dromer, D.L. Goldman, J.R. Graybill, R.J. Hamill, T.S. Harrison, R.A. Larsen, O. Lortholary, M.H. Nguyen, P.G. Pappas, W.G. Powderly, N. Singh, J.D. Sobel, T.C. Sorrell, Clinical practice guidelines for the management of cryptococcal disease: 2010 update by the infectious diseases society of America, *Clin. Infect. Dis.* 50 (3) (2010) 291–322.
- [20] G.R. Epler, Bronchiolitis obliterans organizing pneumonia, 25 years: a variety of causes, but what are the treatment options? *Expert Rev. Respir. Med.* 5 (3) (2011) 353–361.