

Posttraumatic Hemicerebral Infarction in a Four-Year-Old Girl

Gholamreza Faridaalae^{1,*}; Alireza Taghian²; Tannaz Sattarzadeh Ghadim¹

¹Department of Emergency Medicine, Urmia University of Medical Sciences, Urmia, IR Iran

²Department of Neurosurgery, Urmia university of Medical Sciences, Urmia, IR Iran

*Corresponding author: Gholamreza Faridaalae, Imam Khomeini Hospital, Ershad Ave, Urmia, IR Iran. Tel: +98-9352185261, Fax: +98-4413457265, E-mail: gholamrezafaridaalae@yahoo.com

Received: November 7, 2013; Accepted: April 30, 2014

Introduction: Brain infarction after trauma is uncommon. Injury of the carotid and vertebrobasilar arteries can cause brain infarction due to occlusion of brain blood flow.

Case Presentation: Emergency medical service (EMS) brought a 4-year-old girl involved in a car accident to the emergency room. She had had seizure controlled by diazepam. She was unconscious and her Glasgow coma scale (GCS) score was eight. Early vital signs were stable. Her first brain CT scan showed a subdural hematoma (SDH). One day after admission to ICU, her GCS decreased to five; hence, a control brain CT was performed. The brain CT scan showed a brain infarction. Six days after admission, her status worsened and her GCS dropped to three and her pupils became dilated bilaterally and unresponsive to light; she was pronounced dead.

Discussion: We present an uncommon case of posttraumatic brain infarction and synchronous SDH.

Keywords: Brain Hemorrhage, Traumatic; Brain Infarction; Child

1. Introduction

Brain infarction after trauma is uncommon. Injury of carotid and vertebrobasilar arteries can cause brain infarction due to occlusion of brain blood flow. Carotid artery injury after blunt trauma occurs in 0.08% to 0.86% of cases (1-3). Hemiplegia is the most common sign of carotid and vertebrobasilar artery occlusion. We present an uncommon case of simultaneous brain infarction and subdural hematoma (SDH) after trauma.

2. Case Presentation

Emergency medical service (EMS) brought in a 4-year-old girl, who was involved in a car accident, to the emergency room (ER). The mechanism of trauma was a car accident; she was ejected from the car after it flipped. Her past medical history was noncontributory. Before arriving to ER, she had had a seizure for three minutes controlled by administration of 2 mg diazepam by EMS paramedics. Upon admission, she had temporoparietal skin abrasion and subgaleal hematoma; the child was unconscious. Her Glasgow coma scale (GCS) score was eight, (her response to pain stimulation was eyes opening, grunting, and withdrawing the limbs). The pupils were miotic with symmetrical and had a weak response to light. Neurological examination findings were symmetrical. We immediately intubated her. Early vital sign were as follows: pulse rate (PR), 150 beat/min; respiratory rate (RR), 18 breath/min; blood pressure (BP), 100/70 mm Hg; axillary temperature (AT), 36.4°C; and arterial oxygen sat-

uration (SpO₂), 98%. The primary brain computed tomography (CT) showed SDH (Figure 1). Early laboratory tests results were within normal limits. Neck, pelvic and chest radiography findings were unremarkable. Serial FAST (focus abdominal sonography for trauma) revealed no significant finding. Doppler ultrasonography revealed the carotid artery thrombosis. We admitted her to the ICU. One day after admission, her GCS score decreased to six; the attending neurosurgeon requested a control brain CT that showed hemicerebral infarction (Figure 2). Another brain CT was performed on the fifth day of admission. The next day, her condition deteriorated, her GCS score decreased to three, and her pupils became bilaterally dilated and unresponsive to light. She was pronounced dead. The latest laboratory test results showed normal values except for hypernatremia (153 mmol/L).

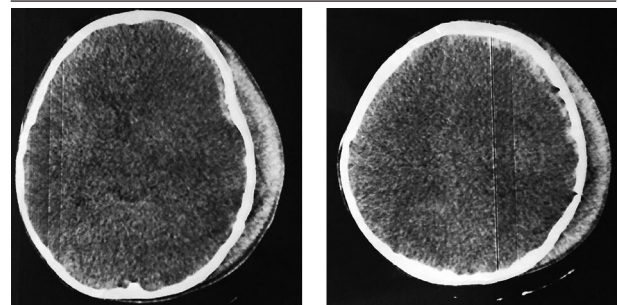


Figure 1. Brain Computed Tomography on the Day of Admission Showing a Small Subdural Hematoma

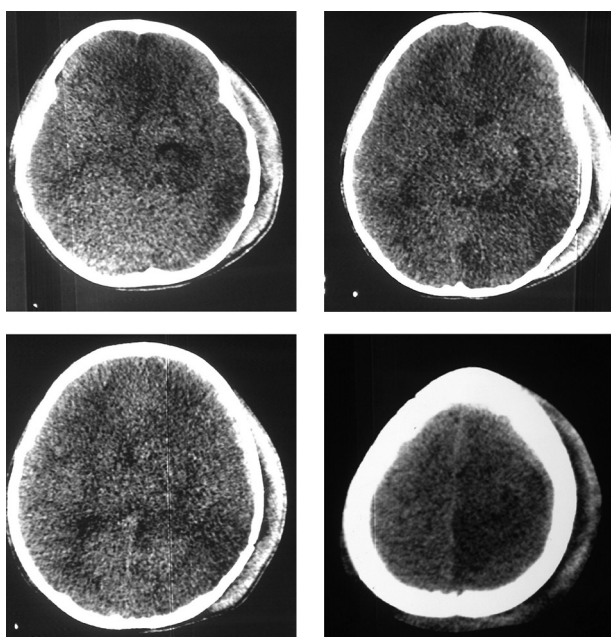


Figure 2. Brain Computed Tomography on the Second Day of Admission Showing Ischemia

3. Discussion

Our patient had brain infarction and SDH. She had no cervical spine injury or penetrating wound. She had temporoparietal abrasion and subgaleal hematoma. Brain infarction after trauma is rare (4). Estimated annual frequency rate of stroke is 27.1 per 100,000 children (one month to 12 years of age) (4). There are many risk factors for brain ischemia in children such as hematologic, inflammatory, and circulatory disorders that can be identified in 89.4% of cases (4). Spasm, thrombosis, and dissection of cranial arteries can disrupt the blood supply to the brain and lead to brain infarction (5). Arterial dissection may account for up to 20% of stroke cases in children

and adolescents (6). Viral infections predispose patients to develop arterial thrombosis after minor head injury (7). Due to the clinical presentation of brain trauma, the diagnosis of brain infarction after trauma is difficult, especially if there is brain hemorrhage with synchronous ischemia. To our knowledge, there are few studies concerning brain infarction after trauma, and we presented an uncommon case of posttraumatic brain infarction and synchronous SDH.

Acknowledgements

All authors express their sincere thanks to the Imam Khomeini Hospital staff.

Authors' Contributions

Study concept and design: Gholamreza Faridaalae and Alireza Taghian; acquisition of data: Tannaz Sattarzadeh Ghadim; drafting the manuscript: Gholamreza Faridaalae; critical revision of the manuscript for important intellectual content: Gholamreza Faridaalae.

References

1. Inamasu J, Guiot BH. Vertebral artery injury after blunt cervical trauma: an update. *Surg Neurol.* 2006;**65**(3):238-45.
2. Biffi WL, Moore EE, Elliott JP, Ray C, Offner PJ, Franciose RJ, et al. The devastating potential of blunt vertebral arterial injuries. *Ann Surg.* 2000;**231**(5):672-81.
3. Yanagawa Y, Iwamoto S, Nishi K. Pontine infarction induced by injury of the perforating branch of the basilar artery after blunt head impact: case report. *Neurol Med Chir (Tokyo).* 2008;**48**(8):343-6.
4. Salih MA, Abdel-Gader AG, Al-Jarallah AA, Kentab AY, Alorainy IA, Hassan HH, et al. Stroke in Saudi children. Epidemiology, clinical features and risk factors. *Saudi Med J.* 2006;**27** Suppl 1:S12-20.
5. Shaffer L, Rich PM, Pohl KR, Ganesan V. Can mild head injury cause ischaemic stroke? *Arch Dis Child.* 2003;**88**(3):267-9.
6. Williams LS, Garg BP, Cohen M, Fleck JD, Biller J. Subtypes of ischemic stroke in children and young adults. *Neurology.* 1997;**49**(6):1541-5.
7. Bodensteiner JB, Hille MR, Riggs JE. Clinical features of vascular thrombosis following varicella. *Am J Dis Child.* 1992;**146**(1):100-2.