

Report of a Hydatid Cyst Case with Biceps Brachii Involvement

Abstract

Muscular hydatid cyst is a rare condition mainly secondary to the cysts from other organs. We hereby present an uncommon case of primary hydatid cyst found in the right biceps brachii muscle of a 36-year-old male. Magnetic resonance revealed no *Echinococcus* involvement in any other part of his body. Chest X-ray was normal, and no trace of cyst was found in the lung. In areas where echinococcosis is endemic, any tumor or mass in any part of the patient's body should be evaluated and examined for *Echinococcus* infestation. This paper is the second case report article on echinococcal biceps brachii infestation existing to this date.

Keywords: *Asymptomatic diseases, biceps brachii, echinococcosis, muscle, report*

Introduction

Echinococcosis (hydatidosis or hydatid disease) is a rare condition caused by the larval stages of the cestode *Echinococcus granulosus* (class Cestoda, in the family Taeniidae, of the genus *Echinococcus*). Although the parasite is ubiquitously distributed, South America, Central Asia, and the Mediterranean Basin are endemic areas.^[1]

Intramuscular hydatid cysts are mainly secondary. Therefore, if not accompanied by any other infestation sites or clinical manifestations, primary hydatid cyst in skeletal muscles is a very rare condition, reported in 1%–4% of echinococcal infection reports.^[2-4] One hypothesis suggests that this scarceness of muscular infestation is due to the presence of lactic acid in the muscular tissues.^[5] Hereby, we introduce the second case of biceps brachii involvement of hydatid cyst, reported to this date.

Case Report

E. J., a 36-year-old male, referred to Al-Zahra Hospital, which is a referral hospital in Isfahan, Iran, on May 31, 2017. He is married, has a bachelor's degree, and currently works as an employee at an office downtown Isfahan. However, he mentioned formerly working as a butcher and has had multiple direct contacts with

the sheep and dogs when we seek his past history. Six months before referring to us, he had a small palpable sensation of a mass in the right arm for the first time. The mass was gradually growing. At the time of physical examination, as well as any other time in this whole 6-month duration of the disease, he never experienced any form of constitutional signs and symptoms (e.g. fever, shivering, musculoskeletal pain, diaphoresis, or weight loss) or any kind of rashes. Family history of such a condition was negative. Due to his former job and his exposure with the sheep from endemic areas in Isfahan, we clinically suspected an *Echinococcus* infection and obtained a chest X-ray, a lung multislice computed tomography scan, an intra-abdominal sonogram, complete blood count, and hemoglobin. All of the primary paraclinical results were normal. We thereafter obtained a magnetic resonance imaging (MRI) scan and a sonogram of the right arm. Figure 1 shows the patient's biceps brachii MRI documented by a camera. As shown in Figure 1, MRIs were obtained in short interval of time inversion-recovery, and T2-weighted sequences and were suggestive of a cyst without any invasion which enhanced our clinical suspicion. We referred the patient to the surgery department for biopsy taking and diagnosis confirmation. After the operation, in which the cyst was completely resected, biopsy samples were taken to

**Hassan Salehi,
Kiarash Salimi
Boroujeni¹,
Shoeleh Yaghoubi**

*From the Department of
Infectious Diseases, Isfahan
University of Medical Sciences,
¹Faculty of Medicine, Isfahan
University of Medical Sciences,
Isfahan, Iran*

*Address for correspondence:
Dr. Shoeleh Yaghoubi,
Department of Infectious
Diseases, Isfahan University of
Medical Sciences, Isfahan, Iran.
E-mail: sholeyaqubi@gmail.com*

Access this article online

Website: www.advbiores.net

DOI: 10.4103/abr.abr_101_18

Quick Response Code:



How to cite this article: Salehi H, Salimi Boroujeni K, Yaghoubi S. Report of a hydatid cyst case with biceps brachii involvement. *Adv Biomed Res* 2019;8:23.

Received: May, 2018. **Accepted:** January, 2019.

This is an open access journal, and articles are distributed under the terms of the Creative Commons Attribution-NonCommercial-ShareAlike 4.0 License, which allows others to remix, tweak, and build upon the work non-commercially, as long as appropriate credit is given and the new creations are licensed under the identical terms.

For reprints contact: reprints@medknow.com

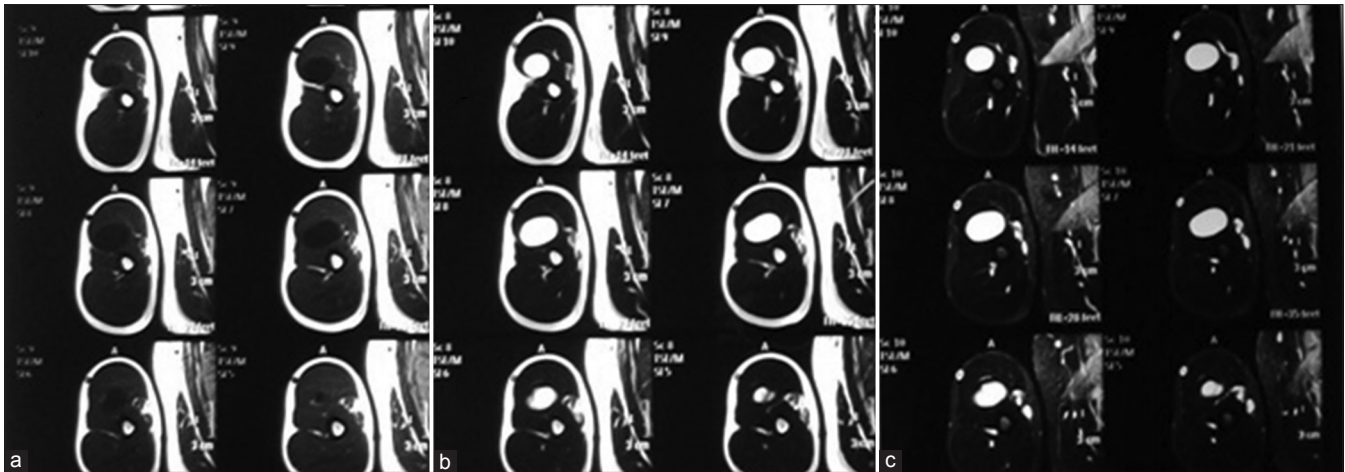


Figure 1: As it is seen in the image, the mass is low signal in T1-weighted sequence (a), high signal in T2-weighted sequence (b), and short inversion time inversion-recovery sequences (c)

the pathology laboratories. With the help of enzyme immunoassay for specific immunoglobulin G (IgG) (EIA Echinococcus Ab, Cypress Diagnostics, Langdorp, Belgium) and reversed enzyme allergosorbent test for specific IgE (REAST Allergyzen IgE, ZenTech, Angleur, Belgium), pathological reports revealed *Echinococcus* infestation of the muscle, and hydatid cyst diagnosis was confirmed.

Discussion

Diverse cases of muscle infestation in the *Echinococcus* involvement have been reported. In one of these reports, the organ of infestation was biceps brachii.^[5] However, some clinicians have reported primary involvements in other muscles as well. Psoas,^[6] biceps femoris,^[7] gluteus maximus,^[6-9] sartorius,^[10,11] soleus,^[12] adductor magnus,^[13] gluteus medius,^[14] thoracic wall muscles,^[15] pterygoids,^[16] and supraspinatus^[17] were a handful of examples of what we found in the databases for primary muscle infestations.

Early diagnosis of this infection is a difficult job, even in the more common hepatic or pulmonary cases. However, the diagnosis becomes even harder when the primary symptoms are associated with a primary mass in the musculoskeletal system. The main clue here is that the patient is coming from an endemic area and has a frequent job/life exposure and/or that the mass shows a slow pace of growth and does not invade the surrounding tissues, leaving a smooth margin.

Conclusion

Hydatid cyst should be considered as one of the main differential diagnoses in such conditions. Judging by the nonaggressive behavior of the tumor, its low growth pace, imaging results, serological results, and immunohistochemical assays (and even DNA tests), such a diagnosis in endemic areas is rather likely. One question remains:

What caused this parasite to infiltrate in this individual's biceps brachii? What could possibly have eased up the process? This question remains unanswered, and further investigations are necessary.

Declaration of patient consent

The authors certify that they have obtained all appropriate patient consent forms. In the form the patient(s) has/have given his/her/their consent for his/her/their images and other clinical information to be reported in the journal. The patients understand that their names and initials will not be published and due efforts will be made to conceal their identity, but anonymity cannot be guaranteed.

Financial support and sponsorship

Nil.

Conflicts of interest

There are no conflicts of interest.

References

1. Eckert J, Deplazes P. Biological, epidemiological, and clinical aspects of echinococcosis, a zoonosis of increasing concern. *Clin Microbiol Rev* 2004;17:107-35.
2. Merkle EM, Schulte M, Vogel J, Tomczak R, Rieber A, Kern P, et al. Musculoskeletal involvement in cystic echinococcosis: Report of eight cases and review of the literature. *AJR Am J Roentgenol* 1997;168:1531-4.
3. von Sinner WN. A case of primary osseous pelvic hydatid disease (*Echinococcus granulosus*). *Rofu* 1991;155:88-90.
4. Rieber A, Brambs HJ, Friedl P. CT in echinococcosis of the lumbar spine and paravertebral structures. *Rofu* 1989;151:379-80.
5. Duncan GJ, Tooke SM. Echinococcus infestation of the biceps brachii. A case report. *Clin Orthop Relat Res* 1990;(261):247-50.
6. Drimousis PG, Stamou KM, Koutras A, Tsekouras DK, Zografos G. Unusual site of recurrent musculoskeletal hydatid cyst: Case report and brief review of the literature. *World J Gastroenterol* 2006;12:5577-8.
7. Ates M, Karakaplan M. Hydatid cyst in the biceps and gluteus

- muscles: Case report. *Surg Infect (Larchmt)* 2007;8:475-8.
8. Sreeramulu PN, Krishnaprasad, Girish Gowda SL. Gluteal region musculoskeletal hydatid cyst: Case report and review of literature. *Indian J Surg* 2010;72:302-5.
 9. Arora V, Nijjar I, Gill K, Singh G. Case report: Primary hydatid cyst of muscle-a rare site. *Indian J Radiol Imaging* 2006;16:239.
 10. Rask MR, Lattig GJ. Primary intramuscular hydatidosis of the sartorius. Report of a case. *J Bone Joint Surg Am* 1970;52:582-4.
 11. Karakaş E, Çullu N, Altay N, Ozturk IA. Infected primary hydatid cyst located in the sartorius muscle. *Indian J Med Microbiol* 2013;31:412-4.
 12. Togrul E, Kalaci A, Sarpel Y, Koltay IS, Ozbarlas S. What's your diagnosis? Solitary hydatid cyst of the soleus muscle. *Ann Saudi Med* 2004;24:288, 307-9.
 13. Vicidomini S, Cancrini G, Gabrielli S, Naspetti R, Bartoloni A. Muscular cystic hydatidosis: Case report. *BMC Infect Dis* 2007;7:23.
 14. Combalia A, Sastre-Solsona S. Hydatid cyst of gluteus muscle. Two cases. Review of the literature. *Joint Bone Spine* 2005;72:430-2.
 15. Alvarez-Sala R, Gomez de Terreros FJ, Caballero P. Echinococcus cyst as a cause of chest wall tumor. *Ann Thorac Surg* 1987;43:689-90.
 16. Turki I, Turki A, Khochtali H, Bakir D, Bakir A. Pterygoïdien hydatid cyst. *Rev Stomatol Chir Maxillofac* 2005;106:27-9.
 17. Tatari H, Baran O, Sanlıdağ T, Göre O, Ak D, Manisali M, *et al.* Primary intramuscular hydatidosis of supraspinatus muscle. *Arch Orthop Trauma Surg* 2001;121:93-4.