

# Preoperative Arterial Embolization to Avoid Intraoperative Bleeding during Endoscopic Sinus Surgery for Organized Hematoma of the Maxillary Sinus: A Case Series and Literature Review

1) *Department of Radiology, Shinshu University School of Medicine, Japan*

2) *Department of Otorhinolaryngology, Shinshu University School of Medicine, Japan*

3) *Department of Laboratory Medicine, Shinshu University School of Medicine, Japan*

4) *Radiology Division of Shinshu University Hospital, Japan*

Masahiro Kurozumi<sup>1</sup>, Yutaka Takumi<sup>2</sup>, Takeshi Uehara<sup>3</sup>, Takeshi Suzuki<sup>1</sup>, Ayumi Ohya<sup>1</sup>, Jun Shinagawa<sup>2</sup>, Jun Miyagawa<sup>4</sup>, Yoshinori Tsukahara<sup>1</sup>, Akira Yamada<sup>1</sup>, Keita Tsukada<sup>2</sup>, Hiroaki Suzuki<sup>2</sup>, Yasunari Fujinaga<sup>1</sup>

## Abstract

**Purpose:** This study aimed to evaluate the safety and efficacy of preoperative arterial embolization of organized hematoma of the maxillary sinus.

**Material and Methods:** Seven patients who were pathologically diagnosed with an organized hematoma of the maxillary sinus and who underwent endoscopic sinus surgery following preoperative arterial embolization for the same from July 2013 to April 2020 at our hospital were included. A literature review of the PubMed database was performed to identify 13 cases on organized hematomas of the maxillary sinuses. The embolization and nonembolization groups comprised patients who underwent preoperative embolization ( $n = 10$ , seven from this study and three from literature) and those who did not undergo preoperative embolization ( $n = 10$ , from literature), respectively. Outcomes of embolization including embolization-related complications and postoperative bleeding were assessed, and volumes of intraoperative blood loss and duration of surgery were compared between the groups.

**Results:** No preoperative embolization-related complications were observed in our cases. The volume of surgical blood loss in the seven cases varied from 0 to 100 mL with a median of 30 mL, and the duration of surgery ranged from 45 to 166 minutes with a median of 112 minutes. The volume of blood loss was significantly lower for the embolization group than that for the nonembolization group ( $p = 0.0031$ ). There was no statistically significant difference regarding duration of surgery between the groups ( $p > 0.10$ ).

**Conclusions:** Preoperative embolization of an organized hematoma of the maxillary sinus is a safe and effective method that helps prevent serious intraoperative hemorrhage.

**Key words:** preoperative arterial embolization, intraoperative bleeding, organized hematoma, maxillary artery

(Interventional Radiology 2021; 6: 102-107)

## Introduction

Organized hematoma of the maxillary sinus is a rare pseudotumor that forms and grows via repeated bleeding and healing. It is occasionally misdiagnosed as a malignant tumor because it involves the destruction and deformation of the surrounding bone. Surgical extirpation is required for treating organized hematoma of the maxillary sinus. Organized hematomas are prone to bleeding; a case has been reported wherein ~1,600 mL of blood was lost despite ligation of the external carotid artery, requiring blood transfusion [1]. In recent years, endoscopic sinus surgery (ESS) has increased. Although the ESS has enabled relatively less invasive resection, cases with severe intraoperative hemorrhage and blood transfusion have also been reported [2, 3]. In principle, it is important to reduce the intraoperative bleeding during ESS to maintain the surgical visual field and prevent complications [4]. Therefore, preoperative embolization is considered as an effective pretreatment for ESS [5].

To the best of our knowledge, no detailed reports on the effectiveness of preoperative embolization for organized hematoma of the maxillary sinus and involving a substantial number of cases have been published thus far. Therefore, in this study, we aimed to evaluate the effectiveness of preoperative embolization in patients who underwent ESS for organized hematoma of the maxillary sinus.

## Material and Methods

### 1. Patients

Seven consecutive patients (four men and three women; mean age: 33 years) who were pathologically diagnosed with organized hematoma of the maxillary sinus were included in this study. All patients underwent ESS following preoperative arterial embolization at our institution from July 2013 to April 2020. None of the patients had a history of trauma or bleeding risk factors or had been receiving oral anticoagulants. Outcomes of the embolization such as embolization-related complications, the volume of surgical blood loss, duration of surgery, and the occurrence of postoperative bleeding were assessed.

### 2. Embolization procedures

Specialists who are certified by the Japanese Society of Interventional Radiology performed a preoperative embolization for all the patients. The femoral artery was punctured and then a 5-Fr sheath introducer was inserted. To prevent thrombus, 3,000 units of heparin were administered intravenously, followed by 1,000 units every hour. A 4-Fr catheter (Medikit's Angiographic Catheter Headhunter type, MEDIKIT CO., LTD., Tokyo, Japan) and a 0.035-inch guidewire (Radifocus® Guidewire 260 cm Angled, TERUMO CO. Tokyo, Japan) were used to select the common and external carotid arteries. Via angiograms, the max-

illary artery was confirmed to be the major feeding artery of the organized hematoma. Thereafter, the 4-Fr catheter was replaced with a 5-Fr guiding catheter (Envoy® 90 cm MPD, Johnson & Johnson K.K. Tokyo, Japan), and the tip of the guiding catheter was inserted into the external carotid artery. A 1.98-Fr microcatheter (Asahi Masters PARKWAY Soft 150 cm, ASAHI INTECC CO., LTD. Aichi, Japan) was inserted into the maxillary artery using the coaxial method. Then, angiography was performed. Continuous intraluminal irrigation of saline containing heparin (10,000 units/L) between the guiding catheter and the microcatheter was performed to prevent the formation of intracatheter thrombi. There was no visualized anastomotic channel between the ophthalmic artery and the maxillary artery wherein the embolization could cause neurological complications. The microcatheter was inserted into the pterygopalatine segment, and gelatin sponge (GS) particles (Spongel®, Astellas Pharma Inc. Tokyo, Japan) were administered intra-arterially, completing the embolization.

The GS used for embolization were prepared according to a report by Katsumori et al.[6] The disappearance of the contrast filling into the sphenopalatine, descending palatine, and posterior superior dental arteries was set as the endpoint for the embolization (**Fig. 1**). A small amount of blood supply from the facial artery on the same side and the maxillary artery on the contralateral side was observed in a few cases; however, these arteries were not embolized.

### 3. Literature review and assessment

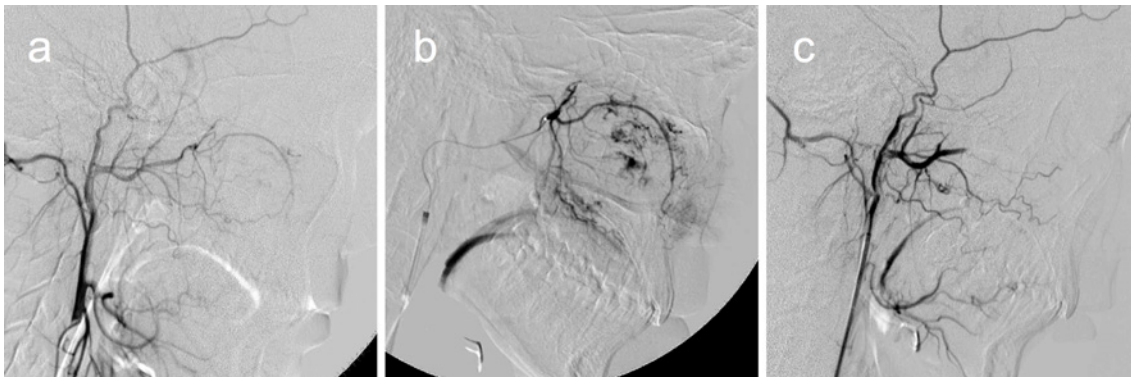We searched the PubMed database for all publications on or before April 2020 using the keywords “organized hematoma,” “maxillary sinus,” “sinonasal,” and “paranasal.” The search extracted 109 publications, all of which were reviewed. We included five papers on 13 cases wherein the following criteria were met: the lesion was primarily present in the maxillary sinus, resection was performed via ESS, and the volume of surgical blood loss was recorded [7-11]. The following items were compared: outcome of the embolization, presence of embolization-related complications, volume of surgical blood loss, duration of surgery, and the occurrence of postoperative bleeding.

### 4. Statistical analysis

To verify the effectiveness of preoperative embolization, we statistically analyzed the difference in volume of surgical blood loss and duration of surgery between the embolization (seven cases from the present study and three cases from extracted publications) and the nonembolization groups (10 cases from extracted publications). We used the Wilcoxon signed-rank test with commercially available software packages for statistical analysis (GraphPad Prism ver. 8.4.2 for Mac, Graphpad software, San Diego, CA, USA). Statistical significance was set at  $p < 0.05$ .

### 5. Ethical approval

This study was approved by our institutional review board



**Figure 1. Angiography of Case 3**

**Angiography of the external carotid artery prior to embolization (a); selective angiography of the maxillary artery (pterygopalatine segment) (b); angiography of the external carotid artery after embolization (c)**

**Increased vascularity was observed in the maxillary sinus on angiography before embolization. Following embolization, increased vascularity and maxillary artery branches were no longer observed. Blood stagnation was observed in the maxillary artery.**

**Table 1. Summary of the Seven Cases.**

Case	Age	Gender	Chief complaint	Side	Embolization	Bleeding volume (mL)	duration of surgery (min)	Complication (IVR)	Postoperative bleeding	Follow-up (month)	Recurrence
1	16	F	Nasal obstruction	R	Performed (GS)	100	166	NC	NC	12	NC
2	11	F	Left cheek pain	L	Performed (GS)	50	76	NC	NC	5	NC
3	15	M	Numbness of upper lip	R	Performed (GS)	30	98	NC	NC	12	NC
4	45	M	Nasal obstruction	R	Performed (GS)	100	45	NC	NC	12	NC
5	38	M	Epistaxis	L	Performed (GS)	0	180	NC	NC	9	NC
6	40	M	Nasal obstruction	R	Performed (GS)	20	112	NC	NC	7	NC
7	65	F	Nasal obstruction	R	Performed (GS)	0	130	NC	NC	5	NC

M, male; F, female; R, right; L, left; GS, gelatin sponge particles; NC, not confirmed

(No. 4807), and informed consent was waived due to the retrospective nature of the study.

## Results

The results obtained via the examination of our cases are shown in **Table 1**. No preoperative embolization-related complications (e.g., cerebral infarction, hematoma at the puncture site, or vascular injury) were observed in any of the seven cases treated at our hospital. In all the cases, the hematomas were found to have progressed into the nasal cavity. The mass was removed completely and easily in the seven cases with clear vision in the surgical fields during ESS. The volume of surgical blood loss for the seven cases varied from 0 to 100 mL with a median of 30 mL. The duration of surgery ranged from 45 to 166 minutes with a median of 112 minutes. No postoperative bleeding was observed. The follow-up period varied from 5 to 12 months. No recurrences were identified. The imaging findings for Case 3 are shown in **Fig. 2**.

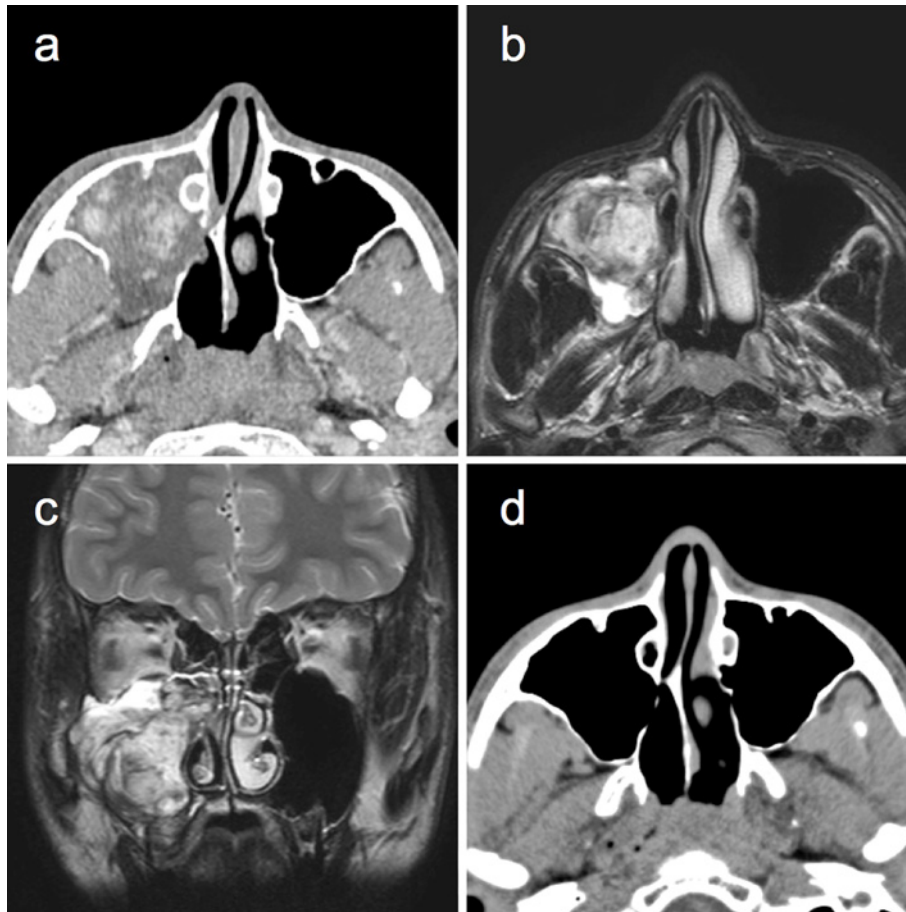
Thirteen cases were extracted from literature, all of which were reported in Japan (**Table 2**). Although Cases 8 and 10

were receiving oral anticoagulants, the medications were discontinued during the perioperative period.

Ten cases wherein preoperative embolization was performed—seven from the present study and three from literature—were allocated to the embolization group. Ten cases from literature wherein the patient did not undergo preoperative embolization were allocated to the nonembolization group.

In the three literature-derived cases of the embolization group, the volume of surgical blood loss varied from 5 to 425 mL with a median of 8 mL. The details of the embolization performed for these three cases were unknown. Although GS was used as an embolic material in two of them, the material used in the remaining case was not specified. Overall, the volume of surgical blood loss of all the ten cases of the embolization group varied from 0 to 425 mL with a median of 25 mL.

The volume of surgical blood loss of the 10 cases of the nonembolization group ranged from 30 to 700 mL with a median of 325 mL. The duration of surgery was stated for seven out of the 10 cases and ranged from 30 to 155 minutes with a median time of 95 minutes. No descriptions of



**Figure 2.** Imaging findings for Case 3

Axial image from preoperative contrast-enhanced Computed Tomography (CT) (a); fat-suppressed T2-weighted axial MR image (b); fat-suppressed T2-weighted coronal MR image (c); axial noncontrast CT 1 year after the surgery (d)

The mass lesion was enhanced and occupied the maxillary sinus. The posterior wall of the maxillary sinus was displaced, and bony erosion was observed. Marked contrast enhancement was observed inside the mass (a).

The lesion was shown as a mixture of heterogeneous signal intensity on MRI; the enhanced area on CT matched the area with high signal intensity on T2-weighted image (b).

These findings are characteristic of a chronic hematoma from which bleeding has occurred repeatedly. The lesion had progressed into the nasal cavity, and the destruction of the middle nasal concha was observed (c). No recurrence of the lesion was observed on CT 1 year after surgery. The displaced posterior wall had recovered (d).

postoperative bleeding were provided for five of the ten cases, and no postoperative bleeding was observed in the other five cases.

A comparison of the two groups revealed that the volume of surgical blood loss was significantly lower in the embolization group than in the nonembolization group ( $p = 0.0031$ ). The duration of surgery was stated for the embolization group (seven cases from the present study) and the nonembolization group (seven cases from literature). No significant difference was observed between the groups ( $p > 0.10$ ).

## Discussion

This is the first detailed report on a series of patients who underwent preoperative embolization for organized hematoma of the maxillary sinus. Previous studies have reported ESS-related complications such as sphenopalatine artery injury and pseudoaneurysm formation, which may cause major intraoperative hemorrhaging [12]. This study reports that preoperative embolization can reduce the amount of blood loss during ESS and prevent ESS-related complications. This study presents data on the sites of embolization, devices, endpoints for embolization, and angiography images from the perspective of a safe resection of organized hema-

**Table 2. Summary of the Cases Extracted from Literature.**

First author (Year)	Case	Age	Gender	Chief complaint	Side	Embolization	Bleeding volume (mL)	duration of surgery (min)	Complication (IVR)	Postoperative bleeding
Suzuki et al. (2008)	8	62	M	Epistaxis	R	NP	250	80		NC
Suzuki et al. (2008)	9	50	F	Bloody rhinorrhea	L	NP	250	70		NC
Suzuki et al. (2008)	10	57	M	Nasal obstruction	L	NP	350	110		NC
Omura et al. (2010)	11	30	F	Epistaxis	L	NP	700	ND		ND
Omura et al. (2010)	12	38	M	Epistaxis	L	Performed	425	ND	ND	ND
Omura et al. (2010)	13	31	M	Nasal obstruction	R	NP	380	ND		ND
Ohta et al. (2013)	14	14	M	Epistaxis	L	Performed (GS)	5	ND	ND	ND
Ohta et al. (2013)	15	36	F	Nasal obstruction	R	Performed (GS)	8	ND	ND	ND
Ohta et al. (2013)	16	31	M	Nasal obstruction	R	NP	65	ND		ND
Urata et al. (2013)	17	18	F	Epistaxis	R	NP	30	30		ND
Imayoshi et al. (2015)	18	35	M	Epistaxis	L	NP	700	127		NC
Imayoshi et al. (2015)	19	16	M	Nasal obstruction	R	NP	300	95		ND
Imayoshi et al. (2015)	20	40	M	Epistaxis	R	NP	450	155		NC

M, male; F, female; R, right; L, left; GS, gelatin sponge particles; NP, not performed; NC, not confirmed; ND, no description

tomas of the maxillary sinus.

Major angiographic complications such as cerebral infarction are a concern regarding embolization procedures; however, no embolization-related complications were observed in our cases. We believe that our methods were unlikely to cause neurological complications for several reasons. First, GS, a particulate embolic material that we are familiar with, was used instead of a liquid embolic material. Second, as embolization was performed only from the pterygopalatine segment, which is located distally from the maxillary artery, the absence of anastomotic branches between the internal and external carotid arteries was confirmed. Third, continuous intraluminal irrigation of saline containing heparin (10,000 units/L) between the guiding catheter and the microcatheter was performed to prevent the formation of intracatheter thrombi.

No postoperative bleeding was observed in any case of this study. It has been reported that serious post-ESS hemorrhage tends to occur within 1-2 weeks, although the severity may vary depending on the degree of surgical invasiveness, paranasal sinus mucosa inflammation, and condition of edema [5]. Miyayama et al. reported that the effect of GS lasts approximately 2-6 weeks [13]. Therefore, we believe that a decrease in the pressure of regional blood perfusion and the ischemic effect achieved by GS (which stays in the maxillary artery branches such as the sphenopalatine artery), both of which last throughout the postoperative period associated with a bleeding tendency, likely contribute to the decrease in blood loss during ESS and the prevention of postoperative bleeding and complications.

No difference in duration of surgery was observed between the groups. However, this study had a small number of cases; therefore, factors other than bleeding, such as the surgical technique used, range of lesions, and varied skill of surgeons, may be largely associated with the duration of surgery.

This study had some limitations. First, we included only a small number of cases because organized hematoma of the maxillary sinus is a rare disease. Second, the control group used for discussing the effectiveness of our technique was sourced from previously published reports; therefore, some selection biases arising from inhomogeneities in the procedure, operators, and imaging findings might have affected the results; however, this problem was unavoidable due to the difficulty in analyzing a large number of cases.

## Conclusion

Preoperative embolization of organized hematoma of the maxillary sinus is a safe and effective method that helps prevent serious intraoperative hemorrhage. Our methods are unlikely to cause neurological complications and may prevent postoperative hemorrhage.

**Acknowledgement:** We would like to thank Editage (www.editage.com) for English language editing.

**Conflict of Interest:** None

## References

- Haginomori S, Kawakami M, Takesima H, et al. Hematocele in maxillary sinus; a report of five cases. *Pract Otorhinolaryngol (Basel)* 1994; 87: 1229-1237.
- Choi SJ, Seo ST, Rha KS, Kim YM. Sinonasal organized hematoma: clinical features of seventeen cases and a systematic review. *Laryngoscope* 2015; 125: 2027-2033.
- Pang W, Hu L, Wang H, et al. Organized hematoma: an analysis of 84 cases with emphasis on difficult prediction and favorable management. *Otolaryngol Head Neck Surg* 2016; 154: 626-633.
- Haruna S. Prevention of complication after ESS procedure. *Nihon Jibiinkoka Gakkai Kaiho* 2015; 118: 736-744.
- Pant H. Hemostasis in endoscopic sinus surgery. *Otolaryngol Clin North Am* 2016; 49: 655-676.

6. Katsumori T, Nakajima K, Mihara T, Tokuhiro M. Uterine artery embolization using gelatin sponge particles alone for symptomatic uterine fibroids: midterm results. *AJR Am J Roentgenol* 2002; 178: 135-139.
7. Suzuki H, Inaba T, Hiraki N, et al. Endoscopic sinus surgery for the treatment of organized hematoma of the maxillary sinus. *Kurume Med J.* 2009; 55: 37-41.
8. Omura G, Watanabe K, Fujishiro Y, Ebihara Y, Nakao K, Asakage T. Organized hematoma in the paranasal sinus and nasal cavity—imaging diagnosis and pathological findings. *Auris Nasus Larynx* 2010; 37: 173-177.
9. Ohta N, Watanabe T, Ito T, et al. Clinical and pathological characteristics of organized hematoma. *Int J Otolaryngol* 2013; doi: 10.1155/2013/539642.
10. Imayoshi S, Kanazawa T, Fukushima N, et al. Three cases of organized hematoma of the maxillary sinus: clinical features and immunohistological studies for vascular endothelial growth factor and vascular endothelial growth factor receptor 2 expressions. *Case Rep Otolaryngol* 2015; doi: 10.1155/2015/846832.
11. Urata S, Ohki M, Tsutsumi T, Kikuchi S. Organised haematoma of the maxillary sinus: pathophysiological differences suggesting a new aetiological hypothesis. *J Laryngol Otol* 2013; 127: 519-524.
12. Campbell RG. Sphenopalatine artery pseudoaneurysm after endoscopic sinus surgery: a case report and literature review. *Ear Nose Throat J* 2012; 91: E4-E11.
13. Miyayama S, Yamakado K, Anai H, et al. Guidelines on the use of gelatin sponge particles in embolotherapy. *Jpn J Radiol* 2014; 32: 242-250.

Interventional Radiology is an Open Access journal distributed under the Creative Commons Attribution-NonCommercial 4.0 International License. To view the details of this license, please visit (<https://creativecommons.org/licenses/by-nc/4.0/>).